



ALMA MATER STUDIORUM
UNIVERSITÀ DI BOLOGNA

ARCHIVIO ISTITUZIONALE DELLA RICERCA

Alma Mater Studiorum Università di Bologna Archivio istituzionale della ricerca

[68Ga]Ga-PSMA-11 PET/CT-Positive Hepatic Inflammatory Pseudotumor: Possible PSMA-Avid Pitfall in Nuclear Imaging.

This is the final peer-reviewed author's accepted manuscript (postprint) of the following publication:

Published Version:

Monastero, F., Vetrone, L., Cardisciani, L., Renzulli, M., Prosperi, E., Cescon, M., et al. (2024). [68Ga]Ga-PSMA-11 PET/CT-Positive Hepatic Inflammatory Pseudotumor: Possible PSMA-Avid Pitfall in Nuclear Imaging. THE JOURNAL OF NUCLEAR MEDICINE, 65, 1658-1659 [10.2967/jnumed.124.267518].

Availability:

This version is available at: <https://hdl.handle.net/11585/998987> since: 2024-12-14

Published:

DOI: <http://doi.org/10.2967/jnumed.124.267518>

Terms of use:

Some rights reserved. The terms and conditions for the reuse of this version of the manuscript are specified in the publishing policy. For all terms of use and more information see the publisher's website.

This item was downloaded from IRIS Università di Bologna (<https://cris.unibo.it/>).
When citing, please refer to the published version.

(Article begins on next page)

Illustrated Post

Title

[68Ga]Ga-PSMA-11 PET/CT positive hepatic inflammatory pseudotumor: possible PSMA-avid pitfall in nuclear imaging

Authors

Fabio Monastero¹, Luigia Vetrone², Lina Cardisciani³, Matteo Renzulli⁴, Enrico Prosperi⁵, Matteo Cescon⁶, Matteo Ravaioli⁶, Stefano Fanti², Andrea Farolfi², and Francesco Vasuri⁷

Affiliations

1. Nuclear medicine, Alma Mater Studiorum University of Bologna, Bologna, Italy; fabio.monastero@studio.unibo.it
2. Nuclear Medicine, IRCCS Azienda Ospedaliero-Universitaria di Bologna, Bologna, Italy; luigia.vetrone@studio.unibo.it; stefano.fanti@aosp.bo.it; andrea.farolfi@aosp.bo.it
3. School of Anatomic Pathology, Department of Biomedical and Neuromotor Sciences, University of Bologna, 40138 Bologna, Italy; lina.cardisciani@studio.unibo.it
4. Department of Radiology, IRCCS Azienda Ospedaliero-Universitaria di Bologna, Via Albertoni 15, 40138 Bologna, Italy; matteo.renzulli@aosp.bo.it
5. Department of Hepatobiliary Surgery and Liver Transplant, IRCCS Azienda Ospedaliero-Universitaria di Bologna, Bologna, Italy; enrico.prosperi@studio.unibo.it
6. IRCCS Azienda Ospedaliero-Universitaria di Bologna, Università di Bologna, Bologna, Italy; matteo.cescon@unibo.it, matteo.ravaioli6@unibo.it
7. Pathology Unit, IRCCS Azienda Ospedaliero-Universitaria di Bologna; francesco.vasuri@aosp.bo.it

First author

Name: Fabio Monastero (RESIDENT)

Address: IRCCS Azienda Ospedaliero-Universitaria di Bologna, via Albertoni 15, 40138, Bologna,
Italy

E-mail: fabio.monastero@studio.unibo.it

Tel: +390512143194

Corresponding author

Name: Andrea Farolfi

Address: IRCCS Azienda Ospedaliero-Universitaria di Bologna, via Albertoni 15, 40138, Bologna,
Italy

E-mail: andrea.farolfi@aosp.bo.it

Tel: +390512143194

WORD COUNT: 537

Text

Prostate-specific membrane antigen (PSMA) is a trans-membrane glycoprotein highly overexpressed in many cancers and benign conditions. [68Ga]Ga-PSMA-11 PET/CT represents a successful diagnostic imaging method in nuclear medicine for prostate cancer.

This is a case of a 64-year-old woman enrolled in the MORE study, a prospective study examining the in vivo and in vitro PSMA-expression in patients with non-prostatic neoplasms with histopathology as reference standard, actively recruiting in Bologna, Italy. The study protocol was approved by the local Ethics Committee (code 538/2021/Oss/AOUBo) and subjects sign a written informed consent. Contrast-enhanced MRI revealed a lesion in ~~Vs~~ segment 5 of the liver, with late enhancement in wash-in and wash-out phases, consistent with ~~fœr~~ hepatocarcinoma (HCC).

[68Ga]Ga-PSMA-11 PET/CT (injected dose) performed 17 days later, showed increased PSMA uptake at the V_s-segment 5 (SUVmaxV_s, 11.3; SUVmax liver background, 7.9), matching the MRI lesion. 8 days after a wedge resection of the V_s-segment 5 of the liver ~~wedge resection~~ was performed.

Yellowish well-defined 2 cm nodule made of inflammatory component (mainly of histiocytes xanthogranulomatous-cells, multinucleated giant cells macrophages containing biliary pigment, with stromal fibrosis and fibroblastic proliferation) was observed, within a non-cirrhotic liver parenchyma. Plasma cells, eosinophilic nodular deposits, surrounded by foamy macrophages or neutrophils and activated myofibroblasts were also observed. Immunohistochemistry showed no cytokeratins+ epithelial cells within the lesion, while histiocytic component was CD68PGM1+/s100- with IgG4/IgG ratio <40%. Final diagnosis was hepatic inflammatory pseudotumor (fibrohistiocytic type) (1).

Both PSMA immunohistochemistry and immunofluorescence were performed: results are listed in Figure 1.

Interestingly, only endothelial cells within the pseudotumor expressed PSMA, while inflammatory cells and normal liver endothelial cells were negative. Hypothetically endothelial cells within the lesion are stimulated by tumoral microenvironment to express PSMA, even if the mechanism beyond is still not known.

Hepatic inflammatory pseudotumor is a rare disease with less than 300 cases described in literature. Differential diagnosis between pseudotumor and HCC with CT and MRI imaging is challenging. One multicentric study showed that 50% of patients with a final diagnosis of pseudotumor received a previous HCC misdiagnosis at CT/MRI (2). However, the prognosis and the treatment are different, often resolvable with more conservative approaches, avoiding ~~useless~~ unnecessary invasive procedures.

The hereby described clinical case highlights that liver lesion's characterization is challenging with PSMA-ligands due to the presence of several PSMA-avid diseases (e.g. HCC, prostate cancer metastases, hemangioma) along with physiological PSMA uptake in the liver parenchyma. Moreover, unlike prostate cancer where PSMA is overexpressed directly by cancer cells, in inflammatory pseudotumor PSMA is expressed by endothelial cells. Therefore, PSMA analysis via immunohistochemistry may support conventional imaging for liver lesions characterization. ~~even if PSMA expression, assessed in vivo with PET or in vitro through immunohistochemistry, may support conventional imaging for liver analysis.~~

DISCLOSURE

No other potential conflicts of interest relevant to this article exist.

REFERENCES

1. Zen Y, Fujii T, Sato Y, Masuda S, Nakanuma Y. Pathological classification of hepatic inflammatory pseudotumor with respect to IgG4-related disease. *Mod Pathol.* 2007; 20(8):884-94.
2. Arora KS, Anderson MA, Neyaz A, Yilmaz O, Pankaj A, Ferrone CR, et al. Fibrohistiocytic Variant of Hepatic Pseudotumor: An Antibiotic Responsive Tumefactive Lesion. *Am J Surg Pathol.* 2021 Oct;45(10):1314–23.

FIGURE

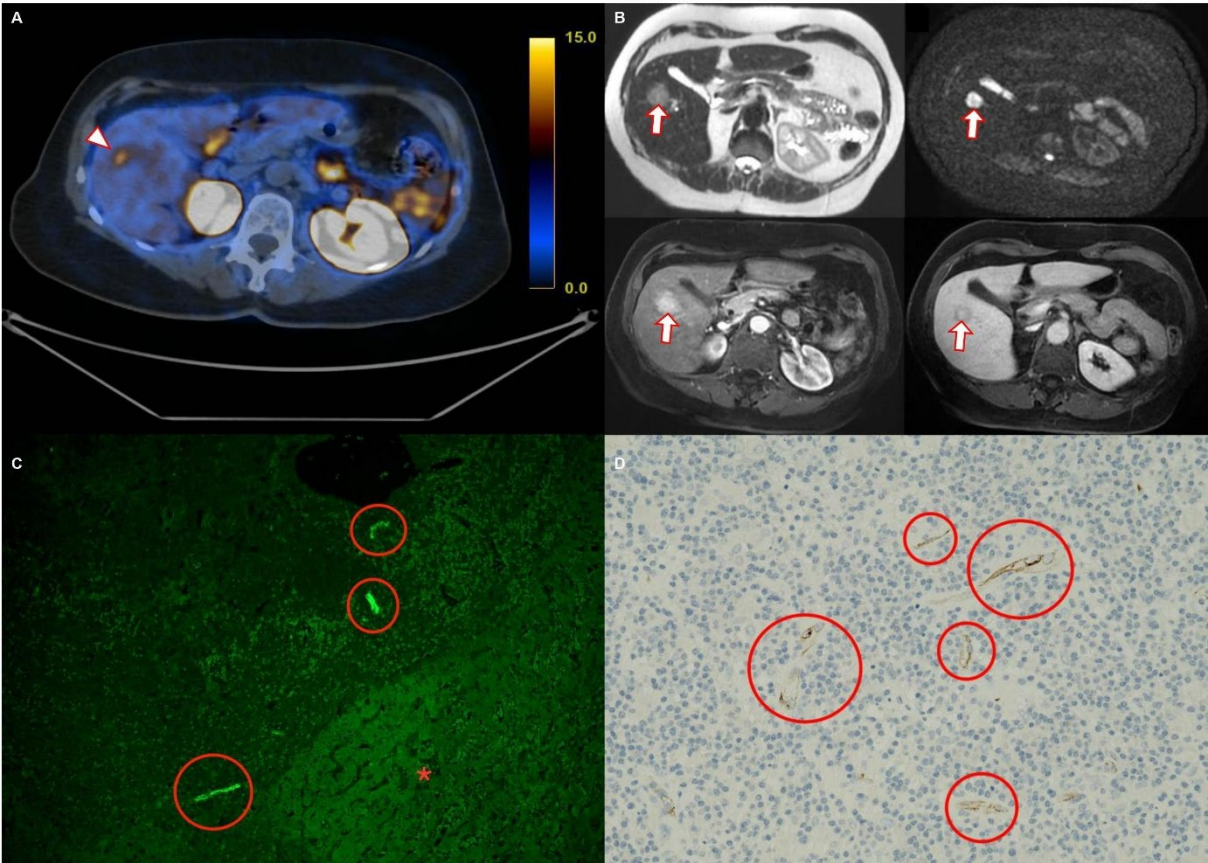


FIGURE LEGEND

(A) Axial fused [68Ga]Ga-PSMA-11 PET/CT showed increased PSMA uptake (SUVmax, 11.3), at V_s-segment 5 (arrowhead). **(B)** Gadolinium-ethoxybenzyl-diethylenetriamine pentaacetic acid MRI showed a nodule in liver segment V_s-segment 5 (arrows), hyperintense in the T2-weighted image, highly hyperintense in the diffusion-weighted image and in the arterial with targetoid sign in the transitional phase. **(C)** Negative PSMA-Immunofluorescence(10x) in normal liver parenchyma (asterisk) with adjacent inflammatory infiltrate and sparse but strongly positive endothelial cells in the intralesional microvascular component (circles). **(D)** PSMA-Immunohistochemistry(20x) sparse positive endothelial cells in the intralesional microvascular component (circles); negative inflammatory cells.