



ALMA MATER STUDIORUM
UNIVERSITÀ DI BOLOGNA

ARCHIVIO ISTITUZIONALE
DELLA RICERCA

Alma Mater Studiorum Università di Bologna Archivio istituzionale della ricerca

Identification of asinine gamma herpesviruses in a donkey with interstitial pulmonary fibrosis, pleural effusion and thrombocytopenia

This is the final peer-reviewed author's accepted manuscript (postprint) of the following publication:

Published Version:

Imposimato, I., Muscatello, L.V., Ellero, N., Lelli, D., Mira, F., Sarli, G., et al. (2024). Identification of asinine gamma herpesviruses in a donkey with interstitial pulmonary fibrosis, pleural effusion and thrombocytopenia. JOURNAL OF EQUINE VETERINARY SCIENCE, 134, 1-6 [10.1016/j.jevs.2024.105014].

Availability:

This version is available at: <https://hdl.handle.net/11585/961704> since: 2024-02-26

Published:

DOI: <http://doi.org/10.1016/j.jevs.2024.105014>

Terms of use:

Some rights reserved. The terms and conditions for the reuse of this version of the manuscript are specified in the publishing policy. For all terms of use and more information see the publisher's website.

This item was downloaded from IRIS Università di Bologna (<https://cris.unibo.it/>).
When citing, please refer to the published version.

(Article begins on next page)

1 Case Report

2 Identification of asinine gamma herpesviruses in a donkey with interstitial pulmonary fibrosis, pleural 3 effusion and thrombocytopenia

4 AUTHORS' NAMES (given name and family name) AND AFFILIATIONS:

5 Ilaria Imposimato, Department of Veterinary Medical Sciences (DIMEVET), University of Bologna, Via Tolara
6 di Sopra, 50, 40064 Ozzano dell'Emilia, Bologna, Italy

7 Luisa Vera Muscatello, Department of Veterinary Medical Sciences (DIMEVET), University of Bologna, Via
8 Tolara di Sopra, 50, 40064 Ozzano dell'Emilia, Bologna, Italy

9 Nicola Ellero, Department of Veterinary Medical Sciences (DIMEVET), University of Bologna, Via Tolara di
10 Sopra, 50, 40064 Ozzano dell'Emilia, Bologna, Italy

11 Davide Lelli, Istituto Zooprofilattico Sperimentale della Lombardia e dell'Emilia-Romagna "Bruno Ubertini",
12 Via Bianchi n. 9, 25124 Brescia, Italy

13 Francesco Mira, Istituto Zooprofilattico Sperimentale della Sicilia "A. Mirri", Via Gino Marinuzzi n. 3, 90129
14 Palermo, Italy; Department of Veterinary Science, University of Messina, Polo Universitario dell'Annunziata,
15 98168 Messina, Italy

16 Giuseppe Sarli, Department of Veterinary Medical Sciences (DIMEVET), University of Bologna, Via Tolara di
17 Sopra, 50, 40064 Ozzano dell'Emilia, Bologna, Italy

18 Francesca Freccero, Department of Veterinary Medical Sciences (DIMEVET), University of Bologna, Via Tolara
19 di Sopra, 50, 40064 Ozzano dell'Emilia, Bologna, Italy

20 CORRESPONDING AUTHOR: Imposimato Ilaria ilaria.imposimato2@unibo.it

21 FULL POSTAL ADDRESS OF CORRESPONDING AUTHOR: Via Tolara di Sopra, 50, 40064 Ozzano dell'Emilia,
22 Bologna, Italy

23 Abstract

24 A 23-year-old domestic donkey (*Equus asinus*) referred for severe respiratory distress due to suspected
25 equine asthma. Ultrasound of the chest revealed bilateral irregular pulmonary consolidation and pleural
26 effusion. Airway endoscopy and tracheal wash cytology showed severe neutrophilic inflammation and
27 bacterial culture was positive for *Streptococcus equi subsp. zooepidemicus*. Despite aggressive treatment, the
28 donkey died in 48 hours. On post-mortem examination, the lung was whitish, collapsed, and firm, with
29 fibrotic multifocal nodular areas. Pleural effusion and pleuritis were detected. Histologically, the lung
30 architecture was markedly replaced by interstitial fibrosis. The histological features observed were suggestive
31 of a severe chronic fibrosing interstitial pleuropneumonia with type 2 pneumocyte hyperplasia and
32 intralesional syncytial cells. Pulmonary fibrosis was associated with the presence of asinine
33 gammaherpesvirus 2 and 5 infection, confirmed by PCR and sequence analysis. The macroscopic and
34 histological pattern of fibrosis was diffuse and interstitial, and the nodular lesions were consistent with
35 spared lung parenchyma, instead of the canonical nodular distribution of the fibrosis observed in equine

36 multinodular pulmonary fibrosis. Asinine herpesviral pulmonary fibrosis is uncommon, but should be
37 considered by clinicians in the list of differentials in donkeys with chronic respiratory signs.

38

39 **Keywords:** asinine gammaherpesvirus, chronic lung disease, equid, histopathology, interstitial pneumonia,
40 Italy, thrombocytopenia

41

42

43 **Introduction**

44 Pulmonary fibrosis, also known as interstitial fibrosing pneumonia is a severe, uncommon fibrotic lung
45 disease of geriatric donkeys characterized by loss of pulmonary function [1,2] and marked syncytial cell
46 formation [3,4]. Pulmonary fibrosis presents an insidious diagnostic-therapeutic course in geriatric donkeys
47 [3,5,6]. Clinical signs may only become evident in the terminal stage of the disease, when severe dyspnea
48 appears [5,7]. Discriminating pulmonary fibrosis from other causes of chronic lower airway disease, such as
49 severe equine asthma represents a challenge for equine practitioners. Data concerning clinical presentation
50 and diagnostic evaluations, including imaging and tracheal/bronchoalveolar fluid analysis are limited [7]. On
51 post-mortem examination, fibrosis of subpleural and interstitial lung tissues have been occasionally reported
52 in donkeys [5].

53
54 Gammaherpesviruses (GHVs) are suspected to be involved as viral pathogens in progressive fibrosing lung
55 disease in humans, rodents, canines, felines, horses, and other equids such as Namibian mountain zebras
56 [3,6,7,8,9,10]. GHVs have occasionally been detected in both healthy and sick donkeys and mules, including
57 those with respiratory, neurological, or abortion signs [11]. Asinine gammaherpesviruses, such as asinine
58 herpesvirus 2 (also known as *Equid herpesvirus 7*), 4 and 5 (AsHV-2, -4 and -5, respectively) have been
59 identified as individual infection [3,10,12,13,14] or in association with pulmonary fibrosis in donkeys [3,4].

60
61 The age of disease onset, its clinical progression, and poor response to medical treatment are recognized as
62 similar features of donkey pulmonary fibrosis and equine multinodular pulmonary fibrosis (EMPF) in horses
63 [15]. EMPF is related to extensive nodular interstitial fibrosis in the adult horse and associated with equine
64 herpesvirus type 5 (EHV-5) infection [4,6,7]. EHV-2 and -5 co-infections are considered cofactors that
65 exacerbate clinical signs [3,4,16]. Although the pathophysiology of EMPF is largely unknown [9,15], a
66 diagnosis can be reached based on changes in thoracic radiographs and ultrasonographic images, histologic
67 examination, and detection of EHV-5 in bronchoalveolar fluid or post-mortem lung tissue [5,7].

68
69 The relationship between Epstein-Barr virus (EBV), cytomegalovirus, human herpesviruses (HHV-7 and -8)
70 and pulmonary fibrosis has been described in humans [8] and, similarly, EHV-5 and EMPF have been
71 associated in equids. Equids and rodents affected by GHVs were proposed as a model of several diseases in
72 human medicine including interstitial pulmonary fibrosis [1,6,7,15,17]. Moreover, the donkey may represent
73 a unique experimental model to elucidate the etiopathogenesis of pleuroparenchymal fibroelastosis (PPFE),
74 a human lung disease [17].

75
76 The aim of this report was to describe the clinical and histomorphological features of an unusual case of
77 pulmonary fibrosis and first detection of asinine herpesviruses from a donkey (*Equus asinus*) in northern Italy.

78 **2. Case report**

79 **2.1 Case history, clinical findings, and diagnostic examinations**

80 A 23-year-old female domestic donkey, weighing 185kg and with a low body condition score (BCS, 2/9), was
81 admitted with suspected pleuropneumonia at the Internal Medicine Unit (Department of Veterinary
82 Medicinal Sciences, University of Bologna, Italy) in September 2022. The donkey was adopted from a donkey
83 shelter and lived on a farm in Emilia Romagna (Italy) for three years, with three other female donkeys.
84 Owners provided informed consent for the veterinary treatment and for the donkey data to be
85 used for future publication.

86 Since 2015, the donkey had a history of asthma and thrombocytopenia (76×10^9 plt/L, reference range RR 95-
87 384 platelets/L), but no further diagnostic investigations were made. In August 2022, the donkey presented
88 depression, weight loss, and respiratory distress. Blood tests revealed thrombocytopenia (65×10^9 plt/L; RR
89 95-384 $\times 10^9$ /L) and increased basal ACTH concentration (177 pg/mL; RR 20-50 pg/mL). Therefore, treatment
90 for severe asthma and pituitary pars intermedia dysfunction (PPID) was started by the referring veterinarian.

91
92 In September 2022, the donkey was referred because of severe and refractory signs of respiratory distress.
93 On admission, the clinical examination revealed depression, a BCS of 2/9, pale mucous membranes,
94 tachycardia (84 bpm, RR 36-52 bpm), respiratory distress characterized by mixed dyspnea, increased
95 respiratory rate (28 breaths/min, RR 12-28 breaths/min), intercostal retraction and dilated nostrils,
96 associated with mucopurulent nasal discharge, and dry cough. On auscultation of the chest, there was a
97 decrease in bronchovesicular sounds in the cranio-ventral fields, without wheezing and crackling. Rectal
98 palpation was within normal limits. The main abnormalities on hematology and biochemistry analysis were
99 a mild neutrophilic leukocytosis, severe thrombocytopenia (15×10^9 plt/L, RR 100-600 $\times 10^9$ plt/L), signs of
100 inflammation with increased serum amyloid A (SAA) concentration (282 μ g/dl, RR 1.8–14.5 μ g/dl), and
101 hyposideremia (22 μ g/dl, RR 55-260 μ g/dl) with decreased ferritin saturation (8.6 %, RR 12-70%). Arterial
102 blood gas analysis revealed a mild respiratory acidosis characterized by pH 7.33, severe hypoxemia (PaO₂
103 40mmHg), hypercapnia (PaCO₂ 61 mmHg), and a mild hypokalemia (3.4 mmol/L mEq/L), hypocalcemia (1.58
104 mmol/L), and increased base excess (6.8mmol/L). Thoracic radiography revealed a diffuse radiopacity due to
105 pleural effusion. Thoracic ultrasonography (Fig.1) revealed the presence of anechoic pleural fluid (2.5 cm in
106 depth) in the ventral part of the chest, compatible with a mild bilateral pleural effusion. The pleuropulmonary
107 surface was irregular, with multiple hypo/heteroechoic subpleural to irregularly shaped areas consistent with
108 pulmonary consolidations (1-1.5 cm diameter in the left hemithorax; 2.5-3 cm diameter in the right
109 hemithorax). The abdominal ultrasound examination was normal.

110
111 Airway endoscopy revealed bronchopulmonary inflammation due to a dense muco-purulent secretion and
112 mucosal edema from the upper airways to the large bronchi. Cytology of a transendoscopic tracheal wash

113 revealed high-grade neutrophilic inflammation, with a septic nature and a bacterial culture yielded
114 *Streptococcus equi subspecies zooepidemicus* colonies, consistent with a bacterial infection. A
115 bronchoalveolar lavage was not performed due to the severe respiratory distress. A percutaneous lung fine
116 needle aspiration was collected for cytology. The sample was poorly cellular and revealed clusters of
117 epithelial cells with moderate features of nuclear activation, admixed with a fewer number of neutrophils,
118 inducing a suspicion of epithelial neoplasia.

119
120 Based on overall findings, the donkey presentation was consistent with a severe bilateral chronic pneumonic
121 disease with a more likely secondary bacterial infection. Differential diagnoses primarily considered were
122 viral or bacterial pleuropneumonia, severe equine asthma, pulmonary fibrosis and a neoplastic syndrome,
123 that was reinforced by the presence of thrombocytopenia.

124

125 2.2 Treatments, follow-up and case outcome

126 The donkey underwent oxygen therapy and standard medical treatment with broad spectrum antibiotics
127 while pending susceptibility test, anti-inflammatory, bronchodilators and mucolytic drugs, gastroprotectant,
128 and fluid, electrolytic and nutritional support (Table 1).

129

130 **Table 1. Medical treatments administered to 23-year-old donkey presented for respiratory distress upon**
131 **admission.**

Treatments (active ingredient)	Dosage, route, time
Oxygen therapy	3 L per minute, intranasal
Salbutamol	500 mcg nebulised, intranasal, q12h
Acetylcysteine	3 ml of 10% solution nebulized, q12h
Sodium ampicillin	20 mg/kg iv q6h
Gentamicin sulphate	6.6 mg/kg iv q24h
Lactate Ringer	2.0 ml/kg/h iv
Dextrose 50%	0.5ml/kg/min iv
Flunixin meglumine	1.1 mg/kg iv q12h
Sucralfate	20 mg/kg q8h po
Pergolide	0.25 mg/day po

132

133 Despite medical treatments the clinical condition worsened. Severe respiratory distress was characterized
134 with further increased respiratory rate (32-36 breaths/min) and abdominal effort. On arterial blood gas
135 analysis there was marked respiratory acidosis: pH 7.242, PaO₂ 32.8 mmHg, PaCO₂ 75.3 mmHg. In 48 hours
136 of hospitalization the donkey progressed to recumbency and death.

137

2.3 Post-mortem examination and diagnostics

A complete post-mortem examination was performed. Pathological findings included pleural involvement and lungs alterations. There were no pathologically relevant abnormalities affecting the other organs. Pleural effusion and pleuritis were detected. The lung was whitish, collapsed, and firm, with multifocal nodular pinkish areas of 1 to 6 cm (Fig.2.1). On cut section, the lung parenchyma adjacent to the nodules was markedly replaced by abundant fibrosis and the nodular lesions were characterized by residual lung parenchyma spared from fibrosis (Fig.2.2).

Histologically, the pleura was thickened up to 10 times normal with abundant fibrosis and granulation tissue. The lung architecture was markedly replaced by interstitial fibrosis (Fig.2.3). Fibrin, degenerated neutrophils (Fig.2.4), fewer macrophages, and occasional syncytial cells were present in the lumen of residual alveoli and bronchioles. Interspersed with the fibrosis were multifocal residual alveolar structures with type II pneumocyte hyperplasia. Areas of unaffected alveoli were present (Fig.2.5). Overall, the histological features observed were suggestive of a severe chronic fibrosing interstitial pleuropneumonia with type 2 pneumocyte hyperplasia and intralesional syncytial cells, suggestive of a possible herpesviral infection.

On biomolecular investigations, the fibrotic lung tissue tested positive by two pan-herpesvirus polymerase chain reaction (PCR) assays, targeting the partial DNA-directed DNA polymerase (DPOL) and the glycoprotein B (gB) genes, and two sequence of the AsHV-5 and AsHV-2, respectively, were identified from the same tissue sample; real-time PCR assays for EHV-1, -2, -4, and -5 tested negative. The attempts to isolate AsHVs using the cell lines gave negative results.

3. Discussion

The identification of asinine gammaherpesviruses in lung tissue associated with interstitial fibrosing pneumonia was herein reported for the first time in a domestic donkey in northern Italy. The diagnostic-therapeutic course of interstitial fibrosis in a donkey is challenging for equine practitioners. The initial respiratory signs of pulmonary fibrosis may be difficult to identify ante-mortem in Donkeys [5, 18] due to their physiological differences such as a reduced pulmonary resistance [5]. Moreover, the reduced cough reflex, the lack of athletic activity and their stoicism probably allow donkeys to cope with a reduced lung function, making it harder to identify [19].

In the presented case, the clinical picture was consistent with the end-stage of a chronic interstitial lung disease, except inspiratory dyspnea was not as evident as it is described in donkeys with pulmonary fibrosis [5,7]. Inspiratory dyspnea might have been masked by other factors than fibrosis, thus altering the respiratory pattern towards a less specific one.

173

174 The old age may be considered as an additional risk factor in the reported case, as in human patients with
175 pleuroparenchymal fibroelastosis (PPFE), a rare condition of idiopathic pulmonary fibrosis (IPF) [17].

176 Concerning collateral findings, there are no reported cases of donkey with pulmonary fibrosis including the
177 arterial blood gas interpretation which revealed respiratory acidosis along with hypoxemia, that progressed
178 to an uncompensated condition. The hypercapnic respiratory failure is reported in the arterial blood gas of
179 human patients with PPFE [17,20].

180

181 Another interesting finding in this case was the persistent and severe thrombocytopenia.

182 To the author's knowledge, there are no other reports of equids affected by pulmonary fibrosis, AsHVs-2 and
183 -5 infection, and thrombocytopenia without other hematological alterations. Thrombocytopenia is
184 commonly associated with clinical conditions including infectious, immune-mediated or neoplastic disorders
185 [21]. In human medicine, a case of a 66-year-old woman with severe thrombocytopenia was reported in
186 association with an active Herpesvirus simplex virus-2 (HSV-2) infection [20]. The mechanisms underlying the
187 HSV-2 as a primary cause of thrombocytopenia is unknown [21]. Some viruses may affect platelet production
188 or destruction, interacting with receptors on the surface or reducing the expression of thrombopoietin
189 receptors [21]. Thrombocytopenia was considered mainly supportive of a paraneoplastic syndrome in this
190 case. A metastatic disease originating from an ovarian tumour in a mare with EMPF was reported [15], but
191 data available concerning paraneoplastic syndrome are limited in donkeys.

192

193 In light of the clinical presentation, equine asthma syndrome, bronchopneumonia and pulmonary fibrosis
194 were included in the diagnostic differentials. Similarly, in presence of chronic lower respiratory tract disease
195 in horses, EMPF should be included in the differential diagnosis [15]. To diagnose EMPF in horses, imaging
196 and (transtracheal aspirates and bronchial lavage) biomolecular testing for EHV-5 from airways secretions
197 have been used [16]. Thoracic radiography can be helpful to discern asthma and pulmonary nodular fibrosis
198 [15]. However, in our case a diffuse radiopacity related to pleural effusion hampered the X-ray diagnostic
199 value in recognizing a certain lung pattern. Due to the deteriorating clinical condition, it was not possible to
200 repeat the radiographic exam. On ultrasound examination of the chest, multiple distinct surface nodules of
201 variable size, with comet-tail artefacts can be consistent with EMPF. Furthermore, no pleural effusion has
202 been reported in EMPF [4, 6, 15] in contrast with the present donkey, but it cannot be excluded that it may
203 have been related to the bacterial infection. The ultrasonographic appearance of pulmonary fibrosis in
204 donkeys is noticeably different from EMPF in horses. In donkeys, ultrasound can prompt a suspicion of
205 pulmonary fibrosis if pleural thickening areas are observed but similarly it does not allow a confirmatory
206 diagnosis [5], as in our case. Computed tomography (CT) and magnetic resonance imaging (MRI) are reported

207 to be useful to diagnose pulmonary fibrosis in human patients [17], however these imaging modalities were
208 not accessible for the donkey.

209

210 Features of bronchoalveolar lavage fluid (BALF) cytology in AsHV-4 or -5-infected donkeys are comparable to
211 those in horses with EHV-5-related EMPF, albeit higher macrophages percentages have been observed in
212 donkeys [17]. However, BALF cytology may not allow to discriminate EMPF from other chronic lung diseases
213 (i.e. equine asthma) [15]. Unfortunately, in our case a BAL was planned but not performed due to the severe
214 and deteriorating respiratory condition. The tracheal aspirate was not PCR-tested for GHV due to financial
215 constraints in the face of the clinical condition and the limited therapeutic options. The lack of PCR testing
216 for GHV on tracheal aspirate and/or BALF represents a main limitation of the study. Nevertheless, in horses,
217 it has been showed that the absence of EHV-5 identified in BALF or in lung biopsy samples did not rule out a
218 diagnosis of EMPF [15]. The tracheal fluid was only diagnostic for a *Streptococcus equi subsp. zooepidemicus*
219 infection, that was considered most likely to be secondary to the underlying lung pathology. PPID is not
220 uncommon in older donkeys [22] and could represent an additional risk factor for pulmonary infection [22,
221 23].

222

223 Lymphoma was reported in a horse with concomitant EMPF due to EHV-5 with an unknown causal
224 relationship [24]. The finding of an increased number of epithelial cells arranged in clusters and characterized
225 by nuclear activation has led to misinterpretation and an incorrect diagnosis of neoplasia. The clusters of
226 epithelial cells are due to the hyperplasia of the pneumocytes, found with the histological examination. To
227 avoid misdiagnosis, epithelial hyperplasia should be considered as cytological differential diagnosis when
228 examining donkeys with the present clinical presentation. The necropsy examination of the entire body,
229 together with the histological examination of multiple sections from all the lung lobes, allowed the exclusion
230 of neoplasia.

231

232 In horses, donkeys and humans, lung fibrosis has been associated with EHV-5, AsHV-4 and -5, and different
233 GHVs, respectively [15]. Horses are usually infected with EHV early in life and GHV is believed to establish its
234 latency in the lymphatic system [15]. In the present case, the possible contact with EHV infected equine or
235 asymptomatic donkeys could not be excluded due to the adoption from a donkey shelter early in life. Viral
236 factors expressed by viral genes, host factors and co-infections could influence the development of
237 pulmonary fibrosis [15,25]. In horses the EHV-5's causative role in EMPF has been recognized [4, 7, 16]. The
238 clinical significance of AsHV-5 in horses has yet to be defined and other lung diseases such as
239 pyogranulomatous pneumonia have been related to EMPF [18]. The pathogenetic mechanism of pulmonary
240 fibrosis may be due to inflammation, epithelial cell injury, abnormal fibroproliferation and deposition of
241 extracellular matrix components [7,15].

242

243 Corticosteroids have been used to treat EMPF and pulmonary fibrosis in horses but owing to their
244 immunosuppressors effect, they could reactivate latent GHVs and indirectly promote viral replication [6, 15].
245 In this case, corticosteroid treatment was avoided to reduce the risk of an iatrogenic reactivation of latency.
246 Antiviral and antifibrotic are reported to treat pulmonary fibrosis on the early stage of infection in horses
247 with EMPF [6]. The lack of effective therapies is one of the limitations in human medicine, associated with
248 the difficulty of detecting the virus in at-risk patients before the development of fibrosis [2]. Similarly, in the
249 present case, the medical treatments were not effective and the patient was referred when the fibrosis was
250 advanced and it was difficult to identify at an early stage.

251

252 Interestingly, in the present case, ultrasonography did not detect a typical nodular pattern of consolidation.
253 Indeed, the macroscopic and histological pattern of fibrosis was diffuse and interstitial, and the nodular
254 lesions were consistent with spared lung parenchyma, instead of the canonical nodular distribution of the
255 fibrosis, hallmark of the equine multinodular pulmonary fibrosis in horses [7]. In fact, in the donkey,
256 compared to the horse, a nodular pattern of fibrosis is not described, but mostly an interstitial pneumonia
257 localized predominantly in the ventral lobes [3]. Instead, the macroscopic features observed in our case are
258 similar to those reported by Miele and colleagues, who interpreted pulmonary fibrosis in 19 donkeys as
259 analogous to human pleuroparenchymal fibroelastosis [17]. However, while pleuroparenchymal
260 fibroelastosis in humans has no specific etiology and is thought to be idiopathic [26], Miele and colleagues
261 identified AsHV-4 and AsHV-5 both in cases with pulmonary fibrosis and in unaffected controls [17].
262 Conversely, Kleiboeker and colleagues suggested AsHV-4 and AsHV-5 as a cause of interstitial pneumonia in
263 donkeys, being negative for herpesviruses animals affected from pneumonia of different proved etiology [3].
264 To date, the role of herpesviruses in determining the disease remains object of debate. Eosinophilic
265 intranuclear inclusion bodies were not present in the lung tissue of the present case. According to the
266 literature, herpesviral inclusion bodies are usually not detected in the donkey [10,27], but are generally
267 visible in histological sections of horses with multinodular pulmonary fibrosis [7,28].

268

269 In donkeys, AsHV-5 has been associated with fatal respiratory disease and a post-mortem diagnosis of
270 interstitial pneumonia [3]. GHVs (AsHV-2 and AsHV-5) were previously isolated in the Pantesco breed donkey,
271 an Italian breed threatened by extinction, in the Sicily region, Italy [13]. However, GHVs in the donkeys were
272 not considered the sole cause of the respiratory manifestation. The authors supposed that respiratory
273 infection caused reactivation of the herpesvirus [13]. In our case, AsHV-2 and -5 were detected for the first
274 time in a domestic donkey in Emilia Romagna and could be considered in relationship with pulmonary
275 fibrosis, being associated with the canonical histological hallmarks that occur during herpesvirus infection.

276

277 **4.Conclusion**

278 Asinine gammaherpesviruses were detected in association with pulmonary fibrosis for the first time in Emilia
279 Romagna in a domestic donkey and, for the second time, in the asinine population in Italy. The clinical signs
280 and diagnostic findings in the present case add further characterization of the pulmonary fibrosis in this
281 species. The presence of GHVs has been related to pulmonary fibrosis, a chronic and progressive disease, in
282 the present case characterized by acute exacerbation and rapid clinical deterioration. The exact role of GHVs,
283 as a causative or precipitating factors in the pathogenesis of pulmonary fibrosis remains a matter of debate.
284 The present case suggests the importance of considering as a differential and testing donkeys for AsHV-2/5
285 early in the course of lower respiratory tract diseases.

286 **Declaration of interest:** None.

287

288 **References**

- 289 [1] American Thoracic Society. Idiopathic pulmonary fibrosis: diagnosis and treatment. International
290 consensus statement. American Thoracic Society (ATS), and the European Respiratory Society (ERS). *Am J*
291 *Respir Crit Care Med.* 2000 Feb;161(2 Pt 1):646-64. doi: 10.1164/ajrccm.161.2.ats3-00. PMID: 10673212.
- 292 [2] Naik PK, Moore BB. Viral infection and aging as cofactors for the development of pulmonary fibrosis.
293 *Expert Rev Respir Med.* 2010;4(6):759-771.
- 294 [3] Kleiboeker SB, Schommer SK, Johnson PJ, Ehlers B, Turnquist SE, Boucher M, et al. Association of two
295 newly recognized herpesviruses with interstitial pneumonia in donkeys (*Equus asinus*). *J Vet Diagn Invest*
296 2002;14:273e80.
- 297 [4] Back H, Kendall A, Grandón R, Ullman K, Treiberg-Berndtsson L, Ståhl K et al. Equine multinodular
298 pulmonary fibrosis in association with asinine herpesvirus type 5 and equine herpesvirus type 5: a case
299 report. *Acta Vet Scand.* 2012 Sep 25;54(1):57.
- 300 [5] Thiemann AK. Respiratory disease in the donkey. *Equine Vet. Education* 2012;24(9):469-478.
- 301 [6] Marenzoni ML, Passamonti F, Lepri E, Cercone M, Capomaccio S, Cappelli K et al. Quantification of Equid
302 herpesvirus 5 DNA in clinical and necropsy specimens collected from a horse with equine multinodular
303 pulmonary fibrosis. *J Vet Diagn Invest.* 2011 Jul;23(4):802-6.
- 304 [7] Williams KJ, Maes R, Del Piero F, Lim A, Wise A, Bolin DC et al. Equine multinodular pulmonary fibrosis: a
305 newly recognized herpesvirus-associated fibrotic lung disease. *Vet Pathol.* 2007 Nov;44:849-62. doi:
306 10.1354/vp.44-6-849. PMID: 18039898.
- 307 [8] Vannella KM, Luckhardt TR, Wilke CA, van Dyk LF, Toews GB, Moore BB. Latent Herpesvirus Infection
308 Augments Experimental Pulmonary Fibrosis. *Am J Respir Crit Care Med* 2010, 181:465–477.
- 309 [9] Borchers K, Frölich K, Ludwig H. Detection of equine herpesvirus types 2 and 5 (EHV-2 and EHV-5) in
310 Przewalski's wild horses. *Arch Virol.* 1999; 144:771-80.
- 311 [10] Maboni G, Kelly EJ, Clancy CS, De Luca E, Baldwin TJ, Van Wettere AJ et al. Detection of asinine
312 gammaherpesviruses in association with pulmonary fibrosis in free-ranging donkeys. *J Vet Diagn Invest.* 2022
313 Jan;34(1):167-171.doi: 10.1177/10406387211052998. Epub 2021 Oct 23. PMID: 34689632; PMCID:
314 PMC8688973.
- 315 [11] Vengust M, Wen X, Bienzle D. Herpesvirus-associated neurological disease in a donkey. *J Vet Diagn*
316 *Invest.* 2008 Nov;20(6):820-3.
- 317 [12] Rushton JO, Kolodziejek J, Nell B, Nowotny N. Prevalence of asinine herpesvirus type 5 (AsHV-5) infection
318 in clinically normal Lipizzaner horses. *Vet J.* 2014 Apr;200(1):200-3.

319 [13] Mira F, Canuti M, Di Bella S, Puleio R, Lavazza A, Lelli D et al. Detection and Molecular Characterization
320 of Two Gammaherpesviruses from Pantesco Breed Donkeys during an Outbreak of Mild Respiratory Disease.
321 *Viruses*. 2021 Aug 2;13(8):1527.

322 [14] Jerele S, Davis E, Mapes S, Pusterla N, Navas González FJ, Iglesias Pastrana C et al, Survey of Serum
323 Amyloid A and Bacterial and Viral Frequency Using qPCR Levels in Recently Captured Feral Donkeys from
324 Death Valley National Park (California). *Animals (Basel)*. 2020 Jun 23;10(6):1086. doi: 10.3390/ani10061086.

325 [15] Scheurer L, Bachofen C, Herteman N, Hilbe M, Wolfer N, Schoster A. A case series highlighting the role
326 of different gamma-herpesviruses in Equine Multinodular Pulmonary Fibrosis. *Schweiz Arch Tierheilkd*. 2020
327 Apr;162:245-256.

328 [16] Wilkins PA, "Equine multinodular pulmonary fibrosis: New, emerging or simply recently described?."
329 *Equine Veterinary Education* 20.9 (2008): 477-479.

330 [17] Miele A, Dhaliwal K, Du Toit N, Murchison JT, Dhaliwal C, Brooks H et al. Chronic pleuropulmonary fibrosis
331 and elastosis of aged donkeys: similarities to human pleuroparenchymal fibroelastosis. *Chest*. 2014
332 Jun;145:1325-1332.

333 [18] Witte FG, Frank N, Wilkes RP, et al. Association of asinine herpesvirus-5 with pyogranulomatous
334 pneumonia in a mare. *J Vet Intern Med* 2012;26:1064–8.

335 [19] Vitale V, Bonelli F, Briganti A, Sgorbini M. Bronchoalveolar lavage fluid cytological findings in healthy
336 Amiata donkeys. *Open Vet J*. 2021 Jan-Mar;11(1):160-164. doi: 10.4314/ovj.v11i1.23. Epub 2021 Feb 28.
337 PMID: 33898298; PMCID: PMC8057225.

338 [20] Watanabe S, Waseda Y, Takato H, et al. Pleuroparenchymal fibroelastosis: distinct pulmonary
339 physiological features in nine patients. *Respir Investig* 2015;53:144–55.

340 [21] Siddiqui RS, Lakhdar S, Buttar C, Saliya M. Thrombocytopenia Secondary to Herpes Simplex Virus-2
341 Infection Successfully Treated by Acyclovir. *Cureus*. 2020 Dec 28;12:12338.

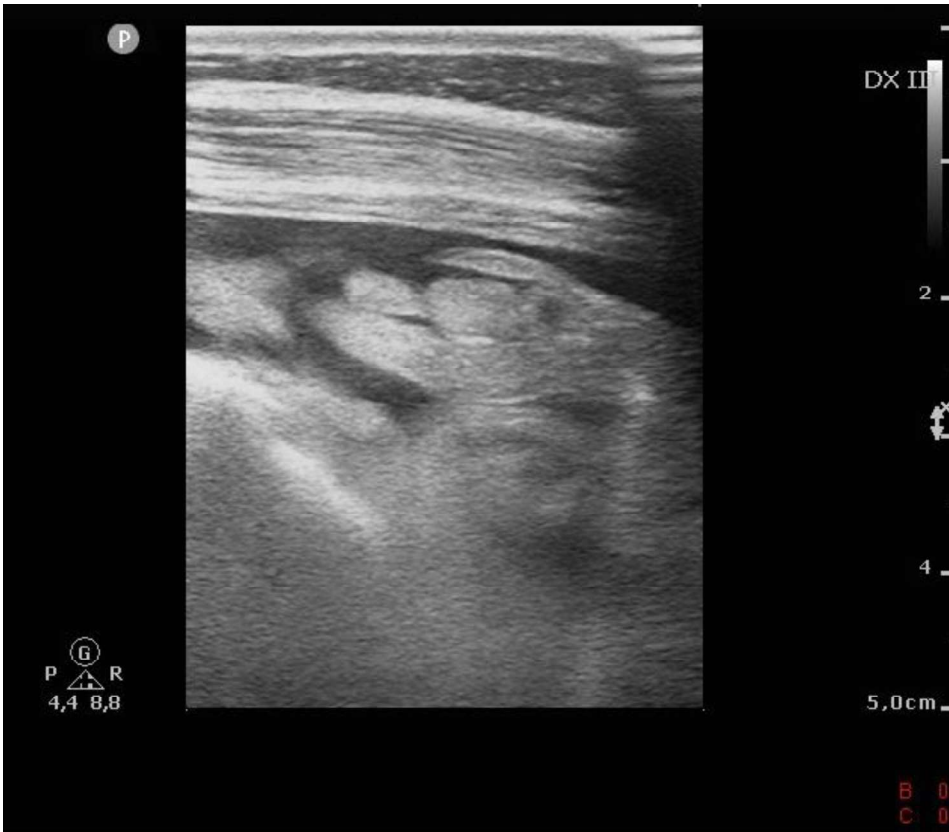
342 [22] Mendoza FJ, Toribio RE, Perez-Ecija A. Donkey Internal Medicine—Part II: Cardiovascular, Respiratory,
343 Neurologic, Urinary, Ophthalmic, Dermatology, and Musculoskeletal Disorders. *J Equine Vet Sci*. 2018;65:86-
344 97.

345 [23] Mejia-Pereira S, Perez-Ecija A, Buchanan BR, Toribio RE, Mendoza FJ. Evaluation of dynamic testing for
346 pituitary pars intermedia dysfunction diagnosis in donkeys. *Equine Vet J*. 2019 Jul;51:481-488.

347 [24] Bawa B, Werf KV, Beard L, Davis E, Andrews G, Almes K, Equine Multinodular Pulmonary Fibrosis and
348 Lymphoma in a Horse Associated with Equine Herpesvirus-5, *Journal of Equine Veterinary Science*, Volume
349 34, Issue 5, 2014, Pages 694-700.

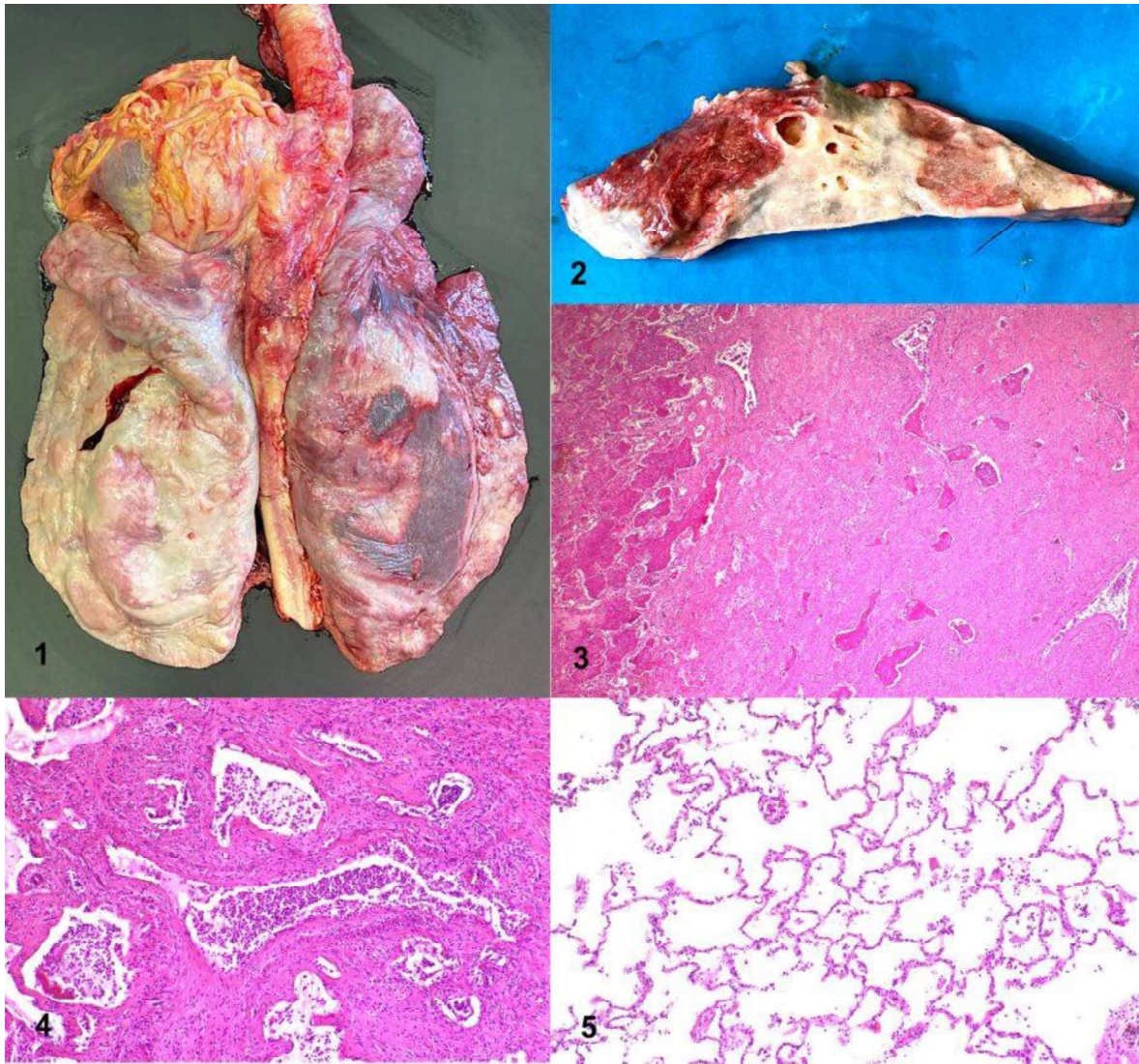
350 [25] Huang WJ, Tang XX. Virus infection induced pulmonary fibrosis. *J Transl Med*. 2021 Dec 7;19(1):496. doi:
351 10.1186/s12967-021-03159-9

- 352 [26] Chua F, Desai SR, Nicholson AG, Devaraj A, Renzoni E, Rice A, Wells AU. Pleuroparenchymal
353 Fibroelastosis. A Review of Clinical, Radiological, and Pathological Characteristics. *Ann Am Thorac Soc*. 2019
354 Nov;16(11):1351-1359. doi: 10.1513/AnnalsATS.201902-181CME. PMID: 31425665; PMCID: PMC6945468.
- 355 [27] Caswell KJ, W. J. (2016). Respiratory system. In K. a. Jubb, *Pathology of domestic animals* (p. 568). St.
356 Louis, Missouri: M. Grant Maxie.
- 357 [28] Schwartz G, Edery N, Moss L, Hadad R, Steinman A, Karniely S. Equid Herpesvirus 8 Isolated From an Adult
358 Donkey in Israel. *J Equine Vet Sci*. 2020 Nov;94:103247.



359

360 **Figure 1.** Ultrasonographic image of the right thorax, within the third intercostal space, at the first day of
361 hospitalization showing the presence of anechoic pleural fluid and irregular and heterogeneous echogenicity
362 pleuropulmonary surface.



363

364 **Figure 2. Post mortem examination of the lungs from a 23-year-old donkey presented for respiratory**
 365 **distress**

366 **2.1**The lung is whitish and collapsed, with multifocal pinkish nodules.

367 **2.2** Cut section of the lung: the whitish area is depressed and firm on cut section, suggestive of fibrosis; the
 368 reddish area corresponds to the section of a nodule, and it is composed of spared lung parenchyma not
 369 affected by fibrosis.

370 **2.3** The lung architecture is markedly replaced by interstitial fibrosis. The residual alveoli and bronchioles are
 371 filled with abundant fibrin and inflammatory cells, 40x, Haematoxylin and Eosin (H-E).

372 **2.4** Higher magnification of residual airways filled with degenerated neutrophils, 100x, H-E.

373 **2.5** Alveoli spared from fibrosis, 100x, H-E.

374 **Supplementary Materials**



375
376 **Figure 3** The 23-years-old donkey on admission.