

CASE REPORT

Calcium in the (Big) Pipes: Intra-TEVAR Calcifications!

Salomé Kuntz ^{a,b,*}, Fabien Thaveau ^{a,b}, Michaël Ohana ^c, Gianandrea Pasquinelli ^{d,e}, Nabil Chakfé ^{a,b}, Anne Lejay ^{a,b}

^a Department of Vascular Surgery and Kidney Transplantation, University of Strasbourg, Strasbourg, France

^b GEPROMED, Strasbourg, France

^c Department of Radiology, University of Strasbourg, Strasbourg, France

^d Department of Medical and Surgical Sciences - DIMEC, University of Bologna, Bologna, Italy

^e Pathology Unit, IRCCS AOUBO, Bologna, Italy

Introduction: Calcification of a vascular endograft and adjacent tissues (adventitia, media, and neointima) can result in graft failure. This report shows a rare case of intraluminal calcifications in the distal end of a thoracic endovascular aortic repair (TEVAR) endograft implanted 11 years previously for grade IV blunt traumatic aortic injury (BTAI) in a young patient.

Report: A 24 year old man required TEVAR for a BTAI caused by a motorcycle accident. The procedure consisted of TEVAR and an emergency left carotid subclavian venous bypass. Eleven years after the procedure, he had severe hypertension. Intra-TEVAR calcifications appeared, gradually increasing on computed tomography angiography (CTA). Calcifications in the distal luminal end of the TEVAR were responsible for a 60% stenosis on CTA. An open approach was indicated after multidisciplinary discussion, based on the gradient value. The patient underwent explantation, with total replacement of the aortic arch and descending thoracic aorta with re-implantation of the supra-aortic vessels, under extracorporeal circulation. Macroscopic analysis showed no device degeneration but revealed a solid mass at the distal end of the TEVAR. Both microcomputed tomography and histopathology confirmed the calcific nature of the lesions.

Conclusion: This case highlights a rare long term graft failure due to calcified neo-atherosclerosis in a TEVAR.

© 2023 The Authors. Published by Elsevier Ltd on behalf of European Society for Vascular Surgery. This is an open access article under the CC BY-NC-ND license (<http://creativecommons.org/licenses/by-nc-nd/4.0/>).

Article history: Received 17 May 2023, Revised 30 August 2023, Accepted 15 September 2023,

Keywords: Neo-atherosclerosis, TEVAR, surgical procedures

INTRODUCTION

Calcification of a vascular endograft and adjacent tissues (adventitia, media, and neointima) can result in graft failure, but is a much less reported complication than the usual complications such as thrombosis or neointimal hyperplasia.¹ Graft failure remains a major challenge that compromises the long term performance of vascular grafts due to mechanical dysfunction, arterial occlusion, or distal embolisation of calcific deposits.

This report shows a rare case of intraluminal calcifications in the distal end of a thoracic endovascular aortic repair (TEVAR) implanted 11 years ago for a grade IV blunt traumatic aortic injury (BTAI) in a young patient. He underwent TEVAR explantation after the development of severe

hypertension due to neo-atherosclerosis within the distal end of the endograft.

Case report

A 24 year old man required TEVAR for a BTAI caused by a motorcycle accident. The procedure consisted of a 26 × 26 × 100 GORE TAG endograft implantation (W. L. GORE & Associates Inc., Flagstaff, AZ, USA) and an emergency left carotid subclavian venous bypass because of re-injection of the leak from the subclavian artery. The proximal left subclavian artery was ligated and the great saphenous vein was used. During the follow up, aneurysmal degeneration of the venous bypass was noted eight years after the procedure and the patient underwent venous graft excision and redo prosthetic Dacron bypass of the carotid subclavian bypass. The first signs of intra-TEVAR calcifications appeared at the same time, gradually increasing on computed tomography angiography (CTA) (Fig. 1). Eleven years later, he developed severe hypertension (four drug regimen), had no signs of claudication, and had normal kidney function. CTA showed calcifications in the distal luminal end of the TEVAR, responsible for a 60% stenosis of the thoracic descending aorta. The stenosis was confirmed by dynamic magnetic resonance imaging, 70% estimated stenosis, 276 cm/s peak systolic velocity (PSV) and

* Corresponding author. Department of Vascular Surgery and Kidney Transplantation, Strasbourg University Hospital, Nouvel Hôpital Civil, 1 Place de l'hôpital, 67091, Strasbourg, Cedex, France.

E-mail address: salome.kuntz@gmail.com (Salomé Kuntz).

Twitter: [@gepromed](https://twitter.com/gepromed)

2666-688X/© 2023 The Authors. Published by Elsevier Ltd on behalf of European Society for Vascular Surgery. This is an open access article under the CC BY-NC-ND license (<http://creativecommons.org/licenses/by-nc-nd/4.0/>).

<https://doi.org/10.1016/j.ejvsf.2023.09.006>

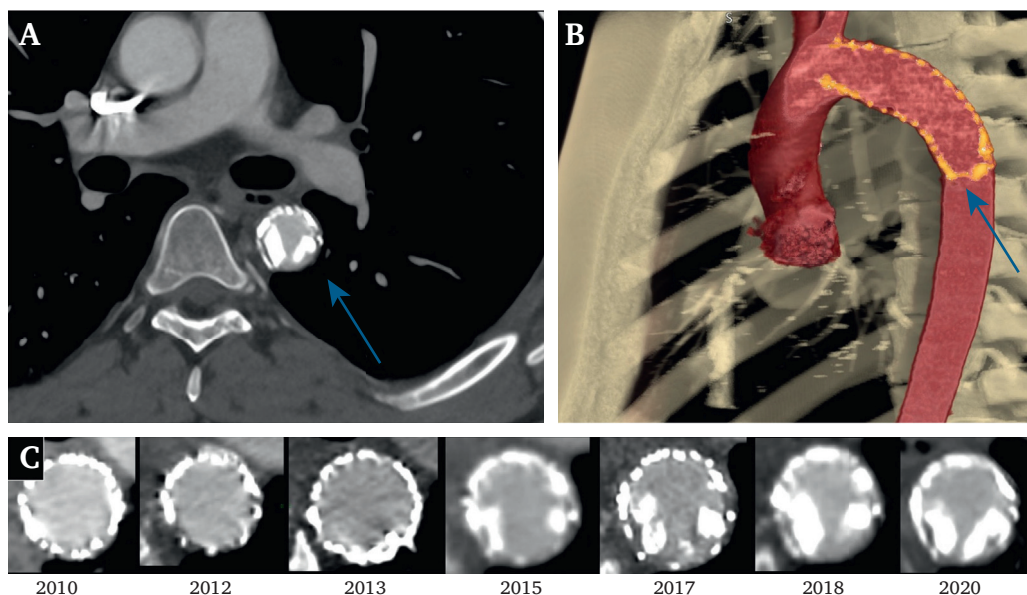


Figure 1. Follow up computed tomography angiography of the 35 year old patient. **(A)** A transverse section of the thoracic endovascular aortic repair (TEVAR) at the site of the in stent stenosis, highlighted by the blue arrow. **(B)** The frontal plane of the 3D reconstruction at the site of the device and the in stent calcifications are highlighted by the blue arrow. **(C)** The transverse sections of the distal end of the TEVAR over the years, with the increasing burden of calcification.

30 mmHg gradient, and on transoesophageal ultrasonography, 50% estimated stenosis, 300 cm/s PSV, and 30 mmHg pressure gradient (Supplementary Figure S1). An open approach was preferred after multidisciplinary discussion. The patient underwent sternotomy for TEVAR explantation, with total replacement of the aortic arch and descending thoracic aorta with re-implantation of the supra-aortic vessels, under extracorporeal circulation, using a 24 mm Dacron graft. He was discharged seven days after the surgical procedure, no longer needing hypotensive drugs. The clinical follow up at two years was uneventful, completed by duplex ultrasound every six months. He presented with high blood pressure, which was totally controlled with two hypotensive drugs. The device was sent to GEPROMED for explant analysis. The macroscopic analysis showed no device degeneration but revealed a solid mass at the distal end of the TEVAR (Fig. 2). Both microcomputed tomography and histopathology confirmed the calcific nature of the lesions (Fig. 3).

DISCUSSION

Better outcome of TEVAR compared with open repair has changed the therapeutic paradigm for thoracic aortic lesions, especially for BTAI, although the long term durability of TEVAR remains a concern.² Long term complications include TEVAR infection, endoleak, aortobronchial or aorto-oesophageal fistula, retrograde dissection, and also endograft failure (thrombosis, stenosis, or misplacement), mandating lifelong surveillance. TEVAR for BTAI might also lead to hypertension and cardiac modifications and aortic remodelling.^{3,4} This case belongs to the general topic of graft failure due to neo-atherosclerosis,⁵ determined either by the canonical atherogenetic mechanism that goes

through various stages of atheroma formation or as hypothesised in this case by a non-canonical way that goes through thrombus formation and its remodelling.

Some very rare cases of intraluminal thrombus within a TEVAR for BTAI have been described.⁶ Trauma patients develop a hypercoagulable state. Therefore, one of the hypotheses concerning the mechanism of calcifications inside a TEVAR is that the patient developed an asymptomatic thrombus that calcified over the years, inducing an increasing stenosis. Calcification can be superimposed on thrombus remodelling and the proposed determinant is intima erosions; other keys may be the endothelial mesenchymal transition, the recruitment of mesenchymal cells from the arterial adventitia, and the involvement of circulating osteogenic progenitors.⁷ Retrospectively, the early post-operative CTA 48 hours after the first surgery might have shown some thrombus, although the blooming artefact made this difficult to prove. Also, the fact that the intra-TEVAR calcifications might increase the arterial parietal rigidity, changing the aortic flow and accelerating the neo-atherosclerosis process leading to the device failure cannot be excluded either.

Another would be TEVAR oversizing, meaning that the geometry of the distal end of the endograft seemed to be squashed, which may have provoked persistent turbulence leading to thrombus formation and mineralisation. Using TEVAR for BTAI means that the choice of diameter of the TEVAR is the one that best fits the proximal part in an urgent setting, usually with important oversizing.⁸ Most BTAIs occur in young patients, who are more likely to have acute curvature of the aortic arch.⁹ A difference between the TEVAR and aortic diameter combined with the tight aortic curvature are the triggers of

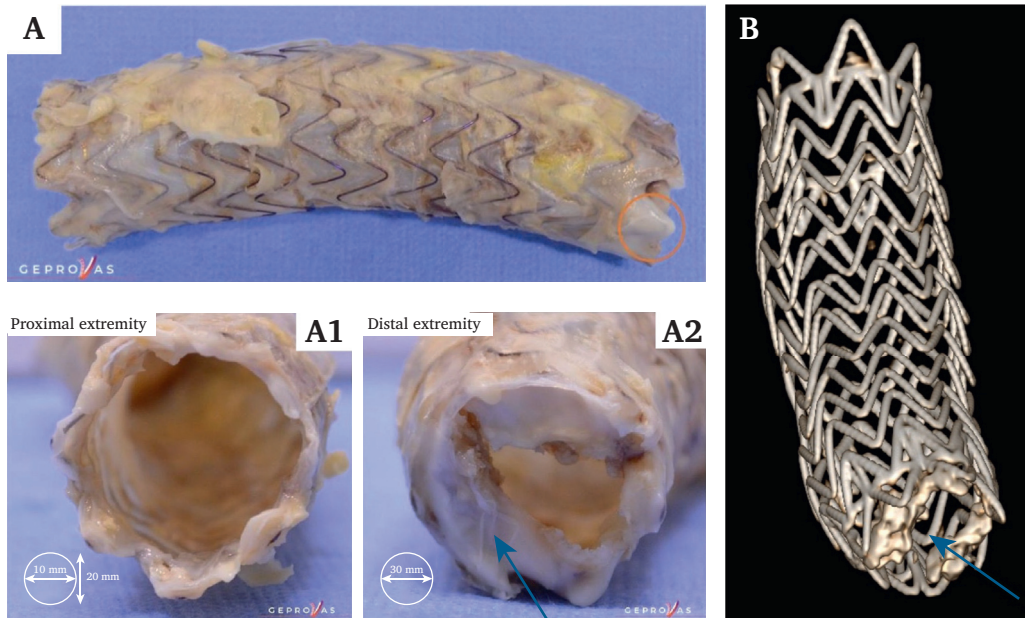


Figure 2. Explant analysis. **(A)** Macroscopic picture of the explanted device. **(A1)** The proximal extremity of the endograft. **(A2)** The distal end with a solid mass attached to the thoracic endovascular aortic repair (TEVAR), highlighted by a blue arrow. **(B)** 3D microcomputed tomography reconstruction of the explant. The intra-TEVAR calcifications are shown by the blue arrow.

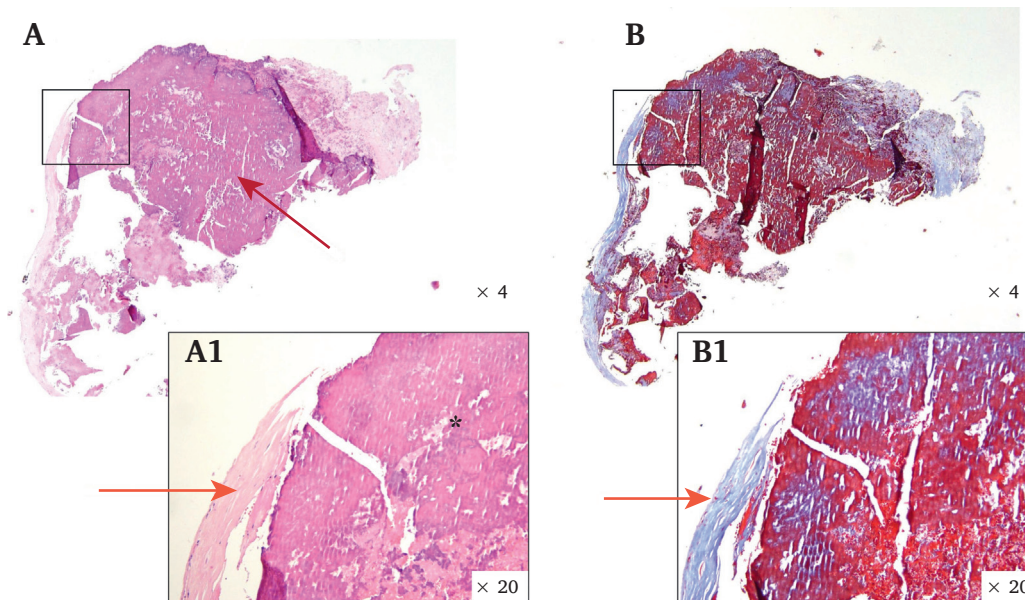


Figure 3. Histopathological analysis. **(A)** A decalcified fragment by ethylenediamine tetraacetic acid (EDTA) haematoxylin and eosin (HE) staining, $\times 4$. The fuchsia pink central nodular zone corresponds to the initially calcified (stony) zone whose calcium ions have been captured and resorbed by EDTA as shown with a red arrow. **(A1)** The decalcified fragment by EDTA and HE staining, $\times 20$. On the right, the decalcified area is shown with a black asterisk. On the left, the fibrous capsule made from collagen and a few mesenchymal cells whose small blue comma shaped nuclei can be recognised are shown with an orange arrow. **(B)** The same fragment with Masson trichrome staining. It shows that the thin shell surrounding the calcified focus corresponds to fibrocollagen tissue. The close up **B1** $\times 20$ shows that the outer capsule which is strongly coloured in blue corresponds to fibrocollagen tissue.

complications such as malapposition and collapse, but also aortic remodelling.¹⁰ With respect to pre-operative CTA measurements, stent grafts should be oversized

by about 10%.⁹ A 26 mm graft, corresponding to a 18% oversizing at both ends and 10% at the mid part, was chosen. This oversizing might explain the

neo-atherosclerosis creating a turbulent flow point, leading to thrombus formation and neo-atherosclerosis.

Both hypotheses, post-traumatic hypercoagulable state but more probably oversizing, might have led to the fact that calcifications appeared through thrombus formation. To the best of the authors' knowledge, this is the first case reported of calcifications inside a TEVAR that led to explantation. The case highlights a rare long term graft failure due to neo-atherosclerosis in a TEVAR.

FUNDING

None.

CONFLICT OF INTEREST

None.

ACKNOWLEDGEMENTS

We would like to thank our collaborators: Nicole Neumann, GEPROMED, Strasbourg, France; Marie-Pierre Chenard, Department of Pathology, University of Strasbourg, France; David Smith Kamerow.

APPENDIX A. SUPPLEMENTARY DATA

Supplementary data related to this article can be found at <https://doi.org/10.1016/j.ejvsf.2023.09.006>.

REFERENCES

- 1 Brown TK, Alharbi S, Jiang HB. Prosthetic vascular grafts engineered to combat calcification: progress and future directions. *Biotechnol Bioeng* 2023;**120**:953–69.
- 2 Farber MA, Giglia JS, Starnes BW, Stevens SL, Holleman J, Chaer R, et al. Evaluation of the redesigned conformable GORE TAG thoracic endoprosthesis for traumatic aortic transection. *J Vasc Surg* 2013;**58**:651–8.
- 3 Tigkiropoulos K, Sigala F, Tsilimigras DI, Moris D, Filis K, Melas N, et al. Endovascular repair of blunt thoracic aortic trauma: is postimplant hypertension an incidental finding? *Ann Vasc Surg* 2018;**50**:160–6.
- 4 Tzilalis VD, Kamvysis D, Panagou P, Kaskarelis I, Lazarides MK, Perdikides T, et al. Increased pulse wave velocity and arterial hypertension in young patients with thoracic aortic endografts. *Ann Vasc Surg* 2012;**26**:462–7.
- 5 Otsuka F, Byrne RA, Yahagi K, Mori H, Ladich E, Fowler DR, et al. Neoatherosclerosis: overview of histopathologic findings and implications for intravascular imaging assessment. *Eur Heart J* 2015;**36**:2147–59.
- 6 Beijer E, Scholtes VPW, Truijers M, Nederhoed JH, Yeung KK, Blankensteijn JD. Intragraft obstructive thrombus two years after endovascular repair of traumatic aortic injury: a case report and review of the literature. *EJVES Vasc Forum* 2021;**53**:36–41.
- 7 Almekhlafi MA, Hu WY, Hill MD, Auer RN. Calcification and endothelialization of thrombi in acute stroke: pathology of thrombi in stroke. *Ann Neurol* 2008;**64**:344–7.
- 8 Gennai S, Leone N, Andreoli F, Munari E, Berchiolli R, Arcuri L, et al. Influence of thoracic endovascular repair on aortic morphology in patients treated for blunt traumatic aortic injuries: long term outcomes in a multicentre study. *Eur J Vasc Endovasc Surg* 2020;**59**:428–36.
- 9 Riambau V, Böckler D, Brunkwall J, Cao P, Chiesa R, Coppi G, et al. Editor's Choice — management of descending thoracic aorta diseases: clinical practice guidelines of the European Society for Vascular Surgery (ESVS). *Eur J Vasc Endovasc Surg* 2017;**53**:4–52.
- 10 García Reyes ME, Gonçalves Martins G, Fernández Valenzuela V, Domínguez González JM, Maeso Lebrun J, Bellmunt Montoya S. Long-term outcomes of thoracic endovascular aortic repair focused on bird beak and oversizing in blunt traumatic thoracic aortic injury. *Ann Vasc Surg* 2018;**50**:140–7.