

# Intravascular Ultrasound in the Detection of Bridging Stent Graft Instability During Fenestrated and Branched Endovascular Aneurysm Repair Procedures: A Multicentre Study on 274 Target Vessels

Giuseppe Ascitutto <sup>a,\*</sup>, Abdulhakim Ibrahim <sup>b</sup>, Nicola Leone <sup>c</sup>, Stefano Gennai <sup>c</sup>, Michele Piazza <sup>d</sup>, Michele Antonello <sup>d</sup>, Anders Wanhainen <sup>a,e</sup>, Kevin Mani <sup>a</sup>, David Lindström <sup>a</sup>, Lisa Struk <sup>b</sup>, Alexander Oberhuber <sup>b</sup>

<sup>a</sup> Division of Vascular Surgery, Department of Surgical Sciences, Uppsala University, Uppsala, Sweden

<sup>b</sup> Department of Vascular and Endovascular Surgery, University Hospital Münster, Münster, Germany

<sup>c</sup> Department of Vascular Surgery, Ospedale Civile di Baggiovara, Azienda Ospedaliero-Universitaria di Modena, Università di Modena e Reggio Emilia, Modena, Italy

<sup>d</sup> Vascular and Endovascular Surgery Division, Department of Cardiac, Thoracic, Vascular Sciences and Public Health, Padua University, Padua, Italy

<sup>e</sup> Department of Surgical and Peri-operative Sciences, Surgery, Umeå University, Umeå, Sweden

## WHAT THIS PAPER ADDS

Intravascular ultrasound (IVUS) is used increasingly in endovascular procedures. Its potential in fenestrated or branched EVAR (F/B-EVAR) as an adjunctive diagnostic tool has not been fully investigated. The current study supports the safety of IVUS during F/B-EVAR and its value in supporting the decision of immediate re-intervention for unstable target visceral vessels. The authors support the need for further investigations in order to prove the role of IVUS in improving the long term results of F/B-EVAR.

**Objective:** The use of intravascular ultrasound (IVUS) reduces contrast medium use and radiation exposure during conventional endovascular aneurysm repair (EVAR). The aim of this study was to evaluate the safety and efficacy of IVUS in detecting bridging stent graft (bSG) instability during fenestrated and branched EVAR (F/B-EVAR).

**Methods:** This was a prospective observational multicentre study. The following outcomes were evaluated: (1) technical success of the IVUS in each bSG, (2) IVUS findings compared with intra-operative angiography, (3) incidence of post-operative computed tomography angiography (CTA) findings not detected with IVUS, and (4) absence of IVUS related adverse events. Target visceral vessel (TVV) instability was defined as any branch or fenestration issues requiring an additional manoeuvre or re-intervention. Any IVUS assessment that detected stenosis, kinking, or any geometric TVV issue was considered to be branch instability. All procedures were performed in *ad hoc* hybrid rooms.

**Results:** Eighty patients (69% males; median age 72 years; interquartile range 59, 77 years) from four aortic centres treated with F/B-EVAR between January 2019 and September 2021 were included: 70 BEVAR (21 off the shelf; 49 custom made), eight FEVAR (custom made), and two F/B-EVAR (custom made), for a total of 300 potential TVVs. Two TVVs (0.7%) were left unstented and excluded from the analysis. The TVVs could not be accessed with the IVUS catheter in seven cases (2.3%). Furthermore, 17 (5.7%) TVVs could not be examined due to a malfunction of the IVUS catheter. The technical success of the IVUS assessment was 91.9% (274/298), with no IVUS related adverse events. Seven TVVs (2.5%) showed signs of bSG instability by means of IVUS, leading to immediate revisions. The first post-operative CTA at least 30 days after the index procedure was available in 268 of the 274 TVVs originally assessed by IVUS. In seven of the 268 TVVs (2.6%) a re-intervention became necessary due to bSG instability.

**Conclusion:** This study suggests that IVUS is a safe and potentially valuable adjunctive imaging technology for intra-operative detection of TVV instability. Further long term investigations on larger cohorts are required to validate these promising results and to compare IVUS with alternative technologies in terms of efficiency, radiation exposure, procedure time, and costs.

**Keywords:** Aneurysm, Endovascular aneurysm repair, Endovascular treatment/therapy, Intravascular ultrasound, Thoracoabdominal aneurysm, Thoracoabdominal aortic aneurysm

Article history: Received 10 December 2022, Accepted 7 September 2023, Available online 12 September 2023

© 2023 The Author(s). Published by Elsevier B.V. on behalf of European Society for Vascular Surgery. This is an open access article under the CC BY license (<http://creativecommons.org/licenses/by/4.0/>).

\* Corresponding author. Division of Vascular Surgery, Department of Surgical Sciences, Uppsala University, SE-751 85 Uppsala, Sweden.

E-mail address: [giuseppe.asciutto@surgsci.uu.se](mailto:giuseppe.asciutto@surgsci.uu.se) (Giuseppe Ascitutto).

1078-5884/© 2023 The Author(s). Published by Elsevier B.V. on behalf of European Society for Vascular Surgery. This is an open access article under the CC BY license (<http://creativecommons.org/licenses/by/4.0/>).

<https://doi.org/10.1016/j.ejvs.2023.09.009>

## INTRODUCTION

Fenestrated and branched endovascular aortic repair (F/B-EVAR) of complex aneurysms has shown promising results in terms of reduced mortality and morbidity rates compared with open surgery.<sup>1</sup> This has led to a global increase in the use of this technique during the past two decades.<sup>2–4</sup>

The complexity of these procedures leads to a risk of adverse events related to instability of the bridging stent grafts (bSGs) in the target visceral vessels (TVVs). TVV instability can result in the development of endoleaks, as well as organ loss and potential death due to end organ ischaemia. Timely detection and treatment of TVV instability is desirable to avoid complications.

Single plane angiography provides a routine TVV examination, allowing immediate treatment of undesirable findings. The simple and swift method explains the fact that it is still considered the gold standard for intra-operative assessment of TVV instability. This even when compared with intra-operative cone beam computed tomography (CBCT).<sup>3–6</sup>

Intravascular ultrasound (IVUS) during endovascular procedures has gained widespread use in the last decades. Its potential to reduce contrast agents and radiation exposure alongside flow evaluation of vascular targets are important features.<sup>7,8</sup>

With regard to endovascular aortic repair (EVAR), several recent reports have shown that IVUS is safe and reliable.<sup>9</sup> The use of IVUS technology during BEVAR procedures in order to prove its applicability in detecting target vessel instability has been described previously.<sup>10</sup> Furthermore, preliminary data on its use as an adjunctive imaging technique during F/B-EVAR have been reported.<sup>11</sup>

The aim of this prospective multicentre study was to evaluate the safety and efficacy of IVUS in detecting TVV issues during F/B-EVAR in a larger patient cohort. Furthermore, the aim was to analyse the incidence of bSG instability on post-operative computed tomography angiography (CTA) not detected with intra-operative IVUS.

## MATERIALS AND METHODS

### Study design

A multicentre study was conducted on patients treated with F/B-EVAR for complex aortic aneurysm (thoraco-abdominal, pararenal, or juxtarenal) at four tertiary university hospitals. This was a retrospective analysis of prospectively collected data on the use of IVUS as completion imaging in elective or emergency F/B-EVAR. The study was performed in accordance with the ethical principles as defined by the Declaration of Helsinki after approval from all local ethics committees. The study protocol was registered at [www.clinicaltrials.gov](http://www.clinicaltrials.gov) (NCT04663074).

Patients presenting with target vessel instability after F/B-EVAR, i.e., patients with planned secondary branch interventions, were not considered for inclusion. There were no IVUS specific exclusion criteria.

### Examination technique

All procedures included in the study were performed in a hybrid room under general anaesthesia and fusion imaging.

TVVs were treated via a transbrachial or transfemoral approach for BEVAR with implantation of the bSG over a 180 degree bendable steerable sheath. FEVARs were conducted via a transfemoral approach, with implantation of the bSG over a 90 degree bendable steerable sheath. The IVUS examination technique has been described previously.<sup>10,11</sup> Briefly, after deployment of the bSG through the axillary or femoral artery, and after angiographic assessment of its patency, a Vision PV 0.018 or 0.035 inch IVUS catheter (Volcano, Philips, Amsterdam, The Netherlands) was advanced through the bSG under fluoroscopy. All bSGs were investigated sequentially with the IVUS catheter at the end of each implantation. After activation of the B mode modality, the IVUS catheter was pulled gently back through the bSG up to the aortic main body endograft. The longitudinal and axial sequences were stored for post-procedural processing. Both projections were two dimensional images and were taken in B mode.

### Study endpoints and definitions

The current study assessed IVUS ability to detect immediate TVV instability after bSG deployment. The primary endpoint of this study was the comparison between IVUS findings and intra-operative single plane angiography. Secondary endpoints were the technical success of the IVUS assessment (defined as and the incidence of post-operative CTA instability not detected with intra-operative IVUS). The safety endpoint was defined as the absence of IVUS related adverse events.

TVV instability was defined as any branch or fenestration issues requiring additional manoeuvre or re-intervention.<sup>12</sup> Any IVUS assessment that detected stenosis, kinking or any geometric TVV issue was considered to be branch instability.

TVV stenosis was defined as a lumen diameter reduction of more than 50% compared with the expected diameter of the deployed bSG. TVV patency was defined as the absence of relevant TVV stenosis or occlusion.<sup>13</sup> IVUS related adverse events included any complications that occurred after catheter insertion into the TVVs. Data were reported according to the current reporting standard.<sup>14</sup>

The outcome measures were assessed intra-operatively using IVUS followed by single plane angiography. Intra-operative findings were compared with those of the first CTA, at the earliest 30 days post-operatively. Bridging stent instability detected at the first CTA was assumed to have occurred intra-operatively and missed at the final imaging. Acute kidney injury (AKI) was defined as by the Kidney Disease Improving Global Outcomes guidelines.<sup>15</sup>

### Statistical analysis

All continuous variables analysed were non-normally distributed and therefore expressed as median and interquartile range (IQR), whereas dichotomous variables were presented as crude numbers and percentages. All statistical analyses were performed using SPSS Statistics for Windows version 28 (IBM Corp., Armonk, NY, USA).

**Table 1. Demographics, indications and target vessel data of the entire population of 80 patients investigated for bridging stent instability with intravascular ultrasound (IVUS)**

	Patients (n = 80)	
	Frequency or median	Stenosis > 50%
Age – years	72 (59, 77)	
Male	55 (69)	
Chronic kidney disease*	27 (34)	
Current smoker	25 (31)	
<b>Treatment indication</b>		
TAAA	65 (81)	
Aortic dissection	2 (3)	
Dissection + aneurysm	13 (16)	
Aneurysm diameter – mm	61 (58, 70)	
<b>Target visceral vessel (n = 300)</b>		
Coeliac trunk	69 (23)	17 (25)
Superior mesenteric artery	80 (27)	5 (6)
Right renal artery	74 (25)	8 (11)
Left renal artery	72 (24)	9 (12)
Accessory renal artery	5 (1)	0

Data are presented as median (interquartile range) or n (%).

Continuous variables are expressed as median and interquartile range (IQR), and dichotomous variables are presented as crude numbers (%). TAAA = thoraco-abdominal aortic aneurysm.

\* Defined as an estimated glomerular filtration rate less than 60 mL/min/1.73 m<sup>2</sup>.

## RESULTS

Eighty patients (69% males; median age 72 years; IQR 59, 77 years) treated for a complex aortic aneurysm (thoraco-abdominal, pararenal, or juxtarenal) between January 2019 and September 2021 (Table 1) were included. The patients underwent BEVAR in 70 cases (21 off the shelf; seven William Cook Europe, ApS, Bjaeverskov, Denmark, and 14 Jotec GmbH, Hechingen, Germany); 49 custom made (three William Cook and 46 Jotec GmbH). Eight patients underwent FEVAR (custom made William Cook) and two combined F/B-EVAR (custom made William Cook), accounting for a total of 300 potential TVVs. The median procedure time was 310 minutes (239 – 396), the median fluoroscopy time 79 minutes (64 – 110) while the dose area product was 316 213.50 mGy.cm<sup>2</sup> (134 340.75 – 570 525.75). No peri-operative (i.e., intra-hospital) deaths were reported. AKI occurred in 15 cases (18.7%), requiring temporary or permanent dialysis in eight cases (10%). Six of these patients had a history of chronic renal impairment (i.e., estimated glomerular filtration rate less than 60). One of 15 cases of AKI resulted from occlusion of a renal artery. Five patients (6.2%) died during the first 30 post-operative days.

Seventeen TVVs (5.7%; 10 patients) could not be examined due to a malfunction of the IVUS catheter. In particular, the image radius was reduced to different extents, probably due to damage of the piezoelectric crystals in the transducer.

Furthermore, the TVVs could not be accessed with the IVUS catheter in seven (2.3%) cases (five because of lost wire and two due to failure to advance the IVUS catheter over the wire). In all these cases, a 0.018 inch catheter was used to approach the TVVs. In one case the target vessel

could not be connected to the aortic stent graft while in one case a branch was left unconnected to reduce the risk of spinal cord ischaemia. These two cases (0.7%) were not considered technical failures and were excluded from the analysis, accounting for a total of 274 potential target vessels. The technical success of the IVUS assessment was 91.9% (274/298), with no IVUS related adverse events. Overall, 74 TVVs (27%) were examined with a 0.035 inch catheter, while 200 (73%) TVVs were examined with a 0.018 inch catheter.

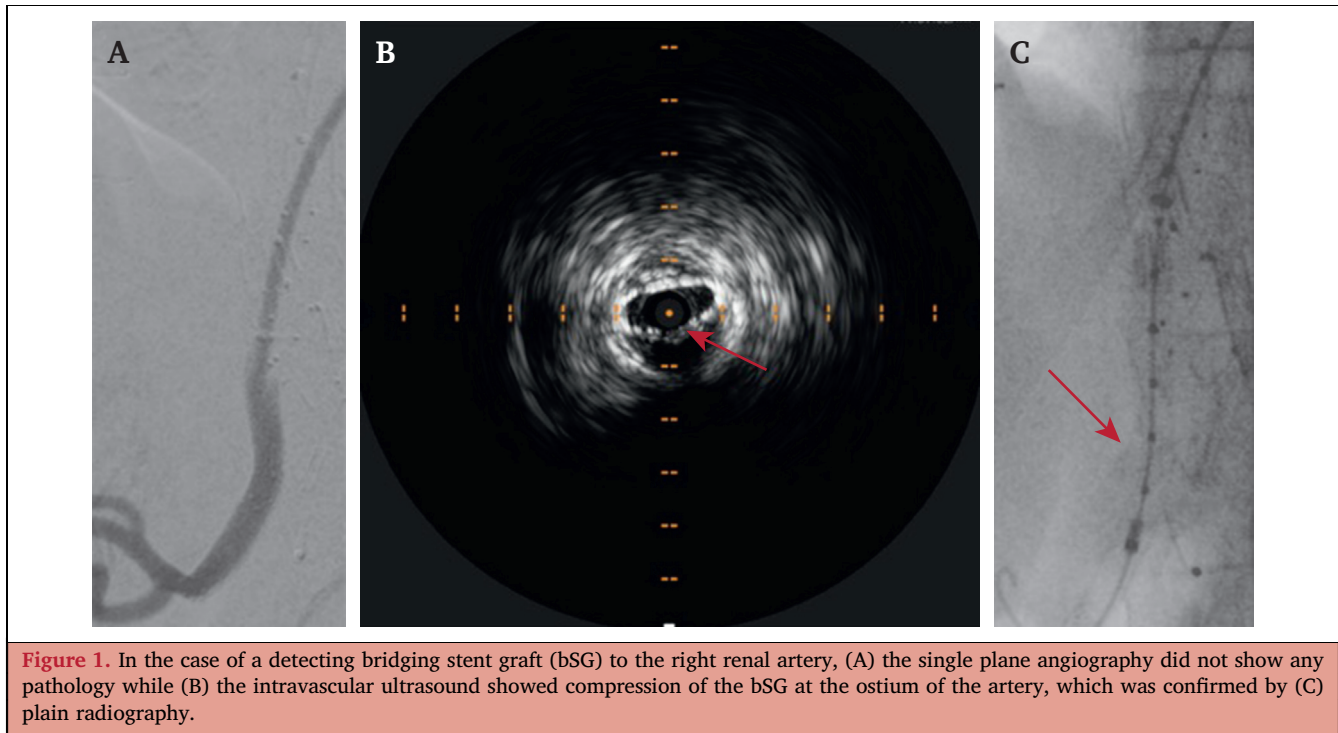
A total of 406 bSGs were assessed with IVUS, including 103 Advanta V12 (Atrium Medical Corp, Hudson, NH, USA), 38 BeGraft (Bentley InnoMed GmbH, Hechingen, Germany), 46 Covera (Bard, Tempe, AZ, USA), 36 E-ventus (Jotec GmbH), 180 VBX (W. L. Gore, Newark, DE, USA), and three Viabahn (W. L. Gore). A total of seven TVVs (2.5%) showed signs of instability by means of IVUS (all more than 50% stenosis of the bSG). In all cases, the IVUS findings were not detected by the final plain angiogram (Fig. 1 and Supplementary Video S1). The IVUS assessment led to an immediate revision in all seven cases (one coeliac trunk, three superior mesenteric arteries, three renal arteries). All unstable TVVs were detected in patients undergoing primary BEVAR, with implantation of the bSG over a 180 degree bendable steerable sheath. There were no additional complications in the TVV segments examined by IVUS which were found exclusively on the final angiography. The details of the IVUS findings and subsequent treatment of the seven TVVs are summarised in Table 2 and below (intra-operative picture as supplementary material).

In one case, a stenosis of a balloon expandable (b-ex) stent graft for the superior mesenteric artery was seen caused by extrinsic compression between the endograft main body and the aortic wall. The stenosis was treated with a b-ex stent. In another case, the IVUS showed a stenosis of a b-ex stent graft at the ostium of the superior mesenteric artery. The stenosis was treated with a self expandable (s-ex) stent. In one case, a maladaptation between the distal edge of the bSG and the coeliac trunk was detected, the bSG was relined with a b-ex stent graft. In the same patient, the IVUS showed stenosis of a b-ex stent graft at the ostium of a renal artery. The stenosis was treated by relining with a b-ex stent graft. In another case, a maladaptation between the distal edge of the bSG and the superior mesenteric artery was detected, relined with a s-ex stent. In the same patient, the IVUS showed stenosis of a b-ex stent graft at ostium of a renal artery. The stenosis was treated by relining with a s-ex stent graft. In another case, the IVUS detected compression of the bSG to an accessory renal artery, which was relined with a b-ex stent graft.

All TVVs requiring intra-operative correction based on the IVUS findings were imaged with angiography and IVUS to confirm final results.

## Re-interventions and follow up

During the first 30 post-operative days one TVV related re-intervention was performed due to the occlusion of a b-ex



stent graft in a renal artery. The occlusion had led to an AKI and was confirmed by a CTA on the fourth day after the implantation of a branched stent graft. A rotational thrombectomy was performed. Due to the unsatisfactory result of the thrombectomy, the TVV was relined with a b-ex stent graft and a s-ex stent. Technical issues regarding the originally implanted bSG could not be identified.

The first post-operative CTA (at least 30 days after the index procedure) was available in 75 cases (94%), accounting for 268 of the 274 TVVs originally assessed by IVUS. In seven of the 268 TVVs (2.6%) where the IVUS or the plain angiogram did not show any sign of instability by the end of the index procedure, re-intervention became necessary due to CTA findings. All findings were unrelated to any kind of symptomatology and theoretically should have been detected by IVUS intra-operatively. In all cases, relining was performed.

Details of the CTA identified pathological findings and subsequent treatment of the seven TVVs are summarised in [Table 3](#) and below.

One patient treated by BEVAR underwent re-intervention to all four branches four months after the index procedure. An type IIIc endoleak forced the relining of a b-ex stent graft in the superior mesenteric artery with a new b-ex stent graft. Due to a maladaptation between the bSG and the artery, distal relining with a s-ex stent was performed. Furthermore, the CTA showed a stenosis of a b-ex stent graft at the ostium of the coeliac trunk and of the left renal artery as well as a maladaptation between the bSG and both arteries. The stenoses were treated with a b-ex stent graft, while the maladaptation was dealt with a s-ex stent. Moreover, due to a distal maladaptation between the b-ex stent graft and the right renal artery, relining with a s-ex stent was performed.

**Table 2.** Intravascular ultrasound (IVUS) findings and intra-operative re-interventions of the entire population of 80 patients investigated for bridging stent instability with IVUS

TVV	BEVAR/FEVAR	bSG	IVUS finding	Type of re-intervention
CT	BEVAR	s-ex	maladaptation between the bSG and the TVV	Relining with b-ex stent graft
SMA	BEVAR	b-ex	extrinsic compression between the aortic graft and the aortic wall	Relining with s-ex stent
SMA	BEVAR	b-ex	stenosis of the bSG at the ostium of the TVV	Relining with b-ex stent
SMA	BEVAR	s-ex	maladaptation between the bSG and the TVV	Relining with s-ex stent
RRA	BEVAR	s-ex	stenosis of the bSG at the ostium of the TVV	Relining with a b-ex stent graft
RRA	BEVAR	s-ex	stenosis of the bSG at the ostium of the TVV	Relining with s-ex stent
ARA	BEVAR	s-ex	stenosis of the bSG due to compression of the bSG	Relining with a b-ex stent graft

ARA = accessory renal artery; b-ex = balloon expandable; bSG = bridging stent graft; CT coeliac trunk; s-ex = self expandable stent graft; SMA = superior mesenteric artery; RRA = right renal artery; TVV = target visceral vessel.



**Table 3. Computed tomographic findings and re-interventions in the population of patients investigated for bridging stent instability with intravascular ultrasound (IVUS) who completed the 30 day follow up (n = 75)**

TVV	BEVAR/FEVAR	bSG	Computed tomography findings	Type of re-intervention
SMA	BEVAR	b-ex	maladaptation between the bSG and the TVV; type IIIc endoleak	Intrastent relining with b-ex stent graft and distal relining with s-ex stent
CT	BEVAR	b-ex	stenosis of the bSG at the ostium of the TVV; maladaptation between the bSG and the TVV	Intrastent relining with b-ex stent graft and distal relining with s-ex stent
LRA	BEVAR	b-ex	stenosis of the bSG at the ostium of the TVV; maladaptation between the bSG and the TVV	Intrastent relining with b-ex stent graft and distal relining with s-ex stent
RRA	BEVAR	b-ex	maladaptation between the bSG and the TVV	Distal relining with s-ex stent
SMA	BEVAR	b-ex	stenosis of the bSG at the ostium of the TVV	Relining with b-ex stent graft
LRA	BEVAR	b-ex	stenosis of the bSG at the ostium of the TVV	Relining with b-ex stent graft
CT	BEVAR	b-ex	maladaptation between the bSG and the TVV	Relining with s-ex stent

ARA = accessory renal artery; b-ex = balloon-expandable; bSG = bridging stent graft; CT coeliac trunk; s-ex = self expandable stent graft; SMA = superior mesenteric artery; LRA = left renal artery; RRA = right renal artery; TVV = target visceral vessel.

In one case, the CTA performed two months after a BEVAR showed a stenosis of a b-ex stent graft at the ostium of the superior mesenteric artery and of the left renal artery. The stenoses were treated with a b-ex stent graft. In the same patient, a distal relining with a s-ex stent was performed due to a maladaptation between the distal part of the bSG for the coeliac trunk and the artery.

## DISCUSSION

The Achilles heel of F/B-EVAR is related to bSG complications. Routine intra-operative bSG control is done by angiography. It has already been reported that single plane angiography has limited ability to identify possible bSG complications due to its bi-dimensional character.<sup>3</sup> Nevertheless, plain angiography alone detects pathological findings in up to 7% of the cases.<sup>3</sup> Bi-plane angiography guidance has recently been shown to have similar results to single plane angiography in terms of median fluoroscopy time, contrast agent volume applied, radiation dose, and technical success in F/B-EVAR procedures. However, the use of bi-plane angiography guidance was associated with a significant decrease in operation time.<sup>16</sup>

In the current multicentre study, the advantages and disadvantages of using IVUS for intra-operative control of the bSG in complex EVAR has been investigated. The overall technical success was 91.9%. No IVUS related complications were detected. All technical failures were related to access issues. In all these cases, a 0.018 inch catheter was used to approach the TVVs. In particular, all cases of malfunction of the IVUS catheter (14 cases) appeared after the cannulation of the second or third branch in BEVAR procedures performed via a transfemoral approach with implantation of the bSG over a 180 degree angle. The remaining cases where the IVUS examination was not performed (five because of lost wire and two due to failure to advance the IVUS catheter over the wire) occurred in patients who underwent FEVAR with implantation of the bSG over a 90 degree angle. This could be the result of exhaustion of the steerable sheath and or of the IVUS catheter when used over challenging angles. The issue of losing the wire or failing to advance the IVUS catheter could have been

eventually avoided by using a 0.035 inch catheter, thus avoiding a wire exchange.

Overall, intra-operative IVUS detected seven unstable bSG (2.5%) that were not detected during angiography. These data can be compared with those previously reported in a single centre study on 33 TVVs, where the number of unstable bSGs detected by IVUS was significantly higher (12%).<sup>11</sup> The potential to immediately correct possible pathological findings strengthens the value of IVUS as a complementary imaging method in complex EVAR.

The additional use of IVUS has advantages over angiography alone. IVUS gives a 360 degree axial view of the vessel, thereby more accurately evaluating the morphological characteristics of a potential landing zone. The use of IVUS could also lead to a reduction of contrast medium injection and radiation exposure.<sup>7</sup> Radiation exposure is a major problem for the patient and for the operator during F/B-EVAR procedures.

The use of IVUS allows a comparable if not superior vessel evaluation, potentially reducing the use of the completion angiography. A mean fluoroscopy time of 79 minutes reported in the current study underlines this aspect. A high level of experience is required for F/B-EVAR procedures as well as for IVUS examination. This aspect together with the additional information gained by IVUS examination can potentially decrease radiation exposure during F/B-EVAR.

Limited use of contrast medium thanks to the complementary use of IVUS can potentially reduce the risk of AKI, a major complication in the context of the F/B-EVAR procedure. The incidence of AKI after F/B-EVAR has been described as occurring in up to 41%.<sup>4</sup> In the current study, an AKI incidence of 18.7% was reported (requiring temporary or permanent dialysis in 10% of the cases). The use of high volumes of contrast medium has been associated with an increased risk of AKI.<sup>17,18</sup>

However, the limited number of TVVs included in the present cohort as well as the non-randomised character of the current study do not allow conclusions on the influence of IVUS on the occurrence of AKI.

The use of the IVUS causes additional costs, as well as prolonged procedure times. Furthermore, a learning curve for the correct interpretation of IVUS images should be

expected. Regarding the time needed to perform IVUS, an additional procedure time of 3.5 minutes per vessel during BEVAR has been reported previously.<sup>10</sup>

The 30 day CTA detected an additional seven cases of TVV branch instability, which had been missed by intra-operative IVUS warranting intervention, thus limiting IVUS in this report to a 50% sensitivity. While the merit of avoiding additional radiation exposure and avoiding potential secondary interventions is indisputable, there seems to be a lack of effectiveness of this method. On the other hand, it cannot be excluded that the later cases of TVV branch instability were not present intra-operatively and developed solely post-operatively.

Despite its potential, the use of IVUS alone, without complementary angiography, is considered unsafe. Apart from its sensitivity and specificity which should be further investigated, another limitation of IVUS technology applied to F/B-EVAR is its inability to detect distal embolisation or TVV related endoleak.

### Limitations

The current study has several limitations. Despite its multi-centre, prospective character, the lack of a randomisation between IVUS and non-IVUS supported F/B-EVAR as well as a lack of comparison with CBCT has to be considered. Furthermore, the use of different approaches to the use of the IVUS as well as to the F/B-EVAR technology (i.e., inner branches, outer branches, fenestrations, and or a combination of them) could have influenced the results. Moreover, the short follow up could affect the incidence of bSG instability. IVUS does not allow the detection or exclusion of any kind of endoleak, even when using the ChromaFlow technology. This is due its limited sensitivity and specificity in flow detecting, but also because IVUS examination is not carried out at the end of the procedure when the aneurysm is theoretically completely excluded. Therefore, intra-operative IVUS is to be considered as a complement to single plane angiography rather than a stand alone diagnostic method in complex F/B-EVAR. Its value is to be seen in better evaluating geometric aspects such as maladaptation or kinking of the bSG, which can be easily overseen by single plane angiography.

### Conclusion

The use of IVUS as a complementary diagnostic tool during F/B-EVAR has been shown to be safe and accurate in the current experience. This multicentre study suggests that IVUS may be a valuable adjunctive imaging technology in intra-operative detection of TVV instability in F/B-EVAR. Further long term investigations on larger cohorts of patients are required to validate these results. Furthermore, this minimally invasive diagnostic method should also be compared with alternative technologies such as CBCT in terms of efficiency, radiation exposure, procedural time, and costs.

### APPENDIX A. SUPPLEMENTARY DATA

Supplementary data to this article can be found online at <https://doi.org/10.1016/j.ejvs.2023.09.009>.

### REFERENCES

- 1 Ellahi A, Shaikh FN, Kashif H, Khan H, Ali E, Nasim B, et al. Effectiveness of endovascular repair versus open surgery for the treatment of thoracoabdominal aneurysm: a systematic review and meta analysis. *Ann Med Surg (Lond)* 2022;**81**:104477.
- 2 Silingardi R, Gennai S, Leone N, Gargiulo M, Faggioli G, Cao P, et al. Standard “off-the-shelf” multibranched thoracoabdominal endograft in urgent and elective patients with single and staged procedures in a multicenter experience. *J Vasc Surg* 2018;**67**:1005–16.
- 3 Tenorio ER, Oderich GS, Sandri GA, Ozbek P, Kärrkäinen JM, Macedo TA, et al. Impact of onlay fusion and cone beam computed tomography on radiation exposure and technical assessment of fenestrated-branched endovascular aortic repair. *J Vasc Surg* 2019;**69**:1045–58.
- 4 Walker J, Kaushik S, Hoffman M, Gasper W, Hiramoto J, Reilly L, et al. Long-term durability of multibranched endovascular repair of thoracoabdominal and pararenal aortic aneurysms. *J Vasc Surg* 2019;**69**:341–7.
- 5 Hertault A, Maurel B, Sobocinski J, Gonzalez TM, Le Roux M, Azzaoui R, et al. Impact of hybrid rooms with image fusion on radiation exposure during endovascular aortic repair. *Eur J Vasc Endovasc Surg* 2014;**48**:382–90.
- 6 Panuccio G, Greenberg RK, Wunderle K, Mastracci TM, Eagleton MG, Davros W. Comparison of indirect radiation dose estimates with directly measured radiation dose for patients and operators during complex endovascular procedures. *J Vasc Surg* 2011;**53**:885–94.
- 7 Vogt KC, Brunkwall J, Malina M, Ivancev K, Lindblad B, Risberg B, et al. The use of intra-vascular ultrasound as control procedure for the deployment of endovascular stented grafts. *Eur J Vasc Endovasc Surg* 1997;**13**:592–6.
- 8 Hoshina K, Kato M, Miyahara T, Mikuriya A, Ohkubo N, Miyata T. A retrospective study of intravascular ultrasound use in patients undergoing endovascular aneurysm repair: its usefulness and a description of the procedure. *Eur J Vasc Endovasc Surg* 2010;**40**:559–63.
- 9 Illuminati G, Nardi P, Fresilli D, Sorrenti S, Lauro A, Pizzardi G, et al. Fully ultrasound-assisted endovascular aneurysm repair: preliminary report. *Ann Vasc Surg* 2022;**84**:55–60.
- 10 Usai MV, Oberhuber A, Ascitutto G. Assessment of bridging stent grafts in branched endovascular aortic repair (EVAR) procedures using intravascular ultrasound (IVUS). *EJVES Vasc Forum* 2020;**47**:51–4.
- 11 Gennai S, Leone N, Saitta G, Migliari M, Lauricella A, Farchioni L, et al. Intravascular ultrasound in branched and fenestrated endovascular aneurysm repair: initial experience in a single-center cohort study. *J Endovasc Ther* 2021;**28**:828–36.
- 12 Mastracci TM, Greenberg RK, Eagleton MJ, Hernandez AV. Durability of branches in branched and fenestrated endografts. *J Vasc Surg* 2013;**57**:926–33.
- 13 Oderich GS, Forbes TL, Chaer R, Davies MG, Lindsay TF, Mastracci T, et al. Reporting standards for endovascular aortic repair of aneurysms involving the renal-mesenteric arteries. *J Vasc Surg* 2021;**73**:4S–52S.
- 14 Fillinger MF, Greenberg RK, McKinsey JF, Chaikof EL, on behalf of the Society for Vascular Surgery Ad Hoc Committee on TEVAR Reporting Standards. Reporting standards for thoracic endovascular aortic repair (TEVAR). *J Vasc Surg* 2010;**52**:1022–33.
- 15 KDIGO Clinical Practice Guideline for Acute Kidney Injury. *Kidney Int* 2012;**2**(Suppl):1–138.
- 16 Sotir A, Klopff J, Wolf F, Funovics MA, Loewe C, Domenig C, et al. Monoplane versus biplane fluoroscopy in patients undergoing fenestrated/branched endovascular aortic repair. *J Vasc Surg* 2023;**77**:1359–66.
- 17 Liang NL, Mohapatra A, Avgerinos ED, Katsargyris A. Acute kidney injury after complex endovascular aneurysm repair. *Curr Pharm Des* 2019;**25**:4686–94.
- 18 Dossabhoy SS, Simons JP, Crawford AS, Aiello FA, Judelson DR, Arous EJ, et al. Impact of acute kidney injury on long-term outcomes after fenestrated and branched endovascular aortic aneurysm repair. *J Vasc Surg* 2020;**72**:55–65.