






Case Report

A Case of Advanced Hepatocellular Carcinoma with Bone Metastases Managed with Tyrosine Kinase Inhibitors and Aggressive Palliative Radiation Therapy: Role of Combination Therapy for Extending Survival

Luca Ielasi ^{1,2}, Bernardo Stefanini ^{1,2}, Fabio Piscaglia ^{1,2}, Alessandro Granito ^{1,2,*} and Francesco Tovoli ^{1,2}

¹ Division of Internal Medicine, Hepatobiliary and Immunoallergic Diseases, IRCCS Azienda Ospedaliero-Universitaria di Bologna, 40138 Bologna, Italy

² Department of Medical and Surgical Sciences, University of Bologna, 40138 Bologna, Italy

* Correspondence: alessandro.granito@unibo.it

Abstract: We report the case of a 68-year-old man with advanced hepatocellular carcinoma (HCC) with multiple bone metastases (BM) treated with tyrosine kinase inhibitors. Despite an insufficient disease control on BM with a progression free survival (PFS) of 6 months, sorafenib was not discontinued and multiple radiation therapy (RT) sessions with a palliative purpose were performed. Thanks to this aggressive radiotherapy approach in order to control the bone tumor burden, the patient has continued sorafenib for 34.6 months achieving an overall survival (OS) of 41.3 months. This result highlights the importance of a tailored management of patients with advanced HCC and the role of the RT for BM control, even if at lower cumulative radiation dose, for extending patient survival.

Keywords: hepatocellular carcinoma; bone metastases; radiotherapy; sorafenib



Citation: Ielasi, L.; Stefanini, B.; Piscaglia, F.; Granito, A.; Tovoli, F. A Case of Advanced Hepatocellular Carcinoma with Bone Metastases Managed with Tyrosine Kinase Inhibitors and Aggressive Palliative Radiation Therapy: Role of Combination Therapy for Extending Survival. *Gastroenterol. Insights* **2023**, *14*, 38–44. <https://doi.org/10.3390/gastroent14010005>

Academic Editor: David A. Gerber

Received: 22 December 2022

Revised: 22 January 2023

Accepted: 10 February 2023

Published: 12 February 2023



Copyright: © 2023 by the authors. Licensee MDPI, Basel, Switzerland. This article is an open access article distributed under the terms and conditions of the Creative Commons Attribution (CC BY) license (<https://creativecommons.org/licenses/by/4.0/>).

1. Introduction

Hepatocellular carcinoma (HCC) is a leading cause of cancer-related death worldwide and a globally relevant medical problem [1]. Despite the significant advances in surveillance and diagnosis, and the availability of multiple treatment modalities, the prognosis remains poor, mainly in advanced stage [2]. In this setting, surgical approaches and loco-regional treatments cannot generally control the entire tumor burden and systemic therapy is the recommended treatment [3–5]. The last decade has been characterized by the advent of several new systemic agents, in both first line settings and beyond, expanding the therapeutic armamentarium for advanced HCC patients.

However, symptoms of advanced HCC as well as side effects of systemic therapies not only reduce the quality of life but also cause treatment interruptions and dose reductions that can potentially decrease therapeutic efficacy. Therefore, through a multidisciplinary management, the optimal treatment of advanced HCC should also aim at efficiently controlling cancer-related symptoms to prolong life while preserving quality of life [6].

Of note, there is now the possibility of combining multiple treatment approaches together with systemic therapy and this could theoretically provide better outcomes.

Among these combination treatments, loco-regional ones are assuming a relevant role in liver oncology in the last years, both for hepatic and extrahepatic tumor localizations. Radiation therapy is widely used in clinical practice for the management of HCC, even in advanced stages. It can be for curative purposes, to ablate the lesion through a higher dose of radiation, or it can be palliative, to shrink the volume of the tumor mass, or for the relief of pain by a lower dose of radiation.

Bone metastases are generally the most common target of palliative, antalgic, radiation therapy. We report a case of a patient with advanced HCC and multiple bone metastases who was initially treated with first line sorafenib with a good intrahepatic treatment

response, but an insufficient disease control on extrahepatic disease. During treatment with sorafenib, that has not been discontinued according to the multidisciplinary team decision, multiple radiation therapy sessions with analgesic purpose have been performed on bone metastases. This approach provided satisfactory, safe, and effective control of bone pain due to metastatic cancer with improved quality of life and extended survival.

2. Case Report

In 2010, a 68-year-old obese Caucasian male (BMI 34.5 kg/m²) underwent segmental liver resection for a monofocal poorly differentiated (G3 according to Edmonson–Steiner classification) hepatocellular carcinoma (HCC), that had arisen on a precirrhotic liver with underlying non-alcoholic fatty liver disease (F3 according to METAVIR histopathological system). HCC was detected during regular ultrasound surveillance because the patient presented chronic hepatitis C infection (HCV), previously treated with interferon alpha and ribavirin achieving a sustained virologic response since 2000. No other significant clinical conditions were reported in his past medical history, with the exception of a mild chronic obstructive pulmonary disease as a former smoker.

In 2015, recurrence of histology confirmed G3 HCC (three hepatic nodules) during the follow up. Consequently, the patient was treated with transarterial chemo-embolization. Unfortunately, progressive disease due to incomplete response of the treated nodules and appearance of new intrahepatic (three nodules) and extrahepatic lesions was detected on a contrast enhanced computed tomography (CT) scan performed three months after the loco-regional treatment. The presence of multiple bone metastases (left clavicle, V left rib, D5, D11 and L4 vertebrae, sacrum and left iliac crest) defined the progression as an advanced stage of disease, according to the Barcelona Clinic for Liver Cancer staging system (BCLC stage C). At that point, serum alpha-fetoprotein (AFP) was negative (4.7 ng/mL), liver function was preserved (Child–Pugh class A5) and patient general conditions were good according to Eastern Cooperative Oncology Group Performance Status (ECOG-PS 0).

Sorafenib was started as first-line systemic treatment at a full dose of 800 mg/day in December 2015. Permanent reduction to 400 mg/day was necessary to manage drug-related adverse events (grade 3 diarrhea, grade 2 hand/foot skin reaction, grade 2 oral mucositis, grade 1 fatigue and grade 1 weight loss); a satisfactory drug tolerance was consequently achieved, allowing the patient to continue the treatment with sorafenib.

Six months after the beginning of first-line systemic therapy (June 2016), radiological progression of disease was documented due to dimensional increase of only the V left costal metastases. Based on the stability of both intrahepatic and other bone localizations of disease, the patient was referred to the Radiotherapy Unit for radiation therapy (RT) and sorafenib was continued. In fact, the patient refused to be enrolled in second-line clinical trials available at that moment.

Meanwhile, two more RT sessions with analgesic purpose were performed on left clavicle and L4 vertebra because of the appearance of left clavicular and back lumbar pain without pathological fractures on X-rays.

In December 2016, a new bone metastasis at L2 vertebra was detected on CT scan, while other intra- and extrahepatic localizations were stable. Consistent with the previous treatment strategy, RT was performed on L2 vertebra and sorafenib was continued. After a few months, two RT sessions with analgesic purpose were performed on bone localization of D5 vertebra because of the appearance of back dorsal pain without pathological fractures on X-rays.

In October 2018, a significant progression of disease occurred. Hepatic lesions increased in number and dimensions, but also new abdominal lymph nodes and bone lesions (X right rib) appeared. In light of this evident disease progression under the ongoing therapy, sorafenib was permanently discontinued. Given the good tolerance to first line sorafenib, regorafenib was started as a second-line therapy (regorafenib was licensed for HCC in Italy in 2018) at a standard dose of 160 mg/day in cycles of 3 weeks on/1 week

off. Another RT session on X right rib was performed with antalgic purpose few days after switching to regorafenib.

Regorafenib was well tolerated, and only low-grade drug-related adverse events were reported (grade 1 diarrhea and grade 1 fatigue), so no dose reduction was required.

The first assessment of treatment response performed with CT scan after 8 weeks from second-line therapy initiation showed stable disease. However, regorafenib was discontinued 2.6 months after, due to the clinical deterioration of the patient's general conditions (ECOG-PS 3); liver function was, however, still preserved (Child–Pugh class A6).

Although the drug discontinuation too place, the patient's general conditions did not improve. The patient died due to bacterial pneumonia in May 2019.

3. Discussion

Hepatocellular carcinoma is the most common histological type of primary liver cancer and it represents the sixth most common cancer and the third cause of cancer-related death worldwide with more than 830,000 deaths per year [1]. In the majority of cases, HCC occurs in patients with an underlying chronic liver disease, mainly cirrhosis. The most common etiologies of liver cirrhosis are chronic viral hepatitis (HBV infection and HCV infection), chronic alcohol assumption and non-alcoholic fatty liver disease.

Patients with liver cirrhosis are considered at high risk of developing liver cancer and they are included in surveillance programs, generally based on semiannual ultrasound surveillance, to detect disease at an early stage in order to augment the likelihood of curative treatment.

Surveillance has been shown to increase the probability of diagnosing HCC at earlier stages of the disease, increasing the rate of access to curative treatments and, consequently, increasing patients' survival [3]. Patients with eradicated hepatitis C virus infection and non-alcoholic fatty liver disease are categories that are of special interest because they are also at risk of developing HCC, but they are formally excluded by surveillance programs [7].

The prognosis varies greatly among HCC patients with different stages of disease with median survivals ranging from more than 5 years for very early and early stages to 3 months for terminal stage [5].

Despite recent advances in treatment that have significantly improved the survival outcomes of patients with HCC, the presence of extrahepatic spread, an indirect sign of tumor biological aggressiveness, remains a predictor of poor prognosis [2]. Patients with extrahepatic spread, just as patients with macrovascular tumor invasion or cancer-related deterioration of general conditions (ECOG-PS > 0), are considered in an advanced stage of the disease [5]. According to the main international guidelines, patients with metastatic HCC undergo systemic therapy as first treatment option [3–5].

Bone metastases (BM) represent the second most common extrahepatic site for HCC after lungs, accounting for approximately the 30% of extrahepatic HCC localizations [8]. In addition to the primary tumor burden, patients with BM suffer from skeleton-related events, loss of mobility, reduced quality of life and increased medical cost [9]. Radiation therapy (RT) is widely used for management of BM with both curative and palliative purpose [10].

The role of stereotactic ablative radiotherapy (SABR) in combination with standard treatments in patients with BM has been largely studied in the last years.

The SABR-COMET (Stereotactic Ablative Radiotherapy for the Comprehensive Treatment of Oligometastases) trial on various solid cancers (mainly breast, lung, colorectal and prostate) showed a prolonged progression free survival (PFS) and overall survival (OS) in oligometastatic patients (i.e., with <5 BM) treated with SABR in a median follow-up of 25 months. Among 66 patients randomized in the treatment arm, 19 patients (28.7%) experienced grade 2 or worse treatment-related adverse events and 3 patients died (4.5%) [11].

In the long-term and extended long-term analysis of SABR-COMET trial (median follow-up of 51 months and beyond 5 years, respectively), authors confirmed the durable improvement in OS and PFS in the SABR arm with 21.3% of patients achieving a survival

of more than 5 years and a lower need of cytotoxic chemotherapy. Moreover, no significant differences in quality of life between arms have been observed [12,13].

In parallel, *Kim TH* et al. showed the beneficial effect of RT in 530 patients with BM from HCC with an OS of 5.1 months in the entire study population. Higher radiation dose (>60 Gy) was significantly related to better outcomes than lower radiation dose, with an OS of 8.1 and 4.4 months, respectively. No significant differences were reported between fractionated and unfractionated radiation dose regimens [14]. In this study, sorafenib was administered only in 194 patients (37% of the entire study population), and data on survival of this subgroup are lacking.

On the other hand, RT used with palliative purposes can result in an overall pain improvement in 73%–99% of cases and a complete pain relief in 17%–44% of patients with HCC and BM, thus reducing analgesic requirements [15]. The latter figure is of particular interest in HCC patients, most of whom have an underlying liver dysfunction potentially affecting analgesic metabolism [16]. Different radiation schedules have been proposed; recently, *He J* et al. showed that high-dose multiple fraction schedule is related to a longer period of pain relief compared to hypofractionated RT [17].

The median OS remains poor (5.0–7.4 months) with worse outcomes in patients with spinal cord compression and skull BM [15,18–20]. Among patients with spinal metastases, the rates of pathologic vertebral compression fractures and metastatic epidural spinal cord compression have been estimated to be 12.6% and 9.5%, respectively [21].

The potential benefits of combining RT with systemic therapy in selected subgroups of patients has also been demonstrated by the results of the NRG Oncology/RTOG 1112 trial (NCT01730937), presented at the last American Society for Radiation Oncology (ASTRO) Annual Meeting. This is a randomized phase 3 study of sorafenib with or without stereotactic body radiation therapy (SBRT) for locally advanced HCC patients who were ineligible for surgical resection or other local or regional standard therapies showed that adding SBRT improved OS, PFS, and time to progression (TTP) in patients with advanced HCC, compared to sorafenib alone, with no significant increase in adverse events [22].

Similarly, a recent meta-analysis of *Li H* et al. demonstrated that combination therapy was more effective than sorafenib monotherapy in patient with advanced HCC. In particular, sorafenib plus RT was the combination with longer median OS and PSF and lower rate of adverse events [23].

At the time of presentation of the index patient, the only available therapy was sorafenib, an oral multitarget tyrosine kinase inhibitor (TKI) that suppresses tumor neo-angiogenesis and tumor cell proliferation. Since its registration trial in 2008 [24], the increasing experience with the management of sorafenib and its drug-related adverse events led to longer treatment duration and survival in patients with advanced HCC [25,26]. Additionally, the advent of regorafenib, another oral TKI and the first available second line therapy for patients who tolerated and progressed on sorafenib, improved survival further, extending up to 26 months the median overall survival of patients with preserved liver function, and not amenable to loco-regional treatments for HCC [27,28].

In the last few years, two more oral TKIs have been approved for the treatment of advanced HCC. Lenvatinib was demonstrated to be non-inferior to sorafenib as first line therapy, and cabozantinib was demonstrated to be superior to placebo as second and third line therapy in previously sorafenib treated patients [29–32].

Nowadays, the therapeutic scenario of advanced HCCs is moving toward immunotherapy since the combination of atezolizumab (a PD-L1 inhibitor antibody) plus bevacizumab (an anti-VEGF antibody) demonstrated its superiority compared to sorafenib as a first-line therapy [33], and several promising trials are now ongoing.

Of note, TKIs still remain the only treatment strategy in patients with contraindications to immune checkpoint inhibitors and solid organ recipients [34]. Moreover, TKIs still represent the only available option for second- and third-line therapy in many countries, while optimal therapeutic sequencing for patients experiencing failure to first line atezolizumab/bevacizumab is still to be defined [35,36].

At the same time, the high cost of immune checkpoint inhibitors and the need to schedule continuous intravenous infusions raise a pharmacoeconomic issue and a logistical problem that could limit the spread of these new therapeutic regimens.

The strong relationship between the tumor microenvironment and the efficacy of immune checkpoint inhibitors questions the actual role of these novel treatments in the disease control of certain sites like bone. First preclinical data are now emerging [37,38], but real-life results on metastases site specific efficacy are not yet available.

We reported a case in which an aggressive use of palliative RT led to a long-lasting OS in a patient with advanced metastatic HCC (41.3 months), despite a short PFS of only 6 months (Figure 1 and Table 1).

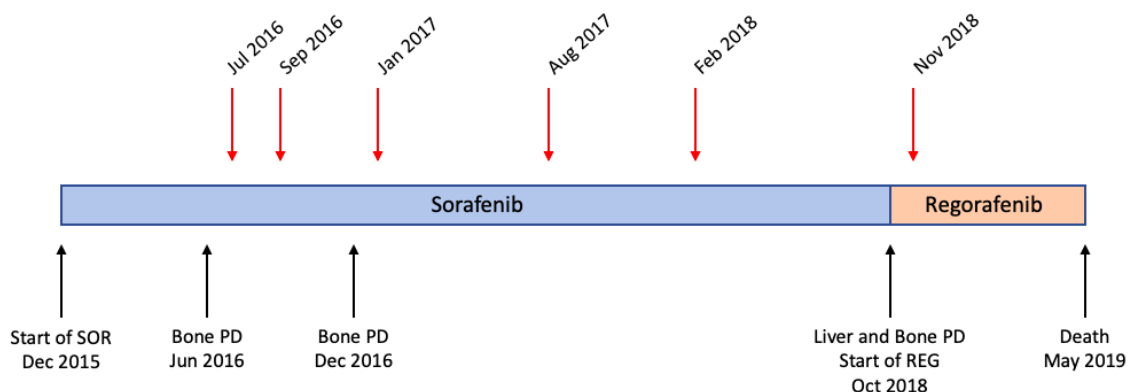


Figure 1. Timeline from the start of sorafenib until death of the patient. Red arrows represent radiation therapy sessions. PD: progression of disease; REG: regorafenib; SOR: sorafenib.

Table 1. Date, localization and radiation schedules of each radiation therapy sessions for bone metastases.

Date	Site	Single Dose	Sessions	Total Dose
Jul 2016	5th left rib	4 Gy	5	20 Gy
Sep 2016	Left clavicle	4 Gy	5	20 Gy
Sep 2016	L4 vertebra	4 Gy	5	20 Gy
Jan 2017	L2 vertebra	4 Gy	5	20 Gy
Aug 2017	D5 vertebra	4 Gy	5	20 Gy
Feb 2018	D5 vertebra	4 Gy	3	12 Gy
Nov 2018	10th right rib	4 Gy	5	20 Gy

This extended survival is far from the aforementioned data reported in literature about both TKIs and RT. The multidisciplinary team, in agreement with patient personal preference, decided to not discontinue sorafenib until a significant progression of the entire tumor burden, leading to a longer duration of treatment (34.6 months) and a longer survival consequently.

4. Conclusions

The combination of systemic therapy and repeated radiation therapy sessions, although at lower cumulative dose and for a palliative purpose, and a tailored management of the patient allowed a significant extension of patient survival that was estimated as poor a priori.

Considering the current refinement and increasing availability of multiple treatment modalities, the possibility of combining different therapeutic approaches should always be considered, even in advanced stages of the disease, not only to shrink the tumor burden but also to avoid deterioration of quality of life. Evaluation of each case by a multidisciplinary team is the key to establish the best treatment strategy.

Author Contributions: Conceptualization, L.I.; writing—original draft preparation, L.I. and B.S.; writing—review and editing, A.G. and F.T.; Supervision, F.P. All authors have read and agreed to the published version of the manuscript.

Funding: This research received no external funding.

Institutional Review Board Statement: As case report based on normal clinical practice, the approval by local Ethical Committee was not mandatory.

Informed Consent Statement: Patient relatives were aware of our intention to publish this manuscript. A freely given informed consent was obtained.

Data Availability Statement: Clinical, laboratory and radiological reports concerning the case described in this manuscript are available from the corresponding author on reasonable request.

Conflicts of Interest: F.T. has served as a consultant for Bayer, Ipsen, and Eisai and an advisory board member for Laforce. F.P. is a consultant for Bayer, Bracco, Eisai, Esaote, Exact Sciences, Ipsen and Samsung and an advisory board member for AstraZeneca, Bayer, Eisai, MSD, Roche. L.I., B.S. and A.G. have no conflict of interest to declare.

References

1. Sung, H.; Ferlay, J.; Siegel, R.L.; Laversanne, M.; Soerjomataram, I.; Jemal, A.; Bray, F. Global Cancer Statistics 2020: GLOBOCAN Estimates of Incidence and Mortality Worldwide for 36 Cancers in 185 Countries. *CA Cancer J. Clin.* **2021**, *71*, 209–249. [[CrossRef](#)]
2. Uka, K. Clinical features and prognosis of patients with extrahepatic metastases from hepatocellular carcinoma. *World J. Gastroenterol.* **2007**, *13*, 414. [[CrossRef](#)] [[PubMed](#)]
3. European Association for the Study of the Liver. EASL Clinical Practice Guidelines: Management of hepatocellular carcinoma. *J. Hepatol.* **2018**, *69*, 182–236. [[CrossRef](#)]
4. Heimbach, J.K.; Kulik, L.M.; Finn, R.S.; Sirlin, C.B.; Abecassis, M.M.; Roberts, L.R.; Zhu, A.X.; Murad, H.; Marrero, J.A. AASLD guidelines for the treatment of hepatocellular carcinoma. *Hepatol. Baltim. Md.* **2018**, *67*, 358–380. [[CrossRef](#)] [[PubMed](#)]
5. Reig, M.; Forner, A.; Rimola, J.; Ferrer-Fàbrega, J.; Burrel, M.; Garcia-Criado, Á.; Kelley, R.K.; Galle, P.R.; Mazzaferro, V.; Salem, R.; et al. BCLC strategy for prognosis prediction and treatment recommendation: The 2022 update. *J. Hepatol.* **2022**, *76*, 681–693. [[CrossRef](#)]
6. Aimar, G.; Marino, D.; Zichi, C.; Gamba, T.; Caglio, A.; De Vita, F.; Sperti, E.; Di Maio, M. Advanced hepatocellular carcinoma: Impact of systemic treatments on health-related quality of life and patient-reported outcomes. *Liver Cancer Int.* **2022**, *3*, 90–98. [[CrossRef](#)]
7. Stefanini, B.; Tonnini, M.; Serio, I.; Renzulli, M.; Tovoli, F. Surveillance for hepatocellular carcinoma: Current status and future perspectives for improvement. *Expert Rev. Anticancer Ther.* **2022**, *22*, 371–381. [[CrossRef](#)]
8. Schlageter, M.; Quagliata, L.; Matter, M.; Perrina, V.; Tornillo, L.; Terracciano, L. Clinicopathological Features and Metastatic Pattern of Hepatocellular Carcinoma: An Autopsy Study of 398 Patients. *Pathobiology* **2016**, *83*, 301–307. [[CrossRef](#)]
9. Coleman, R.E.; Croucher, P.I.; Padhani, A.R.; Clézardin, P.; Chow, E.; Fallon, M.; Guise, T.; Colangeli, S.; Capanna, R.; Costa, L. Bone metastases. *Nat. Rev. Dis. Primer* **2020**, *6*, 83. [[CrossRef](#)]
10. Huang, Z.; Wen, J.; Wang, Y.; Han, S.; Li, Z.; Hu, X.; Zhu, D.; Wang, Z.; Liang, J.; Chen, X.; et al. Bone metastasis of hepatocellular carcinoma: Facts and hopes from clinical and translational perspectives. *Front. Med.* **2022**, *16*, 551–573. [[CrossRef](#)]
11. Palma, D.A.; Olson, R.; Harrow, S.; Gaede, S.; Louie, A.V.; Haasbeek, C.; Mulroy, L.; Lock, M.; Rodrigues, G.B.; Yaremko, B.P.; et al. Stereotactic ablative radiotherapy versus standard of care palliative treatment in patients with oligometastatic cancers (SABR-COMET): A randomised, phase 2, open-label trial. *Lancet* **2019**, *393*, 2051–2058. [[CrossRef](#)]
12. Palma, D.A.; Olson, R.; Harrow, S.; Gaede, S.; Louie, A.V.; Haasbeek, C.; Mulroy, L.; Lock, M.; Rodrigues, G.B.; Yaremko, B.P.; et al. Stereotactic Ablative Radiotherapy for the Comprehensive Treatment of Oligometastatic Cancers: Long-Term Results of the SABR-COMET Phase II Randomized Trial. *J. Clin. Oncol. Off. J. Am. Soc. Clin. Oncol.* **2020**, *38*, 2830–2838. [[CrossRef](#)]
13. Harrow, S.; Palma, D.A.; Olson, R.; Gaede, S.; Louie, A.V.; Haasbeek, C.; Mulroy, L.; Lock, M.; Rodrigues, G.B.; Yaremko, B.P.; et al. Stereotactic Radiation for the Comprehensive Treatment of Oligometastases (SABR-COMET): Extended Long-Term Outcomes. *Int. J. Radiat. Oncol. Biol. Phys.* **2022**, *114*, 611–616. [[CrossRef](#)]
14. Kim, T.H.; Park, S.; Rim, C.H.; Choi, C.; Seong, J. Improved oncologic outcomes by ablative radiotherapy in patients with bone metastasis from hepatocellular carcinoma. *J. Cancer Res. Clin. Oncol.* **2021**, *147*, 2693–2700. [[CrossRef](#)]
15. Hayashi, S.; Tanaka, H.; Hoshi, H. Palliative external-beam radiotherapy for bone metastases from hepatocellular carcinoma. *World J. Hepatol.* **2014**, *6*, 923–929. [[CrossRef](#)]
16. Tovoli, F.; De Lorenzo, S.; Samolsky Dekel, B.G.; Piscaglia, F.; Benevento, F.; Brandi, G.; Bolondi, L. Oral oxycodone/naloxone for pain control in cirrhosis: Observational study in patients with symptomatic metastatic hepatocellular carcinoma. *Liver Int.* **2018**, *38*, 278–284. [[CrossRef](#)]
17. He, J.; Shi, S.; Ye, L.; Ma, G.; Pan, X.; Huang, Y.; Zeng, Z.-C. A randomized trial of conventional fraction versus hypofraction radiotherapy for bone metastases from hepatocellular carcinoma. *J. Cancer* **2019**, *10*, 4031–4037. [[CrossRef](#)]

18. Seong, J.; Koom, W.S.; Park, H.C. Radiotherapy for painful bone metastases from hepatocellular carcinoma. *Liver Int. Off. J. Int. Assoc. Study Liver* **2005**, *25*, 261–265. [[CrossRef](#)]
19. He, J.; Zeng, Z.C.; Tang, Z.Y.; Fan, J.; Zhou, J.; Zeng, M.S.; Wang, J.-H.; Sun, J.; Chen, B.; Pan, B.-S. Clinical features and prognostic factors in patients with bone metastases from hepatocellular carcinoma receiving external beam radiotherapy. *Cancer* **2009**, *115*, 2710–2720. [[CrossRef](#)]
20. Guo, X.; Xu, Y.; Wang, X.; Lin, F.; Wu, H.; Duan, J.; Xiong, Y.; Han, X.; Baklaushev, V.; Xiong, S.; et al. Advanced Hepatocellular Carcinoma with Bone Metastases: Prevalence, Associated Factors, and Survival Estimation. *Med. Sci. Monit.* **2019**, *25*, 1105–1112. [[CrossRef](#)]
21. Van den Brande, R.; Cornips, E.M.; Peeters, M.; Ost, P.; Billiet, C.; Van de Kelft, E. Epidemiology of spinal metastases, metastatic epidural spinal cord compression and pathologic vertebral compression fractures in patients with solid tumors: A systematic review. *J. Bone Oncol.* **2022**, *35*, 100446. [[CrossRef](#)] [[PubMed](#)]
22. Dawson, L.A.; Winter, K.; Knox, J.; Zhu, A.X.; Krishnan, S.; Guha, C.; Kachnic, L.A.; Gillin, M.; Hong, T.S.; Craig, T.; et al. NRG/RTOG 1112: Randomized Phase III Study of Sorafenib vs. Stereotactic Body Radiation Therapy (SBRT) Followed by Sorafenib in Hepatocellular Carcinoma (HCC) (NCT01730937). *Int. J. Radiat. Oncol. Biol. Phys.* **2022**, *114*, 1057. [[CrossRef](#)]
23. Li, H.; Wu, Z.; Chen, J.; Su, K.; Guo, L.; Xu, K.; Gu, T.; Jiang, Y.; Wang, P.; Zeng, H.; et al. External radiotherapy combined with sorafenib has better efficacy in unresectable hepatocellular carcinoma: A systematic review and meta-analysis. *Clin. Exp. Med.* **2022**. Epub ahead of print. [[CrossRef](#)] [[PubMed](#)]
24. Llovet, J.M.; Ricci, S.; Mazzaferro, V.; Hilgard, P.; Gane, E.; Blanc, J.F.; de Oliveira, A.C.; Santoro, A.; Raoul, J.L.; Forner, A.; et al. Sorafenib in advanced hepatocellular carcinoma. *N. Engl. J. Med.* **2008**, *359*, 378–390. [[CrossRef](#)]
25. Tovoli, F.; Ielasi, L.; Casadei-Gardini, A.; Granito, A.; Foschi, F.G.; Rovesti, G.; Negrini, G.; Orsi, G.; Renzulli, M.; Piscaglia, F. Management of adverse events with tailored sorafenib dosing prolongs survival of hepatocellular carcinoma patients. *J. Hepatol.* **2019**, *71*, 1175–1183. [[CrossRef](#)]
26. Raoul, J.L.; Adhoute, X.; Penaranda, G.; Perrier, H.; Castellani, P.; Oules, V.; Bourlière, M. Sorafenib: Experience and Better Management of Side Effects Improve Overall Survival in Hepatocellular Carcinoma Patients: A Real-Life Retrospective Analysis. *Liver Cancer* **2019**, *8*, 457–467. [[CrossRef](#)]
27. Bruix, J.; Qin, S.; Merle, P.; Granito, A.; Huang, Y.H.; Bodoky, G.; Pracht, M.; Yokosuka, O.; Rosmorduc, O.; Breder, V.; et al. Regorafenib for patients with hepatocellular carcinoma who progressed on sorafenib treatment (RESORCE): A randomised, double-blind, placebo-controlled, phase 3 trial. *Lancet Lond. Engl.* **2017**, *389*, 56–66. [[CrossRef](#)]
28. Granito, A.; Forgione, A.; Marinelli, S.; Renzulli, M.; Ielasi, L.; Sansone, V.; Benevento, F.; Piscaglia, F.; Tovoli, F. Experience with regorafenib in the treatment of hepatocellular carcinoma. *Ther. Adv. Gastroenterol.* **2021**, *14*, 17562848211016960. [[CrossRef](#)]
29. Kudo, M.; Finn, R.S.; Qin, S.; Han, K.H.; Ikeda, K.; Piscaglia, F.; Baron, A.; Park, J.-W.; Han, G.; Jassem, J.; et al. Lenvatinib versus sorafenib in first-line treatment of patients with unresectable hepatocellular carcinoma: A randomised phase 3 non-inferiority trial. *Lancet* **2018**, *391*, 1163–1173. [[CrossRef](#)]
30. Ielasi, L.; Tovoli, F.; Piscaglia, F. Lenvatinib mesylate to treat hepatocellular carcinoma. *Drugs Today* **2019**, *55*, 305–313. [[CrossRef](#)]
31. Abou-Alfa, G.K.; Meyer, T.; Cheng, A.L.; El-Khoueiry, A.B.; Rimassa, L.; Ryoo, B.Y.; Cicin, I.; Merle, P.; Chen, Y.; Park, J.-W.; et al. Cabozantinib in Patients with Advanced and Progressing Hepatocellular Carcinoma. *N. Engl. J. Med.* **2018**, *379*, 54–63. [[CrossRef](#)]
32. Tovoli, F.; Dadduzio, V.; De Lorenzo, S.; Rimassa, L.; Masi, G.; Iavarone, M.; Marra, F.; Garajova, I.; Brizzi, M.P.; Daniele, B.; et al. Real-Life Clinical Data of Cabozantinib for Unresectable Hepatocellular Carcinoma. *Liver Cancer* **2021**, *10*, 370–379. [[CrossRef](#)]
33. Finn, R.S.; Qin, S.; Ikeda, M.; Galle, P.R.; Ducreux, M.; Kim, T.Y.; Kudo, M.; Breder, V.; Merle, P.; Kaseb, A.O.; et al. Atezolizumab plus Bevacizumab in Unresectable Hepatocellular Carcinoma. *N. Engl. J. Med.* **2020**, *382*, 1894–1905. [[CrossRef](#)] [[PubMed](#)]
34. Tovoli, F.; Pallotta, D.P.; Sansone, V.; Iavarone, M.; De Giorgio, M.; Ielasi, L.; Di Costanzo, G.G.; Giuffrida, P.; Sacco, R.; Pressiani, T.; et al. Outcomes of Sorafenib for Recurrent Hepatocellular Carcinoma After Liver Transplantation in the Era of Combined and Sequential Treatments. *Transplantation* **2023**, *107*, 156–161. [[CrossRef](#)]
35. Ielasi, L.; Sansone, V.; Granito, A.; Benevento, F.; De Lorenzo, S.; Tovoli, F. An update of treatments of hepatocellular carcinoma in patients refractory to sorafenib. *Drugs Today Barc. Spain 1998* **2018**, *54*, 615–627. [[CrossRef](#)]
36. Jose, A.; Bavetta, M.G.; Martinelli, E.; Bronte, F.; Giunta, E.F.; Manu, K.A. Hepatocellular Carcinoma: Current Therapeutic Algorithm for Localized and Advanced Disease. *J. Oncol.* **2022**, *2022*, 3817724. [[CrossRef](#)]
37. Xiang, L.; Gilkes, D.M. The Contribution of the Immune System in Bone Metastasis Pathogenesis. *Int. J. Mol. Sci.* **2019**, *20*, 999. [[CrossRef](#)]
38. Wang, K.; Gu, Y.; Liao, Y.; Bang, S.; Donnelly, C.R.; Chen, O.; Tao, X.; Mirando, A.J.; Hilton, M.J.; Ji, R.R. PD-1 blockade inhibits osteoclast formation and murine bone cancer pain. *J. Clin. Investig.* **2020**, *130*, 3603–3620. [[CrossRef](#)]

Disclaimer/Publisher’s Note: The statements, opinions and data contained in all publications are solely those of the individual author(s) and contributor(s) and not of MDPI and/or the editor(s). MDPI and/or the editor(s) disclaim responsibility for any injury to people or property resulting from any ideas, methods, instructions or products referred to in the content.