

## HOW I DO IT

# Post-Covid-19 Airway Stenosis: Tracheal Resection-Anastomosis Using The Tritube<sup>®</sup> Ventilation

Gabriele Molteni, MD, PhD, FEBORL-HNS<sup>®</sup>; Virginia Dallari, MD<sup>®</sup>; Erika Segato, MD<sup>®</sup>;  
 Francesco Mattioli, MD, PhD

**Key Words:** airway stenosis, covid-19, tracheal resection, tracheal anastomosis, Tritube<sup>®</sup> ventilation.

*Laryngoscope*, 00:1–4, 2023

## INTRODUCTION

As reported in the literature, up to 12% of all COVID-19 patients may need intensive care unit admission for severe interstitial pneumonia, with possible long-term endotracheal intubation for mechanical ventilation and subsequent tracheostomy.<sup>1</sup> As is now known, prolonged endotracheal intubation can lead to mucosal injury and inflammation, granulation tissue formation, perichondritis, and subsequent stenotic scar tissue development. Moreover, tracheostomy may add trauma to the already damaged tracheal lumen, for example: tracheal ring fracture, collapse, necrosis, malacia, and superinfection.<sup>2</sup>

In this setting, laryngotracheal stenosis represents one of the most common complications of invasive ventilation and tracheostomy. In addition, the absence of accurate monitoring of the cuff pressure or the need to maintain it above 50 mmHg for clinical reasons and prone position ventilation might contribute to the mechanism underlying the stenosis.<sup>2,3</sup>

As predicted by the European Laryngological Society (ELS), the incidence of laryngotracheal stenosis in post-COVID-19 patients may increase and should not be underestimated.<sup>1,2</sup> After intensive care unit discharge, patients with breathing difficulties must receive a targeted evaluation aimed at ruling out the possibility of

iatrogenic laryngotracheal stenosis, because a respiratory distress syndrome might be misdiagnosed in these cases.<sup>2</sup>

Regarding the treatment, Piazza et al state that tracheal resection and anastomosis represent an effective treatment in post-COVID-19 laryngotracheal stenosis patients.<sup>2</sup> Indeed, this strategy is common in the setting of previous prolonged intubation or tracheostomy, since external or internal trauma to the airway is associated with cartilage injury and the potential loss of structural support.<sup>3</sup>

The purpose of the present paper is, therefore, to show step by step the tracheal resection anastomosis type A1, according to the University of Brescia classification,<sup>2</sup> in a post-COVID-19 patient. In addition, on the day of the surgery, the airway was managed with a new device, the Tritube<sup>®</sup> (Ventinova Medical B.V., Eindhoven, The Netherlands) with an outer diameter of only 4.4 mm.

## METHODS

We report the clinical case of a 62-year-old patient who presents to our attention for significant exertional dyspnea, cough, and sometimes dyspnea at rest.

The patient had been intubated for 21 days for severe COVID-19 interstitial pneumonia. Then, he had undergone a percutaneous tracheotomy for difficult weaning from ventilation in January 2021. The patient recovered in February 2021 with removal of the endotracheal cannula. The patient otherwise had no major comorbidities.

Three months after discharge and removal of the cannula, the patient began to complain of dyspnoea on exertion and occasionally at rest. He, therefore, came to our attention about a year later. On fibroscopy, normal vocal cord motility was visualized, but a grade II tracheal subglottic stenosis (50%–71%), according to the Myer-Cotton airway grading system, at the site of a previous tracheotomy (Fig. 1). The patient undergoes a Computed tomography (CT) neck scan, which shows a narrowing of the airway between the third and fourth tracheal rings (Fig. 2).

Results from the literature state that, when feasible, tracheal resection and reconstruction is the treatment of choice in cases of benign tracheal strictures.<sup>3,4</sup> Therefore, considering the scarring and inveterate nature of the stenosis, our patient was a candidate for tracheal resection-anastomosis surgery. Airway management in

This is an open access article under the terms of the [Creative Commons Attribution-NonCommercial License](#), which permits use, distribution and reproduction in any medium, provided the original work is properly cited and is not used for commercial purposes.

From the Unit of Otorhinolaryngology, Head & Neck Department (G.M., V.D., E.S.), University of Verona, Verona, Italy; Otorhinolaryngology Head and Neck Surgery Department (F.M.), University Hospital of Modena, Modena, Italy.

Editor's Note: This Manuscript was accepted for publication on June 14, 2023.

The authors have no funding, financial relationships, or conflicts of interest to disclose.

Send correspondence to Erika Segato, Unit of Otorhinolaryngology, Head & Neck Department, University of Verona, Piazzale L.A. Scuro 10, 37134, Verona, Italy. Email: [erikasegato@hotmail.it](mailto:erikasegato@hotmail.it)

DOI: 10.1002/lary.30859

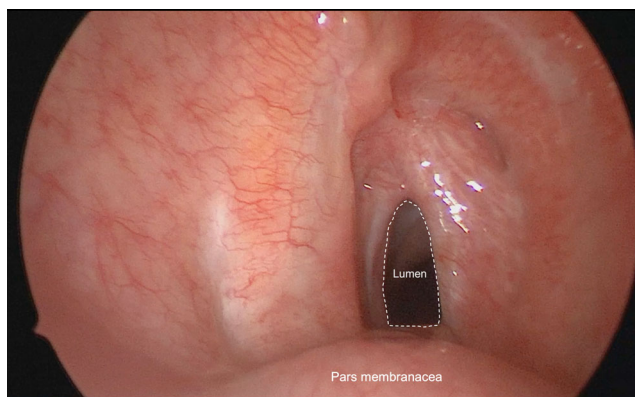


Fig. 1. Preoperative endoscopic view, tracheal stenosis grade II (Myers-Cotton). [Color figure can be viewed in the online issue, which is available at [www.laryngoscope.com](http://www.laryngoscope.com).]

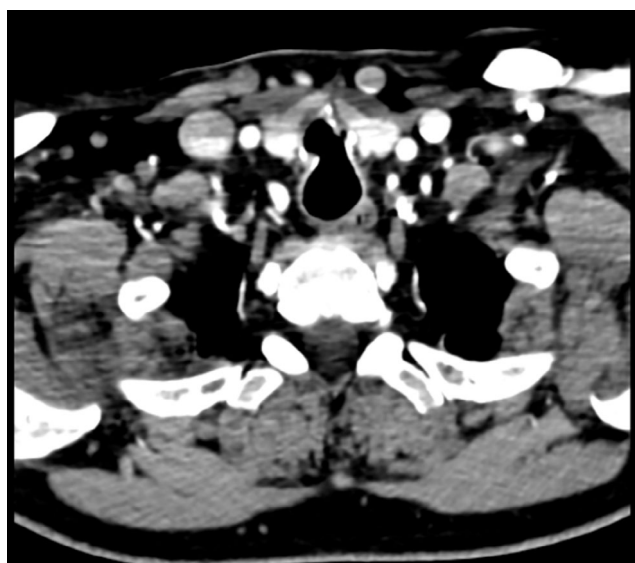


Fig. 2. Preoperative computed tomography (CT) scan showing airways narrowing.

such cases presents a particular challenge to anesthesiologists, so we elected to use the Tritube tracheal tube.<sup>5</sup>

## RESULTS

Intubation of the patient's trachea is performed using a new airway device, the Tritube<sup>®</sup> (Ventinova Medical B.V., Eindhoven, The Netherlands) with an outer diameter of only 4.4 mm. Because of this small lumen, ventilation is achieved using flow-controlled ventilation with the Evone<sup>®</sup> system.<sup>5</sup> The tube has centimeter markings and a malleable stylet loaded in the ventilation lumen. After the insertion of the Tritube<sup>®</sup>, the stylet is removed.

## SURGICAL TECHNIQUE

Awake optical fiber nasotracheal intubation is conducted after local anesthesia of nose, larynx, and trachea.

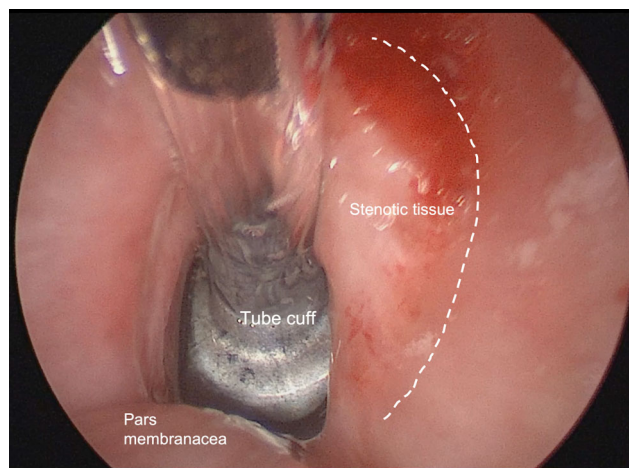


Fig. 3. The Tritube<sup>®</sup> is positioned, tube cuff is placed under the stenotic segment. [Color figure can be viewed in the online issue, which is available at [www.laryngoscope.com](http://www.laryngoscope.com).]

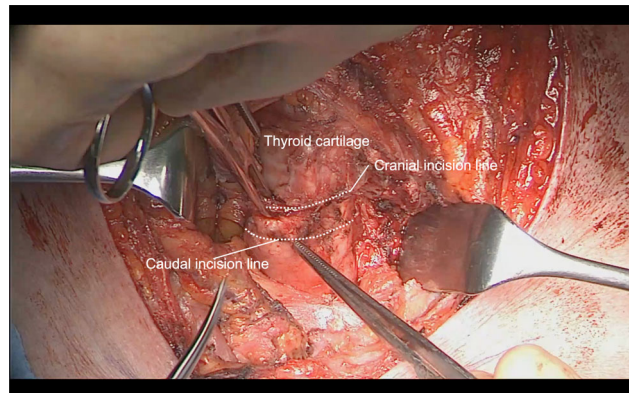


Fig. 4. Identification of cranial and caudal lines of incision on tracheal surface. [Color figure can be viewed in the online issue, which is available at [www.laryngoscope.com](http://www.laryngoscope.com).]

First, a guide wire is positioned in the airways then the Tritube<sup>®</sup> is railroaded in the trachea (Fig. 3).

The patient is placed in a supine position and the neck is hyperextended to facilitate the exit of the trachea from the thoracic inlet.

### STEP 1

A cervical collar incision is performed over the previous tracheostomy scar.

### STEP 2

Superior and inferior myocutaneous flaps are elevated, and the cervical fascia and prelaryngeal muscles are exposed.

### STEP 3

Prelaryngeal muscles and thyroid gland are dissected with subsequent identification of pretracheal fascia and tracheal release for optimal mobilization.

### STEP 4

The length of the stenotic tract is measured; cranial and caudal incisions are made obtaining a beveled shape of the two segments. (Fig. 4).

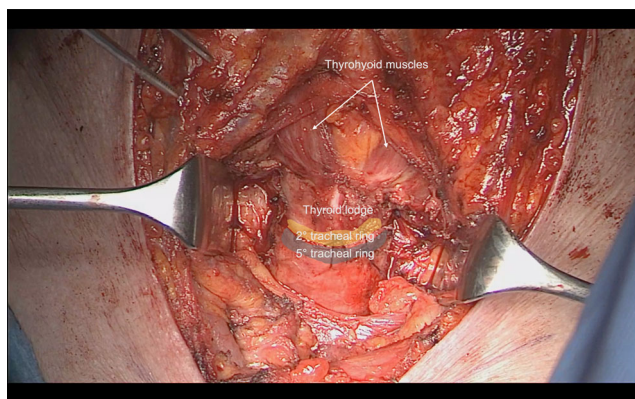


Fig. 5. Anastomosis site after resection. [Color figure can be viewed in the online issue, which is available at [www.laryngoscope.com](http://www.laryngoscope.com).]

### STEP 5

End-to-end anastomosis with submucosal absorbable sutures 2-0 is performed. At the end of the surgery, the anastomosis is tested for air leaks. (Fig. 5).

### STEP 6

A collagen-coated sponge is placed on the suture. Layered closure of neck muscles and fascia is performed. A drainage tube is positioned before closure.

Before the suture, the head is mildly flexed to reduce anastomotic tension. It remains fixed with two

strong chin-chest stitches in this position for 5 days postoperatively.

The patient was gradually woken up after the surgery in the intensive care unit, then transferred to the ENT ward. Post-op care involves bed rest with flexed head as abovementioned, use of PPIs, laxatives, and cough sedatives. The patient was fed via nasogastric tube for the first three post-operative days and then gradually resumed oral feeding. CT scan was conducted at 3 and 7 days post-op, to verify that there were no gas traces or blood collections in the peritracheal tissues. The patient was discharged after 10 days with no complications. The CT scan at 45 days after surgery showed an improvement in the narrowing of the airways (Fig. 6).

Nasogastric tube positioning for 5 days.

### DISCUSSION

Laryngotracheal stenosis complicates tracheal intubation or tracheostomy in 0.6% to 65% of cases. Tracheal strictures after tracheostomy may develop at the site of tracheal incision, located in the upper third of the trachea, or at the cuff site, located in the middle or lower third of the trachea.<sup>4</sup> Exertional dyspnea, cough, and the inability to clear secretions are the most frequently reported symptoms. In this case, surgical resection currently is the curative treatment of choice.<sup>3</sup>

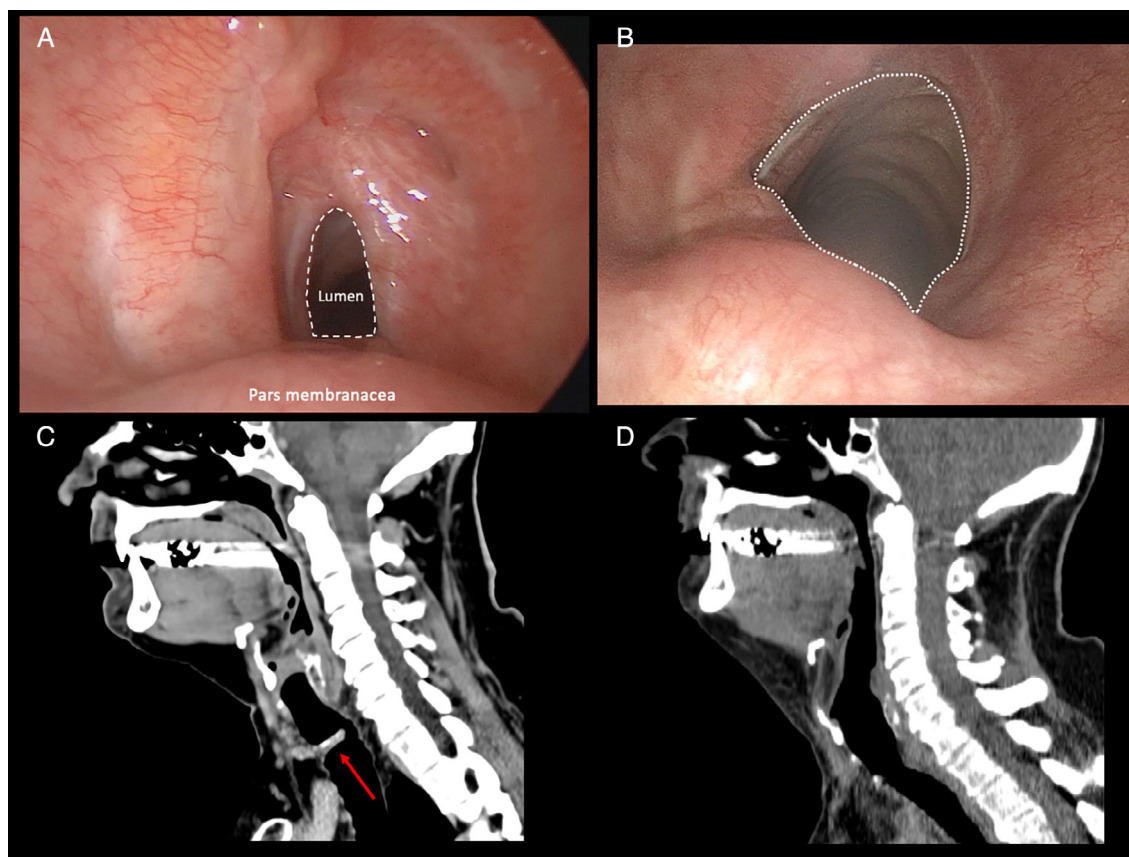
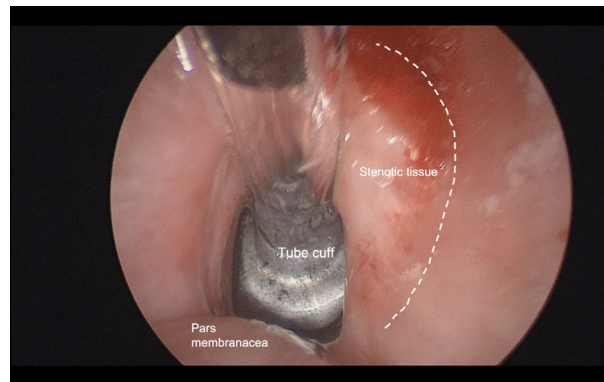


Fig. 6. Comparison between pre- and postoperative endoscopic (A, B) and radiological view (C, D). [Color figure can be viewed in the online issue, which is available at [www.laryngoscope.com](http://www.laryngoscope.com).]

In the literature, two major types of tracheal stenosis are described: the structural and the dynamic ones. Structural stenosis is those in which shrinking and scarring are predominant. Dynamic stenoses are malacic conditions that vary with respiration. Moreover, Plojoux et al describe the dynamic A-shape tracheal stenosis, as a particular type of structural or complex tracheal stenosis that consists of dynamic stenosis due to anterior fracture of one cartilage ring often associated with posteriorly localized malacia.<sup>4</sup>

The case described falls under the latter definition: it was in fact a complex 'A-shaped' stenosis, with cartilage ring fracture, in the aftermath of percutaneous tracheotomy. Endoscopic treatment of tracheal stenosis such as laser radial incisions or balloon dilatation is mainly considered for purely intrinsic, short (around 1 cm), low-grade stenosis, limited to just one subsite of the airway.<sup>1</sup> A-shaped strictures are best approached with surgical treatment with resection and end-to-end anastomosis since there is no shrinking or scarring of trachea.<sup>4</sup> In these cases, endoscopic removal of granulation tissue, dilatations by balloon or rigid bronchoscopic instrumentation, and steroid injection may be proposed as temporary relief from dyspnea.<sup>1</sup> As also reported by Piazza et al, complex and high-grade laryngotracheal stenosis benefit from open-neck surgical techniques.<sup>1</sup> Therefore, considering the scarring and complex nature of our patient's tracheal stenosis, we opted for a tracheal resection-anastomosis operation.

In patients with airway narrowing due to laryngeal or tracheal stenosis, cancer, infection, allergic reactions, and so forth, the introduction of a standard tracheal tube may not be possible. In these cases, jet ventilation, tracheostomy, or even extra-corporeal-membrane oxygenation should be used. However all these solutions present difficulties and side effects. During jet ventilation, the airway needs to be patent to allow for passive expiration and hyperinflation is a well-known risk of this ventilation method. Also, there is no cuff to protect against aspiration.<sup>5</sup> A smaller-diameter tube facilitates tracheal intubation, particularly in patients with severe stenosis of the airways. Moreover, the use of the Tritube<sup>®</sup> device also improves the surgical access during the tracheal procedure, allowing more surgical space. As reported by Kristensen et al, the Tritube<sup>®</sup> device is not without possible complications and drawbacks. First of all, it is necessary to focus on the intratracheal pressure readings on the manometer, because any distraction during ventilation can lead to undesirably high or low intratracheal pressures. Furthermore, insufflated air is not humidified and secretions could obstruct the small lumen. However high flow during insufflation may help to constantly clear the small tube.<sup>5</sup> Also, the volatile anesthetic cannot be used.<sup>5</sup> Lastly, due to its high resistance to flow, spontaneous



Video 1. Post-Covid-19 airway stenosis: tracheal resection-anastomosis using the Tritube<sup>®</sup> ventilation.

Video content can be viewed at <https://onlinelibrary.wiley.com/doi/10.1002/ary.30859>

ventilation through the Tritube<sup>®</sup> is not possible and even assisting spontaneous ventilation through Tritube<sup>®</sup> is hardly possible. Thus, when the patient is emerging from anesthesia, the cuff should be deflated to allow for spontaneous ventilation alongside the tube.<sup>5</sup>

In conclusion, with this procedure, we were able to obtain an improvement in the caliber of the patient's airways and his symptoms with no complications. The use of the Tritube<sup>®</sup> device ensured an optimal visualization of the surgical field maintaining smooth ventilation with stable lung and gas parameters. We aim to raise awareness about post-COVID-19 laryngotracheal stenosis by sharing the diagnostic workup and successful management. To the best of our knowledge, this is the first video that clearly explains this peculiar procedure, using Tritube<sup>®</sup> ventilation.

## BIBLIOGRAPHY

1. Piazza C, Filauro M, Dikkers FG, et al. Long-term intubation and high rate of tracheostomy in COVID-19 patients might determine an unprecedented increase of airway stenoses: a call to action from the European Laryngological Society. *Eur Arch Otorhinolaryngol*. 2021;278(1):1-7. <https://doi.org/10.1007/s00405-020-06112-6>.
2. Piazza C, Lancini D, Filauro M, et al. Post-COVID-19 airway stenosis treated by tracheal resection and anastomosis: a bicentric experience. *Acta Otorhinolaryngol Ital*. 2022;42(2):99-105. <https://doi.org/10.14639/0392-100X-N1952>.
3. Siciliani A, Rendina EA, Ibrahim M. State of the art in tracheal surgery: a brief literature review. *Multidiscip. Respir Med*. 2018;13:34. <https://doi.org/10.1186/s40248-018-0147-2>.
4. Plojoux J, Laroumagne S, Vandemoortele T, Astoul PJ, Thomas PA, Dutau H. Management of benign dynamic "A-shape" tracheal stenosis: a retrospective study of 60 patients. *Ann Thorac Surg*. 2015;99(2):447-453. <https://doi.org/10.1016/j.athoracsur.2014.08.037>.
5. Kristensen MS, de Wolf MWP, Rasmussen LS. Ventilation via the 2.4 mm internal diameter Tritube<sup>®</sup> with cuff—new possibilities in airway management. *Acta Anaesthesiol Scand*. 2017;61(6):580-589. <https://doi.org/10.1111/aas.12894>.