



Contents lists available at ScienceDirect

## International Journal of Surgery Case Reports

journal homepage: [www.casereports.com](http://www.casereports.com)

## A case report of a rare, spontaneous external jugular vein aneurysm

David Ryan Chapman<sup>a</sup>, Raymond Elliot Ho<sup>a</sup>, Antonio Gangemi<sup>b,\*</sup><sup>a</sup> Ross University School of Medicine, Department of Surgery, Saint Anthony Hospital, 2875 W 19th St., Chicago, IL 60623, USA<sup>b</sup> Department of Surgery – Division of General, Minimally Invasive & Robotic Surgery, University of Illinois at Chicago, 840 S. Wood Street, Suite 435E (M/C958), Chicago, IL 60612, USA

## ARTICLE INFO

## Article history:

Received 7 June 2018

Received in revised form 28 August 2018

Accepted 5 September 2018

Available online 14 September 2018

## Keywords:

Case report

Venous aneurysm

External jugular vein

## ABSTRACT

**INTRODUCTION:** Compared to arterial aneurysms, venous pseudoaneurysms are rare and even more rare are external jugular vein aneurysms (EJV). To our knowledge, there are less than 10 well-documented cases of EJV aneurysms accessible.

**PRESENTATION OF CASE:** Our patient is a 75 year old hispanic female who noticed a painless right neck mass two months prior. Ultrasound confirmed a cystic mass of unknown etiology containing doppler flow. Excisional biopsy revealed an EJV aneurysm with pathologic results of: blood, calcified debris, and a vessel wall consistent with EJV pseudoaneurysm.

**DISCUSSION:** EJV aneurysms are clinically rare compared to IJV aneurysms. Recent trauma, cardiovascular disease and age are reported to be the highest significant clinical risk factors in the formation of jugular vein aneurysm (JVA). The absence of trauma in our patient is noteworthy because it eliminates a direct contributor to a normally low-pressure vessel.

**CONCLUSIONS:** Despite their rarity, spontaneous EJV aneurysms should be included in the differential of the elderly hypertensive patient who is presenting with a painless mass of the lateral neck that has cystic appearance and ultrasound findings of doppler flow.

© 2018 The Authors. Published by Elsevier Ltd on behalf of IJS Publishing Group Ltd. This is an open access article under the CC BY-NC-ND license (<http://creativecommons.org/licenses/by-nc-nd/4.0/>).

## 1. Introduction

Compared to arterial aneurysms, venous pseudoaneurysms are rare [1]. So rare, in fact, that Calligaro et al. only reported 4 cases over the span of 20 years at one institution, with just one 1 being an EJV aneurysm [2]. The most common site of aneurysm in the neck is the internal jugular vein (IJV) [3]. Differentials to consider with a lateral neck mass involves a number of etiologies, including tumors and cysts of the superior mediastinum, external laryngeal diverticula, lung cupola inflation and jugular vein aneurysm [4,5]. In comparison to high-pressure arterial systems, the low pressure venous is biomechanically less conducive to aneurysm formation, especially in the absence of trauma or significant cardiovascular disease. Herein, we report a very rare case of spontaneous EJV aneurysm not related to trauma or prior manipulation of the EJV.

This report has been conducted in line with SCARE criteria [6].

## 2. Case report

Patient is a 75 year-old Hispanic female with a significant past medical history of controlled hypertension who noticed a right neck mass two months prior and stated it had not grown since then.

The mass was described as painless which swelled with coughing. The patient denied any trauma, fever, weight loss or night sweats. The physical exam showed a “ping pong ball sized mass” that was mobile, soft, non-tender, non-erythematous, non-pulsatile, and did not move on swallowing (Fig. 1). Ultrasound reported a cystic mass over the right neck of unknown etiology (Fig. 2). Intraoperatively, the lesion appeared to originate from the right EJV. Careful diagnostic excision was then performed (Fig. 3). Final pathology tests revealed “Portion of cystic lesion containing blood and calcific debris with the wall suggestive of a vein.” “The lesion may represent an aneurysm including pseudoaneurysm”.

## 3. Discussion

Anatomically, the EJV is formed by the posterior auricular vein and retromandibular vein. It crosses under the sternocleidomastoid to eventually join the subclavian vein. Clinically, the external jugular vein’s superficial anatomic location predisposes it to iatrogenic traumatic injury after use by central venous catheters. This is a major example of trauma to this low-pressure system leading to formation of EJV aneurysm. Ultrasound is a useful first imaging tool to differentiate this kind of neck mass from the more common possibilities of lymph node enlargement, abscess, cystic hygroma, cavernous hemangioma, laryngocele, and carotid artery aneurysm, and IJV aneurysm [5]. CT angiogram and MR angiography do represent second line investigations that may further and more accurately help to achieve the final diagnosis.

\* Corresponding author.

E-mail address: [agangemi@UIC.edu](mailto:agangemi@UIC.edu) (A. Gangemi).

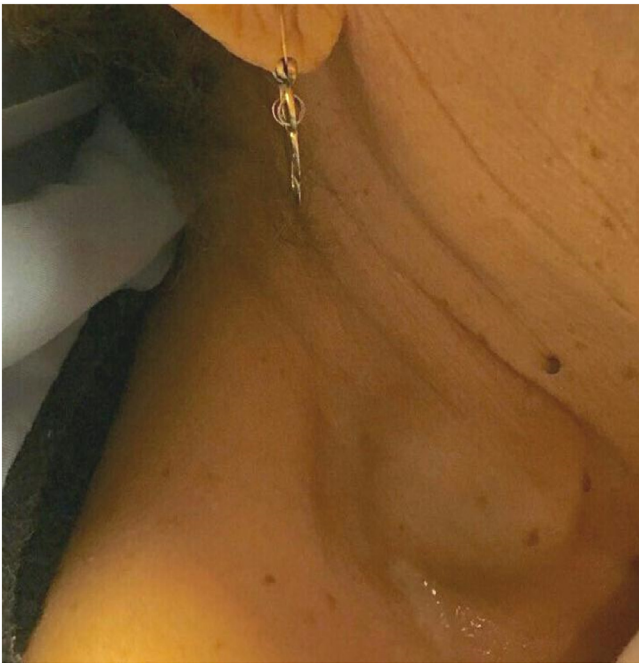


Fig. 1. Pre-operative image of right neck mass.

Additionally, venous aneurysm can be congenital or acquired. Acquired causes include inflammation, trauma, venous valve insufficiency, tumors or arteriovenous fistula secondary to trauma.

EJV aneurysms are clinically rare compared to IJV aneurysms. Recent trauma, cardiovascular disease and age are reported to be the highest significant clinical risk factors in the formation of JVA [4]. The absence of trauma in our patient is noteworthy because it eliminates a direct contributor to a normally low-pressure vessel. It is also unclear as to whether the patient's recently diagnosed hypertension may have played a role in the etiology of this exceptionally rare condition.

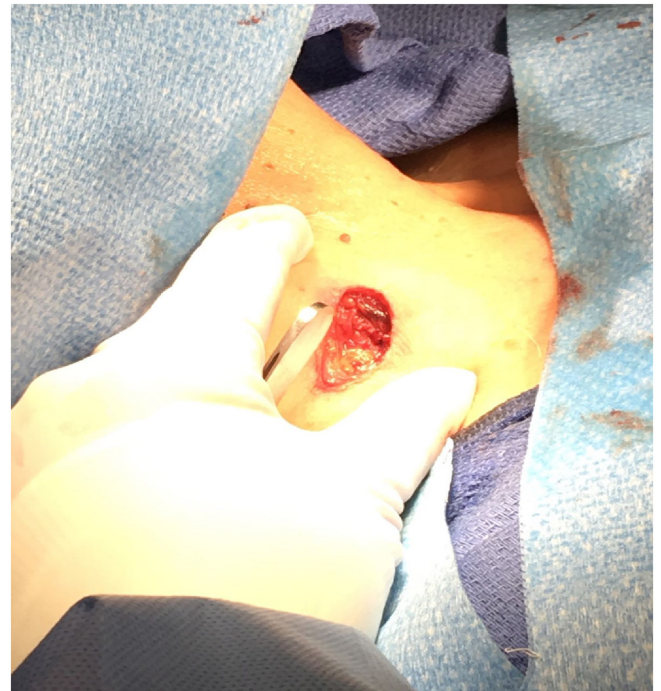

Fig. 3. Intra-operative image showing external jugular vein after resection of the aneurism.

Mohanty et al. noted that in elderly hypertensive patients the compression of the left innominate vein by a high atherosclerotic aorta could contribute to the formation of fusiform dilation of the involved vessel and/or its tributaries [7,8]. While our elderly patient failed to report a history of trauma, she did have hypertension and therefore potentially atherosclerosis. Additionally her pseudoaneurysm was located on the right side of her neck. There are several variations of branch points for the internal carotids and subclavian arteries from the aorta. It is possible that an anatom-

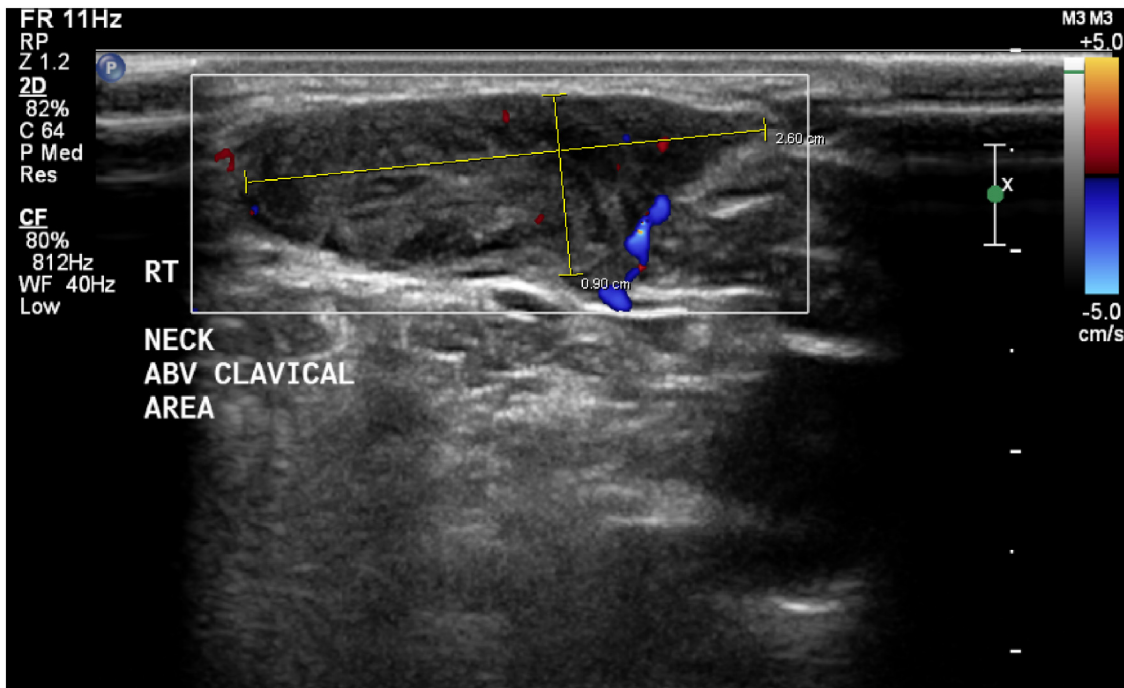


Fig. 2. Pre-operative ultrasound imaging showing "cystic mass of the right neck".

ical variant exposed the EJV to a portion of hypertensive artery that could have contributed to the etiology of the EJV aneurysm. A pre-operative CT or MRI angiogram could have confirmed this hypothesis. These second-line diagnostic modalities are very accurate in diagnosing aneurysms, including JVA, but are also associated with high costs, radiation exposure (CT angiogram) and use of contrast agents that may lead to allergic reactions or adverse renal conditions.

Furthermore, the patient complained of discomfort and concerns related to the presence of her neck mass and requested to have an excisional biopsy to achieve, at once, the definitive diagnosis and treatment of the condition. Therefore, the second line diagnostic work up would not have changed our surgical management. Hence, the etiology of our EJV aneurysm case remains idiopathic.

Our case report suggests that, despite their exceptional rarity, spontaneous EJV aneurysms should be included in the differential of the elderly hypertensive patient who is presenting with a painless, cystic mass of the lateral neck that has ultrasound findings of doppler flow.

### Conflicts of interest

The authors declare no conflicts of interest pertinent to this case report.

### Funding source

No source of funding to be declared.

### Ethical approval

No Institutional Review Board is required for publication of a case report at our institution.

### Consent

Written informed consent was obtained from the patient for publication of this case report and accompanying images. A copy of the written consent is available for review by the Editor-in-Chief of this journal on request.

### Author contribution

Study Concept and Design: Antonio Gangemi, David Ryan Chapman, Raymond Elliot Ho.

Data Collection: David Ryan Chapman, Raymond Elliot Ho, Antonio Gangemi.

Writing of Paper: David Ryan Chapman, Raymond Elliot Ho, Antonio Gangemi.

### Registration of research studies

None.

### Guarantor

Antonio Gangemi.

### Provenance and peer review

Not commissioned, externally peer-reviewed.

### References

- [1] S. Karapolat, B. Ekut, Y. Unlu, Multiple aneurysms of the left external jugular vein, *Turk. J. Med. Sci.* 35 (2005) 43–45.
- [2] K.D. Calligaro, S. Ahmad, R. Dandora, M.J. Dougherty, R.P. Savarese, K.J. Doerr, S. McAfee, D.A. DeLaurentis, *Surgery* 117 (January (1)) (1995) 1–6, Review. [PubMed: 7809821].
- [3] R.A. McCready, M.A. Bryant, L. Divelbiss, B.A. Chess, Subclavian venous aneurysm: case report and review of the literature, *J. Vasc. Surg.* 45 (5) (2007) 1080–1082.
- [4] Y. Zohar, R. Ben-Tovim, P. Talmi, Phlebectasia of the jugular system, *J. Craniomaxillofac. Surg.* 17 (1989) 8–9 [PubMed: 2646326].
- [5] N.M. Shah, V.S. Shah, P.R. Dalal, P. Mishra, A pseudoaneurysm of the external jugular vein- a case report, *Gujarat Med. J.* (July) (2015) 52–54.
- [6] R.A. Agha, A.J. Fowler, A. Saetta, I. Barai, S. Rajmohan, D.P. Orgill, for the SCARE Group, The SCARE statement: consensus-based surgical case report guidelines, *Int. J. Surg.* 34 (October) (2016) 180–186, <http://dx.doi.org/10.1016/j.ijssu.2016.08.014>, Epub 2016 Sep 7.
- [7] D. Mohanty, B.K. Jain, P.K. Garg, A. Tandon, External jugular venous aneurysm: a clinical curiosity, *J. Nat. Sci. Biol. Med.* 4 (January–June (1)) (2013) 223–225 [PubMed: 3633282].
- [8] F.A. Nwako, N.E. Agugua, C.A. Udeh, R.I. Osuorji, Jugular phlebectasia, *J. Pediatr. Surg.* 24 (1989) 303–305 [PubMed: 2709297].

### Open Access

This article is published Open Access at [sciencedirect.com](https://www.sciencedirect.com). It is distributed under the [IJSCR Supplemental terms and conditions](#), which permits unrestricted non commercial use, distribution, and reproduction in any medium, provided the original authors and source are credited.