



ALMA MATER STUDIORUM
UNIVERSITÀ DI BOLOGNA

ARCHIVIO ISTITUZIONALE DELLA RICERCA

Alma Mater Studiorum Università di Bologna Archivio istituzionale della ricerca

Evaluation of testicular echotexture with Ecotext as a diagnostic method of testicular dysfunction in stallions

This is the final peer-reviewed author's accepted manuscript (postprint) of the following publication:

Published Version:

Availability:

This version is available at: <https://hdl.handle.net/11585/927366> since: 2023-06-09

Published:

DOI: <http://doi.org/10.1016/j.theriogenology.2022.03.004>

Terms of use:

Some rights reserved. The terms and conditions for the reuse of this version of the manuscript are specified in the publishing policy. For all terms of use and more information see the publisher's website.

This item was downloaded from IRIS Università di Bologna (<https://cris.unibo.it/>).
When citing, please refer to the published version.

(Article begins on next page)

This is the final peer-reviewed accepted manuscript of:

Da Silva-Álvarez E, Gaitskell-Phillips G, Ortiz-Rodríguez JM, Serres C, García-Rodríguez B, Gutiérrez-Cepeda L, Martín-Cano FE, Echegaray A, Escartin-Casas N, Requena F, Gil MC, Peña FJ, Ortega-Ferrusola C. Evaluation of testicular echotexture with Ecotext as a diagnostic method of testicular dysfunction in stallions. *Theriogenology*. 2022 Jun;185:50-60. doi: 10.1016/j.theriogenology.2022.03.004. Epub 2022 Mar 16. PMID: 35378327.

The final published version is available online at:

<https://doi.org/10.1016/j.theriogenology.2022.03.004>

Terms of use:

Some rights reserved. The terms and conditions for the reuse of this version of the manuscript are specified in the publishing policy. For all terms of use and more information see the publisher's website.

This item was downloaded from IRIS Università di Bologna (<https://cris.unibo.it/>)

When citing, please refer to the published version.

Evaluation of testicular echotexture with Ecotext as a diagnostic method of testicular dysfunction in stallions

Da Silva-Álvarez E¹, Ortiz-Rodríguez JM¹, Gaitskell-Phillips G¹, Serres C², García-Rodríguez B³, Gutiérrez-Cepeda, L², Martín- Cano FE¹, Echegaray A⁴, Escartin-Casas N⁴, Requena F⁵, Gil MC¹, Peña FJ¹, Ortega-Ferrusola C^e

Laboratory of Equine Reproduction and Equine Spermatology, Veterinary Teaching Hospital, University of Extremadura, Cáceres, Spain¹, Department of Animal Medicine and Surgery, Faculty of Veterinary Science, University Complutense of Madrid, Madrid, Spain², Cyneological Service of the Civil Guard, Valdemoro, Madrid, Spain³, Humeco, Huesca, Spain⁴, Department of Cell Biology, Physiology and Immunology, University of Cordoba, Cordoba, Spain.⁵

Correspondence should be addressed to C Ortega Ferrusola; email: cristinaof@unex.es

Veterinary Teaching Hospital, University of Extremadura, Avda. de la Universidad s/n, 10003 Cáceres, Spain

Short title:

Evaluation of testicular echotexture in fertile and subfertile stallions

ABSTRACT

This study aimed to assess if Ecotext, a new software for evaluation of testicular echotexture, is a good method for diagnosis of stallions with testicular dysfunction (TD). Relationships between Ecotext parameters and sperm motility and production, testicular volume, and testicular blood flow were also studied. Ecotext provides a total of six echotexture parameters: Ecotext 1 (black pixels), 2 (white pixels) and 3 (grey pixels), and another 3 parameters related to hypoechogenic areas: Ecotext tubular density (ETD), Ecotext tubular diameter (ETd), and Ecotext tubular area (ETA). Stallions (n=33) were assessed using proven diagnostic techniques (spermiogram, B-mode and Pulse Doppler ultrasound), and subsequent analysis with Ecotext. Animals were classified as “control stallions” (n:21, acceptable semen quality), and “stallions with TD” (n:12, poor semen quality (TM < 60%, PM < 45% and total n° of sperm with PM < 2000 x 10⁶ spz), that were subdivided into “induced TD group” (immunized, anti-GnRH vaccine) and “acquired TD group”. The acquired TD group showed differences in all Ecotext parameters in relation to controls (Ecotext 1:0.11±0.17 vs 2.82±2.52,

Ecotext 2:1584.0±575.8 vs 388±368.2, Ecotext 3:134.2±9.26; ETA: 2.14±0.59 vs 5.40±1.90; ETd: 65.66±6.27 vs 86.93±10.65 and ETD: 92.35±11.24 vs 132.10±16.35, $p \leq 0.001$). Results suggest acquired TD stallions were suffering testicular degeneration with loss of architecture and function as all Ecotext parameters were altered in relation to controls. Induced TD horses only showed a reduction in ETD (116.2±8.59 vs 132.10±16.35, $p \leq 0.001$), despite all sperm parameters being worse. These findings suggested immunized stallions probably only experience an acute loss of testicular functionality and parenchyma architecture is likely not affected since differences in Ecotext parameters with control stallions were not detected. ETD was the best parameter to identify animals with TD (AUC: 0.84, optimal cut-off value of 124.3 seminiferous tubules/cm²). Correlations were found between ETD and Doppler indices (PI: 0.60; RI: 0.47 $p \leq 0.001$), total testicular volume (r: 0.48; $p \leq 0.05$) and sperm motility (TM:0.51; and PM:0.54; $p \leq 0.001$) and production (r:0.51; $p \leq 0.001$). In summary, Ecotext could identify changes in testicular echotexture of stallions with TD. Results open the possibility for new research focused on establishing the relationship between Ecotext parameters and histomorphometry features in stallion testes.

Keywords: equine, ultrasonography, testis, testicular blood flow, subfertility, testicular parenchyma, spermatozoa, computer-assisted pixel analysis

1. Introduction

Testicular dysfunction (TD) is a difficult condition to diagnose in equines, especially in its initial stages [1]. Unilateral TD could result following conditions such as inguinal hernia or testicular torsion [2]. However, bilateral TD is more common in geriatric stallions (> 18 years old) as a result of aging. In adult or young stallions, it has been diagnosed as an acute transient problem after an episode of hyperthermia or immunization with anti-GnRH vaccines, which temporally suppress testicular function[3,4]. Depending on the cause and degree of testicular damage, testicular function may improve, return to normal over a period of months or end in irreversible testicular degeneration. Thus, monitoring with non-invasive techniques in valuable stallions would allow diagnosis and identification of early changes and timely administration of treatment [5].

Testicular degeneration is an acquired atrophy of the seminiferous tubules, resulting in a reduction of testicular size and a decrease in sperm quality and sperm production [2]. However, even though clinical signs could be evident, histological analysis is necessary to confirm the presence of this pathology [1]. Stallions with advanced stages of this condition usually have testicles with a palpable

soft texture, but in earlier stages stallions may present testes of normal size and consistency [1]. To date, testicular biopsy is the only accurate technique to confirm the diagnosis of this pathology. Despite recent studies having shown that repeated testicular biopsy does not result in detrimental effects on prospective fertility [6,7], this invasive technique is not widely used among equine practitioners.

Traditionally, the breeding soundness evaluation of a stallion with reduced fertility included a basic spermogram and the ultrasonographic examination of the reproductive tract[8–10]. The most common parameters used in the diagnosis of testicular dysfunction are sperm quality and production parameters, the measurement of total testicular volume (TTV), DSOe (expected Daily Sperm Output) parameters and calculation of spermatogenic efficiency (DSO per milliliter of testis) [1,13]. Testicular inefficiency might be suspected if total sperm numbers and semen quality is declining progressively over time, or if a stallion is producing low numbers of sperm relative to testicular volume and DSO (Daily Sperm Output)[5,12]. Several semen collections (7-10 semen extractions or 2-3 ejaculations per day for 3-5 days) over consecutive days are required to calculate the DSO of each stallion. However, these parameters require frequent measurement of the testis and semen analysis at the same time of the year (seasonal variations) to identify subtle changes indicative of testicular dysfunction. This practice is difficult to carry out at most stud farms, so a decrease in these indicators is usually detected in the later stages. Measurement of plasma hormone levels is also performed in cases of severe testicular dysfunction. These stallions typically present high levels of FSH and LH, as well as low plasma estradiol[13]. Nonetheless, hormonal levels in plasma may not be a good predictor of mild to moderate TD[9].

The introduction of ultrasound examination into the breeding soundness evaluation has improved the diagnosis of fertility problems in this species[14]. Moreover, Doppler ultrasound has improved the early diagnosis of testicular dysfunction [15–17]. However, the evaluation of testicular blood flow requires some practitioner experience and ultrasound equipment with the Pulse Doppler modality. Therefore, the incorporation of new affordable non-invasive techniques into the breeding soundness assessment, providing a simple and fast diagnosis of testicular dysfunction in field conditions is necessary. B-mode ultrasound is one of the techniques most extensively used in the diagnosis of different conditions in stallions. This ultrasonographic modality allows a visual evaluation of the anatomical structures of the testis and the identification of gross lesions, as well as prediction of the efficiency of sperm production by calculating testicular volume and subsequent estimation of Daily Sperm Output (DSOe)[11,12]. However, this technique is of limited diagnostic value as most pathological conditions do not produce any change in testicular echogenicity that can be detected visually [18]. Even stallions with advanced stages of testicular degeneration present an apparently

normal testicular echotexture [5]. Currently, computer-assisted pixel analysis of testicular ultrasonograms has been used to quantify the echotexture of testicular parenchyma as an alternative method to the evaluation of testicular tissue structure in several species [19–25]. Most of these algorithms are based on the detection of changes in pixel intensity (mean numerical pixel) and pixel heterogeneity (pixel standard deviation) in ultrasonograms of the testis [23,25–27]. Changes in these parameters have been linked to variations in the histomorphology of testicular tissue [24,26,27]. Recently, a new specific software for testicular echotexture analysis has been designed by HUMECO in collaboration with ECM (Ecotext software, Humeco, Spain) [28,29]. This software has been tested in rams and boars, but not in stallions [28,29]. Ecotext was created to be used with EXAGO ultrasound scanners and provides a quick method for evaluation of testicular function and structure. Each pixel of the image obtained reflects the testicular parenchyma, whose intensity can be measured according to the different shades of gray, black and white. This procedure allows the identification of subtle variations, which cannot be appreciated with the naked eye, to be measured and identified. According to the manufacturer, Ecotext provides the user with a total of six different parameters: three parameters at normal resolution: Ecotext 1, Ecotext 2 and Ecotext 3, related to the number of black, white, and grey pixels respectively, and three parameters at high resolution related to hypoechogenic areas: Ecotext tubular density (density of hypoechogenic areas), Ecotext tubular diameter (mean diameter of hypoechogenic areas) and Ecotext tubular area (total percentage of hypoechogenic area). Thus, we hypothesized that Ecotext could be an easy to use, valuable non-invasive tool to identify stallions with testicular dysfunction in field conditions.

The aims of this study were to investigate whether Ecotext is a good method for diagnosis of stallions with testicular dysfunction and to study the relationship between Ecotext parameters and those of sperm quality and sperm production, testicular volume, and testicular blood flow used normally in the diagnosis of this condition.

2. Materials and methods

2.1 Experimental design

The present work aims to investigate whether Ecotext parameters are good markers of testicular dysfunction in equines. For this purpose, 21 control stallions with good seminal characteristics, 9 immunized stallions with anti-GnRH vaccine (induced TD) and 3 stallions with acquired TD were used. The relationship between Ecotext parameters, and the parameters commonly used in the

diagnosis of fertility problems (those of sperm motility and sperm production, TTV, and testicular blood flow), were also investigated by correlations.

2.2 Animals

A total of 33 stallions of various breeds (Pure Spanish Horse, Spanish Arabian, Anglo Arabian and Spanish Sport Horse) and ages (4-19 years old) were included in this study (Table 1). Horses were classified into groups of 21 control stallions with normal testicular functionality (acceptable semen quality, based on established minimum standard values of semen quality recommended by the Society for Theriogenology stallion BSE Manual (Total motility (TM) > 60%; Progressive motility (PM) > 45% and total n° of sperm with progressive motility > 2000 x 10⁶) [8–10], and 12 stallions with testicular dysfunction (induced TD and acquired TD) with poor semen quality (TM < 60 and < 45% and low sperm production with a total n° of sperm with progressive motility < 2000 X 10⁶ spz)[8,10]. A complete clinical history was taken for all stallions included in this study, since testicular degeneration (acquired condition) and hypoplasia (congenital condition) are indistinguishable clinically and histologically.

The control stallions were horses used as breeders at the Veterinary Teaching Hospital of the University of Extremadura, with a proven fertility (10 stallions); stallions that came to the hospital for semen freezing (6 stallions) and a pre-purchase reproductive examination (5 stallions) (Table 1). All stallions with testicular dysfunction were stallions referred to the Veterinary Teaching Hospital for acquired fertility problems and poor semen quality. Nine (4-6 years old) of the twelve horses had been previously immunized (primary and booster) with anti GnRH vaccine (Improvac®, Zoetis, Spain) in a time frame of 2-8 months prior to the study, showing induced testicular dysfunction (subfertile stallions 1-9). Stallion number 10 had an acquired idiopathic testicular dysfunction, and the last two stallions were diagnosed with acquired testicular dysfunction associated with age (stallions 11-12) (Table 1). All of them had seminal parameters below the minimum standard values for sperm quality recommended by the Society for Theriogenology stallion [8,10]. The study was carried out during the 2019-2021 breeding seasons by the Reproduction Service of the Veterinary Teaching Hospital of the University of Extremadura. The animals were kept and handled according to the standards established by European Union (Law 6/2913 June 11 and European Directive 2010/63/EU), and they were all vaccinated and dewormed.

2.3 Semen collection and evaluation

Ejaculates were collected with a prewarmed (45–50 °C) Missouri model artificial vagina (IMV, France), lubricated with non-spermicidal gel and an inline filter to eliminate the gel fraction. Stallions were stimulated with a mare in estrous and semen was collected using a phantom. Semen was immediately transported to the laboratory for evaluation and processing.

2.3.1 Sperm production (DSOa: actual Daily Sperm Output)

To calculate the DSOa, the extragonadal sperm reserves were depleted. For this purpose, semen was collected from each stallion for 7-10 consecutive days until the total number of sperm collected and sperm quality become more constant[12]. Afterwards, three consecutive ejaculates per stallion were used to assess semen quality and sperm production. To calculate the total number of sperm (TNS), the volume of the filtered ejaculate (gel free fraction) was measured in a measuring beaker and sperm concentration (fluid density) was assessed using a spectrophotometer (Spermacue®, Minitube Ibérica, La Selva del Camp, Spain). The TNS at DSO (TNS: volume x concentration) was calculated for each stallion[12].

2.3.2 Sperm motility

Sperm motility was assessed using a computer-assisted sperm analysis (CASA) system (ISAS V.1.2, Proiser, Valencia, Spain) according to the standard protocols used at our center[30]. Semen was loaded into a 20 µm deep Leja chamber (Leja, Amsterdam, The Netherlands) and placed on a warmed stage at 38°C. Analysis was based on evaluation of 60 consecutive digitalized images obtained using a 10X negative phase-contrast objective (Olympus CX 41). At least three different fields were recorded to ensure that at least 500 spermatozoa were analyzed per sample. Spermatozoa with a VAP (average velocity) < 15 µm/s were considered immotile, while only spermatozoa with a VAP > 35 µm/s were considered motile. Spermatozoa deviating < 45% from a straight line (STR) were classified as linearly motile[30]. The percentage of total motility (TM) and progressive motility (PM) (STR > 45% and VAP > 35 µm/s) was calculated in all ejaculates.

2.4 Ultrasound examination of the testes

Firstly, the testes were examined by visual inspection and palpation, and following this they were evaluated using B-mode ultrasonography. The ultrasound equipment used in this study was a

Mylab™ Seven (Esaote, Spain) with two different probes: 1-8 MHz convex transducer (AC2541®) and 6-13 MHz linear traducer (SL3323®).

2.4.1 B-mode ultrasound evaluation:

The B-mode ultrasound modality was used to measure the testicular volume (TV: $0.053 \times \text{height} \times \text{length} \times \text{width}$) and calculate the total testicular volume (TTV: TV left+ TV right). Then, the estimated Daily Sperm Output (DSOe: $[0.024 \times \text{TTV}] - 0.76$) was calculated. The spermatogenic efficiency (DSO per milliliter of testis) was also calculated by dividing the TNS in the ejaculate at DSO by the total testicular volume(TTV) [11,12,31,32].

2.4.2 Pulse Doppler ultrasound evaluation:

Testicular spectral analysis was carried out according to the method described by Ortiz-Rodriguez et al [17]. During the examination, the stallions were restrained in stocks and sedated with xylazine (0.5 mg/kg intravenous) immediately prior to performing the testicular blood flow exam[18]. Blood flow assessment did not take more than 15-20 minutes per stallion.

The Doppler parameters were obtained from the marginal branch of the testicular artery (capsular artery). The parameters measured in this study were the Peak Systolic Velocity (PSV), End Diastolic Velocity (EDV), Time Average Maximum Velocity (TAMV). The Resistive Index (RI: $\text{PSV} - \text{EDV} / \text{PSV}$) and Pulsatility Index (PI: $\text{PSV} - \text{EDV} / \text{TAMV}$) were also automatically calculated by the ultrasound equipment. A total of four cardiac cycles (waveform) were recorded per testicle.

The diameter of the testicular artery of each testicle was also measured at the epididymal edge of the testicle, close to the tail of the epididymis (capsular artery (CA))[15,18]. Color Doppler was first applied to identify the capsular artery. Following this, a longitudinal section of this artery in each testis was frozen in B-mode to measure the arterial diameter.

2.4.3 Evaluation of ecotexture of the testicular parenchyma

The echotexture of the testicular parenchyma was assessed using B-mode ultrasounography with an EXAGO® ultrasound machine (ECM, Angouleme, France), connected to a 7.5 MHz linear rectal probe. Each ultrasound image of the testis in B-mode was later evaluated using a specific image analysis software (Ecotext®, Humeco, Huesca, Spain). Briefly, three transverse cross sections of the middle of the testis (cranial to the central vein) were taken per testicle. Three 124-frame videos of each testicle were recorded and downloaded to a computer for further analysis with Ecotext®. Lubricant gel was used as a coupling material between the transducer and the scrotum and minimum

pressure was applied to obtain the images. The echographic videos were analysed using algorithms, selecting a region of interest (ROI) and obtaining the average from the 3 videos for the following parameters: Ecotext 1 (black pixel), Ecotext 2 (white pixel) and Ecotext 3 (gray pixels). Ecotext tubular density (density of hypoechogenic areas (density of tubules/cm²), Ecotext tubular area (percentage of hypoechogenic areas in the total area of the ROI) and Ecotext tubular diameter (mean diameter of hypoechogenic areas of the lumen of the seminiferous tubules (µm)[28]. (Fig. 1)

2.7 Statistical analysis

Statistical analysis was carried out using GraphPad Prism version 9.00 for Mac, La Jolla California USA, (www.graphpad.com). The data were first examined using a Shapiro-Wilk test and D'Agostino & Pearson omnibus to test the distribution of the data. A Levene's test was used to assess the homogeneity of variances for the variables calculated. Paired t-tests were used with parameters with a normal distribution and those parameters with a non-Gaussian distribution were assessed with a Mann Whitney U test. Differences between control and TD stallions were considered statistically significant with a $p \leq 0.05$. All data are displayed as mean \pm SD.

Receiver operating characteristic (ROC) curves and Youden's J statistics were used to investigate the value of the proposed variables as indicators of TD and cut-off values were also established. Receiver operating characteristics (ROC) analyses were used expressing prognostic value as area under curve (AUC) with a 95% confidence interval (CI) and significance test.

The correlation between Ecotext parameters and the other parameters evaluated in the study were investigated using a Pearson and Spearman's correlation test. Significant correlations were identified when $p \leq 0.05$.

3. Results

3.1 Sperm production

Stallions with TD (induced and acquired) had a lower sperm production at DSO ($1891 \pm 1409 \times 10^6$ spz) than stallions with normal testicular functionality ($5843 \pm 1699 \times 10^6$ spz) ($p \leq 0.0001$). However, when both groups were analyzed separately, stallions with induced TD had a lower number of total sperm at DSO than stallions with an acquired testicular inefficiency (1230 ± 867 vs 3874 ± 215) ($p \leq 0.05$) (Table 2).

3.2 Sperm motility

Stallions with TD in this study presented values of TM and PM below minimum standard values of seminal quality recommended by the Society for Theriogenology stallion BSE Manual and the cut-off values used in our center [8,10,33] (TM: 32.41 ± 16.89 ; PM: 16.18 ± 10.82) [34]. Significant differences were observed between control stallions and stallions with induced TD (TM: 84.79 ± 5.61 vs 51.22 ± 18.68 ; PM: 61.30 ± 10.29 vs 12.03 ± 4.04) ($p \leq 0.0001$) and acquired TD (TM: 84.79 ± 5.61 vs 26.14 ± 11.31 ; PM: 61.30 ± 10.29 vs 29.44 ± 15.40) (Fig.2). Mean values of individual data for TM, PM and total n° of sperm with PM for each stallion included in the study are showed as supplementary data.

3.3 B-Mode Ultrasonographic assessment

Expected DSO and TTV were also lower in stallions with TD than in control stallions (DSOe: 2933 ± 2026 vs 5832 ± 1650 ; TTV: 175 ± 80.96 vs 295 ± 68.8) ($p \leq 0.0001$). However, when stallions were grouped together based on induced and acquired dysfunction, only stallions vaccinated with Improvac (induced) showed a significant decrease in expected DSO and TTV compared with stallions with normal testicular functionality (DSOe: 2041 ± 1097 vs 5832 ± 1650 ; TTV: 143.4 ± 48.61 vs 295 ± 68.8) ($p \leq 0.0001$) (Table 2). Stallions with acquired TD did not show significant differences in these parameters compared with the control group (Table 2). DSO per milliliter of testis was also lower in the TD stallion group (10.56 ± 5.68) than in stallions with normal testicular functionality (19.86 ± 3.48) ($p \leq 0.0001$) (table 2). Mean values of individual data for TTV, DSO/ml of the testis, DSOe and DSOa of each stallion included in the study are shown in the supplementary data.

Testicular artery diameters were significantly smaller in the TD stallion group than in control stallions (2.22 ± 0.42 vs 3.02 ± 0.38 mm) ($p \leq 0.0001$) (Table 3). However, when stallions were divided into stallions with induced and acquired TD, testicular artery diameters in stallions with acquired testicular dysfunction did not show significant differences from those of normal stallions (Table 3).

3.4 Evaluation of testicular blood flow

Despite the small size of the testicles of some stallions, all Doppler parameters could be obtained from the capsular artery in all animals included in the study. Stallions with acquired TD had higher values for PI and RI than stallions with normal testicular functionality ($p \leq 0.05$) (Table 4). In contrast, immunized stallions (induced TD) showed a significant decrease in both indices compared with normal stallions. (PI: 0.83 ± 0.18 vs 1.15 ± 0.24 ; and RI: 0.51 ± 0.07 vs 0.63 ± 0.08) ($p \leq 0.0001$) (Table 3).

Conversely, all Doppler velocities were significantly lower in stallions with TD than in control horses ($p \leq 0.0001$) (PSV: 13.58 ± 5.59 vs 21.23 ± 6.30 ; EDV: 5.63 ± 2.05 vs 7.89 ± 2.93 ; TAMV: 7.97 ± 3.04 vs 12.02 ± 4.01 , ($p \leq 0.0001$). However, when a separate assessment was performed in those horses with TD, differences between normal stallions and stallions with acquired TD were not found (Figure 4).

3.5 Evaluation of testicular echotexture

Stallions with TD were found to have significantly lower values for Ecotext 1 (2.82 ± 3.54 vs 1.65 ± 3.09 , $p \leq 0.05$), Ecotext tubular area (5.40 ± 1.90 vs 4.07 ± 1.54 , $p \leq 0.01$) and Ecotext tubular density (132.1 ± 16.35 vs 110.2 ± 13.91 , $p \leq 0.0001$) parameters than control stallions (Figure 5). However, when stallions with poor semen were subclassified into stallions with induced or acquired testicular dysfunction, only the later presented significant differences in all Ecotext parameters (Table 5). Stallions with acquired TD were found to have alterations in all Ecotext parameters compared with the control group. Ecotext 2 (white pixels) and Ecotext 3 (grey pixels) were significantly increased in the acquired TD group compared with the control group (Ecotext 2: 1584.0 ± 575.8 vs 388 ± 368.2 and Ecotext 3: 134.2 ± 9.26 : ($p \leq 0.0001$). However, Ecotext 1 (black pixels) were increased in control stallions. Ecotext tubular area, Ecotext tubular diameter and Ecotext tubular density were lower in stallions with acquired TD than in the control group ($p \leq 0.0001$). All mean values and standard deviations are shown in Table 5 for each group of stallions. Only immunized stallions had lower values for Ecotext tubular density in relation to controls ($p \leq 0.0001$).

3.6 Predictive values of Ecotext parameters in the diagnosis of testicular dysfunction in stallions using ROC curves

Parameters that showed differences between stallions with normal testicular functionality and TD stallions were further investigated constructing ROC curves and Youden's J index statistics to determine their prognostic value as markers of testicular degeneration. Ecotext tubular density was the best Ecotext parameter to differentiate normal stallions from stallions with TD, with an area under curve (AUC) of 0.84; $p \leq 0.0001$. The optimal cut-off value for this parameter was 124.3 seminiferous tubules/cm². In general, stallions with TD reliably fell below this cut-off value. Ecotext tubular area had a lower predictive value (AUC: 0.69; $p \leq 0.01$).

3.7 Correlation between Ecotext parameters, Doppler parameters, and sperm production

Correlations between Ecotext parameters and the different parameters used in this study were

evaluated using a Pearson's test and Spearman's test. (Table 5). Correlations between tubular density with the other parameters from the study were evaluated using a Pearson's test. (Table 5). Significant positive correlations were found between Ecotext tubular density and Doppler indices (PI: 0.52; RI: 0.40 $p \leq 0.0001$), total testicular volume (0.42; $p \leq 0.05$) and sperm motility parameters (TM: 0.49; and PM: 0.54; $p \leq 0.001$).

Ecotext 2 (white pixels) (parameter increased in stallions with acquired TD) was correlated with both Doppler indices (RI (r: 0.53; $p \leq 0.01$), PI (r: 0.52; $p \leq 0.05$)) and Doppler velocities (PSV (r: 0.66; $p \leq 0.001$) and TAMV (r: 0.63; $p \leq 0.05$)). Moreover, negative correlations were observed between this parameter and spermatogenic efficiency (DSO/ml of the testis: -0.50; $p \leq 0.05$). Ecotext tubular area was negatively correlated with RI (r: -0.65; $p \leq 0.001$), PI (r: -0.69; $p \leq 0.001$), PSV (r: -0.70; $p \leq 0.001$) and TAMV (r: -0.54; $p \leq 0.01$). Ecotext tubular diameters was also negatively correlated with Doppler indices and TAMV (Table 5).

4. Discussion

This study was conducted to investigate whether the use of a specific software for analysis of testicular echotexture may be a suitable tool for diagnosis of stallions with declining testicular function in field conditions. Reference values for the six Ecotext parameters were established for the first time in normal stallions and stallions with induced and acquired TD in the present study. As would be expected, visual echotexture dissimilarities could not be appreciated in the B-mode images when they were compared with those from the control stallions. Nevertheless, Ecotext software was able to identify changes in the testicular echotexture of stallions with testicular inefficiency. These stallions had lower Ecotext 1 (black pixels) ($p \leq 0.05$), Ecotext tubular area (percentage of hypoechogenic areas in the total area of the ROI) ($p \leq 0.001$) and Ecotext tubular density (density of hypoechogenic areas (density of tubules/cm²)($p \leq 0.0001$) values than stallions in the control group. Previous research has indicated that during puberty testicular echogenicity (pixel intensity) increases, due to the growth and expansion of the seminiferous tubules, Sertoli cell differentiation, increased seminiferous tubule diameter and lumen size, and rapid development of the population of all germ cell types that lead to initiation of spermatogenesis [25,26,29,35]. Differences in testicular echotexture (pixel intensity) have already been described in prepubertal horses in a previous report [36]. However, in this study the authors did not find differences in echotexture among adult stallions. This could be because they used different software (Image J program) and the number of adult stallions analyzed was small and non-pathological, and therefore probably had a very homogeneous echotexture.

In the present study, when echotexture parameters were evaluated separately in stallions with induced and acquired TD, we found interesting results. Stallions with acquired TD showed differences in all Ecotext parameters with respect to the controls. Ecotext 1, Ecotext tubular area, Ecotext tubular diameter and Ecotext tubular density were lower in these stallions than in controls ($p \leq 0.0001$), despite both groups having similar values of DSOe and TTV. In consensus with our results, previous research looking at germ cell loss rates showed that it is likely that testicular degeneration is present in stallions before there is any appreciable reduction in testicular size which is clinically significant[37]. The stallions included in this group were two geriatric stallions and one stallion with chronic idiopathic subfertility (all of them with chronic TD). Ecotext parameters are related to hypoechogenic areas of the testicular parenchyma detected on ultrasonography, not with histomorphometric parameters obtained from histological sections. However, our results suggest that it is likely that these stallions were developing a degenerative testicular process with a loss of testicular architecture and function, since all Ecotext parameters were altered compared to controls. To date, testicular biopsy is the only accurate technique to confirm a diagnosis of testicular degeneration [5]. Unfortunately, histopathological studies could not be performed on these stallions and thus, we cannot confirm it. The most common histological finding in testes with degeneration is a loss of the normal architecture of the seminiferous epithelium, with a reduced diameter of these tubules due to a loss of germ cells [1]. In addition, testicular degeneration is also commonly characterized by increased echogenicity (due to fibrosis) [38]. In accordance with this, the stallions with acquired TD in our study had also a significant increase in Ecotext 2 (white pixels) and Ecotext 3 (grey pixels) parameters in relation to the control group (Ecotext 2: 1584.0 ± 575.8 vs 388 ± 368.2 and Ecotext 3: 134.2 ± 9.26 : ($p \leq 0.0001$), which once again supports our hypothesis.

In contrast, horses with induced TD (Improvac™) only showed a significant reduction in the Ecotext tubular density (116.2 ± 8.59 vs 132.10 ± 16.35 , $p \leq 0.001$), despite the fact that all sperm production and quality parameters were notably worse in this group. Similarly, to our results, in a recent report, boars immunized with Improvac also showed a reduction in testicular size and sperm production, but they did not exhibit differences in the histopathologic parameters such as seminiferous tubule diameters, tubule area and interstitial area in relation to controls[39]. They only showed Sertoli and Leydig cell atrophy with reductions in cytoplasmic volume and very few spermatids. The stallions with induced TD were vaccinated within a timeframe of 2-8 months before the study, and although we could not obtain previous data from these stallions, all of them had a significant decrease in all parameters evaluated in relation to control stallions. Therefore, a possible explanation for our results is that immunized stallions experience a transient and acute loss of testicular functionality due to a reduction in testosterone production. However, the architecture of the testicular parenchyma may not

be affected since differences in Ecotext parameters with control stallions were not detected. Moreover, several studies have demonstrated that the effect of immunization against gonadotrophin releasing hormone (GnRH) is reversible [40,41]. Therefore, it is probably that GnRH immunization only temporarily affects testicular function and not the architecture of the seminiferous tubules. This finding suggests that Ecotext may be a suitable tool to identify immunized stallions from those with acquired chronic TD. However, additional studies with a greater number of animals would be necessary.

Pulse Doppler ultrasound is a suitable tool for the diagnosis of testicular dysfunction in equines since a proper vascular perfusion is necessary for adequate functionality of the testis. Recent studies have demonstrated that evaluation of vascularization of the testis has been used as a predictor of spermatogenesis and as an indicator of testicular dysfunction [16,42,43]. Moreover, males with TD show an increase in Doppler indices due to higher vascular resistance in the vessels [16,17,44]. To the contrary, we did not find significant differences in any Doppler parameters (Doppler indices and velocities) obtained from stallions with TD in relation to control stallions. Moreover, stallions with TD presented a non-significant decrease in the values of both Doppler indexes (PI and RI). Nevertheless, when we analyzed Doppler parameters in stallions with induced and acquired TD separately, we observed completely different results in both groups. Pulsed Doppler ultrasound revealed a lower vascular supply in the testicles with an acquired TD, characterized by an increase in Doppler indices (PI: 1.83 ± 0.17 vs 1.15 ± 0.24 ; RI: 0.78 ± 0.03 vs 0.63 ± 0.08 , $p \leq 0.0001$) compared with the control group. Instead, the stallions with induced TD had lower Doppler indices (PI: 0.83 ± 0.18 vs 1.15 ± 0.24 ; RI: 0.51 ± 0.07 vs 0.63 ± 0.08 , $p \leq 0.0001$) than controls. Unfortunately, we were unable to record Doppler indices and obtain data from immunized stallions prior to the administration of the vaccine. Therefore, we cannot determine whether these stallions already had lower Doppler indices before immunization or whether anti-GnRH immunization and its hormonal effects may cause any changes to testicular blood flow. Therefore, more studies are needed to verify these findings. In this study, interesting correlations were also found among Ecotext and Doppler parameters in stallions with TD. Positive correlations were found between Ecotext 2 and Ecotext 3 (parameter increased in stallions with acquired TD) and Doppler indices (PI and RI) and Doppler velocities (PSV and TAMV). In addition, negative correlations were observed between Ecotext 2 (white pixels) and spermatogenic efficiency (DSO/ml of testis: -0.50 ; $p \leq 0.05$).

Another interesting finding in this study was that stallions with induced TD presented smaller testicular artery diameters compared with healthy stallions (2.05 ± 0.32 vs 3.02 ± 0.38 mm; $p \leq 0.0001$). However, we did not detect differences in testicular artery diameters between acquired TD

stallions and the control group. A possible cause of this is that the TTV in immunized stallions was significantly reduced, unlike in the group of stallions with acquired TD. In addition, the reduced number of animals included in the group with acquired TD was also taken into account. Several studies have observed that the testicular artery diameter can be affected by different factors such as the season, pentoxifylline or TD[16,18,45,46]. However, findings from our study suggested that the larger the testicular size, the greater the vascular requirements are likely to be since only stallions with a significant reduction in testicular volume had a significantly smaller testicular artery diameter.

The parameters that presented the best prognostic values, using the area under the ROC curve, for differentiation from stallions with normal testicular function from those with TD were Ecotext tubular density (AUC values of 0.84; $p \leq 0.0001$) and Ecotext tubular area (AUC values of 0.69; $p \leq 0.05$). According to this statistical method, Ecotext tubular density is a “good indicator” for the diagnosis of stallions with testicular dysfunction. The optimal cut-off value of tubular density to diagnose horses with TD was 124.3 seminiferous tubules/cm². In general, stallions with testicular dysfunction reliably fell below this cut-off value. Interestingly, Ecotext tubular density presented a high correlation with sperm production (DSOr: 0.51; $p \leq 0.05$) and sperm motility (TM: 0.51, PM: 0.54 $p \leq 0.05$). All these results strongly suggest that the computer-assisted pixel analysis of testicular ultrasonograms could be a good predictor of testicular functionality.

Ecotext may be a helpful tool for the diagnosis of stallions with TD. These results also open the possibility for new research focused on identifying the relationship between Ecotext parameters and histomorphometric characteristics in stallion testes.

Conclusion

Ecotext software is a simple and fast method of analysis that could enhance the diagnostic power of testicular ultrasonography in clinical practice and provide a non-invasive diagnosis of testicular dysfunction in stallions. Ecotext was able to identify changes in the testicular echotexture in stallions with TD in relation to controls. Moreover, this technique may be a suitable tool to identify vaccinated stallions from those with acquired chronic TD. The Ecotext image analysis software has a promising future as a non-invasive diagnostic technique for testicular pathologies, in view of this initial research, further studies involving more animals are warranted.

Declaration of Competing Interest

The authors declare that there are no conflicts of interest that could be perceived to prejudice the

reported research.

Acknowledgements

The authors received financial support for this study from the Ministerio de Ciencias, Innovación y Universidades PID2019-107797RA-100/AEI/10.13039/501100011033 and from Junta de Extremadura-FEDER (IB20163, IB20008 and GR21060). JMOR holds a PhD grant from the Junta de Extremadura- FEDER (PD 18005), Mérida, Spain. GGP holds a PhD grant from the Ministry of Science, Madrid, Spain (PRE2018-083354).

References

- [1] Oristaglio Turner RM. Pathogenesis, Diagnosis, and Management of Testicular Degeneration in Stallions. *Clinical Techniques in Equine Practice* 2007;6. <https://doi.org/10.1053/j.ctep.2007.09.006>.
- [2] Beard W. Abnormalities of the testes. *Equine reproduction*. vol. 1. Second Edition. Oxford: Wiley-Blackwell; 2011.
- [3] Birrell JR, Schulman ML, Botha AE, Ganswindt A, Fosgate GT, Bertschinger HJ. Vaccination against GnRH as a prelude to surgical castration of horses. *Equine Veterinary Journal* 2021. <https://doi.org/10.1111/evj.13411>.
- [4] Janett F, Stump R, Burger D, Thun R. Suppression of testicular function and sexual behavior by vaccination against GnRH (Equity™) in the adult stallion. *Animal Reproduction Science* 2009;115. <https://doi.org/10.1016/j.anireprosci.2008.11.011>.
- [5] Turner RM. Declining testicular function in the aging stallion: Management options and future therapies. *Animal Reproduction Science* 2019;207. <https://doi.org/10.1016/j.anireprosci.2019.06.009>.
- [6] Pozor MA, Zambrano GL, Runcan EE, Kelleman AA, Macpherson ML. Ultrasonographic and morphological sequelae to repeated testicular biopsies in stallions in relation to the lateral branching of the testicular artery. *Equine Veterinary Education* 2016;28. <https://doi.org/10.1111/eve.12587>.
- [7] Rode K, Sieme H, Otzen H, Schwennen C, Lüpke M, Richterich P, et al. Effects of Repeated Testicular Biopsies in Adult Warmblood Stallions and Their Diagnostic Potential. *Journal of Equine Veterinary Science* 2016;38. <https://doi.org/10.1016/j.jevs.2016.01.003>.
- [8] McCue PM. *Breeding Soundness Evaluation of the Stallion*. Equine Reproductive Procedures, Hoboken, NJ, USA: John Wiley & Sons, Inc; 2014. <https://doi.org/10.1002/9781118904398.ch97>.
- [9] Ball BA. Diagnostic Methods for Evaluation of Stallion Subfertility: A Review. *Journal of Equine Veterinary Science* 2008;28. <https://doi.org/10.1016/j.jevs.2008.10.003>.
- [10] Hurtgen JP. Evaluation of the Stallion for Breeding Soundness. *Veterinary Clinics of North America: Equine Practice* 1992;8. [https://doi.org/10.1016/S0749-0739\(17\)30472-8](https://doi.org/10.1016/S0749-0739(17)30472-8).
- [11] Blanchard TL, Johnson L, Varner DD, Rigby SL, Brinsko SP, Love CC, et al. Low Daily Sperm Output Per Ml of Testis as a Diagnostic Criteria for Testicular Degeneration in Stallions. *Journal of Equine Veterinary Science* 2001;21. [https://doi.org/10.1016/S0737-0806\(01\)70228-6](https://doi.org/10.1016/S0737-0806(01)70228-6).
- [12] Love CC, Garcia MC, Riera F, Kenney RM. Evaluation of measures taken by ultrasonography and caliper to estimate testicular volume and predict daily sperm output in the stallion . *Journal of Reproduction and Fertility Supplement* 1991;44:99–105.

- [13] Blanchard T, Varner D, Johnson L, Roser J, Hill J, Miller C. Testicular and hormonal changes in stallions with thermally induced testicular degeneration. *J Reprod Fertil Suppl* 2000;56:51–9.
- [14] Pozor M. Diagnostic applications of ultrasonography to stallion's reproductive tract. *Theriogenology* 2005;64. <https://doi.org/10.1016/j.theriogenology.2005.05.007>.
- [15] Pozor MA, McDonnell SM. Color Doppler ultrasound evaluation of testicular blood flow in stallions. *Theriogenology* 2004;61. [https://doi.org/10.1016/S0093-691X\(03\)00227-9](https://doi.org/10.1016/S0093-691X(03)00227-9).
- [16] Pozor MA, Nolin M, Roser J, Runyon S, Macpherson ML, Kelleman A. Doppler indices of vascular impedance as indicators of testicular dysfunction in stallions. *Journal of Equine Veterinary Science* 2014;34. <https://doi.org/10.1016/j.jevs.2013.10.021>.
- [17] Ortiz-Rodriguez JM, Anel-Lopez L, Martin-Munõz P, Lvarez M, Gaitskell-Phillips G, Anel L, et al. Pulse Doppler ultrasound as a tool for the diagnosis of chronic testicular dysfunction in stallions. *PLoS ONE* 2017;12. <https://doi.org/10.1371/journal.pone.0175878>.
- [18] Ortega-Ferrusola C, Gracia-Calvo L, Ezquerra J, Pena F. Use of Colour and Spectral Doppler Ultrasonography in Stallion Andrology. *Reproduction in Domestic Animals* 2014;49. <https://doi.org/10.1111/rda.12363>.
- [19] Arteaga AA, Barth AD, Brito LFC. Relationship between semen quality and pixel-intensity of testicular ultrasonograms after scrotal insulation in beef bulls. *Theriogenology* 2005;64:408–15. <https://doi.org/10.1016/j.theriogenology.2004.12.008>.
- [20] Pozor M, Morrissey H, Albanese V, Khouzam N, Deriberprey A, Macpherson ML, et al. Relationship between echotextural and histomorphometric characteristics of stallion testes. *Theriogenology* 2017;99:134–45. <https://doi.org/10.1016/j.theriogenology.2017.05.031>.
- [21] Abecia JA, Carvajal-Serna M, Casao A, Palacios C, Pulinas L, Keller M, et al. The continuous presence of ewes in estrus in spring influences testicular volume, testicular echogenicity and testosterone concentration, but not LH pulsatility in rams. *Animal* 2020;14:2554–61. <https://doi.org/10.1017/S1751731120001330>.
- [22] Moxon R, Bright L, Pritchard B, Bowen IM, de Souza MB, da Silva LDM, et al. Digital image analysis of testicular and prostatic ultrasonographic echogenicity and heterogeneity in dogs and the relation to semen quality. *Animal Reproduction Science* 2015;160:112–9. <https://doi.org/10.1016/j.anireprosci.2015.07.012>.
- [23] Ahmadi B, Mirshahi A, Giffin J, Oliveira MEF, Gao L, Hahnel A, et al. Preliminary assessment of the quantitative relationships between testicular tissue composition and ultrasonographic image attributes in the ram. *The Veterinary Journal* 2013;198. <https://doi.org/10.1016/j.tvjl.2013.06.001>.
- [24] Giffin JL, Franks SE, Rodriguez-Sosa JR, Hahnel A, Bartlewski PM. A Study of Morphological and Haemodynamic Determinants of Testicular Echotexture Characteristics in the Ram. *Experimental Biology and Medicine* 2009;234. <https://doi.org/10.3181/0812-RM-364>.
- [25] Brito LFC, Barth AD, Wilde RE, Kastelic JP. Testicular ultrasonogram pixel intensity during sexual development and its relationship with semen quality, sperm production, and quantitative testicular histology in beef bulls. *Theriogenology* 2012;78. <https://doi.org/10.1016/j.theriogenology.2012.01.022>.
- [26] Giffin JL, Bartlewski PM, Hahnel AC. Correlations among ultrasonographic and microscopic characteristics of prepubescent ram lamb testes. *Experimental Biology and Medicine* 2014;239. <https://doi.org/10.1177/1535370214543063>.
- [27] Arteaga AA, Barth AD, Brito LFC. Relationship between semen quality and pixel–intensity of testicular ultrasonograms after scrotal insulation in beef bulls. *Theriogenology* 2005;64. <https://doi.org/10.1016/j.theriogenology.2004.12.008>.
- [28] Abecia JA, Carvajal-Serna M, Casao A, Palacios C, Pulinas L, Keller M, et al. The continuous presence of ewes in estrus in spring influences testicular volume, testicular echogenicity and

- testosterone concentration, but not LH pulsatility in rams. *Animal* 2020;14.
<https://doi.org/10.1017/S1751731120001330>.
- [29] Abecia JA, Gave M, García AI, Casao A, Carvaja-ISerna M, Palacios C, et al. Long days in winter or the presence of adult sexually active rams did not influence the timing of puberty of autumn-born Rasa Aragonesa ram-lambs. *Biological Rhythm Research* 2021;52.
<https://doi.org/10.1080/09291016.2019.1613321>.
- [30] Ortega-Ferrusola C, Macías García B, Suárez Rama V, Gallardo-Bolaños J, González-Fernández L, Tapia J, et al. Identification of Sperm Subpopulations in Stallion Ejaculates: Changes after Cryopreservation and Comparison with Traditional Statistics. *Reproduction in Domestic Animals* 2009;44. <https://doi.org/10.1111/j.1439-0531.2008.01097.x>.
- [31] Turner RM. Current Techniques for Evaluation of Stallion Fertility. *Clinical Techniques in Equine Practice* 2005;4. <https://doi.org/10.1053/j.ctep.2005.07.007>.
- [32] Gebauer MR, Pickett BW, Swierstra EE. Reproductive Physiology of the Stallion. II. Daily Production and Output of Sperm². *Journal of Animal Science* 1974;39.
<https://doi.org/10.2527/jas1974.394732x>.
- [33] Varela E, Rey J, Plaza E, Muñoz de propios P, Ortiz-Rodríguez JM, Álvarez M, et al. How does the microbial load affect the quality of equine cool-stored semen? *Theriogenology* 2018;114.
<https://doi.org/10.1016/j.theriogenology.2018.03.028>.
- [34] Suliman Y, Becker F, Tuchscherer A, Wimmers K. Seasonal variations in quantitative and qualitative sperm characteristics in fertile and subfertile stallions. *Archives Animal Breeding* 2020;63.
<https://doi.org/10.5194/aab-63-145-2020>.
- [35] Evans ACO, Pierson RA, Garcia A, McDougall LM, Hrudka F, Rawlings NC. Changes in circulating hormone concentrations, testes histology and testes ultrasonography during sexual maturation in beef bulls. *Theriogenology* 1996;46. [https://doi.org/10.1016/0093-691X\(96\)00190-2](https://doi.org/10.1016/0093-691X(96)00190-2).
- [36] Pozor M, Morrissey H, Albanese V, Khouzam N, Deriberprey A, Macpherson ML, et al. Relationship between echotextural and histomorphometric characteristics of stallion testes. *Theriogenology* 2017;99. <https://doi.org/10.1016/j.theriogenology.2017.05.031>.
- [37] Blanchard TL, Johnson L. Increased germ cell degeneration and reduced germ cell:Sertoli cell ratio in stallions with low sperm production. *Theriogenology* 1997;47. [https://doi.org/10.1016/S0093-691X\(97\)00025-3](https://doi.org/10.1016/S0093-691X(97)00025-3).
- [38] Humphrey JD, Ladds PW. A quantitative histological study of changes in the bovine testis and epididymis associated with age. *Research in Veterinary Science* 1975;19.
[https://doi.org/10.1016/S0034-5288\(18\)33523-9](https://doi.org/10.1016/S0034-5288(18)33523-9).
- [39] Wicks N, Crouch S, Pearl CA. Effects of Improvac and Bopriva on the testicular function of boars ten weeks after immunization. *Animal Reproduction Science* 2013;142:149–59.
<https://doi.org/10.1016/j.anireprosci.2013.09.017>.
- [40] Kumar N. Chronic Toxicity and Reversibility of Antifertility Effect of Immunization against Gonadotropin-Releasing Hormone in Male Rats and Rabbits. *Toxicological Sciences* 2000;53:92–92.
<https://doi.org/10.1093/toxsci/53.1.92>.
- [41] Balet L, Janett F, Hüsler J, Piechotta M, Howard R, Amatayakul-Chantler S, et al. Immunization against gonadotropin-releasing hormone in dairy cattle: Antibody titers, ovarian function, hormonal levels, and reversibility. *Journal of Dairy Science* 2014;97:2193–203.
<https://doi.org/10.3168/jds.2013-7602>.
- [42] Pinggera G-M, Mitterberger M, Bartsch G, Strasser H, Gradl J, Aigner F, et al. Assessment of the intratesticular resistive index by colour Doppler ultrasonography measurements as a predictor of spermatogenesis. *BJU International* 2008;101:722–6. <https://doi.org/10.1111/j.1464-410X.2007.07343.x>.

- [43] Zelli R, Troisi A, Elad Ngonput A, Cardinali L, Polisca A. Evaluation of testicular artery blood flow by Doppler ultrasonography as a predictor of spermatogenesis in the dog. *Research in Veterinary Science* 2013;95:632–7. <https://doi.org/10.1016/j.rvsc.2013.04.023>.
- [44] Biagiotti G, Cavallini G, Modenini F, Vitali G, Gianaroli L. Spermatogenesis and spectral echo-colour Doppler traces from the main testicular artery. *BJU International* 2002;90:903–8. <https://doi.org/10.1046/j.1464-410X.2002.03033.x>.
- [45] Pozor MA, Muehlhaus J, King A, Macpherson ML, Troedsson MH, Bailey CS. Effect of pentoxifylline treatment on testicular perfusion and semen quality in Miniature horse stallions. *Theriogenology* 2011;76:1027–35. <https://doi.org/10.1016/j.theriogenology.2011.05.005>.
- [46] Boyd A, Pozor M, Bailey C, Verstegen J. Effect of seasonality on testicular blood flow in mature stallions. *Animal Reproduction Science* 2006;94:144–5. <https://doi.org/10.1016/j.anireprosci.2006.03.089>.

Tables

Groups	Stallion	Age	Breed	Weight	Motive for consultation
Normal testicular function (control)	Stallion 1	10	Arabian	380 kg	Breeder
	Stallion 2	11	Pure Spanish Horse	420 kg	Breeder
	Stallion 3	8	Pure Spanish Horse	580 kg	Breeder
	Stallion 4	6	Pure Spanish Horse	620 kg	Freezing semen
	Stallion 5	12	Pure Spanish Horse	530 kg	Freezing semen
	Stallion 6	12	Anglo arabian	520 kg	Breeder
	Stallion 7	11	Pure Spanish Horse	490 kg	Breeder
	Stallion 8	8	Pure Spanish Horse	540 kg	Freezing semen
	Stallion 9	9	Anglo arabian	430 kg	Breeder
	Stallion 10	4	Pure Spanish Horse	350 kg	Pre-purchase reproductive examination
	Stallion 11	5	Spanish Arabian	410 kg	Breeder
	Stallion 12	5	Pure Spanish Horse	510 kg	Breeder
	Stallion 13	4	Pure Spanish Horse	490 kg	Breeder
	Stallion 14	15	Pure Spanish Horse	630 kg	Freezing semen
	Stallion 15	18	Pure Spanish Horse	420 kg	Breeder
	Stallion 16	6	Pure Spanish Horse	450 kg	Pre-purchase reproductive examination
	Stallion 17	12	Pure Spanish Horse	590 kg	Pre-purchase reproductive examination
	Stallion 18	7	Pure Spanish Horse	460 kg	Pre-purchase reproductive examination
	Stallion 19	13	Pure Spanish Horse	600 kg	Pre-purchase reproductive examination
	Stallion 20	6	Pure Spanish Horse	470 kg	Freezing semen
	Stallion 21	12	Pure Spanish Horse	590 kg	Freezing semen
Induced testicular dysfunction	Subfertile stallion 1	4	Pure Spanish Horse	430 kg	Acute transient problem (2 months from first immunization with Improvac)
	Subfertile stallion 2	4	Pure Spanish Horse	460 kg	Acute transient problem (2 months from first immunization with Improvac)
	Subfertile stallion 3	5	Spanish Arabian	420 kg	Acute transient problem (2 months from first immunization with Improvac)
	Subfertile stallion 4	4	Pure Spanish Horse	410 kg	Acute transient problem (2 months from first immunization with Improvac)
	Subfertile stallion 5	4	Pure Spanish Horse	450 kg	Acute transient problem (3 months from first immunization with Improvac)
	Subfertile stallion 6	5	Anglo arabian	410 kg	Acute transient problem (4 months from first immunization with Improvac)
	Subfertile stallion 7	4	Pure Spanish Horse	500 kg	Acute transient problem (6 months from first immunization with Improvac)
	Subfertile stallion 8	6	Pure Spanish Horse	450 kg	Acute transient problem (6 months from first immunization with Improvac)
	Subfertile stallion 9	4	Pure Spanish Horse	470 kg	Acute transient problem (8 months from first immunization with Improvac)
Acquired testicular dysfunction	Subfertile stallion 10	8	Pure Spanish Horse	520 kg	Idiopathic chronic problem (poor semen quality from 3 years ago)
	Subfertile stallion 11	18	Pure Spanish Horse	490 kg	Aging (poor semen quality from 1 years ago)
	Subfertile stallion 12	19	Spanish Sport Horse	450 kg	Aging (poor semen quality from 2 years ago)

TABLE 1: Summary table with data including age, breed, weight, and motive for consultation of individual stallions included in the study.

Sperm production	Control stallions		TD stallions (induced + acquired)		Induced TD stallions		Acquired TD stallions	
	Mean \pm SD	Minimum-maximum	Mean \pm SD	Minimum-maximum	Mean \pm SD	Minimum-maximum	Mean \pm SD	Minimum-maximum
DSOa (x 10⁶ spz)	5843 \pm 1699 ^a	4129-10505	1891 \pm 1409 ^b	398-4110	1230 \pm 867 ^{b,e}	398-2868	3874 \pm 215 ^{c,f}	3687-4110
DSOe (x 10⁶ spz)	5832 \pm 1650 ^a	3549-10560	2933 \pm 2026 ^b	694-7720	2041 \pm 1097 ^b	694-3996	5612 \pm 1849	4264-7720
TTV (cm³)	295 \pm 68.77 ^a	200-492	175 \pm 80.96 ^b	81-374	143.4 \pm 48.61 ^b	81-228	272.3 \pm 88.93	209-374
DSO/ml of testis (x10⁶ spz/ml)	19.86 \pm 3.48 ^a	14.65-27.8	10.56 \pm 5.68 ^b	2.09-18.31	9.00 \pm 5.28 ^b	2.09-16.67	15.24 \pm 4.68 ^d	9.85-18.31

TABLE 2: Measurement of actual Daily Sperm Output (DSOa), expected Daily Sperm Output (DSOe), total testicular volume (TTV) and spermatogenic efficiency (total n° of sperm at DSO/ml of the testis) in control stallions (stallions with normal testicular functionality and acceptable semen characteristics), stallions with testicular dysfunction (TD stallions (induced and acquired)), induced testicular dysfunction stallions (Induced TD stallions)(stallions immunized with anti-GnRH vaccine and with acute TD) and acquired testicular dysfunction stallions (acquired chronic TD stallions) . Values are presented as mean \pm standard deviation of the mean (SD) and minimum and maximum. DSO were expressed in millions of spermatozoa and TTV was expressed in cm³ and spermatogenic efficiency was expressed in millions of spermatozoa per ml of testis. Values with different superscripts differ between groups (a, b; $p \leq 0.0001$; a, c; $p \leq 0.001$; a, d; $p \leq 0.05$; e, f; $p \leq 0.05$).

	Control stallions	TD stallions	Induced TD stallions	Acquired TD stallions
Artery diameter (mm)	3.02 \pm 0.38^a	2.22 \pm 0.42^b	2.05 \pm 0.32^b	2.74 \pm 0.18
PI	1.15 \pm 0.24^a	1.08 \pm 0.48	0.83 \pm 0.18^b	1.58 \pm 0.41^b
RI	0.63 \pm 0.08^a	0.58 \pm 0.14	0.51 \pm 0.07^b	0.78 \pm 0.03^b

TABLE 3: Testicular artery diameters and Doppler indexes (PI: pulsatility index and RE: resistive index) obtained in controls stallions, stallions with testicular dysfunction (TD), stallions with induced TD (immunized with Improvac) and acquired TD stallions (mean values \pm standard deviation (SD)). Values with different superscripts differ between groups (a, b; $p \leq 0.001$).

Ecotext parameters	Control stallions	Induce TD stallions	Acquire TD stallions
	Mean \pm SD	Mean \pm SD	Mean \pm SD
Ecotext 1	2.82 \pm 2.52^a	2.17 \pm 3.44	0.11 \pm 0.17^b
Ecotext 2	388.00 \pm 368.2^a	320.9 \pm 359.7	1584.0 \pm 575.8^c
Ecotext 3	109.50 \pm 9.56^a	106.8 \pm 11.62	134.2 \pm 9.26^c
Tubular Density	132.10 \pm 16.35^a	116.2 \pm 8.59^b	92.35 \pm 11.24^c
Tubular Diameter	86.93 \pm 10.65^a	86.77 \pm 9.47	65.66 \pm 6.27^b
Tubular Area	5.40 \pm 1.90^a	4.71 \pm 1.17	2.14 \pm 0.59^b

TABLE 4: Ecotext parameters obtained in control stallion, induced testicular dysfunction (TD) stallions (horses immunized with Improvac) and acquired testicular dysfunction (TD) stallions (mean values \pm standard deviation (SD)): Ecotext 1 (black pixels), Ecotext 2 (white pixels) and Ecotext 3 (gray pixels). Tubular density (density of hypoechogenic areas (density of tubules/cm²), tubular area (percentage of hypoechogenic areas in the total area of the ROI) and tubular diameter (mean diameter of hypoechogenic areas (μ m)). Values with different superscripts differ between groups (a, b; $p \leq 0.001$; a,c; $p \leq 0.05$).

Correlations	Arterial diameter	PI	RI	PSV	TAMV	DSO/ml testis	TTV	TM	PM	DSOa	DSOe
ECOTEXT 1		-0.57**	-0.54**	-0.47*	-0.44*						
ECOTEXT 2		0.53**	0.52**	0.66***	0.63**	-0.50*					
ECOTEXT 3		0.62**	0.59**	0.56*							
Tubular density	0.44*	-0.60***	-0.47**	-0.43*			0.48**	0.51**	0.54**	0.51**	0.44**
Tubular area		-0.69***	-0.65***	-0.70***	-0.54**						-0.41*
Tubular diameter		-0.68***	-0.63***		-0.52**						

TABLE 5: Correlation obtained by Spearman's test between Ecotext parameters and those from the Doppler evaluation, seminal characteristics, and sperm production. PI: pulsatility index, RI: resistive index, PSV: Peak systolic velocity; TAMV: Time average maximum velocity, spermatogenic efficiency (Daily sperm output (DSO)/ml of the testis), TTV: total testicular volume, TM: Total motility, PM: progressive motility, DSOa: actual daily sperm output and DSOe: expected daily sperm output. * $p \leq 0.05$, ** $p \leq 0.001$, *** $p \leq 0.001$ and **** $p \leq 0.0001$

Figures

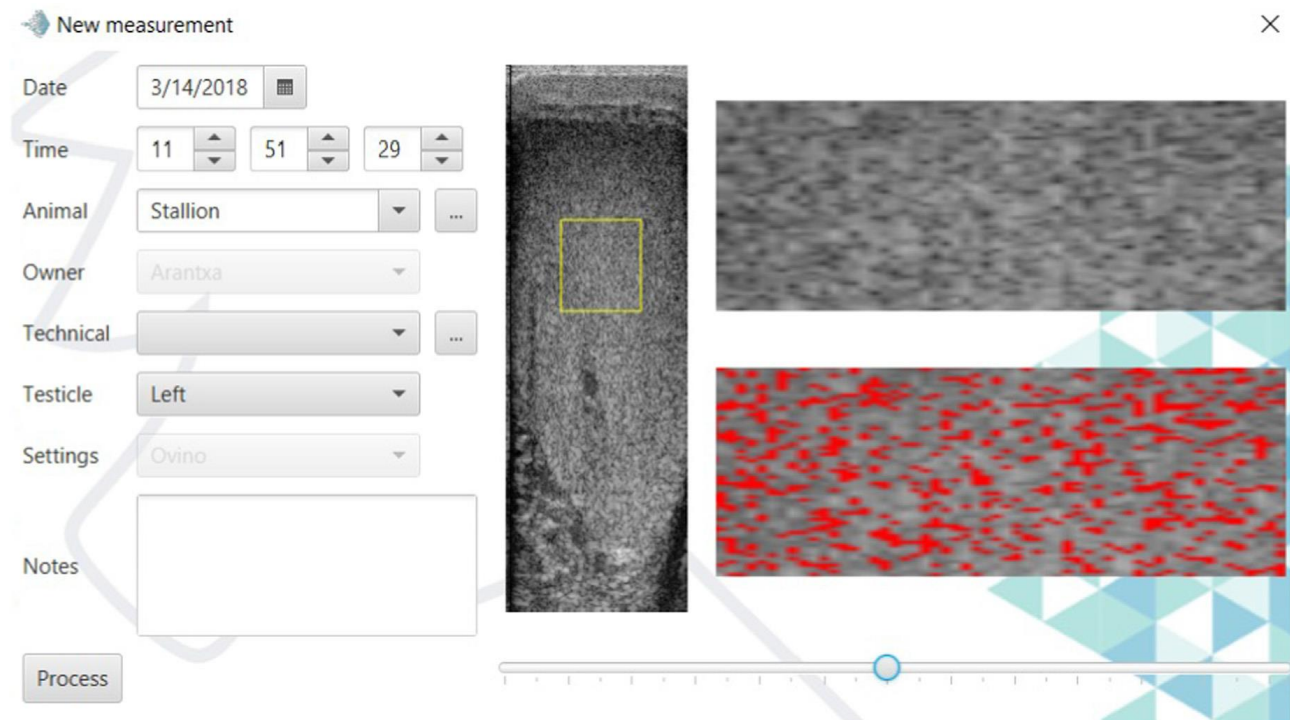


FIGURE 1: Screen capture of ECOTEXT software, showing the analysis of the left testicle of a stallion. To the left, a frame from a raw ultrasound video, with the area of the parenchyma analyzed (yellow square). To the right, a scaled image of the area analyzed (top) and another image with a binary mask of the hypoechoic areas (bottom).

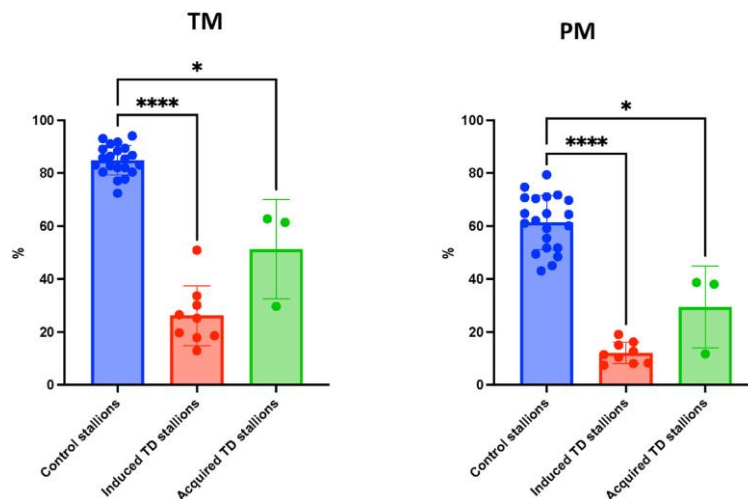


FIGURE 2: Graphs showing sperm motility (TM: total motility and PM: progressive motility) in control stallions, induced testicular dysfunction (TD) stallions and acquired testicular dysfunction (TD) stallions groups. Data for sperm motility and progressive motility are shown in a scatter plot (mean with standard deviation). The data are expressed in percentages (****; $p \leq 0.0001$; *; $p \leq 0.05$).

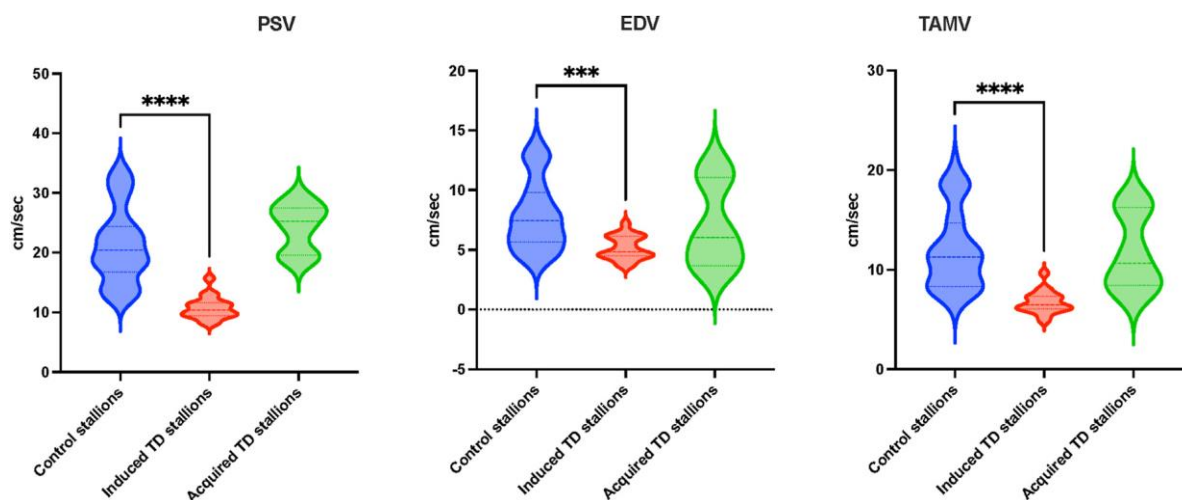


FIGURE 3: Doppler velocity parameters (PSV: peak systolic velocity, EDV: end diastolic velocity and TAMV: time average maximum velocity) from control stallions, induced testicular dysfunction (TD) stallions and acquired testicular dysfunction (TD) stallions are shown in a violin plot (mean with standard deviation). The values are expressed in cm/second. Differences between controls and induced TD group were ****; $p \leq 0.0001$ and ***; $p \leq 0.001$.

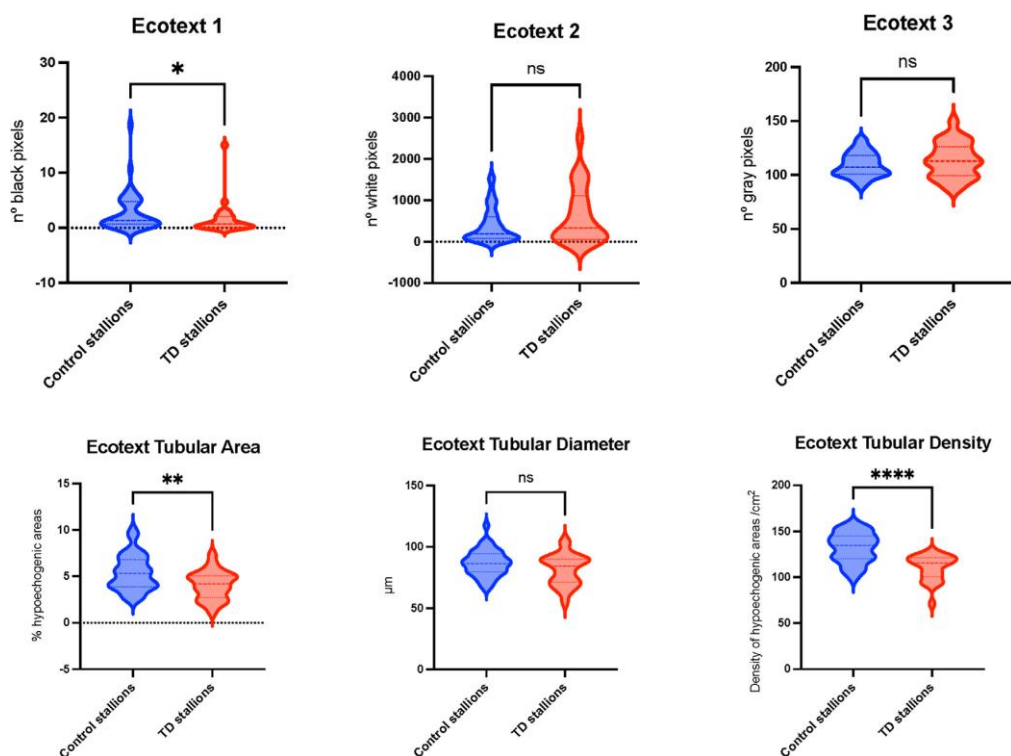


FIGURE 4: Ecotext parameters (Ecotext 1(black pixels), Ecotext 2(white pixels), Ecotext 3(grey pixels), Ecotext tubular area (percentage of hypoechoic areas), Ecotext tubular diameter (micrometers) and Ecotext tubular density (density of hypoechoic areas/cm²) from control stallions and testicular dysfunction (TD) stallions are shown in a violin plot (mean with standard deviation). Differences between both groups were ****; $p \leq 0.0001$, **; $p \leq 0.01$ and *; $p \leq 0.05$.

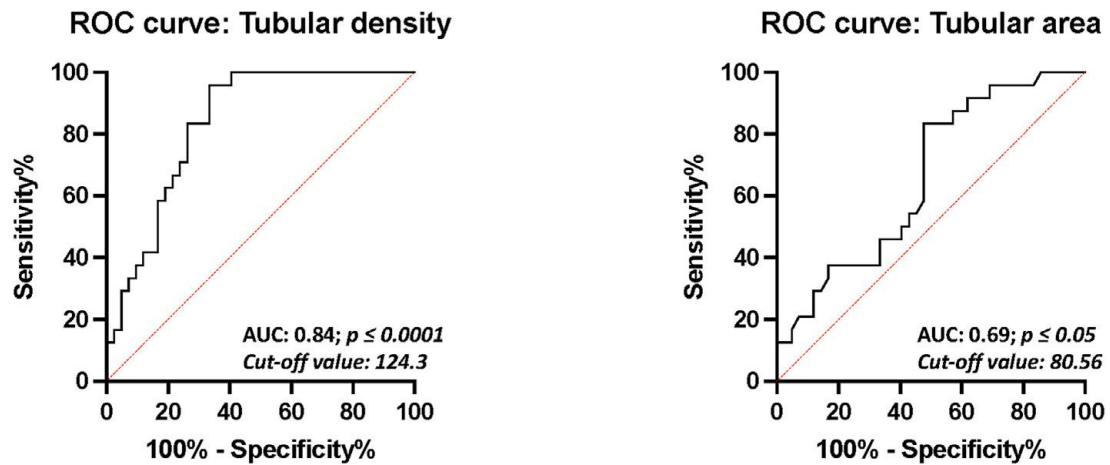


FIGURE 5: Receiver operating characteristic (ROC) curves for the tubular density and tubular area. AUC: Area under the curve. Cut-off value calculated with Youden's J statistics.

Appendix A. Supplementary data

The following is the supplementary data to this article:

Groups	Stallion	TTV (ml)	DSO/ml testis	DSOe	DSOa	TM (%)	PM (%)	Nº Total PM
Normal testicular function	Stallion 1	236	18,15	4401	4283	87	71	3041,17
	Stallion 2	301	15,75	5968	4740	91	75	3555,00
	Stallion 3	284	18,48	5545	5249	82	43	2256,93
	Stallion 4	269	17,63	5193	4744	94	70	3320,57
	Stallion 5	274	15,07	5310	4129	72	49	2023,05
	Stallion 6	273	17,79	5291	4857	92	79	3837,29
	Stallion 7	383	14,65	7926	5609	80	61	3421,69
	Stallion 8	319	15,54	6387	4956	83	70	3469,43
	Stallion 9	263	22,28	5047	5859	83	72	4218,48
	Stallion 10	234	18,16	4351	4249	93	64	2719,57
	Stallion 11	298	18,53	5902	5522	89	65	3589,08
	Stallion 12	271	20,18	5255	5468	83	65	3554,42
	Stallion 13	366	19,63	7513	7186	78	48	3449,28
	Stallion 14	200	27,81	3549	5561	88	60	3336,80
	Stallion 15	284	19,79	5552	5621	89	71	3990,91
	Stallion 16	201	21,51	3564	4323	85	62	2680,47
	Stallion 17	314	22,37	6272	7024	77	55	3863,38
	Stallion 18	268	22,71	5175	6087	86	59	3591,13
	Stallion 19	405	24,48	8466	9915	86	51	5056,48
	Stallion 20	271	25,18	5245	6823	82	45	3070,50
	Stallion 21	492	21,35	10560	10505	80	52	5462,77
Induced testicular dysfunction	Subfertile stallion 1	172	16,67	3368	2868	20	10	298,27
	Subfertile stallion 2	198	11,36	3996	2249	25	13	283,96
	Subfertile stallion 3	108	12,38	1503	1337	51	19	254,20
	Subfertile stallion 4	106	12,18	1991	1291	34	16	209,09
	Subfertile stallion 5	110	12,60	1802	1386	19	8	113,19
	Subfertile stallion 6	81	7,99	694	647	18	8	51,76
	Subfertile stallion 7	228	2,09	2493	477	13	7	35,46
	Subfertile stallion 8	156	2,55	1402	398	30	15	59,83
	Subfertile stallion 9	132	3,16	2400	417	27	11	47,50
Acquire testicular dysfunction	Subfertile stallion 10	209	18,31	4264	3827	30	12	446,44
	Subfertile stallion 11	234	17,56	4851	4110	60	39	1589,07
	Subfertile stallion 12	374	9,85	7720	3687	87	48	1769,60