


A novel drainage strategy using chest tube plus pleural catheter in uniportal upper lobectomy: A randomized controlled trial

Fu Yang¹  | Xing Wang^{1,2} | Honglei Xu² | Beatrice Aramini³ | Yuming Zhu² | Gening Jiang² | Jiang Fan^{1,2}

¹Department of Thoracic Surgery, Shanghai Jiao Tong University First People's Hospital, Shanghai, China

²Department of Thoracic Surgery, Shanghai Tongji University Affiliated Shanghai Pulmonary Hospital, Shanghai, China

³Division of Thoracic Surgery, G.B. Morgagni-L. Pierantoni Hospital, University of Bologna, Forli, Italy

Correspondence

Jiang Fan, Department of Thoracic Surgery, Shanghai Jiaotong University First People's Hospital, Shanghai 200080, China.
Email: fan_jiang@tongji.edu.cn

Funding information

National Natural Science Foundation of China, Grant/Award Number: 81870008; Shanghai Municipal Health Commission, Grant/Award Number: 201840175

Abstract

Background: In this study we explored whether one pleural catheter plus single chest tube drainage could achieve a noninferior drainage effect when compared with the traditional two chest tubes in uniportal video-assisted thoracoscopic surgery (VATS) for an upper pulmonary lobectomy.

Methods: Patients that underwent an upper pulmonary lobectomy from January to November 2020 were enrolled in this single-center, randomized, open-label, noninferiority trial. Prior to closure, patients were randomized to an intervention group who received an improved drainage strategy involving one pleural catheter with one chest tube (24 Fr), while traditional double chest tube drainage was applied for the control group.

Results: A total of 390 patients entered the study, although 190 were excluded for changing nonuniportal surgical approaches or opting for nonlobectomy resections. Finally, 200 patients were randomized (100 in the intervention group and 100 in the control group). The baseline demographic and clinical characteristics were comparable between the groups. The incidence of pneumothorax in the intervention and control groups was similar on postoperative Day 1 (noninferiority, 10% vs. 13%, $p = 0.658$). In addition, there were no significant differences in secondary outcomes such as incidence of pneumothorax by Day 30, postoperative chest tube/pleural catheter removal time, amount of drainage on Day 1, total amount of drainage after operation, or postoperative hospitalization. A significantly lower pain score was observed in the intervention group (3.33 ± 0.68 vs. 3.68 ± 0.94 , $p = 0.003$).

Conclusions: The new strategy is noninferior to double chest tube drainage after an upper pulmonary lobectomy offers superior pain control, and is recommended for an upper lobectomy by uniportal VATS.

KEYWORDS

chest tube, pleural catheter, uniportal video-assisted thoracoscopic surgery, upper lobectomy

INTRODUCTION

Lung cancer is the leading cause of cancer-related deaths in China.^{1,2} Several surgical techniques are currently used as part of the standard of care for early-stage lung cancer, including wedge resection, segmentectomy, lobectomy, and pneumonectomy.³ Lobectomy has been considered the standard care for early-stage non-small cell lung cancer (NSCLC) since randomized trial was carried out by the Lung

Cancer Study Group (LCSG) in 1995.⁴ Inadequate re-expansion of the residual lung is one of the most important causes of morbidity following lung resection and may instigate postoperative pleural effusion, persistent air leak, or atelectasis. The traditional chest drainage method after a lobectomy is via two drainage tubes: one in the posterior and basilar region to drain fluid and the other directed toward the apex of the thoracic cavity to remove air from the chest.^{5,6} Although the two-tube strategy is effective and

widely accepted, it is painful for patients. Theoretically, a single chest tube drainage strategy can reduce the pain level and discomfort after surgery, as long as the drainage tube is placed below the seventh or eighth intercostal space.

In recent years, the development of uniportal video-assisted thoracic surgery (VATS) has further reduced the trauma associated with a lobectomy, with similar safety and feasibility compared with that of two- or three-port VATS. However, drainage strategy and other issues still need further exploration for the uniportal VATS lobectomy. The incision for uniportal VATS lobectomy is usually placed in the fourth or fifth intercostal space between the midaxillary and anterior axillary lines. Single tube drainage through a single port has the possibility of inadequate chest drainage, resulting in pneumothorax and poor lung re-expansion as it can hardly balance the apical position and posterior and basilar region. After an upper pulmonary lobectomy, the cavity needs to be filled by means of the full recruitment of the remaining lobes and elevation of the ipsilateral diaphragm, which places higher demand on the success of the strategy of the drainage tube, in theory. Most randomized trials have demonstrated that there is no significant difference in the drainage effect after a lobectomy between patients with a single chest tube and those with double chest tubes by standard thoracotomy or by two- or three-port VATS;⁷⁻⁹ however, no conclusion has been reached in relation to uniportal VATS lobectomies.

A pleural catheter is a kind of single lumen central venous catheter which is routinely used for rehydration or central venous pressure. It has previously been demonstrated that a pleural catheter (CVC) has an equivalent drainage effect and is associated with less pain than a traditional chest tube for selected thoracoscopic wedge resections.^{10,11} In this study, we conducted a prospective, randomized, noninferiority trial to verify the hypothesis that a CVC combined with chest tube drainage after a uniportal VATS upper pulmonary lobectomy does not increase the incidence of perioperative complications when compared with the traditional double chest tube drainage.

METHODS

Study design

This prospective, single-center, randomized, open-label, noninferiority trial was approved by the Institutional Review Board of Shanghai Pulmonary Hospital (L20-289), and was registered at www.clinicaltrials.gov on July 8, 2020 (registration no: NCT04461652, principal investigator: Jiang Fan). No changes were made to the methods, type of randomization, study outcomes, or eligibility criteria after trial commencement. All participants provided written informed consent before the study.

Participants

We screened adults aged from 18 to 75 years old who were scheduled for uniportal thoracoscopic left or right upper lobectomy at the Shanghai Pulmonary Hospital. All patients learned about the two kinds of operation through preoperative education, and voluntarily joined the research group and signed the ethical agreement. The preoperative exclusion criteria were as follows: (i) Preoperative presence of any unstable systemic disease, such as active infection, uncontrolled hypertension, ineffective blood sugar control in diabetes mellitus, recent history of cerebral or myocardial infarction, and so on; (ii) previous ipsilateral thoracic surgery; (iii) preoperative pneumonia or atelectasis as found by imaging examinations; (iv) coagulation disorders and bleeding tendency and (v) pregnancy or breastfeeding. Just before placing the chest tube(s) for postoperative drainage, a final judgment on registration was performed. Patients were excluded if they required wedge resection or extended lobectomy, exploratory or open-chest surgery, or conversion to pneumonectomy; if severe pleural adhesion was observed during surgery, or if they showed obvious pulmonary/bronchi air leaks during the air-tightness leak test. Finally, the remaining patients were fully registered.

Randomization

This was a two-armed parallel clinical trial with a 1:1 allocation ratio. Prior to closure (before chest tube placing), a member of the research team randomly assigned the patients to the intervention group (improved drainage, ID, CVC plus one chest tube) or control group (double-tube drainage, DD, two chest tubes) via randomization codes that were computer-generated using the PLAN procedure in SAS statistical software (SAS Institute) through simple random sampling. Neither patients nor investigators were blinded to group assignment. The pain assessment team, postoperative management personnel, and follow-up evaluators did not know the grouping of each patient.

Procedure

All participants were scheduled to undergo a uniportal video-assisted thoracoscopic lobectomy. A single port ranging from 3 to 4 cm was placed in the fourth or fifth intercostal space. All operations were performed by three surgical teams led by Fan, Zhu, and Wu. Only two types of lobectomies (left upper lobectomy and right upper lobectomy) were approved in this trial.

All patients received anesthesia with endotracheal intubation and were placed in the lateral position. If the issues mentioned above were encountered during surgery, the participants were excluded from the study and received double-chest-tube drainage. On completion of the upper lobectomy,

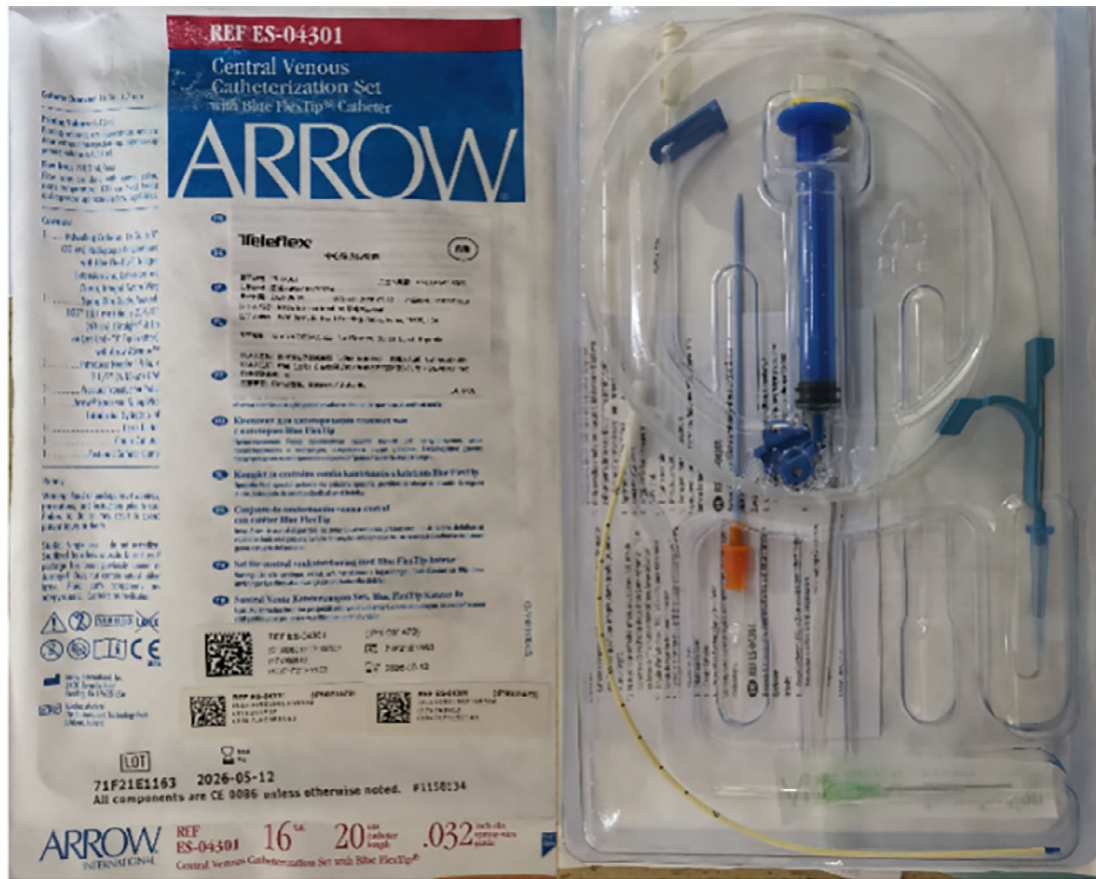

FIGURE 1 Single-lumen central venous catheter (16 Ga × 20 cm)

randomization was carried out. After the patients were assigned to the ID or DD group, the investigators implemented the assigned drainage strategy. In the ID group, one thoracic tube (24-Fr drainage tube) was inserted via an intercostal incision to the thoracic apex, and one CVC (single-lumen central venous catheter, 16Ga × 20 cm, Arrow International Inc. Figure 1) was punctured through the seventh or eighth intercostal space at the posterior axillary line to the cardiophrenic angle (Figure 2a, c, e). In the DD group, two conventional chest tubes (24-Fr) were placed through intercostal incision for drainage (Figure 2b, d); one tube was placed at the bottom and the other was placed at the apex. The conventional chest tubes were connected to the water-seal bottle, while the central venous catheter was connected to the drainage bag. All surgical incisions were closed using 2–0 and 3–0 vicryl continuous sutures (Ethicon). Patients were extubated and transferred directly to the surgical ward following stabilization in the post-anesthesia care unit. No masking of investigators to treatment allocation was performed.

For analgesia, patient-control intravenous analgesia (PCIA) was used for three days after the operation. Some oral analgesics were also administered based on the requirements of the patients. All patients underwent chest radiography on the morning after the day of surgery. Lung compression of more than 50% is considered as massive

pneumothorax. If massive pneumothorax was observed, the following steps were considered: enhanced deep breathing and cough exercises or 8–10 cm H₂O negative pressure suction via chest tube. Follow-up chest radiography was carried out every other day until chest tube/CVC removed. The indications for chest tube/CVC removal were as follows in both groups: adequate lung expansion, absence of air leaks, and 200 ml/day or less drainage fluid. Chest radiography was also carried out about one month after the surgery to evaluate the postoperative recovery of the patients.

Sample size

The trial was designed to test the hypothesis that the new strategy is not inferior to the traditional method in a uniport VATS upper pulmonary lobectomy with respect to the incidence of pneumothorax (primary outcome). Based on previous observational studies,^{7,9,12} the probabilities of postoperative pneumothorax with the new method (ID) and traditional method (DD) were about 10 and 6%, respectively. Considering a 25% noninferiority margin, efficacy analysis estimated that 75 patients in each group were required to achieve a power of 0.99 (via version 15.0; NCSs, Kaysville, UT, USA) with a unilateral α of 0.025. Before dropouts from the groups due to clinical factors or other criteria

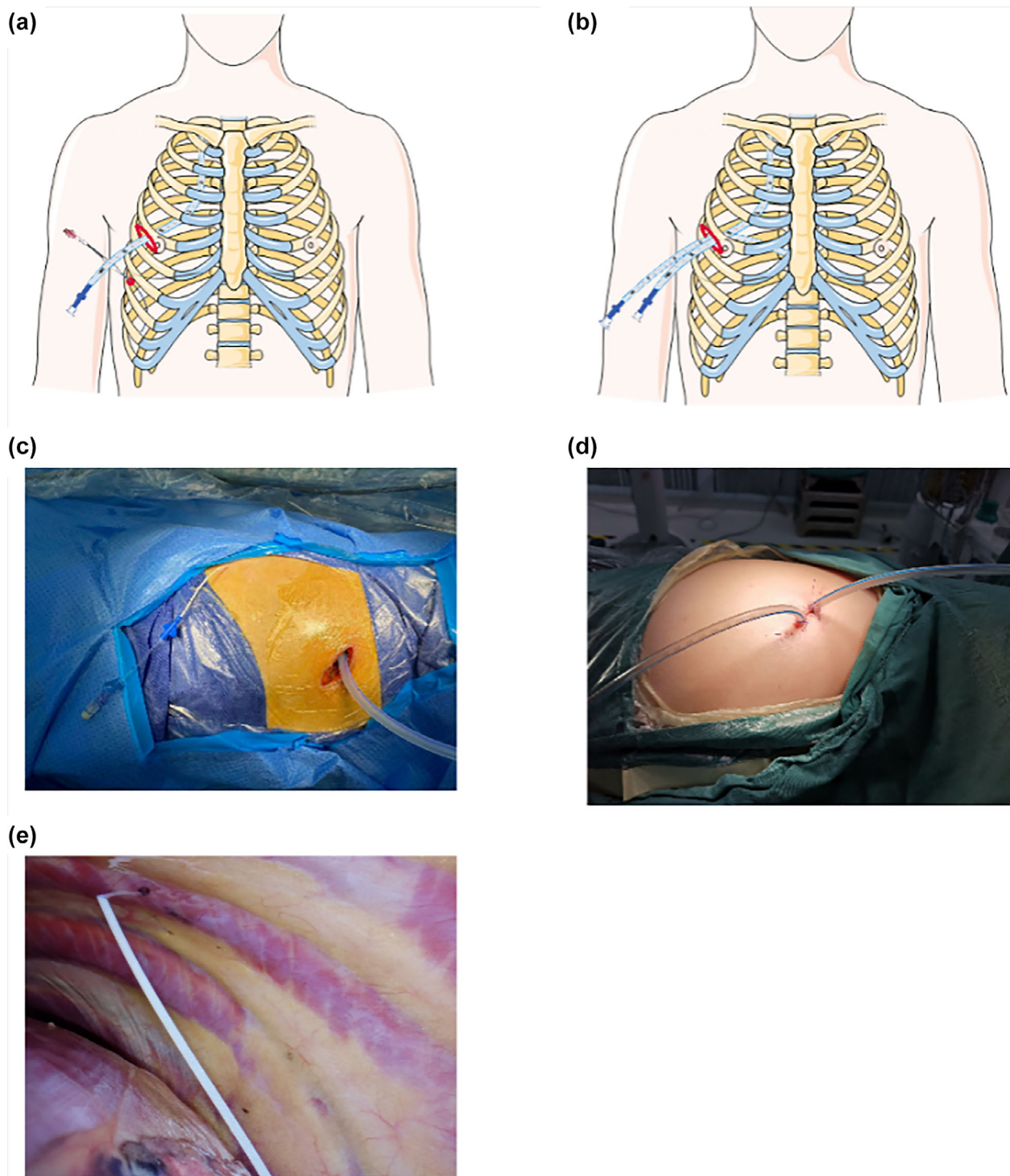


FIGURE 2 Improved drainage used CVC plus one chest tube and double drainage used two chest tubes after upper pulmonary lobectomy. (a) Schematic diagram showing the CVC and chest tube in the improved drainage. (b) Schematic diagram showing the two chest tubes in the double drainage. (c) Insertion of the CVC plus one chest tube. (d) Insertion of the two chest tubes through incision. (e) Location of the CVC in the thoracic cavity

(e.g., changing surgical methods according to pathological results during operation, combination with another lobectomy, etc.), a total of 195 subjects in each group were required, with 390 as the anticipated case number.

The Consolidated Standards of Reporting Trials flow-chart (CONSORT) is shown in Figure 3.

Primary outcome

All study data were collected by nurses and researchers who were not blinded to the group assignment. Baseline patient characteristics were recorded, along with perioperative details. The primary outcome was to assess the incidence of

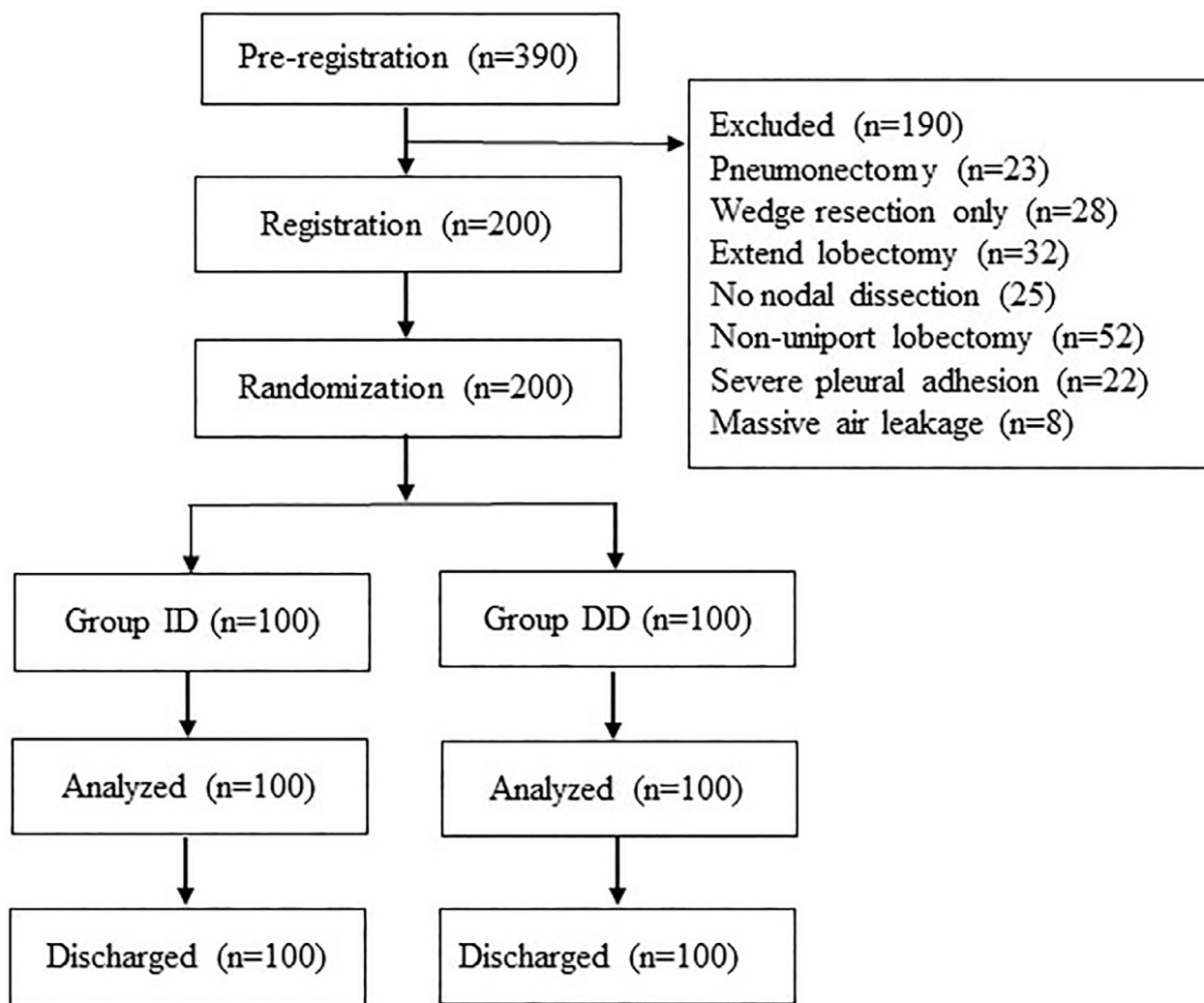


FIGURE 3 Consolidated Standards of Reporting Trials (CONSORT) flow diagram. DD, double drainage; ID, improved drainage

pneumothorax on Day 1 after surgery in both groups. Pneumothorax was defined by a distance of ≥ 3 cm between the apex of the lung and the top of the rib cage on chest radiography.^{13,14}

Secondary outcomes

The secondary outcomes for patients' recovery included visual analog scale (VAS) scores for postoperative pain, postoperative chest tube/CVC removal time, the total volume of pleural effusion on the first day after the operation, and postoperative hospitalization. The perioperative complications were also noted, such as pleural effusion, respiratory infection, or subcutaneous emphysema. Additional clinical outcomes were drainage tube-related complications such as obstructed drainage, chest tube reinsertion, and wound healing.

Postoperative pain was evaluated on Days 1 and 3 after surgery using the VAS, where 0 indicates no pain and 10 indicates the most serious pain.^{15,16} Pleural effusion was defined as a drainage volume of >800 ml. Respiratory infection was defined by a leukocyte count higher than

$10 \times 10^9/l$ or lower than $4 \times 10^9/l$, with the body temperature higher than 38.3°C , symptoms of respiratory system-like purulent sputum, and the use of additional antibiotic therapy. The time to postoperative chest tube removal was defined as the number of days following surgery to the removal of the chest tube. The length of postoperative hospitalization was defined as the number of days from surgery to discharge. Subcutaneous emphysema was graded into three levels: none, observation required, and intervention required. Wound healing was evaluated by the surgeon and nurses after surgery, and graded as normal, delayed healing, or incision infection, according to the status of the drainage tube incision. Delayed healing and incision infection were classified as unsatisfactory wound healing.

Statistical analysis

The categorical variables are reported as counts and percentages and were compared using the chi-square (χ^2), or Fisher's exact test if two of the frequency cells were smaller than

five. The continuous variables are reported as the mean \pm standard deviation (SD) and were compared using the Kruskal–Wallis test. For the incidence of pneumothorax (primary outcome), the one-sided 97.5% ($1-\alpha$) confidence interval (CI) of the risk difference was compared with the prespecified noninferiority margin of 25%. The secondary outcomes were two-sided. A p -value less than 0.05 was considered statistically significant. All statistical analyses were performed using the IBM statistical package for social sciences (SPSS) version 22.0 (IBM Corp.).

RESULTS

Patient general characteristics

According to the inclusion and exclusion criteria, a total of 390 consecutive patients were screened between January and November 2020, with all patients providing written consent. After surgery, 190 patients were excluded due to changing to nonuniportal VATS surgical approaches, nonlobectomy resections, or other excluded criteria mentioned above. Finally, 200 patients were enrolled and allocated to the ID ($n = 100$) and DD ($n = 100$) groups according to the drainage strategies used. In the ID group, 53 patients (53%) underwent a right upper lobectomy while the others had a left upper lobectomy; all of them received the allocated intervention. In the DD group, 60 patients (60%) underwent a right upper lobectomy. The demographic, clinical, operative, and imaging characteristics of both groups were balanced, and are shown in Table 1.

TABLE 1 Baseline characteristics of patients who received improved drainage strategy (ID group) or double drainage strategy (DD group) after upper pulmonary lobectomy.

Variables	ID group ($n = 100$)	DD group ($n = 100$)	p -value
Age	58.74 \pm 9.39	59.13 \pm 9.30	0.768
Sex			0.480
Male	53	47	
Female	47	53	
Smoking status			0.596
Never smokers	78	82	
Current or ever smokers	22	18	
BMI (kg/m ²)	23.98 \pm 3.05	23.67 \pm 3.60	0.511
Chronic disease			0.420
Present	29	23	
Absent	71	77	
Operative side			0.392
Right	53	60	
Left	47	40	

Abbreviations: BMI, body mass index; DD, double drainage; ID, improve drainage.

Primary outcome

The detailed data of the primary outcome are presented in Table 2. In the ID group, the incidence of pneumothorax on Day 1 after surgery was 10.0% while the incidence of pneumothorax on Day 1 after surgery was 13.0% in the DD group (hazard ratio: ID vs. DD, 0.97; 95% confidence interval, 0.88–1.07; $p = 0.658$). Noninferiority was observed ($p = 0.25$, one-sided for noninferiority) as the upper 95% confidence interval of 1.07 was smaller than the prespecified noninferiority margin of 1.25. There was also no significant difference in pneumothorax after 30 days between both groups (0.00% vs. 2.00%, $p = 0.497$).

Secondary outcomes

Postoperative complications

Table 2 provides the results for additional postoperative complications. No significant differences were identified between the two groups in terms of drainage tube blocks, pleural effusion in the 30 days after the operation, chest tube reinsertion after drain removal, wound healing, amount of drainage, duration of drainage, and postoperative hospitalization. Thirty days after the operation, 25 patients (25%) had pleural effusion in the ID group, while 24 patients (24.00%) had pleural effusion in the DD group. No one in the ID group needed chest tube reinsertion because of pleural effusion or pneumothorax. Two patients (2%) in the DD group required chest tube reinsertion because of pleural effusion. There were no statistically significant differences in the amount/duration of drainage between the two groups. One patient in the ID group experienced postoperative bleeding, while two patients in the DD group experienced postoperative bleeding. Some measures, for example, chest radiography, blood routine examination and unblocking a drainage tube postoperatively, enabled hemothorax to be accurately assessed in both groups.

Others

The VAS pain score was significantly lower in the ID than in the DD group on the first day after surgery (3.33 ± 0.68 vs. 3.68 ± 0.94 , $p = 0.003$). On the third day after surgery, no significant difference was detected in the VAS pain scores between the groups, although the VAS scores in the ID group tended to be lower than those in the DD group (2.27 ± 0.58 vs. 2.45 ± 0.74 , $p = 0.058$).

DISCUSSION

Inappropriate re-expansion of the residual lungs after a lobectomy is one of the most important causes of complication after surgery. Sufficient re-expansion is essential to

TABLE 2 Perioperative characteristics of patients who received improved drainage strategy (ID group) or double drainage strategy (DD group) after upper pulmonary lobectomy

Variables	ID group (n = 100)	DD group (n = 100)	95% CI	p-value
Pneumothorax (a line ≥ 3 cm, 1 day after operation)	10 (10.00%)	13 (13.00%)		0.658
Pneumothorax (a line ≥ 3 cm, 30 days after operation)	0 (0.00%)	2 (2.00%)		0.497
Drainage tube blocked	3 (3.00%)	2 (2.00%)		1.000
Pleural effusion (Day 30)	25 (25.00%)	24 (24.00%)		1.000
Chest tube reinsertion	0 (0.00%)	2 (2.00%)		0.497
Unsatisfied wound healing	9 (9.00%)	8 (8.00%)		1.000
Amount of drainage on Day 1 (ml)	204.60 \pm 147.49	194.50 \pm 201.46	-59.34 to 39.14	0.686
Amount of drainage (ml)	881.05 \pm 708.65	743.60 \pm 517.80	-310.53 to 35.63	0.119
Duration of drainage (days)	4.42 \pm 1.99	4.15 \pm 1.35	-0.74 to 0.20	0.262
Postoperative hospitalization (days)	5.22 \pm 2.20	5.12 \pm 1.38	-0.61 to 0.41	0.701
VAS score (Day 1)	3.33 \pm 0.68	3.68 \pm 0.94	0.12 to 0.58	0.003
VAS score (Day 3)	2.27 \pm 0.58	2.45 \pm 0.74	-0.01 to 0.37	0.058

Abbreviations: 95% CI, 95% confidence interval; DD, double drainage; ID, improved drainage; VAS, visual analog scale.

avoid atelectasis, persistent air leakage, postoperative hemothorax, acute respiratory insufficiency, and hypoxemia.¹⁷ The classical and widely accepted practice is to use two drainage tubes for complete drainage of the pleural cavity after a pulmonary lobectomy. One tube is placed into the posterior and basilar region to drain fluid, while the other tube is placed through the anterior axillary line, directed toward the apex, to remove air from the chest.^{5,6}

Although drainage with two chest tubes is effective and widely accepted, it is painful for patients. Theoretically, single-chest-tube drainage causes less pain and discomfort for patients compared with double-tube drainage but has the possibility of insufficient drainage. In recent years, more and more thoracic surgeons have tried the drainage strategy of using one chest tube after a pulmonary lobectomy. Several studies have reported comparisons of chest drainage approaches with one or two chest tubes after a pulmonary lobectomy;^{12,18–21} however, most of the patients in the studies received pulmonary lobectomies via standard thoracotomy. As such, the previous research cannot perfectly represent patients treated by VATS, especially by uniportal VATS. The incision for a uniportal VATS lobectomy is usually placed in the fourth or fifth intercostal space. Single-tube drainage through a single port can lead to inadequate chest drainage, resulting in pneumothorax and poor lung recruitment. If the tube is placed from the uniportal toward the apical position, pleural fluid located in the posterior and basilar region cannot be easily drained. On the other hand, if it is placed from the uniportal into the posterior and basilar region, the air in the apex cannot be easily drained, especially in the case of an upper pulmonary lobectomy.

In the present study, a new strategy of drainage (ID) was introduced with one chest tube plus a CVC for the upper pulmonary lobectomy. To the best of our knowledge, this study is the first prospective randomized clinical trial to compare an improved drainage strategy with routine double-chest-tube drainage after an upper pulmonary

lobectomy by uniportal VATS. We randomly assigned 200 patients to either the ID or DD group. The results of the analysis demonstrated that the clinical outcome of the improved drainage strategy was noninferior to that of routine double-chest-tube drainage, as determined by the occurrence of pneumothorax on Day 1 after surgery as the primary endpoint. One month later, there was no significant difference in the incidence of pleural effusion between the two groups. Moreover, there were no significant differences in the amount/duration of drainage or the incidence of perioperative events. The significant difference between the two groups was the VAS pain score, which was significantly lower in the ID group. We recorded the pain intensities of patients twice on Days 1 and 3 after surgery. On the first day, the mean pain score was 3.33 in the ID group, while it was 3.68 in the DD group ($p = 0.003$). On the third day, the pain score tended to be lower in the ID group, although the difference was not significant ($p = 0.058$). These findings are in agreement with the results of previous studies,^{7,9,22} which have shown lesser postoperative pain with one chest tube. Accordingly, we believe that the use of one chest tube plus a CVC, as an improved drainage strategy for patients undergoing a uniportal VATS lobectomy, presents a safe and feasible strategy during the procedure in clinical practice. The results are comparable with the findings of the study reported by Yang et al.²³ which found that a small-bore pigtail catheter plus one conventional chest tube was sufficient for single incision thoracoscopic lobectomy for lung cancer. However, the diameter of a pigtail catheter is thicker than that of a single lumen CVC. We prefer the single lumen CVC which is sufficient.

Our present study differs from previous studies that have compared a single chest tube with two chest tubes in its study population and method. All of our study population received a uniportal upper lobectomy; as such, our finding is that the improved drainage strategy may be the optimal choice for the upper lobectomy.

We acknowledge that the present trial has certain limitations that should be addressed. First, it was a single-center study. The single-institution setting renders observations more susceptible to the potential effects of institution-specific practices. Second, it was difficult to accurately assess the pleural effusion on the first day after surgery as some patients received supine chest radiography in the medical intensive care unit. Therefore, we compared the pleural effusion one month after surgery between the two groups. Third, we recognize that the lack of blinding to patients and researchers may cause an information bias affecting the interpretation of the results making it difficult to quantify.

In conclusion, the improved drainage strategy with one chest tube plus a CVC is a safe procedure for patients after a uniportal VATS upper pulmonary lobectomy and is likely to be less painful for patients.

AUTHOR CONTRIBUTIONS

FY performed statistical analysis and drafted the work. XW organized the figures and tables. HX collected the data. BA checked the results of the statistical analysis. YZ performed the data check. GJ substantively revised the draft. JF contributed to conception and approved it for publication.

CONFLICT OF INTEREST

The authors declare that there is no conflict of interest.

DATA AVAILABILITY STATEMENT

The datasets used and analyzed during the current study are not publicly available due to privacy issues but are available from the corresponding author on reasonable request.

ORCID

Fu Yang  <https://orcid.org/0000-0003-3752-4871>

REFERENCES

- Sung H, Ferlay J, Siegel RL, Laversanne M, Soerjomataram I, Jemal A, et al. Global Cancer Statistics 2020: GLOBOCAN Estimates of Incidence and Mortality Worldwide for 36 Cancers in 185 Countries. *CA Cancer J Clin*. 2021;71(3):209–49.
- Cao M, Li H, Sun D, Chen W. Cancer burden of major cancers in China: A need for sustainable actions. *Cancer Commun (Lond)*. 2020;40(5):205–10.
- Manser R, Wright G, Hart D, Byrnes G, Campbell DA. Surgery for early stage non-small cell lung cancer. *Cochrane Database Syst Rev*. 2010;2005(1):CD004699.
- Ginsberg RJ, Rubinstein LV. Randomized trial of lobectomy versus limited resection for T1 N0 non-small cell lung cancer. Lung Cancer Study Group. *Ann Thorac Surg*. 1995;60(3):615–22. discussion 622–613.
- Fell SCKT. Technical aspects of lobectomy. In: Shields TW, Locicero J, Ponn RB, Rusch VW, editors. *General Thoracic Surgery*. Philadelphia: Lippincott Williams and Wilkins; 2006. p. 433–57.
- Mattioli S, Berrisford RG, Lugaresi ML, Aramini B. Survey on chest drainage systems adopted in Europe. *Interact Cardiovasc Thorac Surg*. 2008;7(6):1155–9.
- Gomez-Caro A, Roca MJ, Torres J, Cascales P, Terol E, Castaner J, et al. Successful use of a single chest drain postlobectomy instead of two classical drains: a randomized study. *Eur J Cardiothorac Surg*. 2006;29(4):562–6.
- Tanaka M, Sagawa M, Usuda K, Machida Y, Ueno M, Motono N, et al. Postoperative Drainage with One Chest Tube Is Appropriate for Pulmonary Lobectomy: A Randomized Trial. *Tohoku J Exp Med*. 2014;232(1):55–61.
- Okur E, Baysungur V, Tezel C, Sevilgen G, Ergene G, Gokce M, et al. Comparison of the single or double chest tube applications after pulmonary lobectomies. *Eur J Cardiothorac Surg*. 2009;35(1):32–5. discussion 35–36.
- Zhang JT, Tang YC, Lin JT, Dong S, Nie Q, Jiang BY, et al. Prophylactic air-extraction strategy after thoroscopic wedge resection. *Thorac Cancer*. 2018;9(11):1406–12.
- Zhang JT, Dong S, Chu XP, Lin SM, Yu RY, Jiang BY, et al. Randomized Trial of an Improved Drainage Strategy Versus Routine Chest Tube After Lung Wedge Resection. *Ann Thorac Surg*. 2020;109(4):1040–6.
- Zhang X, Lv D, Li M, Sun G, Liu C. The single chest tube versus double chest tube application after pulmonary lobectomy: A systematic review and meta-analysis. *J Cancer Res Ther*. 2016;12(Supplement):C309–16.
- Baumann MH, Strange C, Heffner JE, Light R, Kirby TJ, Klein J, et al. Management of spontaneous pneumothorax: an American College of Chest Physicians Delphi consensus statement. *Chest*. 2001;119(2):590–602.
- Haynes D, Baumann MH. Management of pneumothorax. *Semin Respir Crit Care Med*. 2010;31(6):769–80.
- Breivik H, Borchgrevink PC, Allen SM, Rosseland LA, Romundstad L, Hals EK, et al. Assessment of pain. *Br J Anaesth*. 2008;101(1):17–24.
- Sekiyama H. Pain intensity scales and assessment of cancer pain. *Masui*. 2011;60(9):1053–8.
- Kim EA, Lee KS, Shim YM, Kim J, Kim K, Kim TS, et al. Radiographic and CT findings in complications following pulmonary resection. *Radiographics*. 2002;22(1):67–86.
- Alex J, Ansari J, Bahalkar P, Agarwala S, Rehman MU, Saleh A, et al. Comparison of the immediate postoperative outcome of using the conventional two drains versus a single drain after lobectomy. *Ann Thorac Surg*. 2003;76(4):1046–9.
- Pawelczyk K, Marciniak M, Kacprzak G, Kolodziej J. One or two drains after lobectomy? A comparison of both methods in the immediate postoperative period. *Thorac Cardiovasc Surg*. 2007;55(5):313–6.
- Zhou D, Deng XF, Liu QX, Chen Q, Min JX, Dai JG. Single chest tube drainage is superior to double chest tube drainage after lobectomy: a meta-analysis. *J Cardiothorac Surg*. 2016;11(1):88.
- You J, Zhang H, Li W, Dai N, Zheng Z. Single versus double chest drains after pulmonary lobectomy: a systematic review and meta-analysis. *World J Surg Oncol*. 2020;18(1):175.
- Refai M, Brunelli A, Salati M, Xiume F, Pompili C, Sabbatini A. The impact of chest tube removal on pain and pulmonary function after pulmonary resection. *Eur J Cardiothorac Surg*. 2012;41(4):820–2. discussion 823.
- Yang Z, Hu T, Shen H, Huang H. Application of small-bore pigtail catheter to improve pleural drainage after single-incision thorascopic lobectomy for lung cancer. *ANZ J Surg*. 2020;90(1–2):139–43.

How to cite this article: Yang F, Wang X, Xu H, Aramini B, Zhu Y, Jiang G, et al. A novel drainage strategy using chest tube plus pleural catheter in uniportal upper lobectomy: A randomized controlled trial. *Thorac Cancer*. 2023;14(4):399–406. <https://doi.org/10.1111/1759-7714.14759>