






# Treatment of an aneurysmal bone cyst in a young dog: A case report

Matteo Olimpo<sup>1</sup>  | Sara Del Magno<sup>2</sup>  | Emanuela Morello<sup>1</sup>  | Giulio Lenarduzzi<sup>3</sup> | Paolo Buracco<sup>1</sup>  | Lisa Adele Piras<sup>1</sup> 

<sup>1</sup> Department of Veterinary Sciences, University of Turin, Grugliasco 10095, Italy

<sup>2</sup> Department of Veterinary Medical Sciences, University of Bologna, Bologna, Italy

<sup>3</sup> Ambulatorio Veterinario Gaspardis, Udine, Italy

## Correspondence

Matteo Olimpo, Department of Veterinary Sciences, University of Turin, Largo P. Braccini 2-5, 10095 Grugliasco, Italy.  
Email: [matteo.olimpo@gmail.com](mailto:matteo.olimpo@gmail.com)

## Abstract

**Background:** An aneurysmal bone cyst (ABC) is a rare benign lytic lesion affecting the medullary canal of long bones. It has been widely reported in human medicine, but rarely described in domestic animals.

**Objective:** To report the surgical treatment and long term follow-up of a dog affected by ABC.

**Methods:** An 8-month-old, intact female Weimaraner was presented with lameness affecting the left front limb and progressive swelling of the mid-distal radius. Survey radiographs revealed a mid-distal diaphyseal radial lesion. Fine needle aspirates, biopsy, CT scan and histopathology results supported the diagnosis of ABC. Treatment consisted of partial corticotomy of the affected radius, filling of the cystic cavity with demineralised bone matrix and autologous bone graft and stabilisation using lag screws and a neutralisation plate.

**Results:** The long-term follow-up, at 36 post-operative months, showed no recurrence of the cyst and bone modelling. Comparing preoperative radiographs with those at 36 months, bone modelling reduced the radial area by 23.3% in the craniocaudal radiographic view and 30% in the mediolateral projection.

**Conclusions:** This treatment was successful in the case here described, with a 3 years follow-up.

## KEYWORDS

bone grafting, dog, orthopaedic, orthopaedic plates

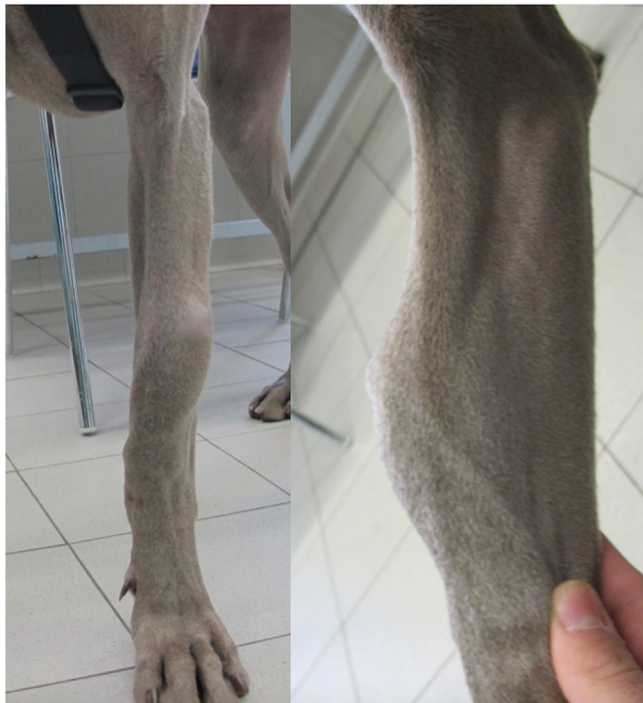## 1 | INTRODUCTION

Aneurysmal bone cysts (ABCs) are expansile benign osteolytic bone lesions consisting of large vascular sinusoids divided by connective tissue septa into blood-filled cavities (Dowdle et al. 2003). They have been extensively reported in human medicine in young adults and children (Muratori et al. 2019; Renegar et al. 1979), whereas they have been infrequently reported in the veterinary literature.

The pathogenesis of ABCs remains speculative and may be multifactorial in both humans and dogs. Most commonly, ABCs appear in the metaphysis of long bones, but they have also been reported in the vertebrae, pelvis, rib and scapula (Barnhart 2002). Although the ABC is benign, local recurrence after treatment has been reported (Mei et al. 2009). Additionally, malignant transformation has been reported in humans and also in a Labrador Retriever (Barnhart 2002). Many treatments have been reported both in humans and companion animals, but

This is an open access article under the terms of the [Creative Commons Attribution-NonCommercial-NoDerivs](https://creativecommons.org/licenses/by-nc-nd/4.0/) License, which permits use and distribution in any medium, provided the original work is properly cited, the use is non-commercial and no modifications or adaptations are made.

© 2021 The Authors. *Veterinary Medicine and Science* published by John Wiley & Sons Ltd.



**FIGURE 1** Photograph of the dog at the first clinical evaluation. An evident bulging at the level of the cranial part of the radial diaphysis was noted. The lesion was firm and had a bony consistency to the touch

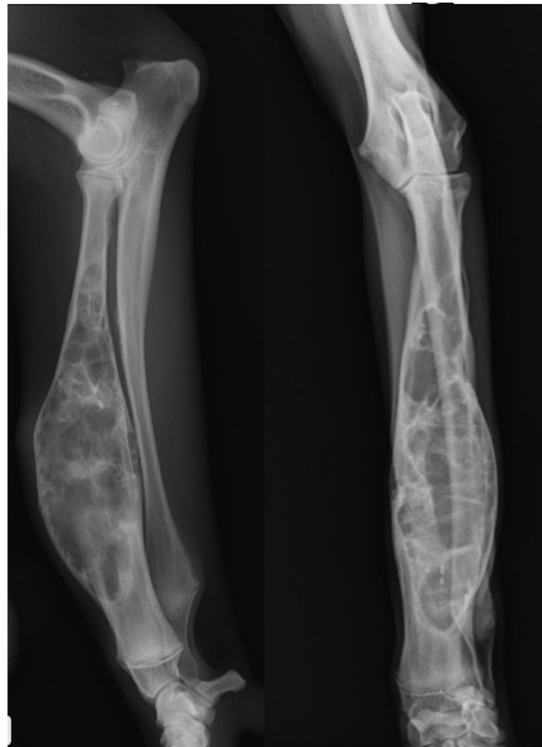a gold standard has still to be defined (Anson et al. 2020; Muratori et al. 2019).

## 2 | CASE HISTORY

An 8-month-old, 18-kg, intact female Weimaraner dog was presented with a large, painful swelling of the cranio-mid-distal region of the left radius (Figure 1). The dog showed progressive lameness of 2 months duration, without history of trauma and not responsive to anti-inflammatory therapy (Meloxicam, Metacam®, Boehringer Ingelheim). At the time of consultation, the lameness was graded, using a 0–5 scale (Forell & Schwarz, 1993), as 4/5. Examination revealed mild atrophy of the muscles of the left thoracic limb and on palpation, the swelling was warm, solid and painful.

## 3 | DIAGNOSTIC PROCEDURES

Results of haematological and serum biochemistry analyses were within normal reference ranges. Orthogonal radiographs of the left antebrachium showed an extensive area (10 × 3 cm) of an expansile, geographic lysis of the mid-distal radius with marked thinning of the overlying cortices (Figure 2). A bone cyst, composed of different chambers divided by septa, was suspected. Proximally, the lesion appeared poorly margined; the distal epiphysis was not involved.



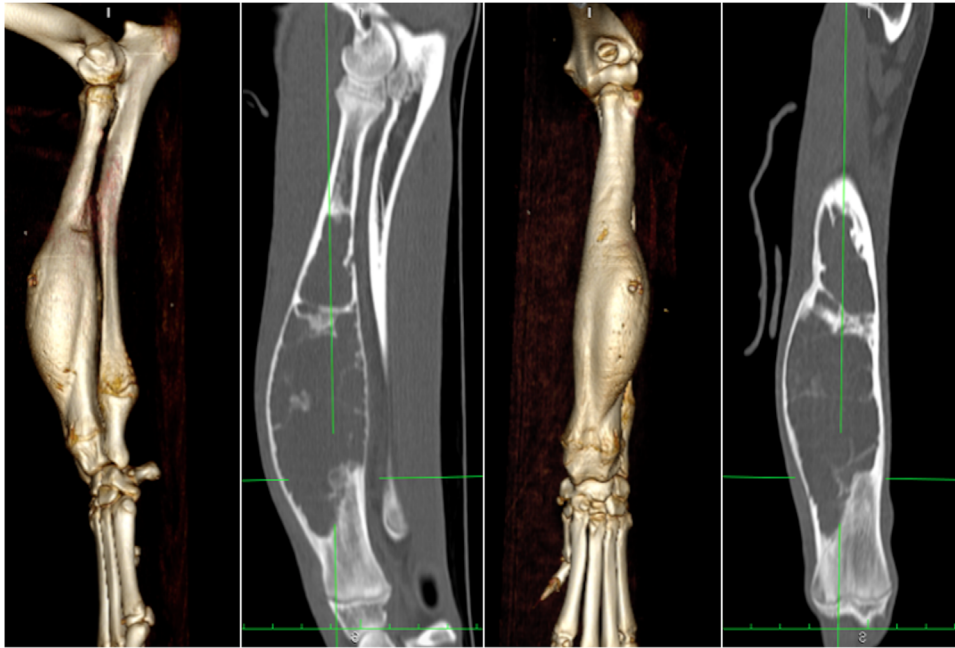
**FIGURE 2** Mediolateral and craniocaudal radiographs of the right antebrachium at presentation. There was an expansile bone lesion at the distal half of the diaphysis and distal metaphysis of the radius, with cortical thinning and thin septa inside the radiolucent cavity. No periosteal reaction or soft tissue swelling was observed

Thoracic radiographs in three views were unremarkable. Fine needle aspirate was performed and yielded a mildly cloudy serosanguineous fluid. Cytological examination showed only a normal blood-rich cell background. The total body CT scan showed a monostotic lesion occupying the 62% of the radial volume (Figure 3). CT-guided multiple biopsies with an 8G Jamshidi needle were performed under general anaesthesia. The tissue samples were sent for both histopathology analysis. Because of the presence of multiple, large-calibre, thin-walled vessels, a histopathology diagnosis of ABC was made.

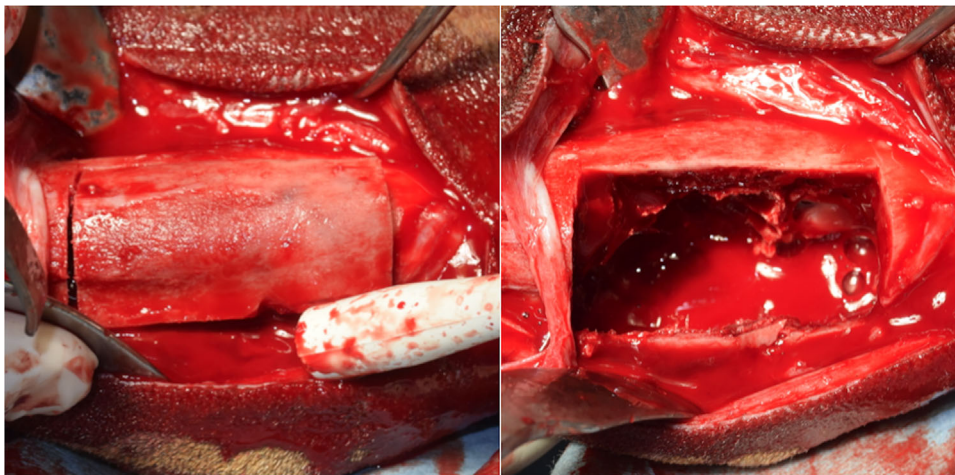
## 4 | TREATMENT

The dog underwent general anaesthesia and the left forelimb was clipped and aseptically prepared for surgery. Induction was achieved with propofol at 2 mg/kg IV (Proposure 1%, Merial) and maintenance with isoflurane (Isoflurane Vet, Merial) aiming for a 0.8% of minimal alveolar concentration after endotracheal intubation, in a mixture of oxygen and air. Analgesia was provided by a target-controlled infusion of fentanyl at a plasma concentration of 1.2–1.6 ng/ml (Fentadon 0.05%, Eurovet Animal Health).

With the patient in dorsal recumbency, a craniomedial approach to the radial diaphysis was performed. Surgical treatment consisted of radial corticotomy and curettage of the bone lesion. A bone window



**FIGURE 3** Both three-dimensional bone reconstruction and multi-planar reconstruction are illustrated. The CT shows an expansile lytic bone lesion of the radius

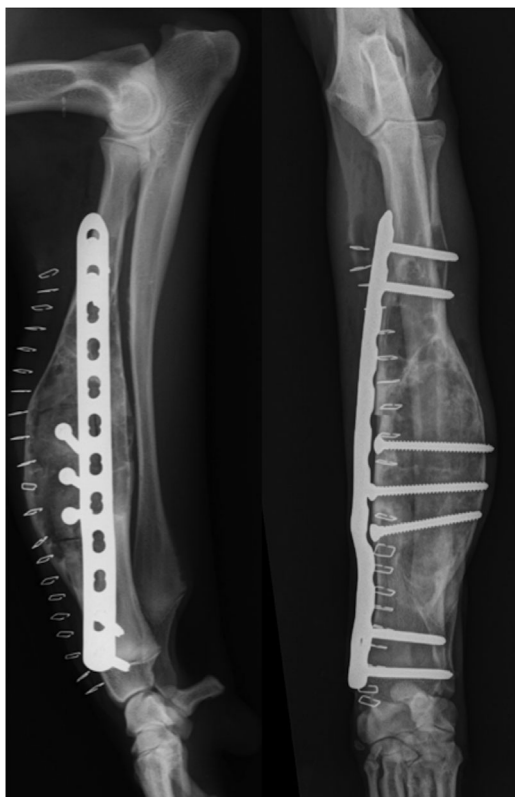


**FIGURE 4** A corticotomy was performed in the radius and the bone cyst cavity was exposed as shown

of  $6 \times 2$  cm on the medial cortex of the radial diaphysis was performed with an oscillating saw (Colibri II, DePuy Synthes) (Figure 4). The resulting bone segment was immersed in warm sterile saline solution during the time of the surgery. Curettage of the inner part of the ABC was performed with a Volkmann curette. Tissue samples collected from the ABC were sent again for both histopathology and aerobic and anaerobic culture examination. The bone cavity was filled with an autologous bone graft collected from the ipsilateral proximal humerus, proximal tibia and distal femur. Because the autologous bone graft was judged insufficient to fill the ABC, it was mixed with 6 cc of demineralised bone matrix (DBM) (Veterinary Tissue Bank). The bone window was reduced to anatomically reposition the bone segment using three 3.5-mm lag screws and a 3.5-mm Locking Compression Plate (LCP, DePuy Synthes),

applied in a neutralisation fashion on the medial side (Figure 5). The surgical wound was closed routinely. Survey radiographs of the limb were performed at this time; they showed a good apposition of the corticotomy segment. The left antebrachium was supported with a modified Robert Jones bandage for the following 2 days. Post-operative care included meloxicam 0.1 mg/kg every 24 h for 10 days following surgery, crate rest for the first week post-operatively, then increasing leash exercise for the subsequent 4 weeks. The dog appeared to be pain free by 2 days after surgery.

Histological examination of the deeper areas of the cyst revealed the presence of intact cavities with walls consisting of spindle-shaped fibroblasts. These cystic spaces were lined mainly by mature, fibrous connective tissue in which osteoid, woven bone and osteoclast-like



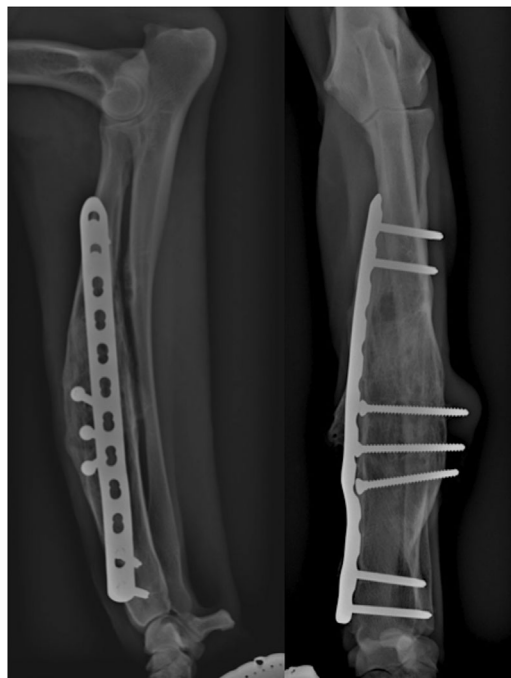
**FIGURE 5** Immediate post-operative radiographs showing the osteosynthesis of the bone window with three 3.5-mm cortical screws positioned in a lag fashion and a 3.5-mm LCP plate in a neutral fashion

giant cells were identified. The underlying cause could not be discerned on examination of numerous sections of the surgical specimen. The final diagnosis was ABC.

Clinical and radiographic follow-up was performed every 30 days. The dog remained clinically asymptomatic, with no lameness, and no sign of pain or recurrence. The dog regained a normal symmetrical front limb muscle tone bilaterally and no evidence of lameness was observed during walking or trotting at the 7 months follow-up examination. Palpation of the antebrachium did not elicit any signs of pain. Survey radiographs at 6 post-operative months showed complete filling of the bone cyst and due to the modelling of the cranial and lateral cortex, the three lag screws appeared too long (Figure 6). Implant removal was discussed with the owner and performed 7 months after surgery. The dog recovered well from implant removal, without episodes of lameness.

Radiographs obtained 36 months post-operatively showed marked bone modelling, with no signs of cyst recurrence (Figure 7).

Preoperative and long-term follow-up orthogonal radiographic projections of the antebrachium were measured to compare the radial area on a dedicated workstation using digital radiographic software (OsiriX, Pixmeo Sarl). The preoperative radial area in the mediolateral view was 57 cm<sup>2</sup>, whereas after 36 post-operative months it was 40.6 cm<sup>2</sup>. The preoperative craniocaudal radius area was 73 cm<sup>2</sup>, whereas after 36 post-operative months it was 56 cm<sup>2</sup> (Figure 8).



**FIGURE 6** Seven months post-operative radiographs showing the modelling of the lateral cortex of the radius at the level of the bone cyst. The radiolucent cavity of the bone cyst is no longer visible

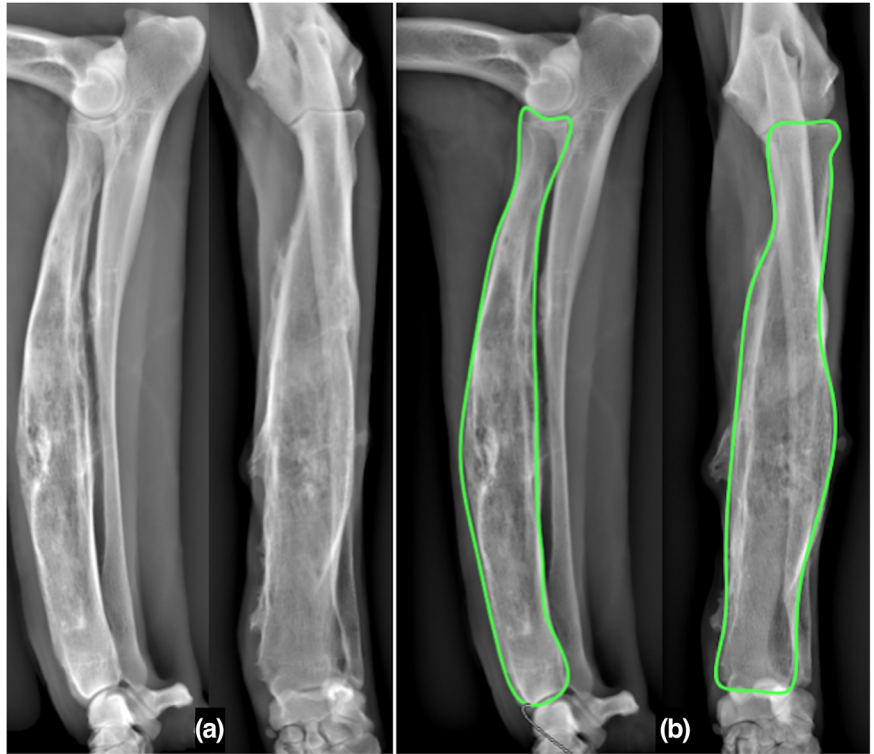
## 5 | DISCUSSION

ABC is a rare disease in companion animals and the final diagnosis is made after histological evaluation to exclude malignancies (Barnhart 2002).

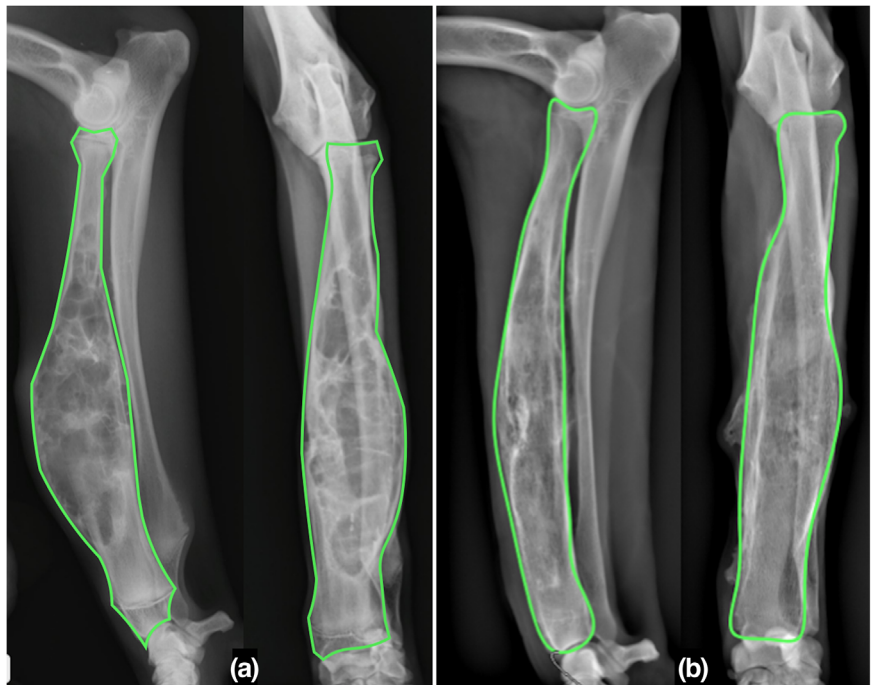
In the present case, a large ABC occupying the 62% of the radius, the weight bearing bone of the antebrachium, was successfully treated by corticotomy and grafting. Reported therapies include grafting of the cystic cavity, sclerotherapy (Adamsbaum et al. 2003; Anson et al. 2020; Lambot-Juhan et al. 2012; Rastogi et al. 2006), cementoplasty and radiation therapy (Vignoli et al., 2015), and ostectomy of the affected bone segment (Barnhart 2002). However, sclerotherapy may take months to be effective and multiple injections of the sclerosing agent may be needed (Adamsbaum et al. 2003; Brosjö et al. 2013). Sclerotherapy was not used here due to the risk of post-operative fracture because of the thinning of the cortex, thus also avoiding the protracted use of protective bandages.

In an attempt to avoid the risk of a post-operative fracture, we decided to treat the ABC by packing the cavity with an autologous bone graft and DBM (Rossanese et al. 2017). Although autogenous cancellous bone is still considered the pre-eminent graft material (Younger & Chapman, 1989), autografting may be limited by the amount of retrievable cancellous bone, patient morbidity, risk of infection, haematoma or fibrous tissue formation. Therefore, the addition of DBM, the most common source of partially purified bone-inducing factors used in human patients (Bolander & Balian, 1986), was empirically selected here. This allogeneic bone is chemically sterilised rather than irradiated in an attempt to preserve its osteoinductive properties. Moreover,

**FIGURE 7** Thirty-six months post-operative radiographs showing the continuous modelling of the cortices of the radius (a). The perimeter of the radius is drawn on both radiographic projections to obtain the area (b)



**FIGURE 8** Comparison between pre-operative radiographs (a) and 36 months post-operative radiographs (b) showing the reduction in the radial area



DBM provides osteoconduction within the collagen network naturally present in the bone.

Even if curettage and cancellous bone grafting are anecdotally reported to provide relatively poor results, with extended recovery periods and high recurrence rates treatment (Dowdle et al. 2003, Duval et al. 1995), recently a successful case of a non-aneurysmatic bone cyst has been reported after treatment with curettage and bone grafting

(Rossanese et al. 2017). The same result was observed in this single case of a large aneurysmatic bone cyst where the treatment was effective, and no recurrence was detected since 36 months. The bone plate prevented the risk of fracture. Bone healing was likely derived from both the local post-curettage cancellous bone invasion and the packed autologous cancellous bone added with an allogeneic DBM in the uncavitated ABC. However, no specific additive role of the DBM in com-

parison with curettage plus cancellous bone autografting alone plus orthopaedic stabilisation was specifically determined.

Even if it has been reported that the cystic cavity may be progressively filled with bone, the increased size of the affected bone may not change, thus never returning to a more physiological appearance (Feigenberg et al. 2001). In this specific case, a 23.3% reduction in the dorsal plane and a 30% in the sagittal plane of the radial area were observed compared to the pre-operative radiographs. This decrease in size of the affected radius to more physiologic dimensions, together with increased bone opacity of the previous cystic cavity and the clinical absence of lameness, supports the good outcome in this case report. A possible explanation may be associated with the young age of the dog, still prone to bone modelling based on weight bearing on the surgically repaired bone abnormality.

In conclusion, even if recurrences have been reported when using cyst curettage and bone plating both in human and veterinary medicine, in this case the treatment was successful with a 3-year follow-up.

#### AUTHOR CONTRIBUTIONS

M.O. and G.L. performed investigation. M.O. and L.A.P. administered the project and wrote the original draft. M.O., E.M., P.B. and L.A.P. performed validation. M.O. performed visualisation. S.D.M., E.M., G.L., P.B. and L.A.P. curated the data. S.D.M., E.M., P.B. and L.A.P. reviewed and edited the manuscript. S.D.M. performed formal analysis. E.M. provided the software. P.B. conceptualised the idea of the study. L.A.P. designed the methodology and performed supervision.

#### ETHICS STATEMENT

The authors confirm that the ethical policies of the journal, as noted on the journal's author guidelines page, have been adhered to. No ethical approval was required as this is a review article with no original research data.

#### DATA AVAILABILITY STATEMENT

The data that support the findings of this study are available from the corresponding author upon reasonable request.

#### PEER REVIEW

The peer review history for this article is available at <https://publons.com/publon/10.1002/vms3.677>

#### ORCID

Matteo Olimpo  <https://orcid.org/0000-0001-6474-7398>

Sara Del Magno  <https://orcid.org/0000-0002-2900-6989>

Emanuela Morello  <https://orcid.org/0000-0002-9801-6646>

Paolo Buracco  <https://orcid.org/0000-0002-0181-0887>

Lisa Adele Piras  <https://orcid.org/0000-0002-0788-0376>

#### REFERENCES

- Adamsbaum, C., Mascard, E., Guinebretière, J. M., Kalifa, G., Dubousset, J. (2003). Intralesional Ethibloc injections in primary aneurysmal bone cysts: An efficient and safe treatment. *Skeletal Radiology* 32, 559–566.
- Anson, A., Soler, M., Martinez, M., Murciano, J., Agut, A. (2020). Sclerotherapy treatment of an assumed aneurysmal bone cyst in a dog. *Veterinary Record Case Reports* 8, e000975.
- Barnhart, M. D. (2002). Malignant transformation of an aneurysmal bone cyst in a dog. *Veterinary Surgery* 31, 519–524.
- Bolander, M. E., Balian, G. (1986). The use of demineralized bone matrix in the repair of segmental defects. Augmentation with extracted matrix proteins and a comparison with autologous grafts. *Journal of Bone and Joint Surgery* 68-A, 1264–1274.
- Brosjö, O., Pechon, P., Hesla, A., Tsagozis, P., Bauer, H. (2013). Sclerotherapy with polidocanol for treatment of aneurysmal bone cysts: Good results in 37 of 38 consecutive patients. *Acta Orthopaedica*, 84, 502–505.
- Dowdle, S. M., Spotswood, T. C., Lambrechts, N. E., Duncan, N. M. (2003). Aneurysmal bone cyst in the distal radius of a dog: Diagnostic imaging and surgical treatment. *Veterinary and Comparative Orthopaedics and Traumatology* 16, 116–121.
- Duval, J. M., Chambers, J. N., Newell, S. M. (1995). Surgical treatment of an aneurysmal bone cyst in a dog. *Veterinary and Comparative Orthopaedics and Traumatology* 8, 213–217.
- Feigenberg, S. J., Marcus, R. B. Jr, Zlotecki, R. A., Scarborough, M. T., Berrey, B. H., Enneking, W. F. (2001). Megavoltage radiotherapy for aneurysmal bone cysts. *International Journal of Radiation Oncology Biology Physics* 49, 1243–1247.
- Forell, E. B., Schwarz, P. R. (1993). Use of external skeletal fixation for treatment of angular deformity secondary to premature distal ulnar physal closure. *Journal of the American Animal Hospital Association* 29, 460–476.
- Lambot-Juhan, K., Pannier, S., Grévent, D., Péjin, Z., Breton, S., Berteloot, L., Emond-Gonsard, S., Boddaert, N., Glorion, C., Brunelle, F. (2012). Primary aneurysmal bone cysts in children: Percutaneous sclerotherapy with absolute alcohol and proposal of a vascular classification. *Pediatric Radiology* 42, 599–605.
- Mei, J., Gao, Y. S., Wang, S. Q., Cai, X. S. (2009). Malignant transformation of aneurysmal bone cysts: A case report. *Chinese Medical Journal* 122, 110–112.
- Muratori, F., Mondanelli, N., Rizzo, A. R., Beltrami, G., Giannotti, S., Capanna, R., Campanacci, D. A. (2019). Aneurysmal bone cyst: A review of management. *Surgical Technology International* 35, 325–335.
- Rastogi, S., Varshney, M. K., Trikha, V., Khan, S. A., Choudhury, B., Safaya, R. (2006). Treatment of aneurysmal bone cysts with percutaneous sclerotherapy using polidocanol: A review of 72 cases with long-term follow-up. *The Journal of Bone and Joint Surgery, British Volume* 88, 1212–1216.
- Renegar, W. R., Thornburg, L. P., Burk, R. L., Stoll, S. G. (1979). Aneurysmal bone cyst in the dog: A case report. *Journal American Animal Hospital Association* 15, 191–195.
- Rossanese, M., Wustefeld-Janssens, B. G., Pratesi, A. (2017). Juxta-articular bone cyst in a dog: Stabilisation with transarticular fixator and computed tomographic follow-up. *Veterinary Record Case Reports* 5:e000473.
- Vignoli, M., Stehlik, L., Terragni, R., Cavallo, L., Proks, P. (2015). Computed tomography-guided cementoplasty combined with radiation therapy for an aneurysmal bone cyst in a dog: A case report. *Veterinarnii Medicina*, 60, 109–14.
- Younger, E. M., Chapman, M. W. (1989). Morbidity at bone graft donor sites. *Journal of Orthopaedic Trauma* 3, 192–195.

**How to cite this article:** Olimpo, M., Del Magno, S., Morello, E., Lenarduzzi, G., Buracco, P., Piras, L.A. (2022). Treatment of an aneurysmal bone cyst in a young dog: A case report. *Veterinary Medicine and Science*, 8, 425–430. <https://doi.org/10.1002/vms3.677>