






# Ki-67 assessment—agreeability between immunohistochemistry and flow cytometry in canine lymphoma

Antonella Rigillo<sup>1</sup>  | Andrea Fuchs-Baumgartinger<sup>2</sup> | Silvia Sabattini<sup>1</sup>  |  
Ondrej Škor<sup>3</sup>  | Chiara Agnoli<sup>1</sup> | Ilse Schwendenwein<sup>4</sup> | Giuliano Bettini<sup>1</sup>  |  
Barbara C. Rütgen<sup>4</sup> 

<sup>1</sup>Department of Veterinary Medical Sciences, University of Bologna, Bologna, Italy

<sup>2</sup>Institute of Pathology, Department of Pathobiology, University of Veterinary Medicine Vienna, Vienna, Austria

<sup>3</sup>Clinic for Internal Medicine, Department for Small Animals and Horses, University of Veterinary Medicine Vienna, Vienna, Austria

<sup>4</sup>Clinical Pathology, Department of Pathobiology, University of Veterinary Medicine Vienna, Vienna, Austria

## Correspondence

Barbara C. Rütgen, Clinical Pathology, Department of Pathobiology, University of Veterinary Medicine Vienna, Veterinärplatz 1, 1210 Vienna, Austria.  
Email: barbara.ruetgen@vetmeduni.ac.at

## Funding information

Travel Bursary assigned to junior scientists

## Abstract

Recent literature suggests a combination of flow cytometric determination of Ki-67 and immunophenotype as a reliable tool to classify canine lymphomas. Immunohistochemistry (IHC) on histological samples is the gold standard technique assessing Ki-67 index. Agreement between IHC and FCM derived Ki-67 indices has never been investigated. The aim of this study was to investigate the agreement between IHC and FCM in the assessment of Ki-67 expression/index, in order to evaluate whether FCM may serve as a non-invasive alternative method for the estimation of proliferative activity in canine lymphoma. Dogs with previously untreated canine lymphoma undergoing diagnostic lymphadenectomy were prospectively enrolled. Ki-67 expression/index was assessed by FCM and IHC and expressed as percentage of positive cells. 39 dogs classified by histopathology matched the inclusion criteria. With both methods, Ki-67 expression/index was higher in intermediate/high-grade lymphomas. Spearman's coefficient of correlation was  $\rho = 0.57$ ; (95% CI 0.33–0.75) suggesting a moderate correlation. A Bland-Altman plot revealed a negative constant bias of  $-3.55$  (95% CI:  $-10.52$  to  $3.42$ ) with limits of agreement from  $-45.71$  to  $38.61$ . The study confirmed agreement albeit with wide confidence intervals between the values of Ki-67 expression/index assessed with FCM and IHC. Discrepancies were observed in a subset of cases. Possible explanation could be that Ki-67 index in IHC is determined in the most proliferative areas of the slide, which could introduce kind of sampling bias, whereas FCM evaluates many more cells in cell suspension. Further studies are warranted to investigate this phenomenon.

## KEYWORDS

agreement, canine lymphoma, flow cytometry, immunohistochemistry, Ki-67

## 1 | INTRODUCTION

Ki-67 is a nuclear protein strictly associated with cellular proliferation as a result of its expression during all active phases of the cell cycle

(G<sub>1</sub>, S, G<sub>2</sub>, and M-phase), and absence in quiescent (G<sub>0</sub>) cells.<sup>1</sup> In the last decades, the evaluation of tumoral Ki-67 as proliferation index (Ki-67 index) has found large interest in both human and veterinary oncology. The prognostic<sup>2–7</sup> and diagnostic value<sup>8–11</sup> of Ki-67 were

This is an open access article under the terms of the Creative Commons Attribution-NonCommercial License, which permits use, distribution and reproduction in any medium, provided the original work is properly cited and is not used for commercial purposes.

© 2021 The Authors. *Veterinary and Comparative Oncology* published by John Wiley & Sons Ltd.

demonstrated in many different tumour types, as well as the respective relevance in predicting response to therapy.<sup>12-14</sup> The most valuable examples of Ki-67 prognostic utility in veterinary medicine are represented by canine mast cell tumours and melanocytic neoplasms.<sup>3,4</sup>

Several studies have attempted to define the role of Ki-67 in canine lymphoma with conflicting results.<sup>15-18</sup>

Although many semi-automated counting methods have been proposed for Ki-67 assessment<sup>5,19-25</sup> immunohistochemistry (IHC) followed by manual counting of positive tumour cells in the most proliferative areas is still considered the gold standard. Invasive sampling, lack of standardization, operator-related bias and high costs because of labor intensiveness are major limitations.<sup>6</sup>

Increasing availability of flow cytometry (FCM) in veterinary settings established immunophenotyping as a first-line tool in the diagnosis of canine lymphoproliferative disorders.<sup>26-28</sup> FCM allows simultaneous immunophenotyping by labelling with multiple antibodies conjugated with fluorescent dyes that scatter a peculiar wavelength after interrogation by a light beam. Minimal invasive sampling (only material from a fine needle aspirate is necessary) and assessment of a minimum  $5 \times 10^5$  cells/tube add to the attractiveness of this analytical method. Inclusion of Ki-67 expression into FCM assessment of canine lymphoma has been shown to be of prognostic relevance in cytologically assessed high grade B-cell lymphomas.<sup>29-31</sup> A combination of FCM Ki-67 index and immunophenotype are proposed as a reliable tool to classify canine lymphomas. The optimal cut off to discriminate between low and high grade lymphoma was established by receiver operating characteristic curves and was 12.2%.<sup>31</sup>

Data investigating agreeability between FCM and IHC are missing.

The purpose of this study was to investigate the agreement between IHC and FCM in the assessment of Ki-67 expression in canine lymphoma.

## 2 | MATERIALS AND METHODS

### 2.1 | Patient cohort and inclusion criteria

Dogs with clinical signs suspect for lymphoma showing lymphadenopathy ( $n = 37$ ) and a mediastinal mass ( $n = 2$ ) were prospectively enrolled (Table 1). All dogs were treatment-naïve. Lymphoma was diagnosed by cytology (Figure 1A-C) in all cases and subsequently immunophenotyped by FCM (Figure 1D-L). Additionally, histopathologic examination of a surgically extracted entire lymph node ( $n = 33$ ) or incisional biopsy samples ( $n = 6$ ) from a lymph node ( $n = 35$ ), mediastinal mass ( $n = 2$ ), intestinal mass ( $n = 1$ ) or retropharyngeal mass ( $n = 1$ ) (Table 1) was performed. The median time between FCM and sampling for histopathology was recorded. During this time no treatment was given.

All samples were classified by WHO classification (Figure 1V-X) and IHC.<sup>32</sup> The animals were recruited at the University of Veterinary Medicine Vienna ( $n = 34$ ) and from the University of Bologna ( $n = 5$ ) from March 2018 to November 2019 (Table 1).

The proliferative activity of Ki-67 was determined by FCM (Figure 1M-R) and IHC (Figure 1S-U) on the same site. Demographic information for each dog was retrieved from medical records, including weight, breed, sex, and age. (Table 1).

### 2.2 | Histology and immunohistochemistry—WHO

Lymphoma histotype was established according to the WHO classification of lymphoid neoplasms by two independent pathologists, (SS and AFB), on formalin-fixed and paraffin embedded (FFPE), 2  $\mu$ m thick histological sections stained with haematoxylin-eosin.<sup>33</sup> Histologic grade was determined based on the mitotic count according to Valli et al., 2011.

Consensus between the two pathologists regarding grade and pattern was achieved in all 39 cases. In three cases, a discrepant WHO diagnosis (#13 DLBCL vs Marginal zone lymphoma, #35 T-lymphoblastic VS PTCL, #38 B-lymphoblastic vs DLBCL) required discussion and review to reach a final consensus (Table 3).

Mitotic figures were counted in five microscopic 400 $\times$  high power fields and averaged. Lymphomas with 0 to 5 mitoses/400 $\times$  field were classified as low grade, those with 6 to 10 mitoses/400 $\times$  field as intermediate grade, and those with more than 10 mitoses/400 $\times$  field were diagnosed as high grade.<sup>32</sup>

On replicate sections immunohistochemical staining with CD3 and CD79acy for immunophenotyping and Ki-67 was performed.

CD20 and Pax5 were used in 15 and 3 cases, respectively. When CD3 and CD79acy staining was negative or inconsistent for histopathologic classification CD20 and Pax5 were additionally applied to obtain a final diagnosis (Table 1).

CD3, CD79acy, CD20, Pax 5, and Ki-67 immunolabelling was performed by an autostainer (Lab Vision Autostainer 360, Thermo Scientific) with a HRP- Polymer method. FFPE blocks were cut in 2  $\mu$ m sections, deparaffinized, rehydrated and pretreated with heat in pH 6 citrate buffer (CD3, CD20, Pax 5 and Ki-67) and pH 8 EDTA buffer (CD79acy), respectively for 20 minutes for antigen unmasking. To decrease background staining, slides were incubated in Hydrogen Peroxidase Block (Thermo Scientific) for 5 minutes and in Ultra Vision Protein Block (Thermo Scientific) for another 10 minutes. A polyclonal rabbit antibody against CD3 (Dako; diluted 1:1000), a monoclonal mouse antibody against CD79acy (Dako; diluted 1:1500; Clone HM47/A9), a monoclonal mouse antibody against Pax 5 (Dako; diluted 1:100; Clone DAK-Pax 5), a polyclonal rabbit antibody against CD20 (Spring Bioscience; diluted 1:1000) and a monoclonal mouse antibody against Ki-67 (Dako; diluted 1:250; Clone MIB-1) was used. The samples were incubated with the primary antibodies for 30 minutes, and subsequently with the secondary antibodies (Bright Vision poly HRP anti rabbit IgG and Bright Vision poly HRP anti mouse IgG, respectively; Immunologic) for 30 minutes. For visualization samples were incubated with DAB Quanto (Thermo Scientific) for 5 minutes. Slides were counterstained with Mayer's haematoxylin, dehydrated, put into Neo-Clear

**TABLE 1** Case ID for histopathology. Case numbers consecutively used throughout the manuscript - #1-#39 breed, sex, age in years, site of sampling for FCM, FCM, and IHC markers performed (beside Ki-67), tissue for histological examination, type of sample (biopsy or surgical) listed for the 40 cases included in the manuscript

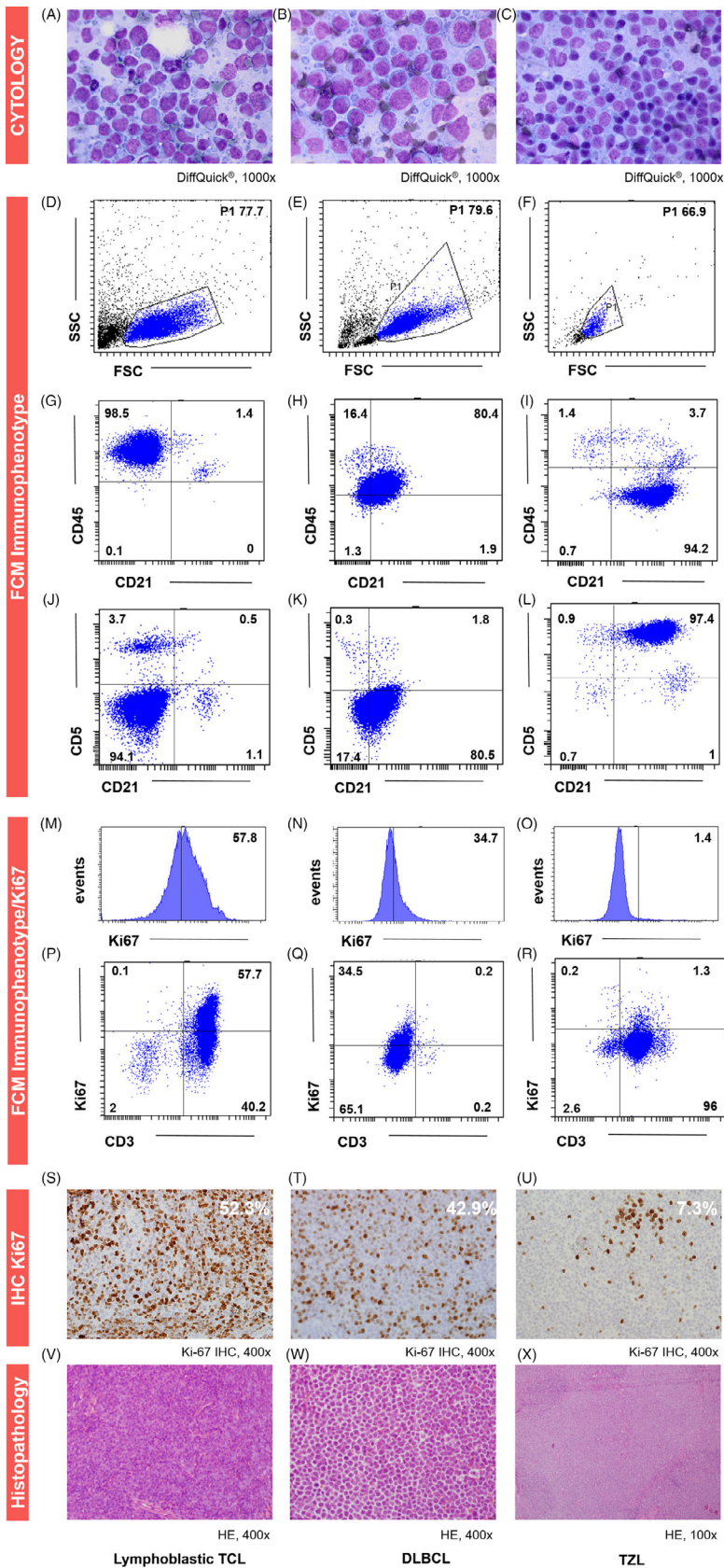
Case ID	#	Breed	sex	age (years)	Site of sampling for FCM	FCM markers performed (beside -Ki-67)	Tissue for histological examination	Type of sample	IHC markers performed (beside Ki-67)
339-18	1	Fox Terrier	fs	7	FNA lymph node	CD45, CD5, CD3, CD4, CD8, CD21, MHCII, CD11a, CD34	lymph node	sectio	CD3, CD79acy
5539-18	2	Bullterrier	f	8	FNA lymph node	CD45, CD5, CD3, CD4, CD8, CD21, MHCII, CD11a, CD34	lymph node	surgical	CD3, CD79acy
5589-18	3	Mixed breed; 6 kg	mc	8	FNA lymph node	CD45, CD5, CD3, CD4, CD8, CD21, MHCII, CD11a, CD34	retropharyngeal area, lymph node - both PTCL	biopsy	CD3, CD79acy
5863-18	4	Schnauzer	fs	5	FNA med mass	CD45, CD5, CD21, MHCII, CD11a	mediastinum	biopsy	CD3, CD79acy
6042-18	5	American Staffordshire Terrier	fs	10	FNA lymph node	CD45, CD5, CD3, CD21, MHCII, CD11a, CD34	lymph node	biopsy	CD3, CD79acy
6161-18	6	Pug	f	1	FNA lymph node	CD45, CD5, CD3, CD4, CD8, CD21, MHCII, CD11a, CD34	lymph node	biopsy	CD3, CD79acy, Pax 5, CD20
6420-18	7	Mixed breed; 17.8 kg	fs	11	FNA lymph node	CD45, CD5, CD3, CD4, CD8, CD21, MHCII, CD11a, CD34	lymph node	surgical	CD3, CD79acy
6573-18	8	Australian Shepherd	fs	9	FNA lymph node	CD45, CD5, CD3, CD4, CD8, CD21, MHCII, CD11a, CD34	lymph node	surgical	CD3, CD79acy
6682-18	9	Pug	m	9	FNA lymph node	CD45, CD5, CD3, CD4, CD8, CD21, MHCII, CD11a, CD34	lymph node	surgical	CD3, CD79acy
6711-18	10	Rough Hair Dachshund	f	8	FNA lymph node	CD45, CD5, CD3, CD4, CD8, CD21, MHCII, CD11a, CD34	lymph node	surgical	CD3, CD79acy
6782-18	11	Border Collie	mc	11	FNA lymph node	CD45, CD5, CD3, CD4, CD8, CD21, MHCII, CD11a, CD34	lymph node	surgical	CD3, CD79acy, CD20
6810-18	12	Bullterrier	fs	4	FNA lymph node	CD5, CD3, CD4, CD8, CD21, MHCII, CD11a, CD34	lymph node	surgical	CD3, CD79acy
6842-18	13	Mixed breed; 12.7 kg	fs	11	FNA lymph node	CD5, CD3, CD4, CD8, CD21, MHCII, CD11a, CD34	lymph node	surgical	CD3, CD79acy, CD20
6875-18	14	Shepherd	mc	10	FNA lymph node	CD5, CD3, CD4, CD8, CD21, MHCII, CD11a, CD34	lymph node	surgical	CD3, CD79acy, Pax 5, CD20

TABLE 1 (Continued)

Case ID	#	Breed	sex	age (years)	Site of sampling for FCM	FCM markers performed (beside -Ki-67)	Tissue for histological examination	Type of sample	IHC markers performed (beside Ki-67)
7038-18	15	Maltese	mc	11	FNA lymph node	CD5, CD3, CD4, CD8, CD21, MHCII, CD11a, CD34	lymph node	surgical	CD3, CD79acy, CD20
7046-18	16	Rottweiler	w	5	FNA lymph node	CD45, CD5, CD3, CD4, CD8, CD21, MHCII, CD11a, CD34	lymph node	surgical	CD3, CD79acy
7320-18	17	Mixed breed; large size, 25.7 kg	f	5	FNA lymph node	CD45, CD5, CD3, CD4, CD8, CD21, MHCII, CD11a, CD34	lymph node	surgical	CD3, CD79acy, CD20
7367-18	18	Mixed breed; 16 kg	fs	10	FNA lymph node	CD45, CD5, CD3, CD4, CD8, CD21, MHCII, CD11a, CD34	lymph node	biopsy	CD3, CD79acy, CD20
7513-18	19	Flat Coated Retriever	f	8	FNA lymph node	CD45, CD5, CD3, CD4, CD8, CD21, MHCII, CD11a, CD34	lymph node	surgical	CD3, CD79acy
7598-18	20	Rottweiler	f	8	FNA lymph node	CD45, CD5, CD3, CD4, CD8, CD21, MHCII, CD11a, CD34	lymph node	surgical	CD3, CD79acy, CD20
5078-19	21	Cocker Spaniel	m	10	FNA lymph node	CD45, CD5, CD3, CD4, CD8, CD21, MHCII, CD11a, CD34	lymph node	surgical	CD3, CD79acy, CD20
5106-19	22	Mixed breed; 30.65 kg	f	10	FNA lymph node	CD45, CD5, CD3, CD4, CD8, CD21, MHCII, CD11a, CD34	lymph node	surgical	CD3, CD79acy, CD20
5134-19	23	Mixed breed; 27.6 kg	mc	11	FNA lymph node	CD45, CD5, CD3, CD4, CD8, CD21, MHCII, CD11a, CD34	intestine, lymph node - all enteric T-cell lymphoma	surgical	CD3, CD79acy, CD20
5280-19	24	Australian Shepherd	mc	5	FNA lymph node	CD45, CD5, CD3, CD4, CD8, CD21, MHCII, CD11a, CD34	lymph node	surgical	CD3, CD79acy, CD20
5351-19	25	Magyar Vizsla	mc	8	FNA lymph node	CD45, CD5, CD3, CD4, CD8, CD21, MHCII, CD11a, CD34	lymph node	surgical	CD3, CD79acy
5547-19	26	Rottweiler	fs	7	FNA lymph node	CD45, CD5, CD3, CD4, CD8, CD21, MHCII, CD11a, CD34	lymph node	surgical	CD3, CD79acy
5467-19	27	Sighthound mixed breed; intermediate size, 22.7 kg	f	8	FNA lymph node	CD45, CD5, CD3, CD4, CD8, CD21, MHCII, CD11a, CD34	lymph node	surgical	CD3, CD79acy

TABLE 1 (Continued)

Case ID	#	Breed	sex	age (years)	Site of sampling for FCM	FCM markers performed (beside -Ki-67)	Tissue for histological examination	Type of sample	IHC markers performed (beside Ki-67)
6074-19	28	Malinois	f	9	FNA lymph node	CD45, CD5, CD4, CD8, CD21, MHCII, CD11a, CD34	lymph node	surgical	CD3, CD79acy
UNIBO AP16758	29	German Shepherd	m	9	FNA lymph node	CD45, CD3, CD79acy	lymph node	surgical	CD3, CD79acy
UNIBO AP18355	30	Labrador Retriever	m	5	FNA lymph node	CD45, CD3, CD79acy	lymph node	surgical	CD3, CD79acy
UNIBO AP18371	31	English Setter	fs	8	FNA lymph node	CD45, CD3, CD79acy	lymph node	surgical	CD3, CD79acy
UNIBO AP18775	32	Irish Setter	fs	6	FNA lymph node	CD45, CD3, CD79acy	lymph node	surgical	CD3, CD79acy
UNIBO AP19122	33	Mixed breed, large size	fs	13	FNA lymph node	CD45, CD3, CD79acy	lymph node	surgical	CD3, CD79acy
A/6337/19	34	American Staffordshire Terrier	mc	12	FNA lymph node	CD45, CD5, CD3, CD4, CD8, CD21, MHCII, CD11a, CD34	lymph node	surgical	CD3, CD79acy, CD20
K/6761/19	35	Labrador Retriever	fs	4	FNA med mass	CD45, CD5, CD3, CD4, CD8, CD21, MHCII, CD11a, CD34	mediastinum	biopsy	CD3, CD79acy
K/7212/19	36	Mixed breed; 19,8 kg	mc	12	FNA lymph node	CD45, CD5, CD3, CD4, CD8, CD21, MHCII, CD11a, CD34	lymph node	surgical	CD3, CD79acy
T/7227/19	37	Magyar Vizsla	fs	8	FNA lymph node	CD45, CD5, CD3, CD4, CD8, CD21, MHCII, CD11a, CD34	lymph node	surgical	CD3, CD79acy
A/7294/19	38	Mixed breed, 21,15 kg	mc	13	FNA lymph node	CD5, CD3, CD4, CD8, CD21, MHCII, CD11a, CD34	lymph node	surgical	CD3, CD79acy, Pax 5, CD20
R/7361/19	39	Saluki	m	6	FNA lymph node	CD5, CD3, CD4, CD8, CD21, MHCII, CD11a, CD34	lymph node	surgical	CD3, CD79acy, CD20



**FIGURE 1** Comparison between cytology, flow cytometry, immunohistochemistry, and pathology in lymphoma immunophenotyping and assessment of Ki-67 expression. Corresponding cytological (A-C, DiffQuick1000x), flow cytometrical plots for Immunophenotyping (D-L, showing the corresponding FSC/SSC (P1), CD45/CD21, CD5/CD21 dot plots) and Ki-67 expression (M-R, showing histograms for Ki-67 and the Ki-67/CD3 dot plot), immunohistochemical (S-U, DAB chromogen, 400x) and histological (V-X, HE stain, 400x) images are shown for three representative patients. In the first column, a representative case of L-TCL #4 is presented showing CD45<sup>+</sup>, CD21<sup>-</sup>, CD5<sup>-</sup>, CD3<sup>+</sup> expression. The expression in FCM and IHC for Ki-67 is high - 57.8% Ki-67<sup>+</sup> and 52.3%, respectively. In the second column, a representative case of DLBCL #10 is presented showing CD45<sup>+</sup>, CD21<sup>+</sup>, CD5<sup>-</sup>, CD3<sup>-</sup> expression. The expression in FCM and IHC for Ki-67 is intermediate - 34.7% Ki-67<sup>+</sup> and 42.9%, respectively. In the third column, a representative case of TZL #2 is presented showing CD45<sup>-</sup>, CD21<sup>+</sup>, CD5<sup>+</sup>, CD3<sup>+</sup> expression. The expression in FCM and IHC for Ki-67 is low - 1.4% Ki-67<sup>+</sup> and 7.3%, respectively. The in the FSC/SSC (P1) gated and marked in blue population (D-F) is the one represented in the subsequent dot plots. It is chosen as a result of size and granularity and life/dead discrimination. In all three cases, the cytological picture shows the presence of lymphoma

**TABLE 2** Species specific and cross reactive monoclonal antibodies, showing clone, isotype, conjugated fluorochrome, and reactivity used for flow cytometry in fine-needle aspirates of canine nodal lymphomas

	Clone	Isotype	Fluorescence labelling	Target species/species cross-reactivity
CD3	CA17.2A12	mlgG1	FITC	anti-canine
CD4	YKIX302.9	rlgG2a	APC	anti-canine
CD5	YKIX322.3	rlgG2a	PerCP-eFLUOR <sup>®</sup> 710	anti-canine
CD8	YCATE 55.9	rlgG1	PE	anti-canine
CD11a	HI111	mlgG1	APC	anti-human, BD Pharmingen™ 559 875
CD21	CA2.1D6	mlgG1	APC	anti-canine
CD45	YKIX716.13	rlgG2b	eFLUOR 450 <sup>®</sup>	anti-canine
MHCII	YKIX334.2	rlgG2a	FITC	anti-canine
CD34	1H6	mlgG1	PE	anti-canine
Ki-67	B56	mlgG1	BV421	anti-human

Abbreviations: APC, allophycocyanin; FITC, fluorescein isothiocyanate; m, mouse; PE, phycoerythrin; r, rat.

and mounted in Neo-Mount (Merck). As positive control a canine lymph node was used.

### 2.3 | Ki-67 evaluation in histopathology

The evaluation of Ki-67 index on IHC sections was performed by two independent pathologists (SS and AR) without knowledge of the FCM results. These results were in concordance (mean difference 5.75%, SD:  $\pm 4.69\%$ , paired *t* test *P* = 0.847), so that the mean of the two counts was used for method comparison.

Five high-power (400 $\times$ ) fields for each case were photographed. Fields were selected among the most proliferative areas, previously assessed by low magnification overview of the whole slide within the purely neoplastic areas. For lymphomas with nodular pattern (2 TZLs and 3 MZLs), the areas of interest for manual counting were selected by previous observation of HE labelled sections together with CD3 and CD79acy IHC labelled slides to avoid highly proliferative reactive follicles.

In each image, the number of Ki-67 positive (brown-stained) and negative (blue-stained) nuclei was manually assessed with a digital cell counter (Fiji-ImageJ Cell Counter, US National Institutes of Health, Bethesda).<sup>35</sup> An average of 4000 cells per case were counted. Ki-67 index was calculated as the mean percentage of positive cells in the five fields. Five HPF were chosen to reach a higher number of cells in order to increase accuracy and improve comparability with FCM.

### 2.4 | Flow cytometry—immunophenotyping and Ki-67

FCM was performed at the University of Veterinary Medicine Vienna, by the same operator (BCR). Five cases were analysed at the University of Bologna by AR. For FCM analyses, cell suspensions were labelled with anti-canine or anti-human cross-reactive monoclonal antibodies against CD3, CD4, CD5, CD8, CD11a, CD21, CD45, CD34, Ki-67, and MHCII, (Table 2) in multicolour staining (Table S1). When setting up this panel used in routine diagnostics, compensation

settings for multicolor staining were established by using single colour samples for automatic compensation by the BD FACSDiva software.

The total nucleated cell count of the single cell suspension from the FNA samples lymph node (*n* = 33) or mediastinal mass (*n* = 2) was determined by an ADVIA 2120 (Siemens, Austria) haematology analyser with the veterinary software setting for dogs. For each analysis,  $5 \times 10^5$  to  $1 \times 10^6$  cells per tube were labelled as described previously.<sup>36</sup>

The viability dye eBioscience Fixable Viability Dye eFluor 780 (Thermo Fischer Scientific, Life Technologies, Carlsbad, CA) was used for live/dead discrimination. Cells only and corresponding isotype controls to every corresponding antibody were used as controls (Table S1).

The staining procedure was performed as follows. All fluorescence conjugated surface antibodies together with the live/dead staining were added in the first step. The intracellular marker, Ki-67 was applied in a second step using the eBioscience Foxp3/Transcription Factor Staining Buffer Set (Invitrogen by Thermo Fischer Scientific, Life Technologies, Carlsbad, CA) according to manufacturers' instructions. In cases with heavy red blood cell contamination and no intracellular staining (Table S1, Tubes 1-6), samples were lysed with the IntraStain-Kit (Dako, Glostrup, Denmark) after the extracellular staining. These samples were treated with the Kit according to manufacturers' instructions.

The labelled cells were analysed on a FACSCanto II flow cytometer (BD Biosciences, San Jose, CA) immediately after staining.

The 5 cases analysed at the University of Bologna were analysed at a MacsQuant 10 flow cytometer (Miltenyi Biotec, Bergisch Gladbach, Germany) and a restricted antibody panel composed of the same clones against CD45, CD3, CD79acy was used. As a result of the restricted panel, these immunophenotyping data were not included in the detailed FCM immunophenotyping results and were only used for B/T-cell lymphoma differentiation. The same Ki-67 clone was used by both institutions.

Gating was performed for all samples using the forward scatter/side scatter (FSC/SSC) dot plot (Figure 1D-F) depicting size and the granularity of the cells/events. The presumed malignant target lymphocytic population was gated and the dead cells excluded by viability stain. The remaining living cells within the gate were used for analysing the antigen expression of all tested antigens.

**TABLE 3** Case ID for Histopathology, case numbers consecutively used throughout the manuscript - #1-#39, FCM antibody expression, FCM report-diagnosis, FCM report-diagnosis, Histopathological-IHC diagnosis based on WHO classification,<sup>34</sup> lymphoma grade, morphologic pattern, IHC Marker results (beside Ki-67), Ki-67 IHC mean, Ki-67% FCM expression, % difference in expression Ki-67 IHC and Ki-67FCM in 40 cases of canine lymphoma. The immunophenotyping of the lymphoma cases is following the expression code used as follows: 0%-19%, 20%-44%, 45%-74%, 75%-100%

Case ID	#	FCM antibody expression	FCM report-diagnosis	Histopathological +IHC diagnosis-WHO	Lymphoma grade	Morphologic pattern	IHC markers results (beside Ki-67)	Ki-67 IHC mean	Ki-67% FCM expression	% Difference in expression Ki-67 IHC and Ki-67 FCM
339-18	1	CD45 <sup>+</sup> , CD5 <sup>-</sup> , CD3 <sup>-</sup> , CD4 <sup>-</sup> , CD8 <sup>-</sup> , CD21 <sup>+</sup> , MHCII <sup>+</sup> , CD11a <sup>+</sup> , CD34 <sup>-</sup>	BCL	Diffuse large B-cell lymphoma	High	Diffuse	CD3: - CD79acy: +	77.445	99.5	-22.055
5539-18	2	CD45 <sup>-</sup> , CD5 <sup>+</sup> , CD3 <sup>+</sup> , CD4 <sup>-</sup> , CD8 <sup>-</sup> , CD21 <sup>+</sup> , MHCII <sup>+</sup> , CD11a <sup>+</sup> , CD34 <sup>-</sup>	TZL	T-zone lymphoma	Low	Nodular	CD3: + CD79acy: -	7.4	1.4	6
5589-18	3	CD45 <sup>+</sup> , CD5 <sup>+</sup> , CD3 <sup>+</sup> , CD4 <sup>+</sup> , CD8 <sup>-</sup> , CD21 <sup>-</sup> , MHCII <sup>-</sup> , CD11a <sup>+</sup> , CD34 <sup>-</sup>	TCL	Peripheral T-cell lymphoma	High	Diffuse	CD3: + CD79acy: -	54.42	44.9	9.52
5863-18	4	CD45 <sup>+</sup> , CD5 <sup>-</sup> , CD3 <sup>+</sup> , CD21 <sup>-</sup> , MHCII <sup>-</sup> , CD11a <sup>-</sup>	TCL	Lymphoblastic T-cell lymphoma	High	Diffuse	CD3: + CD79acy: -	58.795	57.8	0.995
6042-18	5	CD45 <sup>+</sup> , CD5 <sup>-</sup> , CD3 <sup>-</sup> , CD21 <sup>+</sup> , MHCII <sup>+</sup> , CD11a <sup>+</sup> , CD34 <sup>-</sup>	BCL	Diffuse large B-cell lymphoma	Low	Diffuse	CD3: - CD79acy: +	16.11	23	-6.89
6161-18	6	CD45 <sup>-</sup> , CD5 <sup>-</sup> , CD3 <sup>-</sup> , CD4 <sup>-</sup> , CD8 <sup>-</sup> , CD21 <sup>-</sup> , MHCII <sup>-</sup> , CD11a <sup>-</sup> , CD34 <sup>-</sup>	no B-, T-cell lineage CD3 <sup>-</sup> , CD21 <sup>-</sup> , CD34 <sup>-</sup>	Lymphoblastic B-cell lymphoma	High	Diffuse	CD3: - CD79acy: - Pax: + CD20: -	69.005	47	22.005
6420-18	7	CD45 <sup>+</sup> , CD5 <sup>-</sup> , CD3 <sup>-</sup> , CD4 <sup>-</sup> , CD8 <sup>-</sup> , CD21 <sup>+</sup> , MHCII <sup>-</sup> , CD11a <sup>+</sup> , CD34 <sup>-</sup>	BCL	Diffuse large B-cell lymphoma	High	Diffuse	CD3: - CD79acy: +	47.1	40.4	6.7
6573-18	8	CD45 <sup>+</sup> , CD5 <sup>-</sup> , CD3 <sup>-</sup> , CD4 <sup>-</sup> , CD8 <sup>-</sup> , CD21 <sup>+</sup> , MHCII <sup>+</sup> , CD11a <sup>+</sup> , CD34 <sup>-</sup>	BCL	Diffuse large B-cell lymphoma	High	Diffuse	CD3: - CD79acy: +	45.2	30	15.2
6682-18	9	CD45 <sup>+</sup> , CD5 <sup>-</sup> , CD3 <sup>-</sup> , CD4 <sup>-</sup> , CD8 <sup>+</sup> , CD21 <sup>-</sup> , MHCII <sup>-</sup> , CD11a <sup>+</sup> , CD34 <sup>-</sup>	TCL	Peripheral T-cell lymphoma	High	Diffuse	CD3: + CD79acy: -	47.75	63	-15.25
6711-18	10	CD45 <sup>+</sup> , CD5 <sup>-</sup> , CD3 <sup>-</sup> , CD4 <sup>-</sup> , CD8 <sup>-</sup> , CD21 <sup>+</sup> , MHCII <sup>+</sup> , CD11a <sup>+</sup> , CD34 <sup>-</sup>	BCL	Diffuse large B-cell lymphoma	Intermediate	Diffuse	CD3: - CD79acy: +	43.55	34.7	8.85
6782-18	11	CD45 <sup>+</sup> , CD5 <sup>-</sup> , CD3 <sup>-</sup> , CD4 <sup>-</sup> , CD8 <sup>-</sup> , CD21 <sup>+</sup> , MHCII <sup>+</sup> , CD11a <sup>+</sup> , CD34 <sup>-</sup>	BCL, CD34 <sup>-</sup>	Diffuse large B-cell lymphoma	High	Diffuse	CD3: - CD79acy: (+) CD20: +	81.425	68.3	13.125
6810-18	12	CD5 <sup>-</sup> , CD3 <sup>-</sup> , CD4 <sup>-</sup> , CD8 <sup>-</sup> , CD21 <sup>+</sup> , MHCII <sup>+</sup> , CD11a <sup>+</sup> , CD34 <sup>-</sup>	BCL	Diffuse large B-cell lymphoma	Low	Diffuse	CD3: - CD79acy: +	49.635	61.5	-11.865



TABLE 3 (Continued)

Case ID	#	FCM antibody expression	FCM report-diagnosis	Histopathological +IHC diagnosis-WHO	Lymphoma grade	Morphologic pattern	IHC markers results (beside Ki-67)	Ki-67 IHC mean	Ki-67% FCM expression	% Difference in expression Ki-67 IHC and Ki-67 FCM
6842-18	13	CD5 <sup>+</sup> , CD3 <sup>-</sup> , CD4 <sup>-</sup> , CD8 <sup>-</sup> , CD21 <sup>+</sup> , MHCII <sup>+</sup> , CD11a <sup>+</sup> , CD34 <sup>-</sup>	BCL	Advanced marginal zone lymphoma	Low	Nodular	CD3 <sup>-</sup> , CD79acy: (+) CD20: +	19.5	46	-26.5
6875-18	14	CD5 <sup>-</sup> , CD3 <sup>-</sup> , CD4 <sup>-</sup> , CD8 <sup>-</sup> , CD21 <sup>+</sup> , MHCII <sup>+</sup> , CD11a <sup>+</sup> , CD34 <sup>-</sup>	BCL	Diffuse large B-cell lymphoma	High	Diffuse	CD3 <sup>-</sup> , CD79acy: + Pax: + CD20: +	76.91	50.2	26.71
7038-18	15	CD5 <sup>-</sup> , CD3 <sup>-</sup> , CD4 <sup>-</sup> , CD8 <sup>-</sup> , CD21 <sup>+</sup> , MHCII <sup>+</sup> , CD11a <sup>+</sup> , CD34 <sup>-</sup>	BCL	Diffuse large B-cell lymphoma	High	Diffuse	CD3 <sup>-</sup> , CD79acy: (+) CD20: +	59.1	41	18.1
7046-18	16	CD45 <sup>+</sup> , CD5 <sup>-</sup> , CD3 <sup>-</sup> , CD4 <sup>-</sup> , CD8 <sup>-</sup> , CD21 <sup>+</sup> , MHCII <sup>+</sup> , CD11a <sup>+</sup> , CD34 <sup>-</sup>	BCL	Diffuse large B-cell lymphoma	High	Diffuse	CD3 <sup>-</sup> , CD79acy: +	66.4	49	17.4
7320-18	17	CD45 <sup>-</sup> , CD5 <sup>-</sup> , CD3 <sup>-</sup> , CD4 <sup>-</sup> , CD8 <sup>-</sup> , CD21 <sup>+</sup> , MHCII <sup>+</sup> , CD11a <sup>+</sup> , CD34 <sup>-</sup>	BCL	Diffuse large B-cell lymphoma	Intermediate	Diffuse	CD3 <sup>-</sup> , CD79acy: (+) CD20: +	59.235	59.9	-0.665
7367-18	18	CD45 <sup>+</sup> , CD5 <sup>-</sup> , CD3 <sup>-</sup> , CD4 <sup>-</sup> , CD8 <sup>-</sup> , CD21 <sup>+</sup> , MHCII <sup>+</sup> , CD11a <sup>+</sup> , CD34 <sup>-</sup>	BCL	Diffuse large B-cell lymphoma	Intermediate	Diffuse	CD3 <sup>-</sup> , CD79acy: (+) CD20: +	80.3	98.8	-18.5
7513-18	19	CD45 <sup>-</sup> , CD5 <sup>+</sup> , CD3 <sup>+</sup> , CD4 <sup>-</sup> , CD8 <sup>+</sup> , CD21 <sup>-</sup> , MHCII <sup>+</sup> , CD11a <sup>+</sup> , CD34 <sup>-</sup>	TZL	T-zone lymphoma	Low	Nodular	CD3 <sup>+</sup> , CD79acy: -	26.87	6.9	19.97
7598-18	20	CD45 <sup>+</sup> , CD5 <sup>-</sup> , CD3 <sup>-</sup> , CD4 <sup>-</sup> , CD8 <sup>-</sup> , CD21 <sup>+</sup> , MHCII <sup>+</sup> , CD11a <sup>+</sup> , CD34 <sup>-</sup>	BCL	Diffuse large B-cell lymphoma	Intermediate	Diffuse	CD3 <sup>-</sup> , CD79acy: (+) CD20: +	37.25	64.3	-27.05
5078-19	21	CD45 <sup>+</sup> , CD5 <sup>+</sup> , CD3 <sup>+</sup> , CD4 <sup>-</sup> , CD8 <sup>+</sup> , CD21 <sup>-</sup> , MHCII <sup>+</sup> , CD11a <sup>+</sup> , CD34 <sup>-</sup>	TCL	Peripheral T-cell lymphoma	Low	Diffuse	CD3 <sup>+</sup> , CD79acy: - CD20: -	62.6	93.3	-30.7
5106-19	22	CD45 <sup>+</sup> , CD5 <sup>-</sup> , CD3 <sup>-</sup> , CD4 <sup>-</sup> , CD8 <sup>-</sup> , CD21 <sup>+</sup> , MHCII <sup>+</sup> , CD11a <sup>+</sup> , CD34 <sup>-</sup>	BCL	Diffuse large B-cell lymphoma	High	Diffuse	CD3 <sup>-</sup> , CD79acy: (+) CD20: +	59.53	52.1	7.43
5134-19	23	CD45 <sup>+</sup> , CD5 <sup>+</sup> , CD3 <sup>+</sup> , CD4 <sup>-</sup> , CD8 <sup>+</sup> , CD21 <sup>-</sup> , MHCII <sup>+</sup> , CD11a <sup>+</sup> , CD34 <sup>+</sup>	TCL	Enteric T-cell lymphoma	Intermediate	Diffuse	CD3 <sup>+</sup> , CD79acy: - CD20: -	76.17	83.4	-7.23
5280-19	24	CD45 <sup>+</sup> , CD5 <sup>+</sup> , CD3 <sup>+</sup> , CD4 <sup>-</sup> , CD8 <sup>-</sup> , CD21 <sup>-</sup> , MHCII <sup>+</sup> , CD11a <sup>+</sup> , CD34 <sup>-</sup>	TCL	Peripheral T-cell lymphoma	Intermediate	Diffuse	CD3 <sup>+</sup> , CD79acy: - CD20: -	42.62	21.9	20.72

TABLE 3 (Continued)

Case ID	#	FCM antibody expression	FCM report-diagnosis	Histopathological +IHC diagnosis-WHO lymphoma	Lymphoma grade	Morphologic pattern	IHC markers results (beside Ki-67)	Ki-67 IHC mean	Ki-67% FCM expression	% Difference in expression Ki-67 IHC and Ki-67 FCM
5351-19	25	CD45 <sup>+</sup> , CD5 <sup>-</sup> , CD3 <sup>-</sup> , CD4 <sup>-</sup> , CD8 <sup>-</sup> , CD21 <sup>+</sup> , MHCII <sup>+</sup> , CD11a <sup>---</sup> , CD34 <sup>-</sup>	BCL	Marginal zone lymphoma	Low	Nodular	CD3: <sup>-</sup> CD79acy: <sup>+</sup>	12.85	20.2	-7.35
5547-19	26	CD45 <sup>+</sup> , CD5 <sup>-</sup> , CD3 <sup>-</sup> , CD4 <sup>-</sup> , CD8 <sup>-</sup> , CD21 <sup>+</sup> , MHCII <sup>+</sup> , CD11a <sup>-</sup> , CD34 <sup>-</sup>	BCL	Diffuse large B-cell lymphoma	Intermediate	Diffuse	CD3: <sup>-</sup> CD79acy: <sup>+</sup>	56.875	24.5	32.375
5467-19	27	CD45 <sup>+</sup> , CD5 <sup>-</sup> , CD3 <sup>-</sup> , CD4 <sup>-</sup> , CD8 <sup>-</sup> , CD21 <sup>+</sup> , MHCII <sup>+</sup> , CD11a <sup>-</sup> , CD34 <sup>-</sup>	BCL	Diffuse large B-cell lymphoma	Intermediate	Diffuse	CD3: <sup>-</sup> CD79acy: <sup>+</sup>	74.25	16.3	57.95
6074-19	28	CD45 <sup>+</sup> , CD5 <sup>-</sup> , CD4 <sup>---</sup> , CD8 <sup>-</sup> , CD21 <sup>-</sup> , MHCII <sup>-</sup> , CD11a <sup>---</sup> , CD34 <sup>-</sup>	TCL	Peripheral T-cell lymphoma	High	Diffuse	CD3: <sup>+</sup> CD79acy: <sup>-</sup>	65	1.8	63.2
UNIBO AP16758	29	CD45 <sup>+</sup> , CD3 <sup>-</sup> , CD79acy <sup>+</sup>	BCL	Diffuse large B-cell lymphoma	High	Diffuse	CD3: <sup>-</sup> CD79acy: <sup>+</sup>	57.2	69.3	-12.1
UNIBO AP18355	30	CD45 <sup>+</sup> , CD3 <sup>-</sup> , CD79acy <sup>+</sup>	BCL	Diffuse large B-cell lymphoma	Intermediate	Diffuse	CD3: <sup>-</sup> CD79acy: <sup>+</sup>	63.85	85.6	-21.75
UNIBO AP18371	31	CD45 <sup>+</sup> , CD3 <sup>-</sup> , CD79acy <sup>+</sup>	BCL	Diffuse large B-cell lymphoma	Intermediate	Diffuse	CD3: <sup>-</sup> CD79acy: <sup>+</sup>	92.8	80.5	12.3
UNIBO AP18775	32	CD45 <sup>+</sup> , CD3 <sup>-</sup> , CD79acy <sup>---</sup>	BCL	Diffuse large B-cell lymphoma	Intermediate	Diffuse	CD3: <sup>-</sup> CD79acy: <sup>+</sup>	28.55	39.1	-10.55
UNIBO AP19122	33	CD45 <sup>+</sup> , CD3 <sup>-</sup> , CD79acy <sup>+</sup>	BCL	Diffuse large B-cell lymphoma	Intermediate	Diffuse	CD3: <sup>-</sup> CD79acy: <sup>+</sup>	47.75	64.8	-17.05
A/6337/19	34	CD45 <sup>---</sup> , CD5 <sup>-</sup> , CD3 <sup>-</sup> , CD4 <sup>-</sup> , CD8 <sup>-</sup> , CD21 <sup>---</sup> , MHCII <sup>-</sup> , CD11a <sup>-</sup> , CD34 <sup>-</sup>	BCL	Diffuse large B-cell lymphoma	High	Diffuse	CD3: <sup>-</sup> CD79acy: <sup>(+)</sup> CD 20: <sup>+</sup>	74.35	71.2	3.15
K/6761/19	35	CD45 <sup>+</sup> , CD5 <sup>-</sup> , CD3 <sup>+</sup> , CD4 <sup>-</sup> , CD8 <sup>-</sup> , CD21 <sup>-</sup> , MHCII <sup>-</sup> , CD11a <sup>-</sup> , CD34 <sup>-</sup>	TCL	Peripheral T-cell lymphoma	Intermediate-high	Diffuse	CD3: <sup>+</sup> CD79acy: <sup>-</sup>	58.1	83.3	-25.2
K/7212/19	36	CD45 <sup>+</sup> , CD5 <sup>-</sup> , CD3 <sup>-</sup> , CD4 <sup>-</sup> , CD8 <sup>-</sup> , CD21 <sup>+</sup> , MHCII <sup>+</sup> , CD11a <sup>---</sup> , CD34 <sup>-</sup>	BCL	Diffuse large B-cell lymphoma	Intermediate	Diffuse	CD3: <sup>-</sup> CD79acy: <sup>+</sup>	49.55	50.2	-0.65
T/7227/19	37	CD45 <sup>+</sup> , CD5 <sup>-</sup> , CD3 <sup>+</sup> , CD4 <sup>-</sup> , CD8 <sup>-</sup> , CD21 <sup>+</sup> , MHCII <sup>+</sup> , CD11a <sup>---</sup> , CD34 <sup>-</sup>	Mixed expression CD3 <sup>+</sup> , CD21 <sup>+</sup>	Diffuse large B-cell lymphoma	High	Diffuse	CD3: <sup>-</sup> CD79acy: <sup>+</sup>	66.5	66.4	0.1

TABLE 3 (Continued)

Case ID	#	FCM antibody expression	FCM report-diagnosis	Histopathological +IHC diagnosis-WHO	Lymphoma grade	Morphologic pattern	IHC markers results (beside Ki-67)	Ki-67 IHC mean	Ki-67% FCM expression	% Difference in expression Ki-67 IHC and Ki-67 FCM
A/7294/19	38	CD5 <sup>-</sup> , CD3 <sup>-</sup> , CD4 <sup>-</sup> , CD8 <sup>-</sup> , CD21 <sup>-</sup> , MHCII <sup>+</sup> , CD11a <sup>-</sup> , CD34 <sup>-</sup>	No B-, T-cell lineage CD3 <sup>+</sup> , CD21 <sup>-</sup>	Diffuse large B-cell lymphoma	Intermediate	Diffuse	CD3 <sup>-</sup> CD79acy: (+/-) (= 50% positive, a part weak positive and some of the tumor cells negative)CD 20: +Pax 5: +	69.3	53.6	15.7
R/7361/19	39	CD5 <sup>-</sup> , CD3 <sup>+</sup> , CD4 <sup>-</sup> , CD8 <sup>-</sup> , CD21 <sup>+</sup> , MHCII <sup>+</sup> , CD11a <sup>-</sup> , CD34 <sup>+</sup>	Mixed expression CD3 <sup>+</sup> , CD21 <sup>+</sup>	Diffuse large B-cell lymphoma	Intermediate	Diffuse	CD3: negCD79acy: (+) CD20: pos	61.9	39.3	22.6

Note: 0%-19%, ~20%-44%, ~45%-74%, +75%-100%.

Ki-67 expression was defined as percentage of labelled living lymphocytic cells within the gate. 20,000 events were recorded for every tube. The antibody expression for all antigens except Ki-67 was categorized into 4 groups referring to the percent positive cells: <sup>-</sup>: 0%-19%, <sup>~</sup>: 19.1%-44%, <sup>~</sup>: 44.1%-75%, <sup>+</sup>: 75.1%-100%. According to these criteria positivity/negativity, immunophenotyping in B/T-cell lymphoma and FCM subclassification was performed.

Lymphomas were classified into B-cell lymphoma (BCL) based on the FCM expression patterns being CD45<sup>+/-</sup>, CD5<sup>+/-</sup>, CD3<sup>-</sup>, CD4<sup>-</sup>, CD8<sup>-</sup>, CD21<sup>+/-</sup>, MHCII<sup>~/-/+</sup>, CD11a<sup>-/-/+</sup>, CD34<sup>-/+</sup>.<sup>37</sup>

T-zone lymphomas (TZL) were CD45<sup>-</sup>, CD5<sup>+</sup>, CD4<sup>+</sup>, CD4<sup>-</sup>, CD8<sup>-</sup>, CD21<sup>+/-</sup>, MHCII<sup>+</sup>, CD11a<sup>+</sup>, CD34<sup>-</sup>.<sup>38</sup>

Remaining T-cell lymphomas (TCL) showed following expression pattern: CD45<sup>+</sup>, CD5<sup>-/+</sup>, CD3<sup>-/+</sup> and if CD3<sup>-</sup> then CD4 or CD8<sup>+</sup>, CD4<sup>-/+</sup>, CD8<sup>-/+</sup>, CD21<sup>-</sup>, MHCII<sup>-/+</sup>, CD11a<sup>-/+</sup>, CD34<sup>-/+</sup>.<sup>38</sup>

For Ki-67, the percentage of positive cells within the gated population was determined and recorded.

## 2.5 | Statistical analysis

IHC Ki-67 index and FCM Ki-67 expression results were depicted in dot plots by histologic grade and visually inspected. Inferential statistics of Ki-67 results between high-, intermediate-, and low grade lymphoma cases was performed separately for both methods by the Kruskal-Wallis test. The correlation between IHC Ki-67 index and FCM Ki-67 expression was estimated with Spearman's Rank correlation coefficient. Agreement between methods was assessed by the Bland-Altman difference plot.

Data were analysed with a statistical software (analyse-it v.2.30 by Analyse-it Software.Ltd.,Leeds, LS3 UK). *P*-values <0.05 were considered significant.

## 3 | RESULTS

### 3.1 | Demographic and clinical information of the patient cohort

Thirty-nine dogs fulfilled the criteria for inclusion in the study. There were 11 mixed breed (3 large size, 4 medium size, 1 small size, 6-30.6 kg) and 28 purebred dogs; among the latter, the most represented breed included Rottweiler (n = 3), Fox terrier (n = 1), Pug (n = 2), Bull terrier (n = 2), German shepherd (n = 2), American Staffordshire terrier (n = 2), Australian Shepherd (n = 2), Magyar Vizsla (n = 2), and Labrador retriever (n = 2). There were 5 intact males, 10 neutered males, 10 intact females and 14 spayed females. The mean age was 8.35 years (range, 1-13) (Table 1).

### 3.2 | Histopathology and immunohistochemistry—WHO

B-cell lymphomas (n = 29; 75%) included 26 diffuse large B-cell lymphoma (DLBCL), 1 lymphoblastic (B-LBL) and 2 marginal zone

lymphomas (MZL), whereas T-cell lymphomas ( $n = 10$ ; 25%) consisted of 6 peripheral T-cell lymphomas (PTCL), one lymphoblastic T-cell lymphomas (T-LBL); 2 T-zone lymphomas (TZL) and one enteric T-cell lymphoma (Table 3, Figure 1S-U). These results were in concordance to the FCM immunophenotyping in all cases except 2, in which FCM was showing a mixed expression for CD3 and CD21. These two cases were categorized as diffuse large B-cell lymphomas by histopathology.

The median time elapsed between FCM and sampling for histopathology (lymph node excision or surgical wedge biopsy) was 3.5 days (range, 0-7 days). Animals were left without treatment during this period.

### 3.3 | Histopathology and immunohistochemistry—pattern

Thirty-five lymphoma cases presented a diffuse and 4 a nodular pattern. Out of the latter cases two were TZL and the other two were MZL (Table 3).

### 3.4 | Histopathology and immunohistochemistry—grading

Overall, there were 7 low grade (20%), 16 intermediate grade (40%) and 16 high grade lymphomas (44%) according to Valli and colleagues.<sup>38</sup>

Of 26 DLBCL 11 were high grade, 13 were intermediate grade and 2 were low grade. Of 6 PTCL 3 were high grade, 2 were intermediate grade and 1 was low grade. 1 case of lymphoblastic T and B-cell lymphoma each were high grade. TZL and MZL lymphoma cases were all low grade and the one enteric T-cell lymphoma was intermediate grade (Table 3).<sup>32,33,39</sup>

### 3.5 | FCM Immunophenotyping

Thirty-five cases were analysed in Vienna and five cases in Bologna. In Vienna 29/35 cases were tested for CD45, all cases for CD11a, CD5, CD21, MHCII. All except one case was tested for CD3 and two cases not for CD4 and CD8. CD34 was tested in all cases except one. The discrepancy in some antibodies used was caused by marker availability. The cases analysed in Bologna were tested against CD45, CD3, and CD79acy (Table 1). As a result of this reduced setup, these five cases were only included in the Ki-67 evaluation and not in the FCM Immunophenotyping.

The presumed gated malignant lymphocytes (P1) represented  $67.8 \pm 18.6\%$  with extracellular and  $80.15 \pm 19.01\%$  with intracellular antigens of the total of all recorded events (Figure 1D-F).

Within the gated population (P1) in 33/39 cases data was available,  $91.53 \pm 11.7\%$  were alive with extracellular and  $84.92 \pm 16.61\%$  with intracellular markers (Table S2).

34/39 cases could be unequivocally classified according to their characteristic expression pattern into B-cell lymphoma ( $n = 20$ ) (BCL) (Figure 1H, K) and T-cell lymphoma ( $n = 10$ ).

The T-cell lymphomas were subcategorized in T-Zone lymphoma (TZL) ( $n = 2$ , Figure 1I, L) and T-cell lymphoma (TCL) ( $n = 8$ , Figure 1G, J).

Two cases showed a mixed antibody expression for T- and B-cell markers and two cases did not show any differentiation for the T- or B-cell lineage. Two cases were CD34<sup>~</sup>. One showing BCL expression (case #11) and one showing no T- or B-cell lineage (case #6).

Data are summarized in Table 3.

Results of all 20 B-cell lymphomas immunophenotyped via FCM were in line with the histopathologic diagnosis according to WHO classification consisting of 18 diffuse large B-cell lymphomas and 2 marginal zone lymphomas. Specific expression patterns in FCM regarding the 2 different WHO classification types, DLBCL or MZL could not be identified (Figure 1V-X).

The 2 TZL characterized by FCM showed the already described characteristic marker pattern and were in agreement with the WHO diagnosis of TZL.<sup>40</sup> The eight cases of TCL also showed comparability to 6 Peripheral T-cell lymphomas, 1 enteric T-cell lymphoma and 1 lymphoblastic T-cell lymphomas in histopathology.

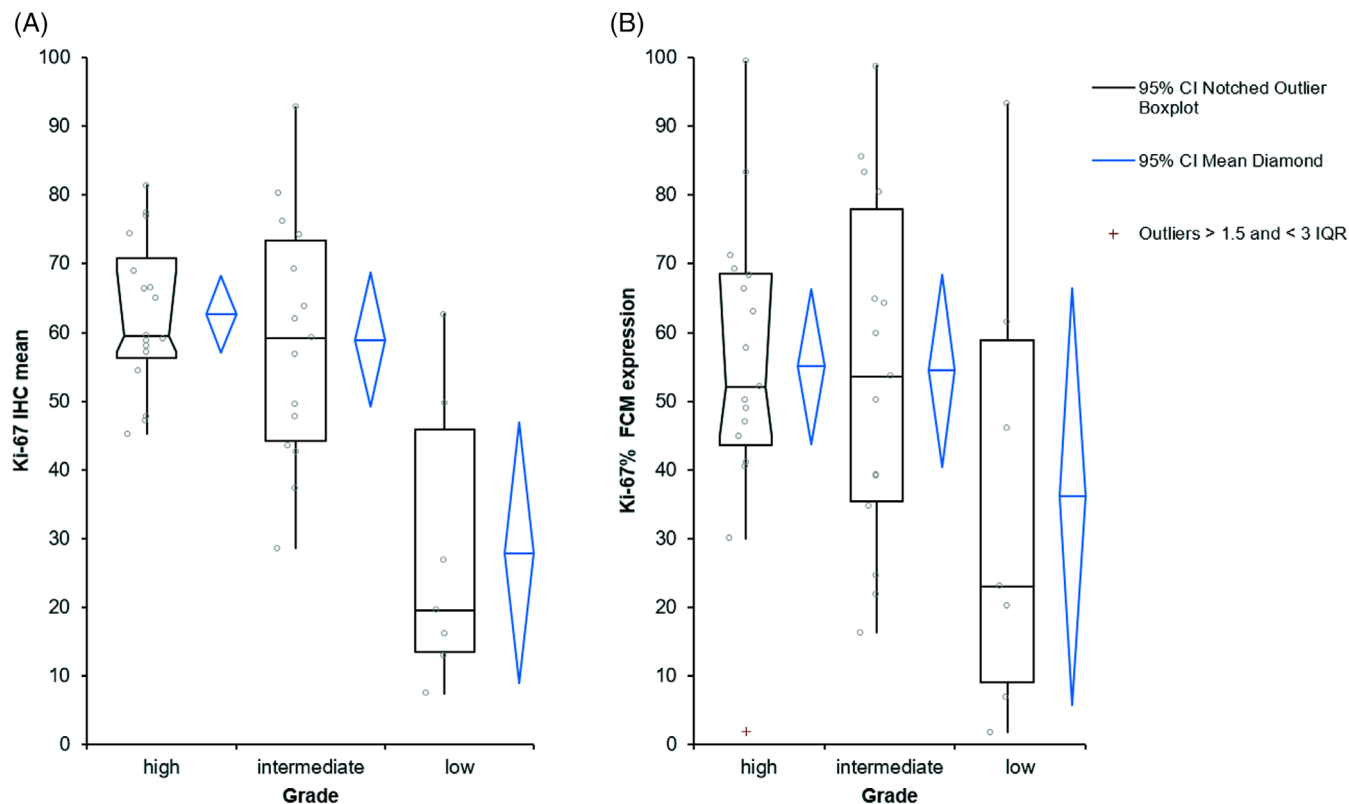
The two cases (5.7%) showing a mixed expression being positive in FCM for CD21 and CD3 were diagnosed as DLBCL in histopathology. The two cases (5.7%) showing no lineage differentiation for B- or T-cell markers were one DLBCL and one lymphoblastic B-cell lymphoma (L-BCL) in histopathology. These four cases were the only discordant results between FCM and histopathology (Table 3).

### 3.6 | Ki-67 expression in FCM and IHC

The median Ki-67 expression was 54.95% (range, 7.4%-92.8%) with IHC and 51.4% (range, 1.7%-99.5%) with FCM (Table 3, Figure 1S-U).

With both methods, Ki-67 index/expression was highest in high grade, slightly lower in intermediate and clearly lower in low grade lymphoma (Figure 2A, B). With IHC a significant difference in Ki-67 index could be observed between high grade and low grade ( $P = 0.0032$ ), as well as intermediate and low grade lymphoma ( $p 0.018$ ). In FCM the difference in Ki-67 expression did not differ significantly between the respective grades because of a huge overlap. Interestingly two cases with very high Ki67% positivity in both methods showed a low mitotic rate and were thus rated as low grade. These were a DLBCL (case #12; IHC 49%, FCM 61%) and a PTCL (case #21; IHC 62%, FCM 93%), both subtypes usually associated with an aggressive behaviour.

The Spearman's Coefficient of Correlation was  $\rho = 0.57$ ; (95% CI 0.33-0.75) suggesting a moderate correlation (Figure 3A). A Bland-Altman plot revealed a negative constant bias of  $-3.55\%$  (95% CI:  $-10.52$  to  $3.42$ ) with limits of agreement from  $-45.71$  to  $38.61$  (95% CI lower:  $-57.72$  to  $-33.69$ ); 95% CI higher:  $26.59$  to  $50.62$ ) (Figure 3B).



**FIGURE 2** Distribution of Ki-67 index/expression of high/intermediate/low grade lymphoma cases ( $n = 39$ ) in IHC A, and FCM B. The horizontal line represents the different lymphoma grades - high, intermediate, low defined by histopathological grading. The vertical line represents the percent counted. The boxes represent the confidence interval of the mean, the solid line within the box represents the mean, and the whiskers show the minimum and the maximum. The outliers  $>1.5$  and  $<3$  of the interquartile range are marked with a red cross

Differences above 30.2% were observed in 2 DLBCL and 1 PTCL, where FCM ratios were consistently lower than IHC results. #28 was a PTCL with a difference of 63.2%, #26, #27 DLBCLs with differences of 32.38% and 57.95%, respectively (Table 3).

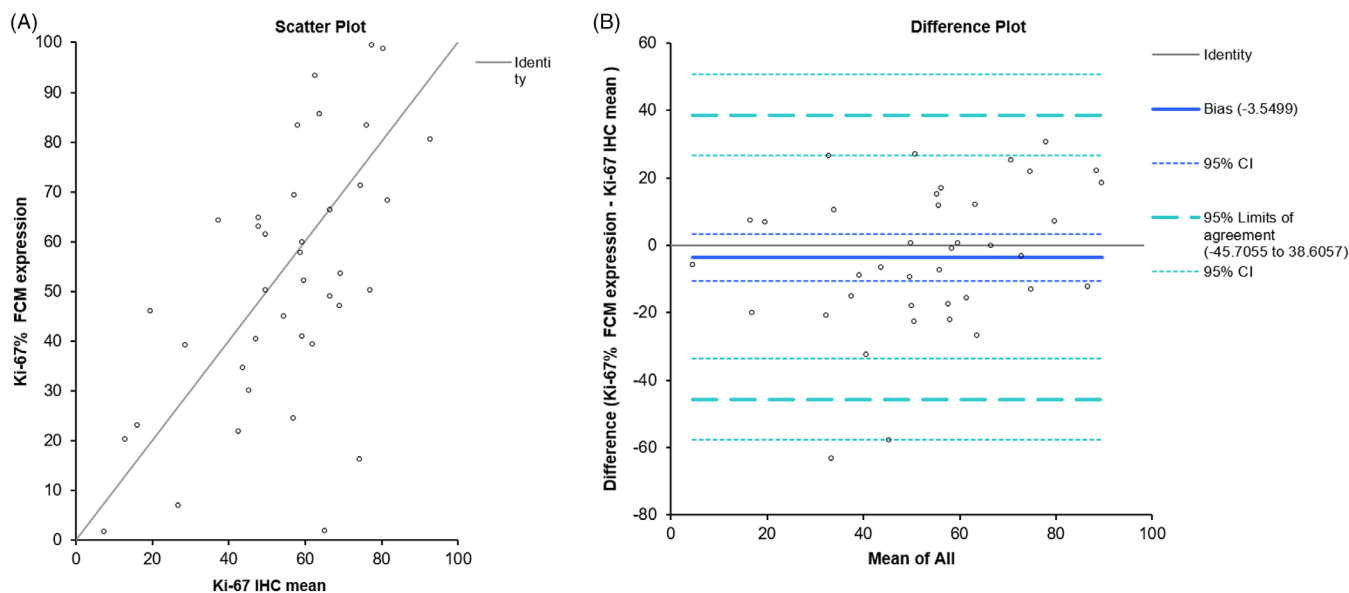
## 4 | DISCUSSION

For the first time agreement of Ki-67 activity between FCM and IHC and its association with WHO grade was prospectively assessed.

Results indicate a substantial albeit moderate correlation between the two techniques. With IHC, a significantly higher Ki-67 expression/index was detected in high- and intermediate-grade lymphomas compared with low grade lymphomas. Differences between high/intermediate grade and low grade were also observed with FCM; however, the differences were statistically not significant. A reason for this lies in the considerable overlap observed between groups in FCM. Interestingly, FCM in evaluating  $20 \times 10^3$  cells showed a fairly constant negative bias over the entire range of observations. A possible explanation is the fact, that in IHC microscopic fields are selected by preparation quality and mitotic activity, which might introduce an observation bias. FCM evaluates many more cells but their localization within the lymph node is unknown. Further the cutoff for FCM Ki-67 positivity is defined by the isotype control, whereas microscopic

differentiation between specific and non specific staining might be difficult in IHC. Determining Ki-67 index only in living cells might be another explanation for the negative bias. Two cases within the dataset showing very high Ki-67 %, both in FCM and IHC, in contrast to a low mitotic index were thus categorized as low grade. These were a DLBCL and a PTCL, both types usually associated with an aggressive behaviour. The DLBCL case was lost for follow up. The patient with PTCL had to be euthanized as a result of disease progression despite chemotherapy on day 67 supporting the suspect of misclassification in terms of grading. The cause for the discrepancy between grading system and the aggressive behaviour could not be explained for these cases; however, this phenomenon has been described in the literature.<sup>41,42</sup>

In three cases, differences over 30.2% between IHC and FCM were observed. In 2 DLBCL and 1 PTCL, Ki-67 expression by FCM was considerably lower than IHC derived Ki-67 index. Differences as such are not surprising, because FCM assesses  $20 \times 10^3$  cells, whereas by IHC an average of  $4 \times 10^3$  cells are evaluated. The method inherent error for small populations is usually quite large. Surprisingly most prominent discrepancies were found with high grade lymphomas whereas IHC yielded consistently higher values. This paradox finding might be explained by the fact that WHO guidelines recommend assessment of Ki-67 positive cells in the most proliferative areas of the slides, which are selected by the evaluators, whereas by



**FIGURE 3** Spearman's rank correlation and Bland-Altman plot of IHC Ki-67 index and FCM Ki-67 expression. The coefficient of correlation A, was  $\rho = 0.57$ ; (95% CI 0.33-0.75) suggesting a moderate correlation. A Bland-Altman plot B, revealed a negative constant bias of  $-3.55\%$  (95% CI:  $-10.52$  to  $3.42$ ) with limits of agreement from  $-45.71$  to  $38.61$  (95% CI lower:  $-57.72$  to  $-33.69$ ; 95% CI higher:  $26.59$  to  $50.62$ )

FCM a cell suspension reflecting the average of proliferative activity is assessed. Further FCM allows simultaneous immunophenotyping of proliferating living cells, thus circumventing non-specific antibody binding as such aiding the discrimination between neoplastic and non-neoplastic cells. Thus assessment of Ki-67 expression by FCM offers apart from financial (labor intensiveness) some technical advantages such as non-invasive sampling, savings of time and material, possibility of multicolour staining and objective discrimination between true positive on non-specific staining, over determining Ki-67 index in IHC.

However, the current standard method is manual counting after IHC staining of histological sections of the positive cells in an area or a grid, expressed either as percentage on the total cell number or as absolute value. A major limit of this method is probably inherent to the lack of uniformity in the assessment of IHC positivity, either operator- and technique-dependent. Factors affecting variability include sample size (biopsy vs full node), lack of consensus in counting field selection, number of evaluated cells and expression of Ki-67 positivity as index (percentage) or absolute numbers. Moreover, the assessment can be affected by the subjectivity in the recognition of positivity as a result of cell overlie and different levels of staining intensity within the same section, and difficulties in discriminating neoplastic cells from the residual non-neoplastic lymphoid population, especially in nodular lymphomas and identification of the most proliferative area. Presence of section artefacts and necrotic areas can further complicate the evaluation. Manual counting is also extremely time-consuming. In human medicine, many automated or semi-automated counting methods based on image-analysis software have been proposed to replace manual counting, but an agreement has still to be reached.<sup>5</sup> In the present study, manual counting was conducted by two independent pathologists and IHC was performed in the same laboratory using an automatic stainer. Additionally, the pictures were

taken with the same microscope and camera, in order to obtain a similar image quality.

Another possible cause for discrepant results in IHC and FCM for Ki-67 in this study could be the fact that the Ki67 clone used in FCM (clone B56) was different from the one used in IHC (clone MIB-1).

The clone B56 was used for FCM because in the authors' hands compatibility to the eBioscience Foxp3 /Transcription Factor Staining Buffer Set was superior. The Ki-67 antigen is known to be conserved between species. In IHC different clones were compared by Lindboe and colleagues in 2005 and MIB-1 and B56 were described as giving significantly higher indices than other 4 tested clones.<sup>43</sup> In this study the B56 antibody came close to MIB-1 with non-significant differences between these two.

A canine species specific clone does not exist.

To the authors knowledge there is no published data available proving the cross reactivity of the MIB-1 clone in dogs. However, it's successful application passed the reviewing process.<sup>29,31</sup> The BD data sheet states reactivity for mouse, rat, chicken and dog for B56, the dako MIB-1 does not mention any cross reactivity testing.

The fact that no significant difference was found between the clones does not replace appropriate testing with western blot analysis, but might suffice as an acceptable argument.

Common knowledge in the scientific community is that the surgical excision of a lymph node to perform histology and immunohistochemistry for the determination of histotype according to WHO classification is nowadays required in state of the art diagnostics. However, histopathology requires much more invasive sampling procedures, and duration of processing is much longer, so that availability of results is delayed. A major diagnostic advantage when dealing with lymphoproliferative disorders is their suitability to immediate analysis by FCM as fresh cell suspension samples, without complicated tissue

processing before antibody incubation. FCM allows for high accuracy the determination of lymphoma immunophenotype.<sup>26,44</sup> Regarding the subtype, the accuracy of FCM is high when the expression pattern identifies a known entity, as TZL and helps to discriminate TZL from the prognostically inferior more aggressive TCL.<sup>34,39,45-49</sup> The accuracy is lower when dealing with other entities such as centrocytic-centroblastic or lymphocytic lymphoma. In this study, FCM showed a substantial agreement with HE and IHC in the identification of the lymphoma subtype, with only two cases of DLBCL not correctly identified as BCL as a result of aberrant CD3 expression and two cases not showing any lineage marker for B- or T-cells. Thus, the use of histopathology and immunophenotyping can be limited to those cases in which a definitive WHO classification diagnosis is difficult to reach with cytology in combination with FCM, which means cases except TZL.<sup>38</sup> According to the current standards of care, for these difficult cases, histology and IHC are still the gold standard methods for final diagnosis.<sup>34</sup> In order to provide a state of the art diagnosis, histopathology was a mandatory inclusion requirement in this study.

Beside the Ki-67 expression investigated by two methods FCM and IHC, the immunophenotypic subclassification was compared between FCM and histopathology and showed highly concordant results represented in 94.3%. All TZL, PTCL and most BCL were in concordance. For lymphoblastic -TCL (L-TCL), L-BCL and MZL no characteristic FCM patterns are defined so far. The two cases showing a discrepant result were of mixed expression being positive in FCM for CD21 and CD3 and were diagnosed as one high CD3<sup>+</sup>, CD79<sup>acy+</sup> and one intermediate CD3<sup>+</sup>, CD79<sup>acy(+)</sup>, CD20<sup>+</sup> diffuse large B-cell lymphoma. Unfortunately, a reason for this could not be found. The two cases showing no lineage markers in FCM, being CD21 and CD3 negative were WHO diagnosed as one DLBCL and 1 L-BCL.

In conclusion, data show correlation between the values of Ki-67 expression/index assessed with FCM and IHC. Occasional discrepancies observed in a subset of cases had no apparent correlation with tumour characteristics. Nevertheless, because of the wide limits of agreement there is possible limitation to use the two methods in alternative way. Further studies on a larger number of cases are warranted to elucidate the cause of such differences.

## ACKNOWLEDGEMENT

This study was supported by the Travel Bursary assigned to junior scientists (AR) in 2018 by the Journal of Comparative Pathology Educational Trust.

## DATA AVAILABILITY STATEMENT

Data sharing is not applicable to this article as no new data were created or analyzed in this study.

## ORCID

Antonella Rigillo  <https://orcid.org/0000-0003-3303-7734>

Silvia Sabbatini  <https://orcid.org/0000-0001-7005-2736>

Ondrej Škor  <https://orcid.org/0000-0003-3107-2923>

Giuliano Bettini  <https://orcid.org/0000-0003-1857-7329>

Barbara C. Rütgen  <https://orcid.org/0000-0001-9080-0164>

## REFERENCES

- Bruno S, Darzynkiewicz Z. Cell cycle dependent expression and stability of the nuclear protein detected by Ki-67 antibody in HL-60 cells. *Cell Prolif*. 1992;25:31-40.
- Araújo MR, Campos LC, Damasceno KA, Gamba CO, Ferreira E, Cassali GD. HER-2, EGFR, Cox-2 and Ki67 expression in lymph node metastasis of canine mammary carcinomas: association with clinical-pathological parameters and overall survival. *Res Vet Sci*. 2016;106:121-130.
- Bergin IL, Smedley RC, Esplin DG, Spangler WL, Kiupel M. Prognostic evaluation of Ki67 threshold value in canine oral melanoma. *Vet Pathol*. 2011;48:41-53.
- Kiupel M, Camus M. Diagnosis and prognosis of canine mast cell tumors. *Vet Clin North Am Small Anim Pract*. 2019;49:819-836.
- Kreipe H. Ki67: biological intertumor variance versus variance of assay. *Pathologie*. 2018;39(Suppl 2):272-277.
- Penault-Llorca F, Radosevic-Robin N. Ki67 assessment in breast cancer: an update. *Pathology*. 2017;49:166-171.
- Soares M, Ribeiro R, Carvalho S, Peleteiro M, Correia J, Ferreira F. Ki-67 as a prognostic factor in feline mammary carcinoma: what is the optimal cutoff value? *Vet Pathol*. 2016;53:37-43.
- Bryant RJ, Banks PM, O'Malley DP. Ki67 staining pattern as a diagnostic tool in the evaluation of lymphoproliferative disorders. *Histopathology*. 2006;48:505-515.
- Carrasco V, Rodríguez-Bertos A, Rodríguez-Franco F, et al. Distinguishing intestinal lymphoma from inflammatory bowel disease in canine duodenal endoscopic biopsy samples. *Vet Pathol*. 2015;52:668-675.
- Sabbatini S, Bassi P, Bettini G. Histopathological findings and proliferative activity of canine sebaceous gland tumours with a predominant reserve cell population. *J Comp Pathol*. 2015;152:145-152.
- Sabbatini S, Lopparelli RM, Rigillo A, et al. Canine splenic nodular lymphoid lesions: immunophenotyping, proliferative activity, and clonality assessment. *Vet Pathol*. 2018;55:645-653.
- Fu DR, Kato D, Endo Y, Kadosawa T. Apoptosis and Ki-67 as predictive factors for response to radiation therapy in feline nasal lymphomas. *J Vet Med Sci*. 2016;78:1161-1166.
- Melzer K, Guscetti F, Rohrer Bley C, Sumova A, Roos M, Kaser-Hotz B. Ki67 reactivity in nasal and periocular squamous cell carcinomas in cats treated with electron beam radiation therapy. *J Vet Intern Med*. 2006;20:676-681.
- Schlotter CM, Tietze L, Vogt U, Heinsen CV, Hahn A. Ki67 and lymphocytes in the pretherapeutic core biopsy of primary invasive breast cancer: positive markers of therapy response prediction and superior survival. *Horm Mol Biol Clin Investig*. 2017;32(2):20170022.
- Kiupel M, Teske E, Bostock D. Prognostic factors for treated canine malignant lymphoma. *Vet Pathol*. 1999;36:292-300.
- Phillips BS, Kass PH, Naydan DK, Winthrop MD, Griffey SM, Madewell BR. Apoptotic and proliferation indexes in canine lymphoma. *J Vet Diagn Invest*. 2000;12:111-117.
- Sierra Matiz OR, Santilli J, Anai LA, et al. Prognostic significance of Ki67 and its correlation with mitotic index in dogs with diffuse large B-cell lymphoma treated with 19-week CHOP-based protocol. *J Vet Diagn Invest*. 2018;30:263-267.
- Sokolowska J, Micun J, Malicka E, Lechowski R. Proliferation activity in canine lymphomas. *Pol J Vet Sci*. 2012;15:727-734.
- Blaker YN, Brodtkorb M, Maddison J, et al. Computerized image analysis of the Ki-67 proliferation index in mantle cell lymphoma. *Histopathology*. 2015;67:62-69.
- Gaudio F, Tamma R, Ingravallo G, et al. Computer-driven quantitative image analysis in the assessment of tumor cell and T cell features in diffuse large B cell lymphomas. *Ann Hematol*. 2018;97:663-668.
- Hida AI, Bando K, Sugita A, et al. Visual assessment of Ki67 using a 5-grade scale (Eye-5) is easy and practical to classify breast cancer subtypes with high reproducibility. *J Clin Pathol*. 2015;68:356-361.

22. Klimowitz AC, Bose P, Nakoneshny SC, et al. Basal Ki67 expression measured by digital image analysis is optimal for prognostication in oral squamous cell carcinoma. *Eur J Cancer*. 2012;48:2166-2174.
23. Maeda I, Abe K, Koizumi H, et al. Comparison between Ki67 labelling index determined using image analysis software with virtual slide system and that determined visually in breast cancer. *Breast Cancer*. 2016;23:745-751.
24. Røge R, Riber-Hansen R, Nielsen S, Vyberg M. Proliferation assessment in breast carcinomas using digital image analysis based on virtual Ki67/cytokeratin double staining. *Breast Cancer Res Treat*. 2016;158:11-19.
25. Wang LW, Qu AP, Liu WL, et al. Quantum dots-based double imaging combined with organic dye imaging to establish an automatic computerized method for cancer Ki67 measurement. *Sci Rep*. 2016;6:20564.
26. Burkhard MJ, Bienzle D. Making sense of lymphoma diagnostics in small animal patients. *Vet Clin North Am Small Anim Pract*. 2013;43:1331-1347.
27. Reggeti F, Bienzle D. Flow cytometry in veterinary oncology. *Vet Pathol*. 2011;48:223-235.
28. Rout ED, Avery PR. Lymphoid neoplasia correlations between morphology and flow cytometry. *Vet Clin North Am Small Anim Pract*. 2017;47:53-70.
29. Poggi A, Miniscalco B, Morello E, et al. Flow cytometric evaluation of Ki67 for the determination of malignancy grade in canine lymphoma. *Vet Comp Oncol*. 2015;13:475-480.
30. Miniscalco B, Poggi A, Martini V, et al. Flow cytometric characterization of S-phase fraction and Ploidy in lymph node aspirates from dogs with lymphoma. *J Comp Pathol*. 2018;161:34-42.
31. Poggi A, Miniscalco B, Morello E, et al. Prognostic significance of Ki67 evaluated by flow cytometry in dogs with high-grade B-cell lymphoma. *Vet Comp Oncol*. 2017;15:431-440.
32. Valli VE, San Myint M, Barthel A, et al. Classification of canine malignant lymphomas according to the World Health Organization criteria. *Vet Pathol*. 2011;48:198-211.
33. Valli VE, Kiupel M, Bienzle D. Hematopoietic system. In: Maxie GM, ed. *Jubb, Kennedy, and Palmer's Pathology of Domestic Animals*. Vol 3, 218. 6th ed. Saint Louis, MO: Saunders Elsevier; 2016.
34. Valli VE, Kass PH, San Myint M, Scott F. Canine lymphomas: association of classification type, disease stage, tumor subtype, mitotic rate, and treatment with survival. *Vet Pathol*. 2013;50:738-748.
35. Schindelin J, Arganda-Carreras I, Frise E, et al. Fiji: an open-source platform for biological-image analysis. *Nat Methods*. 2012;9:676-682.
36. Rütgen BC, Hammer SE, Gerner W, et al. Establishment and characterization of a novel canine B-cell line derived from a spontaneously occurring diffuse large cell lymphoma. *Leuk Res*. 2010;34:932-938.
37. Rao S, Lana S, Eickhoff J, et al. Class II major histocompatibility complex expression and cell size independently predict survival in canine B-cell lymphoma. *J Vet Intern Med*. 2011;25:1097-1105.
38. Seelig DM, Avery P, Webb T, et al. Canine T-zone lymphoma: unique immunophenotypic features, outcome, and population characteristics. *J Vet Int Med*. 2014;28:878-886.
39. Valli VE, Bienzle D, Meuten DE. Tumors of the hemolymphatic system. In: Donald M, ed. *Tumors in Domestic Animals*. 5th ed. Wiley Blackwell: Meuten; 2017:203-321.
40. Valli VE, Vernau W, de Lorimier LP, Graham PS, Moore PF. Canine indolent nodular lymphoma. *Vet Pathol*. 2006;43(3):241-256. <https://doi.org/10.1354/vp.43-3-241>.
41. Gerdes J, Dallenbach F, Lennert K, Lemke H, Stein H. Growth fractions in malignant non-Hodgkin's lymphomas (NHL) as determined in situ with the monoclonal antibody Ki-67. *Hematol Oncol*. 1984;2:365-371.
42. Hall PA, Richards MA, Gregory WM, d'Ardenne AJ, Lister TA, Stansfeld AG. The prognostic value of Ki-67 immunostaining in non-Hodgkin's lymphoma. *J Pathol*. 1988;154:223-235.
43. Lindboe CF, Lykander LG, Bjørnsetol HH. Comparison of monoclonal Ki-67 equivalent antibodies. *J Histotechnol*. 2005;28:25-27.
44. Comazzi S, Gelain ME. Use of flow cytometric immunophenotyping to refine the cytological diagnosis of canine lymphoma. *Vet J*. 2011;188:149-155.
45. Avery PR, Burton J, Bromberek JL, et al. Flow cytometric characterization and clinical outcome of CD4+ T-cell lymphoma in dogs: 67 cases. *J Vet Intern Med*. 2014;28:538-546.
46. Deravi N, Berke O, Woods JP, Bienzle D. Specific immunotypes of canine T cell lymphoma are associated with different outcomes. *Vet Immunol Immunopathol*. 2017;191:5-13.
47. Harris LJ, Rout ED, Labadie JD, et al. Clinical features of canine nodal T-cell lymphomas classified as CD8+ or CD4-CD8- by flow cytometry. *Vet Comp Oncol*. 2020;18:416-427.
48. Martini V, Marconato L, Poggi A, et al. Canine small clear cell/T-zone lymphoma: clinical presentation and outcome in a retrospective case series. *Vet Comp Oncol*. 2016;14:117-126.
49. Mizutani N, Goto-Koshino Y, Tsuboi M, et al. Evaluation of CD25-positive cells in relation to the subtypes and prognoses in various lymphoid tumours in dogs. *Vet Immunol Immunopathol*. 2016;173:39-43.

## SUPPORTING INFORMATION

Additional supporting information may be found online in the Supporting Information section at the end of this article.

**How to cite this article:** Rigillo A, Fuchs-Baumgartinger A, Sabattini S, et al. Ki-67 assessment—agreeability between immunohistochemistry and flow cytometry in canine lymphoma. *Vet Comp Oncol*. 2021;19:551-566. <https://doi.org/10.1111/vco.12694>