

Endometrial carcinoma: past, present, and future

Anna Myriam Perrone^{1,2,3,*}, Antonio De Leo^{2,4,5}, Dario de Biase^{2,5,6}, Gloria Ravegnini^{1,6}, Pierandrea De Iaco^{1,2,3}

¹Division of Oncologic Gynecology Unit, IRCCS-Azienda Ospedaliero-Universitaria di Bologna, 40138 Bologna, Italy

²Centro di Studio e Ricerca delle Neoplasie Ginecologiche (CSR), University of Bologna, 40138 Bologna, Italy

³Department of Medical and Surgical Sciences (DIMEC), University of Bologna, 40138 Bologna, Italy

⁴Department of Experimental, Diagnostic and Specialty Medicine, University of Bologna, Via Massarenti 9, 40138 Bologna, Italy

⁵Molecular Pathology Laboratory, IRCCS Azienda Ospedaliero-Universitaria di Bologna/Azienda USL di Bologna, 40138 Bologna, Italy

⁶Department of Pharmacy and Biotechnology, University of Bologna, 40126 Bologna, Italy

*Correspondence: myriam.perrone@aosp.bo.it (Anna Myriam Perrone)

DOI: [10.31083/j.ejgo4204094](https://doi.org/10.31083/j.ejgo4204094)

This is an open access article under the CC BY 4.0 license (<https://creativecommons.org/licenses/by/4.0/>).

Submitted: 25 June 2021 Accepted: 30 June 2021 Published: 15 August 2021

Endometrial carcinoma (EC) is one of the most frequent malignant gynecological cancers, and in particular in the industrialized countries with a high standard of living and a food surplus [1]. About 69% of endometrial tumors are diagnosed at early stage and about 83% of women survive five years after diagnosis. The mechanisms that predispose to EC, especially the most common ones, are well known. It is a multifactorial disease, based on lifestyles and complex genetic and epigenetic factors. This etiopathogenic complexity outlines an intrinsically complex pathology. However, for years, this disease has been simply divided and trivialized into two main groups: estrogen-dependent (type I) and estrogen-independent (type II) [2, 3]. The EC is considered a cancer with a favorable prognosis and widely spread, so the literature has not reported hypotheses of centralization of treatment. It is a tumor, therefore, far from the well-defined diagnostic-therapeutic structure of ovarian carcinoma, rarer and more lethal. But over time, when we daily deal with this type of cancer, we realize that not all ECs have a favorable prognosis, and some of them resemble ovarian carcinoma. This happens not only for Type II but also for some Type I tumors that sometimes show a surprisingly unexpected aggressive behavior [2]. The European Society for Medical Oncology (ESMO) has identified specific prognostic factors (i.e., age, FIGO stage, histotype, depth of myometrial invasion, lymphovascular space invasion, and lymph node metastases) on which clinicians based the multidisciplinary therapeutic approach (surgery, radiotherapy, and chemotherapy) [4–6]. However, the conventional risk stratification system appears to be insufficient and inadequately informative in current clinical practice. Specifically, from a surgical point of view, traditional parameters are not fully appropriate to define the role and clinical relevance of lymphadenectomy [7]. In this regard, randomized trials have provided uncertain results, leaving the sentinel lymph node to solve the long-standing problem of lymph node staging [8, 9]. In addition,

the traditional classification/prognostic system is also imperfect for the selection of patients for possible adjuvant treatment: the indication for radiotherapy and/or chemotherapy often remains a multi-optional choice. Although the preliminary PORTEC studies have tried to clarify this complex issue, current clinical practice often presents challenges in identifying the most appropriate therapeutic approach [10]. Finally, the sole histopathological parameters used to identify risk factors are not always easily reproducible, particularly in high-grade carcinomas and those with intratumoral heterogeneity. All these factors suggest that EC is inappropriately treated due to subjective interpretation of clinico-pathologic characteristics even by experienced clinicians.

In 2013, the results of The Cancer Genome Atlas (TCGA) project have revolutionized the knowledge of endometrial cancer both from a biological and clinical point of view [11]. Specifically, the TCGA study has introduced a new molecular classification of EC with a relevant prognostic impact and thus a potential implication in the clinical management of patients [11]. The TCGA analysis emphasizes that EC does not represent a single entity, but a group of tumors that may share genomic features with serous ovarian cancer, basal-like breast cancers, and colorectal cancer. Moreover, some endometrioid and serous tumors are molecularly distinct, while others are similar, suggesting that some ECs may benefit from common treatment. Based on this classification, four EC subgroups have been identified: (i) ultra-mutated tumors characterized by pathogenic variants in the exonuclease domain of DNA polymerase-epsilon (*POLE*); (ii) hyper-mutated carcinomas characterized by microsatellite instability (MSI); (iii) a copy-number low group with a low mutational burden; and (iv) a copy-number high group with frequent *TP53* mutations (Fig. 1).

These subgroups differ not only at the molecular and pathological level but also in their prognosis. In particular, *POLE* mutated EC patients have an exceptionally good

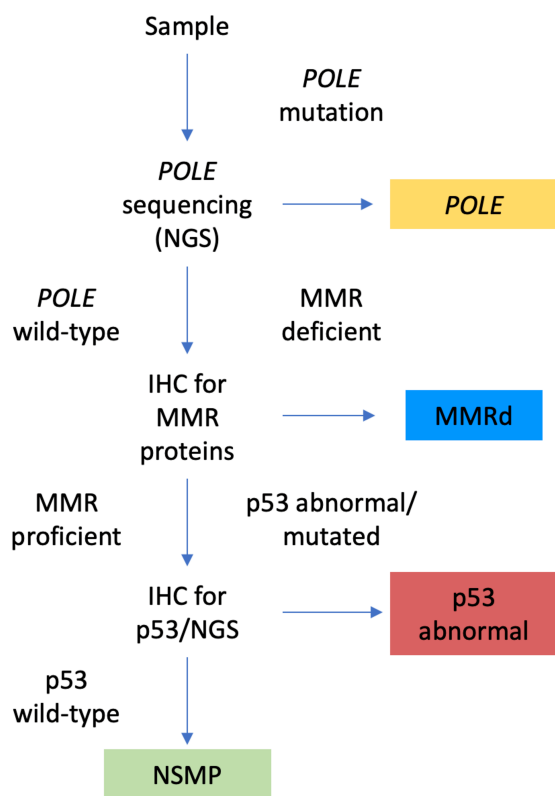


Fig. 1. The figure shows the algorithm used to define to which subclass of the new molecular classification (TCGA) the tissue under examination belongs.

prognosis despite their association with high-grade histology, while copy-number high ECs show poor outcome, even when diagnosed at early stage [12]. Therefore, these molecular characteristics can be used not only for patient classification and risk stratification but also to adapt surgery, adjuvant strategies, and patient observation. The molecular classes proposed by the TCGA have been fundamental in evolving the dualistic Bokhman model into a more refined and molecular-based system. To translate TCGA molecular groups into clinical practice, two groups have proposed and validated molecular classifiers using surrogate markers (*POLE* sequencing, microsatellite instability, and p53 mutation/alteration) to identify the different EC classes. The “surrogate” molecular subgroups identified by these approaches are similar but not identical to the four genomic subtypes described by TCGA: (i) the DNA polymerase Epsilon (*POLE*), with mutations in the exonuclease domain in exons 9–14, corresponds to the ultramutated subtype; (ii) tumors with mismatch repair deficiency (MMRd), which shows the loss of one or more mismatch repair proteins, corresponding to the hypermutated subtype [13]; (iii) p53 abnormal (p53abn) tumors showing an aberrant p53 immunostaining, corresponding to the copy-number high subtype; (iv) p53 wild-type (p53wt) or so-called with no specific molecular profile—NSMP ECs corresponding to the copy-number low group.

Different to TCGA analysis which was performed on fresh frozen tissue using expensive and complex molecular techniques, the surrogate algorithms can be applied to formalin-fixed and paraffin-embedded (FFPE) material using methods routinely applied in pathology laboratories at most cancer centers. This has led to a diagnostic algorithm that incorporated molecular characteristics, resulting in a novel, more objective, and clinically meaningful EC classification that has been also suggested by the most recent 2020 World Health Organization Classification of Female Genital Tumors and ESGO/ESTRO/ESP guidelines [14–16]. However, independently by the molecular subtype, certain histopathological characteristics, such as the extent of lymphovascular space invasion (LVSI) and stage, do not have a molecular surrogate and will remain essential in the pathological assessment. It is reasonable that molecular and clinicopathologic prognostic grouping systems will likely work better together.

The novelty of the new classification has led to a concordance between biopsy samples, curettage, and final hysterectomy, thus providing information that could be used to plan the timing and extent of the surgery.

But the story does not end here, and we expect further episodes hoping for a happy ending especially in the refinement of new molecular prognostic factors. Currently, it is unclear how other potential molecular prognostic factors, such as mutations in *CTNNB1* or *PIK3CA* genes, and L1CAM overexpression, should be integrated into TCGA EC subgroups.

The great innovation of the new molecular classification has overwhelmed all the main research groups dealing with gynaecological oncology that have applied and validated the results of the two groups (PORTEC and ProMisE) comparing the old classification with the new ones [17, 18]. Recently, our group has investigated the feasibility and the prognostic impact of the surrogate TCGA molecular classification of endometrial carcinoma into the clinical setting proposing an immuno-molecular algorithm for improving risk stratification, in particular in the NSMP tumors [19].

In conclusion, we believe that the new TCGA classification may help to standardize the prognostic stratification of patients could provide a framework for subclass-specific study designs that should be developed in the coming years to examine the potential benefit of personalized management of patients. However, there are still open biological and clinical questions to be investigated regarding the identification of specific markers associated with tumor aggressiveness and metastatic potential, and for early detection, disease monitoring, and targeted therapies.

New realities knock on the door of the EC landscape such as liquid biopsy (circulating cells, cDNA, and miRNAs) and to these, artificial intelligence will shortly be added. The integration of all these aspects will ultimately result in the customization of therapy based on the complexity and heterogeneity of the disease. However, the emerging complexity of EC requires treatment in certified high-volume centers that

match specific parameters similarly to those already in place for ovarian cancer. In this context, the European Society of Gynecological Oncology (ESGO) is in the process of preparing a document defining these problems.

Author contributions

Conceptualization AMP; Writing the paper: AMP, ADL, DdB, GR; Supervision: PDI. All authors read and approved the final manuscript.

Ethics approval and consent to participate

Not applicable.

Acknowledgment

The authors thank the multidisciplinary team of the IR-CCS Azienda Ospedaliero-Universitaria di Bologna for their daily collaboration in the decision-making process for the treatment of gynecological cancer patients. In particular Donatella Santini, Andrea Galuppi, Claudio Zamagni, Daniela Turchetti, Daniela Rubino and Martina Ferioli.

Funding

This research received no external funding.

Conflict of interest

The authors declare no conflict of interest.

References

- [1] Ferlay J, Colombet M, Soerjomataram I, Dyba T, Randi G, Bettio M, *et al.* Cancer incidence and mortality patterns in Europe: Estimates for 40 countries and 25 major cancers in 2018. *European Journal of Cancer*. 2018; 103: 356–387.
- [2] Setiawan VW, Yang HP, Pike MC, McCann SE, Yu H, Xiang Y, *et al.* Type I and II endometrial cancers: have they different risk factors? *Journal of Clinical Oncology*. 2013; 31: 2607–2618.
- [3] Prat J, Gallardo A, Cuatrecasas M, Catasús L. Endometrial carcinoma: pathology and genetics. *Pathology*. 2007; 39: 72–87.
- [4] Matoda M, Omatsu K, Yamamoto A, Nomura H, Tanigawa T, Kawamata Y, *et al.* Importance of platinum-free interval in second-line chemotherapy for advanced or recurrent endometrial cancer. *European Journal of Gynaecological Oncology*. 2014; 35: 224–229.
- [5] Perrone AM, Marcobberardino BB Di, Rossi MM, *et al.* Laparoscopic versus laparotomic approach to endometrial cancer. *European Journal of Gynaecological Oncology*. 2012; 33: 376–381.
- [6] Ditto A, Casarin J, Pinelli C, Perrone AM, Scollo P, Martinelli F, *et al.* Hysteroscopic versus cervical injection for sentinel node detection in endometrial cancer: a multicenter prospective randomised controlled trial from the Multicenter Italian Trials in Ovarian cancer (MITO) study group. *European Journal of Cancer*. 2020; 140: 1–10.
- [7] Schuurman TN, Stiekema A, Schagen van Leeuwen JH, Verheijen RHM. Systematic lymphadenectomy in patients with clinical stage II endometrial carcinoma: a case report and review of the literature. *European Journal of Gynaecological Oncology*. 2012; 33: 530–533.
- [8] Pendlebury A, Radeva M, Rose PG. Surgical lymph node assessment influences adjuvant therapy in clinically apparent stage I endometrioid endometrial carcinoma, meeting Mayo criteria for lymphadenectomy. *Journal of Surgical Oncology*. 2021; 123: 1292–1298.
- [9] Bogani G, Papadia A, Buda A, Casarin J, Di Donato V, Gasparri ML, *et al.* Sentinel node mapping vs. sentinel node mapping plus back-up lymphadenectomy in high-risk endometrial cancer patients: Results from a multi-institutional study. *Gynecologic Oncology*. 2021; 161: 122–129.
- [10] Creutzberg CL, van Putten WL, Koper PC, Lybeert ML, Jobsen JJ, Wárlám-Rodenhuis CC, *et al.* Surgery and postoperative radiotherapy versus surgery alone for patients with stage-1 endometrial carcinoma: multicentre randomised trial. *The Lancet*. 2000; 355: 1404–1411.
- [11] Levine DA. Integrated genomic characterization of endometrial carcinoma. *Nature*. 2013; 497: 67–73.
- [12] Espinosa I, De Leo A, D'Angelo E, Rosa-Rosa JM, Corominas M, Gonzalez A, *et al.* Dedifferentiated endometrial carcinomas with neuroendocrine features: a clinicopathologic, immunohistochemical, and molecular genetic study. *Human Pathology*. 2018; 72: 100–106.
- [13] Dondi G, Coluccelli S, De Leo A, Ferrari S, Gruppioni E, Bovicelli A, *et al.* An analysis of clinical, surgical, pathological and molecular characteristics of endometrial cancer according to mismatch repair status. A multidisciplinary approach. *International Journal of Molecular Sciences*. 2020; 21: 1–17.
- [14] IARC Publications Website. Female Genital Tumours. 2020. Available at: <https://publications.iarc.fr/Book-And-Report-Series/Who-Classification-Of-Tumours/Female-Genital-Tumours-2020> (Accessed: 24 June 2021).
- [15] Concin N, Matias-Guiu X, Vergote I, Cibula D, Mirza MR, Marnitz S, *et al.* ESGO/ESTRO/ESP guidelines for the management of patients with endometrial carcinoma. *International Journal of Gynecologic Cancer*. 2021; 31: 12–39.
- [16] De Leo A, Santini D, Ceccarelli C, Santandrea G, Palicelli A, Acquaviva G, *et al.* What Is New on Ovarian Carcinoma: Integrated Morphologic and Molecular Analysis Following the New 2020 World Health Organization Classification of Female Genital Tumors. *Diagnostics*. 2021; 11: 697.
- [17] Wortman BG, Creutzberg CL, Putter H, Jürgenliemk-Schulz IM, Jobsen JJ, Lutgens LCHW, *et al.* Ten-year results of the PORTEC-2 trial for high-intermediate risk endometrial carcinoma: improving patient selection for adjuvant therapy. *British Journal of Cancer*. 2018; 119: 1067–1074.
- [18] Kommos S, McConechy MK, Kommos F, Leung S, Bunz A, Magrill J, *et al.* Final validation of the ProMisE molecular classifier for endometrial carcinoma in a large population-based case series. *Annals of Oncology*. 2018; 29: 1180–1188.
- [19] De Leo A, de Biase D, Lenzi J, Barbero G, Turchetti D, Grillini M, *et al.* Arid1a and ctnnb1/ β -catenin molecular status affects the clinicopathologic features and prognosis of endometrial carcinoma: Implications for an improved surrogate molecular classification. *Cancers*. 2021; 13: 1–22.