

Alma Mater Studiorum Università di Bologna
Archivio istituzionale della ricerca

Value of first-trimester assessment in prediction of third trimester sonographic stage of placenta accreta spectrum disorder and surgical outcome

This is the final peer-reviewed author's accepted manuscript (postprint) of the following publication:

Published Version:

Cali, G., Timor-Tritsch, I., Forlani, F., Palacios-Jaraquemada, J., Monteagudo, A., Kaelin Agten, A., et al. (2020). Value of first-trimester assessment in prediction of third trimester sonographic stage of placenta accreta spectrum disorder and surgical outcome. *ULTRASOUND IN OBSTETRICS & GYNECOLOGY*, 55(4), 450-459 [10.1002/uog.21939].

Availability:

This version is available at: <https://hdl.handle.net/11585/849769> since: 2022-01-31

Published:

DOI: <http://doi.org/10.1002/uog.21939>

Terms of use:

Some rights reserved. The terms and conditions for the reuse of this version of the manuscript are specified in the publishing policy. For all terms of use and more information see the publisher's website.

This item was downloaded from IRIS Università di Bologna (<https://cris.unibo.it/>).
When citing, please refer to the published version.

(Article begins on next page)

Integration of first-trimester assessment in the ultrasound staging of placenta accreta spectrum disorders

Giuseppe Cali^{1,2}, Ilan Timor-Tritsch³, Francesco Forlani², Josè Palacios-Jaraquemada⁴, Ana Monteagudo⁵, Andrea Kaelin Agten⁶, Maria Elena Flacco⁷, Asma Khalil⁸, Danilo Buca⁹, Lamberto Manzoli⁷, Marco Liberati⁹, Francesco D'Antonio¹⁰

- 1: Department of Obstetrics and Gynaecology, Azienda Ospedaliera Villa Sofia Cervello, Palermo, Italy
2: Department of Obstetrics and Gynaecology, Arnas Civico Hospital, Palermo, Italy
3: Department of Obstetrics and Gynaecology, Division of Maternal-Fetal Medicine, New York University SOM, New York, NY, USA
4: Centre for Medical Education and Clinical Research (CEMIC), University Hospital, Buenos Aires, Argentina
5: Department of Obstetrics, Gynecology and Reproductive Science, Icahn School of Medicine at Mount Sinai, New York, New York
6: Fetal Medicine Unit, St George's University Hospital NHS Foundation Trust, London, UK
7: Department of Medical Sciences, University of Ferrara
8: Fetal medicine Unit, Division of developmental Sciences, St. George's University of London, London, United Kingdom
9: Department of Obstetrics and Gynaecology, University of Chieti, Chieti, Italy
10: Fetal Medicine Unit, Department of Medical and Surgical Sciences, Department of Obstetrics and Gynecology, University of Foggia, Foggia, Italy

Corresponding Author:

Francesco D'Antonio, MD, PhD
Fetal Medicine Unit
Department of Medical and Surgical Sciences,
Department of Obstetrics and Gynecology
University of Foggia
Viale L. Pinto, 71100 Foggia, Italy
E-mail address: dantoniofra@gmail.com

Short title: Integration of first trimester assessment in PAS

Keywords: placenta accreta spectrum, cross-over sign, ultrasound

This article has been accepted for publication and undergone full peer review but has not been through the copyediting, typesetting, pagination and proofreading process which may lead to differences between this version and the Version of Record. Please cite this article as doi: 10.1002/uog.21939

CONTRIBUTION

What are the novel findings of this work?

Early sonographic assessment at (5-7 postmenstrual weeks) can predict PAS stage in women at high risk for these anomalies. COS1 and implantation of the gestational sac “in the niche” of the prior CS scar and “below the line” were independently associated and predictive of severe stages of PAS in the third trimester of pregnancy.

What are the clinical implications of this work?

first trimester US can help in the risk stratification of women affected by PAS and it is able to identify a large proportion of women who will be affected by the most severe types of these anomalies. COS1 and implantation of the gestational sac “in the niche” and “below the line” were independently associated with adverse surgical outcome.

This article has been accepted for publication and undergone full peer review but has not been through the copyediting, typesetting, pagination and proofreading process which may lead to differences between this version and the Version of Record. Please cite this article as doi: 10.1002/uog.21939

ABSTRACT

Objective: To explore the role of early first trimester ultrasound at 5-7 postmenstrual weeks of gestation in predicting sonographic staging of placenta accreta spectrum (PAS) and to elucidate whether integrating first trimester assessment with ultrasound staging of PAS can predict surgical outcome in women at risk for PAS.

Methods: Secondary analysis of prospectively collected data of women who had at least one previous caesarean delivery (CD) or uterine surgery and placenta previa for whom early (5-7 weeks of gestation) ultrasound images could be retrieved. The relationship between gestational sac position and prior CD scar was assessed using classifications by Cali et al. (cross-over COS), Kaelin Agten et al. ("on the scar" vs "in the niche" implantation) and Timor-Tritsch et al. ("above the line" vs "below the line" implantation) by two different examiners blinded to the final diagnosis and clinical outcome. Primary aim of the study was to explore the strength of association and predictive accuracy of first trimester ultrasound in predicting PAS stage. Secondary aim was to elucidate whether integration of first trimester ultrasound with PAS staging can predict surgical outcome. Logistic regression and area under the curve analyses were used to analyse the data.

Results: One hundred and eighty-seven women were included. Of these, 79.6% (95% CI 67.1-88.2) had COS1, 94.4% (95% CI 84.9-98.1) "in the niche" and 92.6% (95% CI 82.4-97.1) "below the line" implantation confirmed to be affected by PAS3 in the third trimester of pregnancy. On multivariate logistic regression analysis, COS1 (OR: 7.9 (95% CI 4.0-15.5; $p < 0.001$), "in the niche" (OR: 29.1, 95% CI 8.1-104; $p < 0.001$) and "below the line" (OR: 38.1, 95% CI 12.1-121; $p < 0.001$) implantations, however, neither parity ($p = 0.4$), nor the number of prior CDs ($p = 0.5$) were independently associated with PAS3. When translating these figures in a diagnostic model, either COS1 (AUC: 0.94, 95% CI 0.91-0.97), or implantation "in the niche" (AUC: 0.92, 95% CI 0.89-0.96) or "below the line" (AUC: 0.92, 95% CI 0.88-0.96) had a high predictive accuracy for PAS3. Adverse surgical outcome was more common in women with COS1 ($p < 0.001$), implantation "in the niche" ($p < 0.001$) and "below the line" ($p < 0.001$) than those without them. On multivariate logistic regression analysis, ultrasound diagnosis of PAS3 (OR: 4.3, 95% CI 2.1-17.3), COS1 (OR: 7.9, 95% CI 4.0-15.5; $p < 0.001$), "in the niche" (OR: 29.1, 95% CI 8.1-104; $p < 0.001$) and "below the line" (OR: 7.9, 95% CI 4.0-15.5; $p < 0.001$) implantations were independently associated with adverse surgical outcome. When combining the three imaging methods, we identified, an area we call "high-risk-for-PAS Triangle"

This article has been accepted for publication and undergone full peer review but has not been through the copyediting, typesetting, pagination and proofreading process which may lead to differences between this version and the Version of Record. Please cite this article as doi: 10.1002/uog.21939

which may enable an easy visual perception and application of the three methods to prognosticate the risk for CSP and PAS, although it requires validation in further large prospective studies.

Conclusion: Early first trimester sonographic assessment of pregnancies after CDs can reliably predict ultrasound staging of possible PAS. Integrating first with second and third trimester ultrasound can stratify surgical risk of women affected by PAS.

INTRODUCTION

Placenta accreta spectrum (PAS) disorders encompasses a heterogenous group of conditions characterized by an abnormal adhesion to, and invasion of trophoblastic tissue through the myometrium and uterine serosa¹⁻⁴. Although the natural history of PAS disorders has not been completely elucidated yet, placenta previa and prior caesarean delivery (CD) or uterine surgery represents its main risk factors^{4,5}. Furthermore, recent evidence supports the role of caesarean scar pregnancy (CSP) as an early precursor of PAS⁶⁻⁹.

Advances in prenatal imaging have led to an increase of the detection rate of PAS, which in turn has improved their surgical outcome¹⁰⁻¹⁵. We published recently on prenatal staging of PAS based upon a number of ultrasound (US) signs in women at high risk for these disorders¹⁶. However, this staging system did not take into account the role of first trimester US findings.

Early first trimester (5-7 postmenstrual weeks of gestation) US has been recently shown to predict the possibility of developing PAS in women at high risk for this anomaly, thus supporting the role of early sonographic evaluation as a potential early predictor of surgical complications of PAS¹⁷⁻²¹.

The primary aim of this study was to elucidate whether retrospective early first trimester assessment (at 5-7 postmenstrual weeks of gestation) can correlate with US staging of PAS in the second half of pregnancy. Secondary aim was to explore whether combining first trimester assessment in the sonographic staging of PAS can stratify the risk of surgical outcome in these pregnancies.

METHODS

Study population

This is a secondary retrospective analysis of a previous, prospective longitudinal study on the diagnostic performance of US in detecting PAS including women with placenta previa and at least one prior CD or uterine surgery between 2009 and 2018²². All women had a longitudinal bimonthly assessment in the second and third trimester of pregnancy as per local guidelines, in order to detect PAS. STROBE guidelines were followed²³.

Ultrasound assessment was performed via transvaginal and transabdominal US in all cases. All examinations were originally performed using a 4.0-6.0 MHz curved transabdominal or 5.0-7.0 MHz transvaginal transducers (GE Voluson® 730, General Electrics and Samsung WS80A with Elite, Samsung); when using Colour Doppler US the pulsed rate frequency (PRF) was initially set at 1.3 KHz but it was lowered in order to identify the presence of placental lacunar flow.

According to the distribution of the classical ultrasound signs of PAS, each case was labelled according to our previously proposed US staging:^{16,24}

PAS0: Placenta previa with no US signs of invasion or placenta previa with placental lacunae but no evidence of abnormal uterine-bladder interface (loss of the clear zone and/or bladder wall interruption).

PAS1: Presence of at least two of the following ultrasound signs:

- Placental lacunae
- Loss of the clear anechoic zone of the myometrium
- Bladder wall interruption

PAS2: PAS1 + uterovescical hypervascularity

PAS3: PAS1/PAS2 + evidence of increased vascularity in the inferior part of the lower uterine segment extending in the parametrial region.

Early first trimester ultrasound images from 5 to 7 postmenstrual weeks of gestations were retrieved from the computerized database of each referring hospital and the relationship between the gestational sac and the prior CD scar was assessed according to the classification reported by Cali et al. (“cross-over sign”, [COS])^{17,18}, Kaelin Agten et al. (“on the scar” vs. “in the niche” implantation)¹⁹ and

Timor-Tritsch et al. (“below the line” vs. “above the line” implantation)²⁰ by two different examiners blinded to the final diagnosis and clinical outcome. A detailed description of first trimester assessment of the relationship between the prior CS and the gestational sac according to the three different classification system is reported in Appendix 1 and Figure 1 A, B,C and D.

Clinical management of PAS disorders

All women with a prenatal and intra-operative diagnosis of PAS were treated with caesarean hysterectomy and pre-operative temporary occlusion of internal iliac arteries using balloon catheters²⁵⁻²⁷. For those cases showing sonographic evidence of PAS and no clear placental invasion at direct visualization, after the delivery of the fetus and clamping of the cord, the balloon catheters were inflated and an attempt to expel the placenta performed. This was aided by administering intravenous carbetocin (Duratocin, Ferring, Italy) and controlled cord traction. In the event of failed placental detachment, hysterectomy was performed, preserving the adnexa and leaving the placenta in situ. Conversely, for cases showing placental tissue protruding through the uterine serosa, a longitudinal incision on the uterine fundus was performed to deliver the fetus, followed by cesarean hysterectomy without any attempt to remove the placenta.

Finally, women presenting with placenta previa with no US evidence of PAS had CD with an incision performed on the lower uterine segment without the use of interventional radiology techniques. The multidisciplinary team remained the same through the study period.

No attempt was made to leave the placenta in situ in order to delay surgery and women undergoing conservative surgical technique (including TRIPLE-P or one step conservative surgery) excluded from the study not to bias the analysis.

Prenatal pregnancy management, timing of deliveries and surgical technique were independent of the third US grading of PAS or first trimester type of implantation.

Data analysis

In a sample of women diagnosed with PAS disorder ranging from PAS-0 to PAS-3, we investigated the relationship between first trimester implantation of the gestational sac, defined according to the three classifications system reported by Cali et al.^{17,18} (“cross-over sign”, [COS]), Kaelin Agten et al.¹⁹ (“on the scar” vs. “in the niche” implantation) and Timor-Tritsch et al.²⁰ (“below the line” vs.

“above the line” implantation) and the following clinical variables: (1) a third-trimester diagnosis of PAS-3 (versus lower PAS grades); (2) Adverse surgical events occurring during delivery. The latter contained (a composite outcome including: (a) estimated blood loss >1500 mL; (b) transfusion of >5 units of red blood cells, platelets and fresh frozen plasma; (c) surgical complications; (d) admission to Intensive Care Unit).

The potential association between all recorded gestational and ultrasound parameters and the two outcomes were first evaluated with standard univariate analyses (chi-squared test for categorical variables; Kruskal-Wallis test for continuous variables), and then fitting multiple logistic regression models. A stepwise forward process was used for all models building, and the following criteria were adopted for covariates selection: (a) $p < 0.05$ at univariate analyses; (b) clinical significance; (c) COS type (treated as an ordinal variable), cesarean scar implantation (categorized into “in the niche” versus “on the scar” or “normal”) or site of implantation (categorized into “below” versus “above the line”) forced to entry in separate models as mutually exclusive variables, due to their overlapping clinical significance. A total of three and four logistic models were built for PAS-3 and adverse surgical outcome, respectively. As parity status and number of previous CD were collinear, we chose to include the most relevant covariate from a clinical point of view, namely number of prior CD in the models predicting PAS-3. Moreover, to reduce the potential overfitting due to the limited number of women experiencing an adverse surgical outcome ($n=22$), the number of covariates for this outcome was limited to three in every phase of model fitting²⁸. The goodness-of-fit was then checked using Hosmer-Lemeshow test, and the predictive power assessed through C-statistics (area under the Receiving Operator Curve - AUC). For each outcome, any improvement in model performance was assessed from change in the AUC. Standard post-estimation tests were used to check the validity of all final models, performing multicollinearity and influential observation analyses (using standardized residuals, change in Pearson and deviance chi-square).

Additionally, we estimated the potential of: (a) COS-1, (b) “in the niche” and (c) “below the line” implantation to predict both outcomes computing summary estimates of sensitivity, specificity, positive and negative predictive values (PPV and NPV), positive and negative likelihood ratios (LR+ and LR-), and diagnostic odds ratios (DOR). 95% Confidence Intervals (CI) for specificity and sensitivity and for PPV and NPV were computed according to the efficient-score method (corrected for continuity) described by Newcombe²⁹.

Accepted Article

Finally, we tested the differences in adverse surgical outcome, estimated blood loss (EBL), transfusion of packed red blood cells (PRBC), blood products (BP), platelets, fresh frozen plasma (FFP) between women presenting with COS1 or “in the niche” implantation in the first and PAS3 in the third trimester compared to those showing COS2 or “in the scar” in the first and PAS3 in the third trimester of pregnancy. Statistical significance was defined as a two-sided p-value <0.05 for all analyses, which were carried out using Stata, version 13.1 (Stata Corp., College Station, Texas, USA, 2013).

RESULTS

One hundred and eighty-seven women with placenta previa and at least one prior CD or uterine surgery from which early (5-7 postmenstrual weeks of gestation) could be retrieved were included in the analysis. General characteristics of the study population are reported in Table 1. Mean maternal age was 32.8 ± 5.1 years, while the gestational age at birth was 35.3 ± 1.7 weeks. Hysterectomy was performed in all women affected by PAS1-3 compared to none of those presenting with PAS0; likewise, none of the included cases was treated leaving the placenta in situ or partially resective surgical techniques (Table 1).

According to early first trimester US, 41.7% (95% CI 34.9-48.978/187) of cases were labelled as COS0, 29.4% (95% CI 23.4-36.3; 55/187) as COS1 and 28.9% (95% CI 22.9-35.8; 54/187) as COS-2. 19.3% (95% CI 14.2-25.5; 36/187) of cases showed implantation of the gestational sac “on the scar”, while 39.0% (95% CI 32.3-46.2; 73/187) were “in the niche” implantations. (Table 1). Finally, 40.1% (95% CI 33.4-47.3; 75/187) of cases showed implantation of the sac “below”, while 58.9% (95% CI 52.7-66.7; 112/187) “above” the line. When assessing the sonographic staging of PAS, 41.7% (95% CI 34.9-48.9; 78/187) of women were labelled as PAS0, 20.9% (95% CI 15.7-27.2; 39/187) as PAS1, 8.6% (5.6-13.5; 16/187) as PAS2 and finally, 28.9% (95% CI 22.9-35.8; 54/187) as PAS3 (Table 1).

Table 2 showed the distribution of the different types of COS implantation according to the third trimester sonographic staging of PAS. All women with COS0 on early first trimester ultrasound were labelled as PAS0 in the third trimester. Conversely, only 7.7% (95% CI 2.7-20.3; 3/39) of cases labelled as COS-1 in the first trimester were found to be PAS3 in the third trimester of pregnancy compared to 92.3% (95% CI 79.7-97.4; 36/39) of COS2 ($p < 0.01$). More importantly, 79.6% (95% CI 67.1-88.2; 43/54) of cases showing COS1 implantation were found to be PAS3 on third trimester US, compared to 20.4% (95% CI 11.8-32.9; 11/54) of cases showing COS2 ($p < 0.001$).

When assessing the distribution of the “in the niche/on the scar” implantation, 23.1% (95% CI 12.7-38.3; 9/39) of women showing implantation of the gestational sac “in the niche” of the prior CD were PAS1 on third trimester US compared to 76.9% (95% CI 61.7-87.4; 30/39) of those showing implantation “on the scar”. Conversely, 94.4% (95% CI 84.9-98.1; 51/54) of women having

implantation of the gestational sac “in the niche” were PAS3 compared to only 5.6% (95% CI 1.9-15.1; 3/54) of those implanted “on the scar” ($p<0.01$). Finally, all cases with PAS3 had implantation of the center of the gestational sac “below the line”, compared to only 18.0% (95% CI 9.0-32.7; 7/39) and 87.5% (95% CI 64.0-96.5; 14/16) with PAS2 and PAS3 respectively (Table 2).

On multivariate logistic regression analysis, after adjusting for all potential confounders, COS1 implantation, but not parity ($p=0.4$) or the number of prior CS ($p=0.5$) was independently associated with PAS3 with an OR of 7.9 (95% CI 4.0-15.5; $p<0.001$). Likewise, implantation “in the niche” (OR: 29.1 (95% CI 8.1-104; $p<0.001$) and “below the line” (OR: 38.1, 95% CI 12.1-121; $p<0.001$) were also associated with PAS3 (Table 3). When translating these figures in a diagnostic model, either COS1 (AUC: 0.94, 95% CI 0.91-0.97), implantation “in the niche” (AUC: 0.92, 95% CI 0.89-0.96) and “below the line” (AUC: 0.92, 95% CI 0.88-0.96) had a high predictive accuracy for PAS3. The three models showed a similar predictive accuracy in terms of sensitivity and specificity (Figure 2, Table 6).

Adverse surgical outcome complicated 11.8% (95% CI 7.9-17.2; 22/187) pregnancies. Mean maternal age was higher (35.7 ± 3.5 vs 32.4 ± 5.1 years; $p=0.004$) while gestational age at surgery lower (34.1 ± 1.9 vs 35.5 ± 1.6 weeks; $p<0.001$) in women experiencing compared to those not experiencing adverse surgical outcome. Likewise, the incidence of placenta percreta (95.4% vs 29.7%; $p<0.001$) and PAS3 stage on US (81.8% vs 21.8%; $p<0.001$) were higher in pregnancies complicated by adverse surgical outcome.

When exploring the distribution of the different first trimester US signs of abnormal gestational sac implantation, COS1 implantation was more common in women experiencing compared to those not experiencing adverse surgical outcome (86.4% vs 21.8%; $p<0.001$), while there was no difference in the distribution of either COS0 and COS2 implantation between the two groups (Table 4). Likewise, women experiencing adverse surgical outcome had a higher incidence implantation of gestational sac “in the niche” compared to that “on the scar” of the prior CD (94.4% vs 4.6%; $p<0.001$) and “below” compared to “above” the line (90.9% vs 9.1%, $p<0.001$) (Table 4).

On multivariate logistic regression analysis, after adjusting for all potential confounders, PAS3 on US (OR: 4.3, 95% CI 2.1-17.3), COS1 (OR: 7.9, 95% CI 4.0-15.5; $p<0.001$), implantation “in the

niche” of the prior CS (OR: 29.1, 95% CI 8.1-104; $p<0.001$) and “below the line” (OR: 6.6 (95% CI 3.9-16.2; $p<0.001$) were independently associated with adverse surgical outcome (Table 5). When translating these figures in a diagnostic model, either COS1 (AUC: 0.88, 95% CI 0.81-0.95), implantation “in the niche” (AUC: 0.871, 95% CI 0.81-0.93) and “below the line” (AUC: 0.87, 95% CI 0.82-0.93) had a similar high diagnostic accuracy for adverse surgical outcome (Figure 3, Table 7).

Finally, we tested the differences in adverse surgical outcome, EBL, transfusion of PRBC, BP, platelets and FFP between women presenting with COS1 or “in the niche” implantation in the first and PAS3 in the third trimester compared to those showing COS2 or “in the scar” in the first and PAS3 in the third trimester of pregnancy. The occurrence of adverse surgical outcome was higher in women with COS1-PAS3 compared to COS2-PAS3; likewise, mean EBL ($p=0.0048$), BP ($p=0.044$) and PRBC transfused ($p=0.019$) were higher in women with COS1-PAS3 compared to those with COS2-PAS3; while it was not possible to perform the comparison between women with “in the niche”-PAS3 vs “on the scar” PAS3 because only three women had “in the niche”-PAS3 implantation. (Table 8).

DISCUSSION

Main findings

The findings from this study show that retrospective early sonographic assessment at (5-7 postmenstrual weeks) can predict PAS stage in women at high risk for these anomalies. COS1 and implantation of the gestational sac “in the niche” of the prior CS scar and “below the line” were associated and predictive of severe stages of PAS in the third trimester of pregnancy. Conversely, COS2, implantation “on the scar” and “above the line” were associated with less severe types of PAS. COS1, implantation “in the niche” and “below the line” were independently associated with adverse surgical outcome in women with PAS. Finally, retrospective first trimester US showed an overall good predictive accuracy for adverse surgical outcome.

Strengths and limitations

This is the first study exploring the role of first trimester US in predicting PAS stage.

Large sample size, longitudinal and blinded assessment of the included cases from the first trimester of pregnancy until birth represent the major strengths of the study. Furthermore, we explored the role of both the previously published types of first trimester assessment (COS and “in the niche/on the scar” implantation) in predicting PAS stage and surgical outcome. Finally, all cases affected by PAS were managed by the same multidisciplinary team and treated with hysterectomy, thus reducing the risk of bias related to operator’s experience and type of surgical approach adopted.

The main limitation of the study is by the fact that we did not explore whether the application of first trimester assessment could affect prenatal management and the prognosis of these pregnancies, since the study is a secondary retrospective analysis.

Comparison with previous studies

Previous studies have tried to correlate implantation of the gestational sac on first trimester ultrasound and risk of PAS disorders³⁰⁻³⁴. Vial et al.³⁰ proposed two types of implantation types of in women affected by CSP: the first, implantation “on the scar” and the second “deep in the cesarean scar defect”. Likewise, Comstock et al³¹, in a small series of women with previous CS and confirmed PAS, reported that anterior low implantation of the gestational sac was the most common finding at

first trimester US and the same findings were reported in the study by Ballas et al.³² although the included cases were scanned at later gestational ages (8.5-14 weeks).

Naji et al.³³ assessed the relationship between the location of the gestational sac and the internal cervical os at 12 weeks of gestation and found that cases where the sac crossed the scar the pregnancy resulted in placenta previa and postpartum hemorrhage. Finally, Rac et al.³⁴ reported that a smallest myometrial thickness on 1st trimester US significantly improved detection rate of PAS.

Implications for clinical practice and research

One of the major challenges when counseling women with a diagnosis of PAS on US is the lack of objective prenatal predictors of surgical outcome.

Histopathological assessment of the depth of placental invasion is retrospective and it cannot be used prospectively at the time of prenatal diagnosis³⁵⁻³⁸. Furthermore, different degrees of placental invasion can co-exist in the same uterus²⁶. Finally, there might be high variability in the surgical outcome even in women presenting with the same depth of placenta invasion^{16,25,36}. Topography of placental invasion has been recently reported to be a reliable predictor of surgical outcome in women with PAS irrespective of the depth of placental invasion with Invasions in the inferior third of lower uterine segment, posterior bladder and parametria carrying a higher risk of surgical morbidity^{37,38}. However, despite its clinical relevance, assessment of the topography of placental invasion has not yet been consistently reported on ultrasound.

In view of the recently reported association between CSP and PAS, we have recently suggested that women with a prior CS or uterine surgery should undergo early sonographic assessment in order to detect CSP²¹. It is collective author's opinion that an accurate clinical and sonographic evaluation of a pregnancy after a previous CS can facilitate not only timely counseling, but also, if needed, gestational age-appropriate, individualized pregnancy management²¹. However, the effect of such screening program on costs for national health services should be balanced against its efficacy in improving the outcome of these women and may pose ethical dilemmas especially when CSP is detected in asymptomatic women.

The findings from this study showed that first trimester US can help in the risk stratification of women affected by PAS and it is able to identify a large proportion of women who will be affected by the

most severe types of these anomalies. Based upon the findings from the present study, we proposed a new imaging assessment of the relationship between the gestational sac and the prior CS scar aiming at stratifying the risk for PAS in these women. When combining the three imaging methods and placing the defining coordinates of the COS and the “above and below the uterine midline” as well as the “on the scar” and “in the niche” on a sagittal US image of the uterus, we identified, an area we call “high-risk-for-PAS Triangle” (Figure 4). If the centre of the gestational sac is “in the niche” the pregnancy is high risk for PAS. This diagram may enable an easy visual perception and application of the three methods to prognosticate the risk for CSP and PAS, although it requires validation in further large prospective studies. Ideally, such studies would require different ultrasound examinations during the early first trimester in order to confirm a viable CPS, in view of the higher risk of embryonic demise in early pregnancy, and a comprehensive assessment of the inter-and intra-observer variability of this sign in order to test its applicability in clinical practice.

Conclusions

This study demonstrates that early sonographic assessment (at 5-7 postmenstrual weeks of pregnancies after previous CDs and uterine surgeries) can predict PAS stage and surgical outcome. The findings of this study highlight the need for large prospective studies aimed at exploring whether first trimester screening for PAS can improve the prenatal diagnostic accuracy and surgical outcome.

References

1. Jauniaux E, Collins S, Burton GJ. Placenta accreta spectrum: pathophysiology and evidence-based anatomy for prenatal ultrasound imaging. *Am J Obstet Gynecol* 2018; **218**:75-87.
2. Jauniaux E, Chantraine F, Silver RM, Langhoff-Roos J; FIGO Placenta Accreta Diagnosis and Management Expert Consensus Panel. FIGO consensus guidelines on placenta accreta spectrum disorders: Epidemiology. *Int J Gynaecol Obstet* 2018; **140**: 265-273.
3. Belfort MA. Placenta accreta. *Am J Obstet Gynecol* 2010; **203**:430-439.
4. Timor-Tritsch IE, Monteagudo A. Unforeseen consequences of the increasing rate of cesarean deliveries: early placenta accreta and cesarean scar pregnancy. A review. *Am J Obstet Gynecol* 2012; **207**:14-29.
5. Iacovelli A, Liberati M, Khalil A, Timor-Trisch I, Leombroni M, Buca D, Milani M, Flacco ME, Manzoli L, Fanfani F, Calì G, Familiari A, Scambia G, D'Antonio F. Risk factors for abnormally invasive placenta: a systematic review and meta-analysis. *J Matern Fetal Neonatal Med* 2018; **22**:1-11.
6. Timor-Tritsch IE, Monteagudo A, Cali G, Palacios-Jaraquemada JM, Maymon R, Arslan AA, Patil N, Popiolek D, Mittal KR. Cesarean scar pregnancy and early placenta accreta share common histology. *Ultrasound Obstet Gynecol* 2014; **43**: 383-395.
7. Timor-Tritsch IE, Monteagudo A, Cali G, Vintzileos A, Viscarello R, Al-Khan A, Zamudio S, Mayberry P, Cordoba MM, Dar P. Cesarean scar pregnancy is a precursor of morbidly adherent placenta. *Ultrasound Obstet Gynecol* 2014; **44**: 346-53.
8. Calì G, Timor-Tritsch IE, Palacios-Jaraquemada J, Monteagudo A, Buca D, Forlani F, Familiari A, Scambia G, Acharya G, D'Antonio F. Outcome of Cesarean scar pregnancy managed expectantly: systematic review and meta-analysis. *Ultrasound Obstet Gynecol* 2018; **51**:169-175.
9. Zosmer N, Fuller J, Shaikh H, Johns J, Ross JA. Natural history of early first-trimester pregnancies implanted in Cesarean scars. *Ultrasound Obstet Gynecol* 2015; **46**: 367-375.
10. D'Antonio F, Iacovella C, Bhide A. Prenatal identification of invasive placentation using ultrasound: systematic review and meta-analysis. *Ultrasound Obstet Gynecol* 2013; **42**:509-517.

- Accepted Article
11. D'Antonio F, Iacovella C, Palacios-Jaraquemada J, Bruno CH, Manzoli L, Bhide A. Prenatal identification of invasive placentation using magnetic resonance imaging: systematic review and meta-analysis. *Ultrasound Obstet Gynecol* 2014; **44**:8-16.
 12. D'Antonio F, Timor-Tritsch IE, Palacios-Jaraquemada J, Monteagudo A, Buca D, Forlani F, Minneci G, Foti F, Manzoli L, Liberati M, Acharya G, Cali G. First-trimester detection of abnormally invasive placenta in high-risk women: systematic review and meta-analysis. *Ultrasound Obstet Gynecol* 2018; **51**:176-183.
 13. Pagani G, Cali G, Acharya G, Trisch IT, Palacios-Jaraquemada J, Familiari A, Buca D, Manzoli L, Flacco ME, Fanfani F, Liberati M, Scambia G, D'antonio F. Diagnostic accuracy of ultrasound in detecting the severity of abnormally invasive placentation: a systematic review and meta-analysis. *Acta Obstet Gynecol Scand* 2018; **97**: 25-37.
 14. Familiari A, Liberati M, Lim P, Pagani G, Cali G, Buca D, Manzoli L, Flacco ME, Scambia G, D'antonio F. Diagnostic accuracy of magnetic resonance imaging in detecting the severity of abnormal invasive placenta: a systematic review and meta-analysis. *Acta Obstet Gynecol Scand* 2018; **97**:507-520.
 15. Buca D, Liberati M, Cali G, Forlani F, Caisutti C, Flacco ME, Manzoli L, Familiari A, Scambia G, D'Antonio F. Influence of prenatal diagnosis of abnormally invasive placenta on maternal outcome: systematic review and meta-analysis. *Ultrasound Obstet Gynecol* 2018; **52**: 304-309.
 16. Cali G, Forlani F, Lees C, Timor-Tritsch I, Palacios-Jaraquemada J, Dall'Asta A, Bhide A, Flacco ME, Manzoli L, Labate F, Perino A, Scambia G, D'Antonio F. Prenatal ultrasound staging system for placenta accreta spectrum disorders. *Ultrasound Obstet Gynecol* 2019; **53**: 752-760.
 17. Cali G, Forlani F, Timor-Tritsch IE, Palacios-Jaraquemada J, Minneci G, D'Antonio F. Natural history of Cesarean scar pregnancy on prenatal ultrasound: the crossover sign. *Ultrasound Obstet Gynecol* 2017; **50**: 100-104.
 18. Cali G, Forlani F, Minneci G, Foti F, Di Liberto S, Familiari A, Scambia G, D'Antonio F. First-trimester prediction of surgical outcome in abnormally invasive placenta using the cross-over sign. *Ultrasound Obstet Gynecol* 2018; **51**: 184-188.

- Accepted Article
19. Kaelin Agten A, Cali G, Monteagudo A, Oviedo J, Ramos J, Timor-Tritsch I. The clinical outcome of cesarean scar pregnancies implanted "on the scar" versus "in the niche". *Am J Obstet Gynecol* 2017; **216**: 510.e1-510.e6.
 20. Timor-Tritsch IE, Monteagudo A, Cali G, El Refaey H, Kaelin Agten A, Arslan AA. Easy sonographic differential diagnosis between intrauterine pregnancy and cesarean delivery scar pregnancy in the early first trimester. *Am J Obstet Gynecol* 2016; **215**: 225.e1-225.e7.
 21. Timor-Tritsch IE, D'Antonio F, Calí G, Palacios-Jaraquemada J, Meyer J, Monteagudo A. Early first-trimester transvaginal ultrasound is indicated in pregnancy after previous Cesarean delivery: should it be mandatory? *Ultrasound Obstet Gynecol* 2019; **54**:156-163.
 22. Cali G, Forlani F, Timor-Tritsch I, Palacios-Jaraquemada J, Foti F, Minneci G, Flacco ME, Manzoli L, Familiari A, Pagani G, Scambia G, D'Antonio F. Diagnostic accuracy on ultrasound in detecting the depth of invasion in women at risk of abnormally invasive placenta: A prospective longitudinal study. *Acta Obstet Gynecol Scand* 2018; **97**: 1219-1227.
 23. von Elm E, Altman DG, Egger M, Pocock SJ, Gøtzsche PC, Vandenbroucke JP; STROBE Initiative. The Strengthening the Reporting of Observational Studies in Epidemiology (STROBE) statement: guidelines for reporting observational studies. *J Clin Epidemiol* 2008; **61**: 344-349.
 24. Collins SL, Ashcroft A, Braun T, Calda P, Langhoff-Roos J, Morel O, Stefanovic V, Tutschek B, Chantraine F; European Working Group on Abnormally Invasive Placenta (EW-AIP). Proposal for standardized ultrasound descriptors of abnormally invasive placenta (AIP). *Ultrasound Obstet Gynecol* 2016; **47**: 271-275.
 25. D'Antonio F, Iacovelli A, Liberati M, Leombroni M, Murgano D, Cali G, Khalil A, Flacco ME, Scutiero G, Iannone P, Scambia G, Manzoli L, Greco P. Role of interventional radiology in pregnancy complicated by placenta accreta spectrum disorder: systematic review and meta-analysis. *Ultrasound Obstet Gynecol* 2019; **53**: 743-751.
 26. D'Antonio F, Palacios-Jaraquemada J, Lim PS, Forlani F, Lanzone A, Timor-Tritsch I, Cali G. Counseling in fetal medicine: evidence-based answers to clinical questions on morbidly adherent placenta. *Ultrasound Obstet Gynecol* 2016; **47**: 290-301.
 27. Palacios-Jaraquemada JM. Caesarean section in cases of placenta praevia and accreta. *Best Pract Res Clin Obstet Gynaecol* 2013; **27**: 221-232.

28. Pizzi C, Costa GM, Santarella L, Flacco ME, Capasso L, Bert F, Manzoli L. Depression symptoms and the progression of carotid intima-media thickness: a 5-year follow-up study. *Atherosclerosis* 2014; **233**:530-536.
29. Newcombe RG. Two-sided confidence intervals for the single proportion: comparison of seven methods. *Stat Med* 1998; **17**: 857-872.
30. Vial Y, Petignat P, Hohlfield P. Pregnancy in a cesarean scar. *Ultrasound Obstet Gynecol* 2000; **16**: 592-593
31. Comstock CH, Lee W, Vettraino IM, Bronsteen RA. The early sonographic appearance of placenta accreta. *J Ultrasound Med* 2003; **22**: 19-23
32. Ballas J, Pretorius D, Hull AD, Resnik R, Ramos GA. Identifying sonographic markers for placenta accreta in the first trimester. *J Ultrasound Med* 2012; **31**: 1835 -1841
33. Naji O, Wynants L, Smith A, Abdallah Y, Saso S, Stalder C, Van Huffel S, Ghaem-Maghani S, Van Calster B, Timmerman D, Bourne T. Does the presence of a Caesarean section scar affect implantation site and early pregnancy outcome in women attending an early pregnancy assessment unit? *Hum Reprod* 2013; **28**: 1489-1496.
34. Rac MW, Moschos E, Wells CE, McIntire DD, Dashe JS, Twickler DM. Sonographic Findings of Morbidly Adherent Placenta in the First Trimester. *J Ultrasound Med* 2016; **35**: 263-269.
35. Marcellin L, Delorme P, Bonnet MP, Grange G, Kayem G, Tsatsaris V, Goffinet F. Placenta percreta is associated with more frequent severe maternal morbidity than placenta accreta. *Am J Obstet Gynecol* 2018; **219**: 193.e1-193.e9.
36. Dannheim K, Shainker SA, Hecht JL. Hysterectomy for placenta accreta; methods for gross and microscopic pathology examination. *Arch Gynecol Obstet* 2016; **293**:951-958.
37. Lim BH, Palacios-Jaraquemada JM. The morbidly adherent placenta--a continuing diagnostic and management challenge. *BJOG* 2015; **122**: 1673.
38. Palacios-Jaraquemada JM, Bruno CH, Martín E. MRI in the diagnosis and surgical management of abnormal placentation. *Acta Obstet Gynecol Scand* 2013; **92**: 392-397.

Figure legend

Figure 1 (A, B,C): Evaluation of the site of implantation of pregnancies after a previous caesarean delivery based upon the three suggested methods as well as the combination of all three in a combined fashion.

A: Diagrammatic representation showing the relationships between the gestational sac, previous CS and anterior uterine wall (COS insertion). In a sagittal view of the uterus, a straight longitudinal line is drawn connecting the internal cervical os and the uterine fundus through the endometrium (endometrial line) (yellow line). Then the gestational sac is identified and its S-I diameter perpendicular to the endometrial line traced. According to the relationship between the endometrial line and the S-I diameter of the ectopic sac, patients can be divided into two different groups: normal pregnancy (a), the gestational sac implant away from the CS, in close proximity to the uterine fundus; COS1 insertion (b), gestational sac is implanted within the previous CS and \geq two thirds of the S-I diameter of the gestational sac was above the endometrial line towards the anterior uterine wall; COS2+ insertion (c), gestational sac is implanted within the previous CS and $<$ two thirds of the S-I diameter of the gestational sac is above the endometrial line; COS2- insertion (d), gestational sac is implanted in close proximity of within the previous CS, $<$ two thirds of the S-I diameter of the gestational sac is above the endometrial line but there is no intersection between the S-I diameter of the ectopic sac and the endometrial line. b: Ultrasound images showing the different types of COS insertion (A. Ut. W: anterior uterine wall; B: bladder; C: cervix, CS: caesarean scar; E: endometrium; EL: endometrial line; GS: gestational sac; S-I d: superior-inferior diameter; Ut. F: uterine fundus).

B: The definition of “on the scar” was that the placenta implanted partially or fully on top of a well healed scar (1A), while that for “in the niche” was that the placenta implanted into a deficient or dehiscent scar (1B). The method of classifying the pregnancy as “in the niche” and “on the scar” was also defined numerically as follows: Gestation “on the scar”, when the myometrial thickness between the sac and the bladder was ≥ 3 mm. Gestation “in the niche”, when the myometrium measured ≤ 2 mm

C: Differentiating normal, intrauterine pregnancy implantation from a low, anterior implantation of a caesarean scar pregnancy by their sagittal, longitudinal ultrasound picture using “above” vs “below” the line classification. By drawing a perpendicular line to divide uterus in half, location of the centre of the gestational sac (X) determines the diagnosis. If the centre of the sac is ABOVE the half line, closer to the fundus: it is a normal intrauterine gestation (A). If the centre of the sac is BELOW the half line, closer to the cervix: it's a CSP (or in rarest of cases, a cervical pregnancy. Clinical correlation should always be used! (Cx: cervix; F: fundus of the uterus).

Figure 2: Receiver operating characteristics curve showing the diagnostic performance different types of sonographic first trimester implantation of the gestational sac in predicting PAS3 on ultrasound.

Figure 3: Receiver operating characteristics curve showing the diagnostic performance different types of sonographic first trimester implantation of the gestational sac in predicting adverse surgical outcome.

Figure 4: When combining the three different imaging signs of early first trimester assessment of gestational sac implantation and placing the defining coordinates of the COS and the “above and below the uterine midline” as well as the “on the scar” and “in the niche” on a sagittal US image of the uterus, we identified, an area we call “high-risk-for-PAS Triangle”. If the centre of the gestational sac is “in the niche” the pregnancy is high risk for PAS. This diagram enables an easy visual perception and application of the three methods to prognosticate the risk for pregnancy outcome.

Table 1. General characteristics of the study population.

<i>Variables</i>	
<i>A. Maternal and gestational characteristics:</i>	
Mean maternal age in years (SD)	32.8 (5.1)
Mean gestational age at delivery in weeks (SD)	35.3 (1.7)
Number of previous caesarean deliveries, %, (n)	
- 1 prior CS	29.4 (55)
- 2 prior CS	44.9 (84)
- ≥ 3 prior CS	25.7 (48)
Histopathological diagnosis, % (n)	
- Placenta previa without PAS	41.7 (78)
- Placenta accreta	12.3 (23)
- Placenta increta	8.6 (16)
- Placenta percreta	37.4 (70)
<i>B: Placenta accreta spectrum disorders stage (US), % (n)</i>	
- PAS0	41.7 (78)
- PAS1	20.9 (39)
- PAS2	8.6 (16)
- PAS3	28.9 (54)
<i>C. First trimester ultrasound signs:</i>	
Cross-over sign type, % (n)	
- COS0	41.7 (78)
- COS2	28.9 (54)
- COS1	29.4 (55)
“In the niche” vs “on the scar” implantation, %, (n)	
- Normal	41.7 (78)
- “On the scar”	19.3 (36)
- “In the niche”	39.0 (73)
“Above the line” vs “below the line” implantation	
- “Above the line”	59.9 (112)
- “Below the line”	40.1 (75)
<i>D. Pregnancy outcome:</i>	

Composite adverse surgical outcome [†] , % (n)	11.8 (22)
Blood loss> 1500 ml, % (n)	6.4 (12)
Transfusion of units of blood products, % (n)	7.5 (14)
Admission to ICU, % (n)	8.6 (16)
Surgical complication, % (n)	0 (0)
Estimated blood loss in ml (SD)	788 (428)
Total units of BP transfused	1.2 (3.5)
Units of PRBC transfused (SD)	0.51 (1.2)
Units of FFP transfused (SD)	0.43 (1.4)
Units of platelets transfused (SD)	0.26 (1.1)
Operative time (SD)	122.01 (61.9)
Length of stay in days (SD)	5.23 (2.1)

SD = Standard deviation; CD = Caesarean delivery; COS = Cross-over sign; [†] Combination of: (1) estimated blood loss >1500 mL; (2) transfusion of >5 Units of blood products; (3) presence of surgical complication; (4) admission to Intensive Care Unit.

Table 2. Distribution of different types of implantation assessed at first trimester ultrasound according to different ultrasound stages of PAS.

	PAS0 (n= 78)	PAS1 (n= 39)	PAS2 (n= 16)	PAS3 (n= 54)	p-value*
COS0	100 (78/78)	0 (0/39)	0 (0/16)	0 (0/54)	a, b, c
COS1	0 (0/78)	7.7 (3/39)	56.3 (9/16)	79.6 (43/54)	b, c, d, e
COS2	0 (0/78)	92.3 (36/39)	43.8 (7/16)	20.4 (11/54)	a, b, c, d, e
Normal implantation	100 (78/78)	0 (0/39)	0 (0/16)	0 (0/54)	a, b, c
In the niche	0 (0/78)	23.1 (9/39)	81.3 (13/16)	94.4 (51/54)	a, b, c, d, e
On the scar	0 (0/78)	76.9 (30/39)	18.8 (3/16)	5. 6 (3/54)	a, b, d, e
Above the line	(78/78)	82.1 (32/39)	12.5 (2/16)	0 (0/54)	a, b, c, d, e
Below the line	0 (0/78)	17.95 (7/39)	87.5 (14/16)	100 (54/54)	a, b, c, d, e,

* Chi-squared test. a = $p < 0.05$ for the comparison between women with a diagnosis of PAS0 and women with a diagnosis of PAS1; b = $p < 0.05$ for the comparison between women with a diagnosis of PAS0 and women with a diagnosis of PAS2; c = $p < 0.05$ for the comparison between women with a diagnosis of PAS0 and women with a diagnosis of PAS3; d: $p < 0.05$ for the comparison between women with a diagnosis of PAS1 and women with a diagnosis of PAS2.; e: $p < 0.05$ for the comparison between women with a diagnosis of PAS1 and women with a diagnosis of PAS3. f: $p < 0.05$ for the comparison between women with a diagnosis of PAS2 and women with a diagnosis of PAS3.

All p-values that are not indicated were > 0.05 .

Table 3. Logistic regression models evaluating the potential independent predictors of a third-trimester diagnosis of PAS-3, and comparison of the Receiver Operating Characteristic (ROC) curves of each model

<i>Covariates</i>	Adjusted OR (95% CI)	P value
Age, 1-year increase	1.06 (0.93-1.19)	0.4
Gestational age at birth, 1-week increase	0.91 (0.65-1.26)	0.6
Parity, 1-category increase		
- 1 previous birth (ref. cat.)	0	--
- 2 previous births	1.52 (0.47-4.99)	0.5
- ≥ 3 previous births	2.06 (0.47-9.06)	0.3
<i>Model 1:</i> [†]		
COS, 1-category increase	7.91 (4.03-15.5)	<0.001
<i>Model 2:</i> [‡]		
Implantation, "in the niche" vs "on the scar"/normal	29.1 (8.1-104)	<0.001
<i>Model 3:</i> [§]		
Implantation site, below vs above the endometrial line	38.1 (12.0-121)	<0.001

[†] Adjusted for: maternal age, gestational age at delivery, parity, plus COS category.

[‡] Adjusted for: maternal age, gestational age at delivery, parity, plus type of implantation.

[§] Adjusted for: maternal age, gestational age at delivery, parity, plus site of implantation.

Due to a high degree of collinearity across number of previous caesarean sections and parity (spearman's rho=0.95), only the latter covariate was reported in the final models.

Table 4. Comparison of maternal and gestational characteristics and first-trimester ultrasound signs in women with versus women without a third-trimester diagnosis or composite adverse surgical outcome[†].

<i>Variables</i>	Composite adverse outcome (n=22)	No composite adverse outcome (n=165)	p *
A. Maternal and gestational characteristics:			
Mean maternal age in years (SD)	35.68 (3.4)	32.38 (5.1)	0.004
Mean gestational age at birth in weeks (SD)	34.07 (1.9)	35.51 (1.6)	<0.001
Number of previous caesarean deliveries, % (n)			
- 1 prior CS	18.2 (4)	30.90 (51)	0.319
- 2 prior CS	40.9 (9)	45.45 (75)	0.821
- ≥ 3 prior CS	40.9 (9)	23.64 (39)	0.116
Histopathological diagnosis, %			
- Placenta previa without PAS	0 (0)	47.27 (78)	<0.001
- Placenta accreta	0 (0)	13.94 (23)	0.081
- Placenta increta	0 (0)	9.70 (16)	0.224
- Placenta percreta	100 (22)	29.09 (48)	<0.001
B. Ultrasound stage of PAS, % (n)			
- PAS0	0 (0)	47.27 (78)	<0.001
- PAS1	0 (0)	23.64 (39)	0.009
- PAS2	13.64 (3)	7.88 (13)	0.409
- PAS3	86.36 (19)	21.21 (35)	<0.001
C. First trimester ultrasound signs:			
“Cross-over sign” type, % (n)			
- COS0	0 (0)	47.27 (78)	<0.001
- COS2	9.09 (2)	31.52 (52)	0.042
- COS1	90.91 (20)	21.21 (35)	<0.001
“In the niche/on the scar”, % (n)			
- Normal	0 (0)	47.27 (78)	<0.001
- “On the scar”	4.55 (1)	21.21 (35)	0.083
- “In the niche”	95.45 (21)	31.51 (52)	<0.001
“Above the line/below the line”, % (n)			
- “Above the line”	9.09 (2)	66.67 (110)	<0.001
- “Below the line”	90.91 (20)	33.33 (55)	<0.001

† Combination of: (1) estimated blood loss >1500 mL; (2) transfusion of >5 Units of blood products; (3) presence of surgical complication; (4) admission to Intensive Care Unit.

* Chi-squared test and Kruskal-Wallis test for categorical and continuous variables, respectively. All p-values that are not indicated were >0.05.

PAS = Placenta accreta spectrum; SD = Standard deviation; CS = Cesarean section; COS = Cross-over sign.

Table 5. Logistic regression models evaluating the potential independent predictors of a third-trimester diagnosis of PAS-3, and comparison of the Receiver Operating Characteristic (ROC) curves of each model

<i>Covariates</i>	Adjusted OR (95% CI)	P value
Age, 1-year increase	1.06 (0.93-1.19)	0.4
Gestational age at birth, 1-week increase	0.91 (0.65-1.26)	0.6
Parity, 1-category increase		
- 1 previous birth (ref. cat.)	0	--
- 2 previous births	1.52 (0.47-4.99)	0.5
- ≥3 previous births	2.06 (0.47-9.06)	0.3
Ultrasound staging of PAS PAS3	4.27 (2.1-17.3)	<0.001
<i>Model 1:</i> †		
COS,1 vs COS 2	7.91 (4.03-15.5)	<0.001
<i>Model 2:</i> ‡		
"In the niche" vs "on the scar"/normal	29.1 (8.1-79)	<0.001
<i>Model 3:</i> §		
implantation site, "below" vs "above the line"	6.57 (3.9-16.2)	<0.001

† Adjusted for: maternal age, gestational age at delivery, parity, plus COS category.

‡ Adjusted for: maternal age, gestational age at delivery, parity, plus type of implantation.

§ Adjusted for: maternal age, gestational age at delivery, parity, plus site of implantation.

Due to a high degree of collinearity across number of previous caesarean sections and parity (spearman's rho=0.95), only the latter covariate was reported in the final models.

Because PAS3, COS1, implantation "in the niche" and "above the line" represent the main clinical entity, they were entered sequentially in the logistic regression model

Table 6. Diagnostic accuracy of first-trimester ultrasound: (a) different types of cross-over sign (COS); (b) cesarean scar pregnancy variants to predict a diagnosis of placenta accreta spectrum (PAS)-3 disorder: summary estimates of sensitivity, specificity, positive and negative predictive values (PPV and NPV), positive and negative likelihood ratios (LR+ and LR-) and diagnostic odds ratios (DOR). CI = Confidence interval.

<i>First trimester ultrasound signs</i>	Sensitivity % (95% CI)	Specificity % (95% CI)	PPV % (95% CI)	NPV % (95% CI)	LR+ (95% CI)	LR- (95% CI)	DOR (95% CI)
COS-1	79.6 (66.5-89.4)	91.0 (84.8-95.3)	78.2 (65.0-88.2)	91.7 (85.6-95.8)	8.83 (5.06-15.4)	0.22 (0.13-0.38)	39.4 (16.3-95.2)
"In the niche"	94.4 (84.6-88.8)	83.5 (76.0-89.3)	69.9 (58.0-80.1)	97.4 (92.5-99.5)	5.71 (3.88-8.41)	0.07 (0.02-0.20)	85.8 (25.8-281.2)
"Below the line"	100 (93.4-100)	84.21 (76.9-90.0)	72.0 (60.4-81.8)	100 (96.8-100)	6.33 (4.3-9.4)	* (0-0.08)	∞ (66.1- ∞)

Table 7. Diagnostic accuracy of first-trimester ultrasound: (a) different types of cross-over sign (COS); (b) cesarean scar pregnancy variants to predict composite adverse surgical outcome [†]: summary estimates of sensitivity, specificity, positive and negative predictive values (PPV and NPV), positive and negative likelihood ratios (LR+ and LR-) and diagnostic odds ratios (DOR). CI = Confidence interval.

<i>First trimester ultrasound signs</i>	Sensitivity % (95% CI)	Specificity % (95% CI)	PPV % (95% CI)	NPV % (95% CI)	LR+ (95% CI)	LR- (95% CI)	DOR (95% CI)
COS-1	86.4 (65.1-97.1)	78.2 (71.1-84.2)	34.5 (22.2-48.6)	97.7 (93.5-99.5)	3.96 (2.84-5.52)	0.17 (0.06-0.50)	22.7 (6.73-75.6)
"In the niche"	90.9 (70.8-98.9)	67.9 (60.2-74.9)	27.4 (17.6-39.1)	98.2 (93.8-99.8)	2.83 (2.19-3.66)	0.13 (0.04-0.50)	21.1 (5.26-∞)
"Above the line"	90.9 (70.8-98.9)	66.67 (58.9-73.8)	26.67 (17.1-38.1)	98.21 (93.7-99.8)	2.73 (2.04-3.49)	0.14 (0.04-0.42)	19.70 (4.5-180.0)

[†] Combination of: (1) estimated blood loss >1500 mL; (2) transfusion of >5 Units of blood products; (3) presence of surgical complication; (4) admission to Intensive Care Unit.

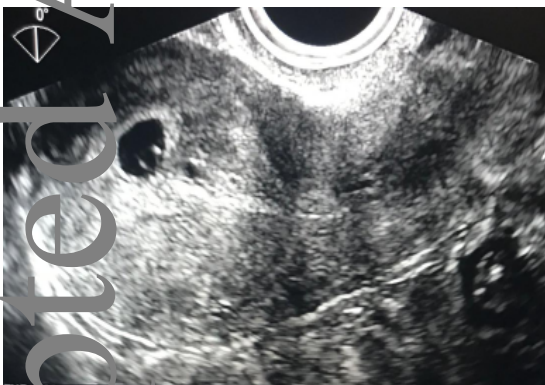Table 8. Differences in surgical outcomes in pregnancies with COS1 implantation in the first trimester and PAS3 stage on third trimester ultrasound compared to women with COS2-PAS3.

Outcome	US PAS stage		p-value
	COS1-PAS3 (n= 43)	COS2-PAS3 (n= 11)	
Composite adverse surgical outcome (%)	44.2 (19)	0 (0)	0.005
EBL >1.500 ml	23.3 (10)	0 (0)	0.101
Transfusion of >5 units of BP	23.3 (10)	0 (0)	0.101
Surgical complications	13.95 (6)	18.2 (2)	0.659
Admission to ICU	0 (0)	0 (0)	1.000
Estimated blood loss (SD)	1289.07±571.78	935.45±157.25	0.048
Mean Units of BP transfused (SD)	4.28±6.23	0.36±0.81	0.044
Mean Units of PRBC transfused (SD)	1.56±1.86	0.18±0.60	0.019
Mean Units of FFP transfused (SD)	1.65±2.54	0.18±0.60	0.064
Mean Units of platelets transfused (SD)	1.07±2.15	0±0	0.107
Length of stay (d) (SD)	6.91±2.11	6.45±1.21	0.492
Operative time (min) (SD)	182.33±31.08	161.82±32.50	0.058
Gestational age at Cc (w) (SD)	33.88±1.99	35.05±0.99	0.066

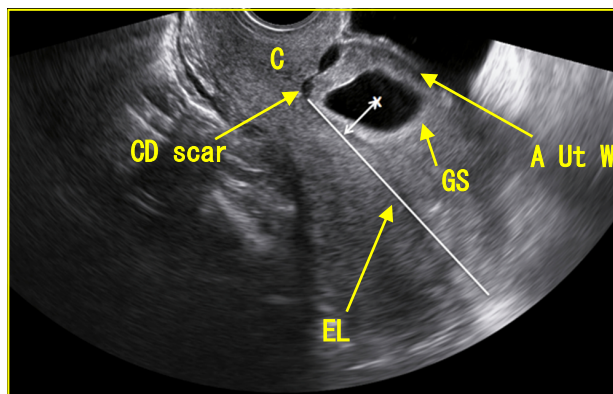
EBL: estimated blood loss; ICU: intensive care unit; BP: blood products; PRBC: packed red blood cells, FFP: fresh frozen plasma; CD: cesarean delivery.

FIGURE 1 A: Cross over sign

COS0



COS1



COS2

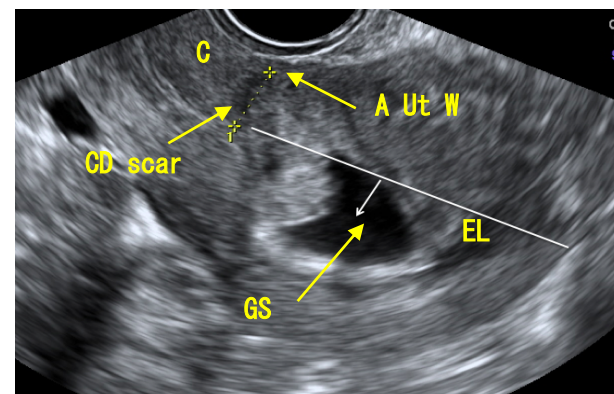


Figure 1B: On the scar (A) and in the niche (B)

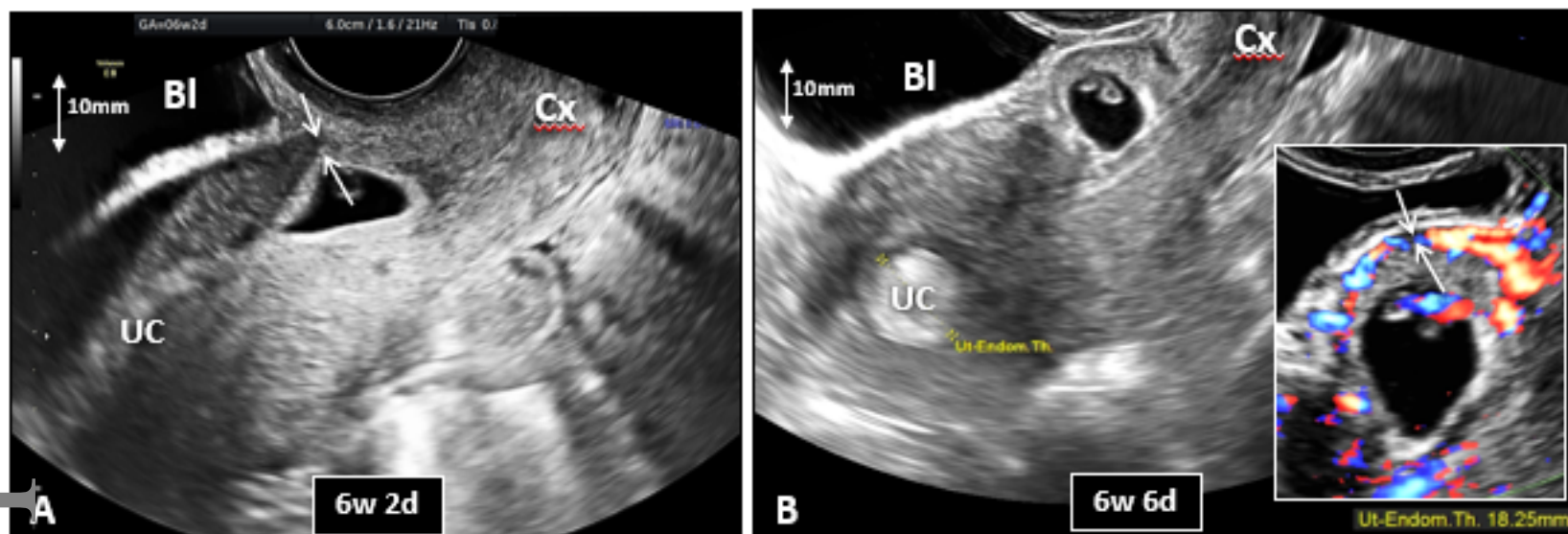
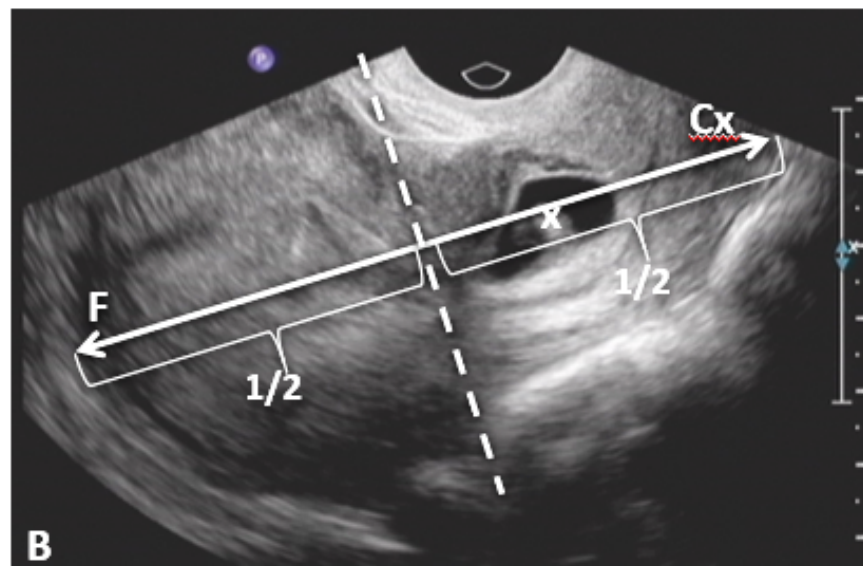
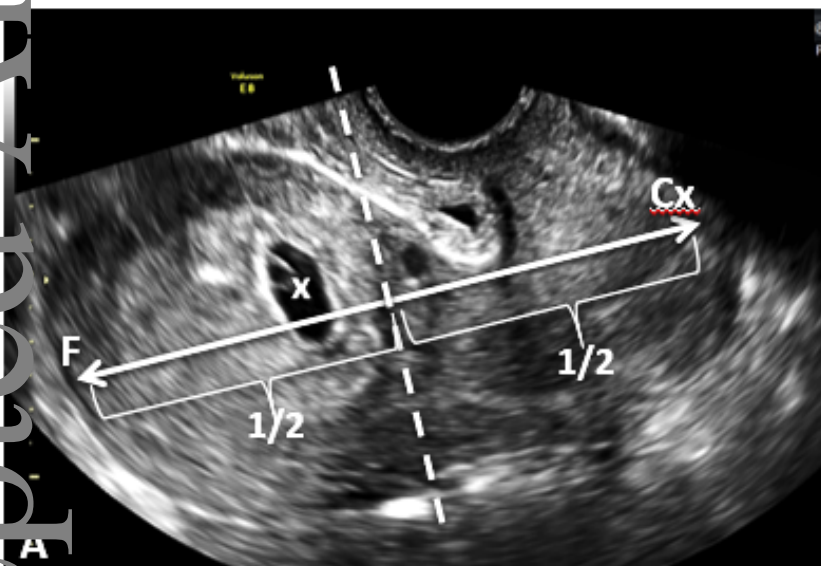
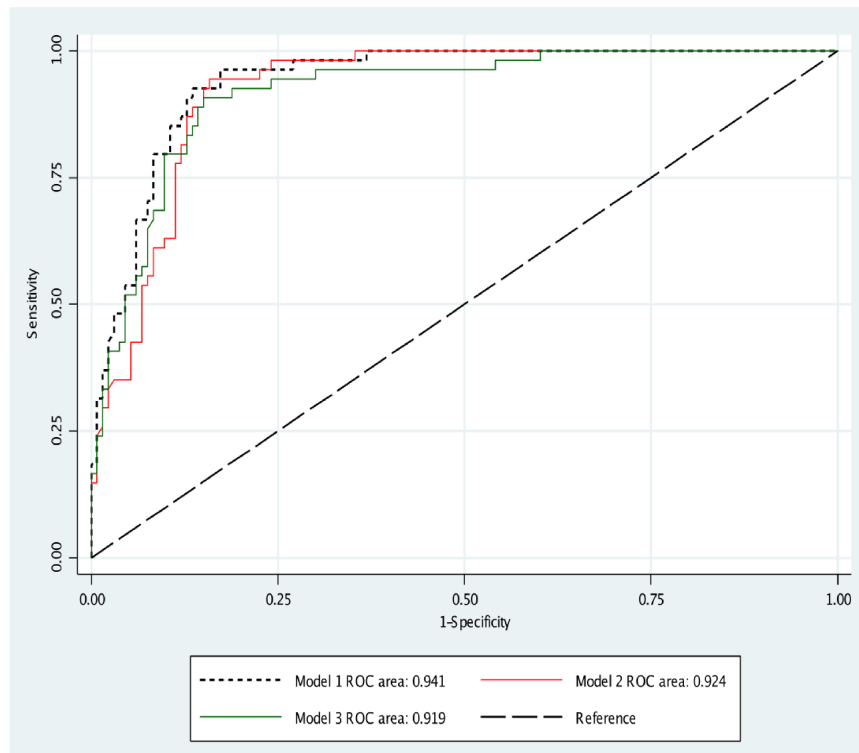


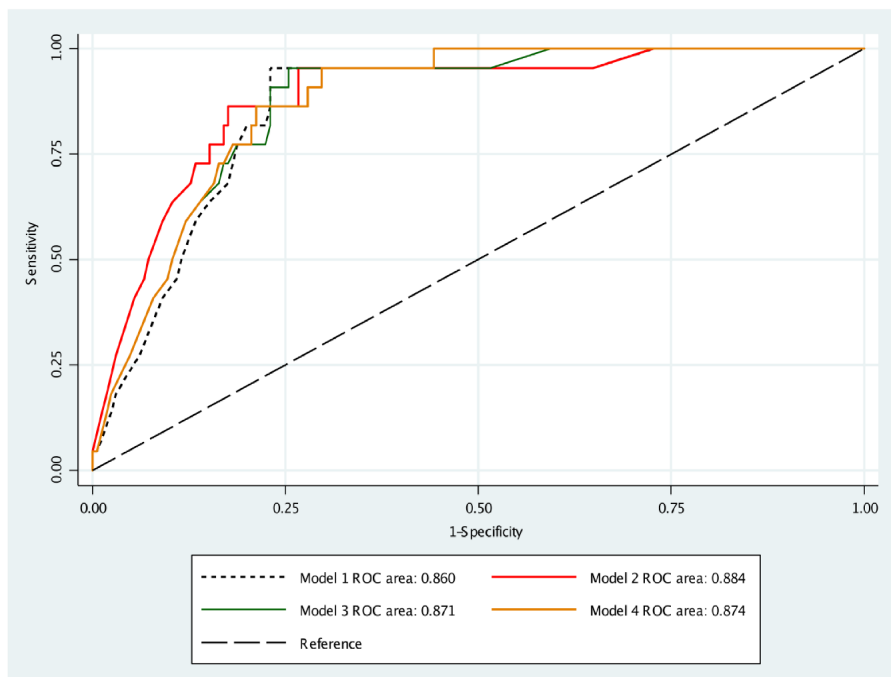
Figure 10: Above vs below the midline of the uterus





ROC curve	[95% CI]	
Model 1	0.941	0.910-0.972
Model 2	0.924	0.887-0.960
Model 3	0.919	0.877-0.960

Ho: $\text{area}(p1) = \text{area}(p2) = \text{area}(p3)$
p = 0.1339



ROC curve [95% CI]

Model 1	0.860	0.790-0.930
Model 2	0.884	0.814-0.953
Model 3	0.871	0.808-0.933
Model 4	0.874	0.816-0.932

Ho: area(p1) = area(p2) = area(p3) = area(p4)
 p = 0.3028

Figure 4: The “Anterio-Inferior PAS Risk Triangle” of pregnancy implantation

