

# The superior parietal lobule of primates: a sensory-motor hub for interaction with the environment

Lauretta Passarelli<sup>1</sup>, Michela Gamberini<sup>1</sup>, Patrizia Fattori<sup>1,\*</sup>

<sup>1</sup>Department of Biomedical and Neuromotor Sciences, University of Bologna, 40126 Bologna, Italy

\*Correspondence: [patrizia.fattori@unibo.it](mailto:patrizia.fattori@unibo.it) (Patrizia Fattori)

DOI:10.31083/j.jin.2021.01.334

This is an open access article under the CC BY 4.0 license (<https://creativecommons.org/licenses/by/4.0/>).

Submitted: 16 October 2020 Revised: 22 December 2020 Accepted: 22 February 2021 Published: 30 March 2021

The superior parietal lobule of the macaque monkey occupies the postero-medial part of the parietal lobe and plays a crucial role in the integration of different sources of information (from visual, motor and somatosensory brain regions) for the purpose of high-level cognitive functions, as perception for action. This region encompasses the intraparietal sulcus and the parieto-occipital sulcus and includes also the precuneate cortex in the mesial surface of the hemisphere. It hosts several areas extensively studied in the macaque: PE, PEip, PEci anteriorly and PEc, MIP, PGm and V6A posteriorly. Recently studies based on functional MRI have suggested putative human homologue of some of the areas of the macaque superior parietal lobule. Here we review the anatomical subdivision, the cortico-cortical and thalamo-cortical connections of the macaque superior parietal lobule compared with their functional properties and the homology with human organization in physiological and lesioned situations. The knowledge of this part of the macaque brain could help in understanding pathological conditions that in humans affect the normal behaviour of arm-reaching actions and can inspire brain computer interfaces performing in more accurate ways the sensorimotor transformations needed to interact with the surrounding environment.

## Keywords

Sensory information; Multisensory; Memory; Attention; Cerebral cortex; Neural networks; Connectivity

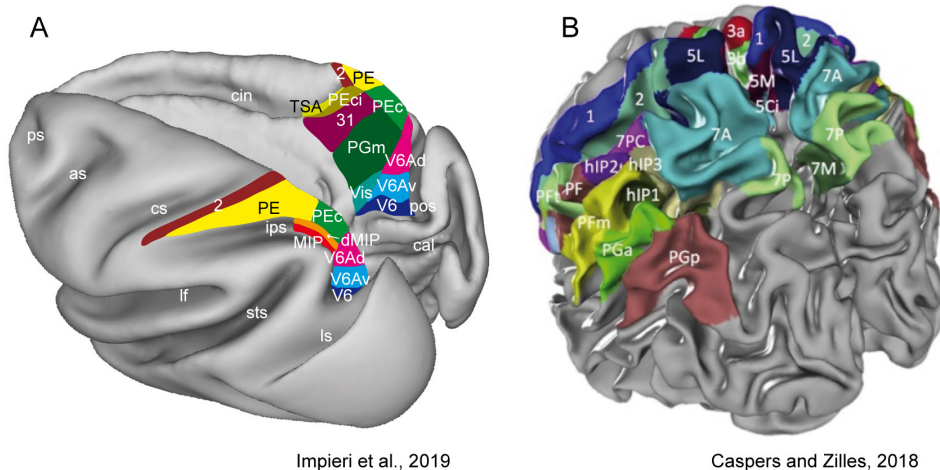
## 1. Introduction

The associative areas of the cerebral cortex are involved in “cognitive functions”, and this is known since long time, as reported in didactic books of neuroscience [1]. Cognitive functions are mental processes that enable us to perform a variety of tasks. The parietal cortex contributes to active roles in the processes of receiving, choosing, transforming, storing, processing and retrieving information, necessary to interact with the world around us. The high complexity of these tasks implies that the associative areas receive and integrate information from multiple sources of the cortical and subcortical structures of the brain.

The majority of the knowledge of the cerebral processes we manage derives from studies performed in the non-human primates. The superior parietal lobule (SPL) of the macaque monkey is an associative cortex and belongs to the parietal neuronal network that associates information com-

ing from motor and premotor, visual and somatosensory cortices. This information is involved in aspects of attention and visuospatial perception, and is found to be at the base of planning and controlling the execution of reaching and grasping movements [2–5]. The SPL region encompasses the intraparietal sulcus and the parieto-occipital sulcus, as caudal part of the parietal lobe in both humans and non-human primates and includes the precuneate cortex in the mesial surface of the hemisphere. In the macaque, it hosts several areas, cyto- and myelo-architectonically defined, that are PE, PEip, PEci anteriorly and PEc, MIP, PGm and V6A posteriorly (Fig. 1A). In human, cytoarchitectonic investigations recently subdivided the SPL in a mosaic of seven distinct areas 5L, 5M and 5Ci anteriorly, 7PC, 7A, 7P and 7M posteriorly (Fig. 1B). In addition, functional MRI studies have been shown that for some of the macaque cortical areas (V6A, PEc and PGm) a perfect parallel functional organization exists in the human SPL [2, 6–12].

The SPL of both humans and non-human primates is then an intricate system whose areas show anatomical and functional properties that underlie different functional roles. We here review the anatomical subdivision, the cortico-cortical and the thalamo-cortical connection and the functional characteristic of the macaque SPL in order to examine how it processes distinct sensory information to guide actions. State-of-the-art studies of the human SPL organization will be discussed by emphasizing the similarities to structure and circuits of the non-human primates directly accessible through experimental investigation. The knowledge of the areas of SPL in the macaque brain could help to understand pathological conditions that in humans affect the normal behaviour of arm-reaching actions. Based on the proposed similarities, we finally indicate new perspectives for the translational approaches in the field of neural prostheses, which allow brain computer interfaces to perform the sensorimotor transformations needed to interact more accurately with the surrounding environment.



**Fig. 1. Superior parietal lobule areas.**

(A): Macaca fascicularis brain, reconstructed using Caret software (<http://brainvis.wustl.edu/wiki/index.php/Caret>; Download). On the left the dorsal view of left hemisphere and on the right the medial view of right hemisphere showing in different colours the location and extent of SPL areas. Adapted from [13]. (B): Human brain showing a modern parcellation of the parietal cortex based on the JuBrain Cytoarchitectonic Atlas ([www.jubrain.fz-juelich.de](http://www.jubrain.fz-juelich.de)). Left dorso-caudal view of both hemispheres showing in different colours the location and extent of SPL areas. Reprinted with permission from [6] published in Elsevier. as, arcuate sulcus; cal, calcarine sulcus; cin, cingulate sulcus; cs, central sulcus; ips, intraparietal sulcus; lf, lateral fissure; ls, lunate sulcus; pos, parieto-occipital sulcus; ps, principal sulcus; sts, superior temporal sulcus. D, dorsal; P, posterior.

## 2. Connectional circuits underling the functional role of macaque SPL

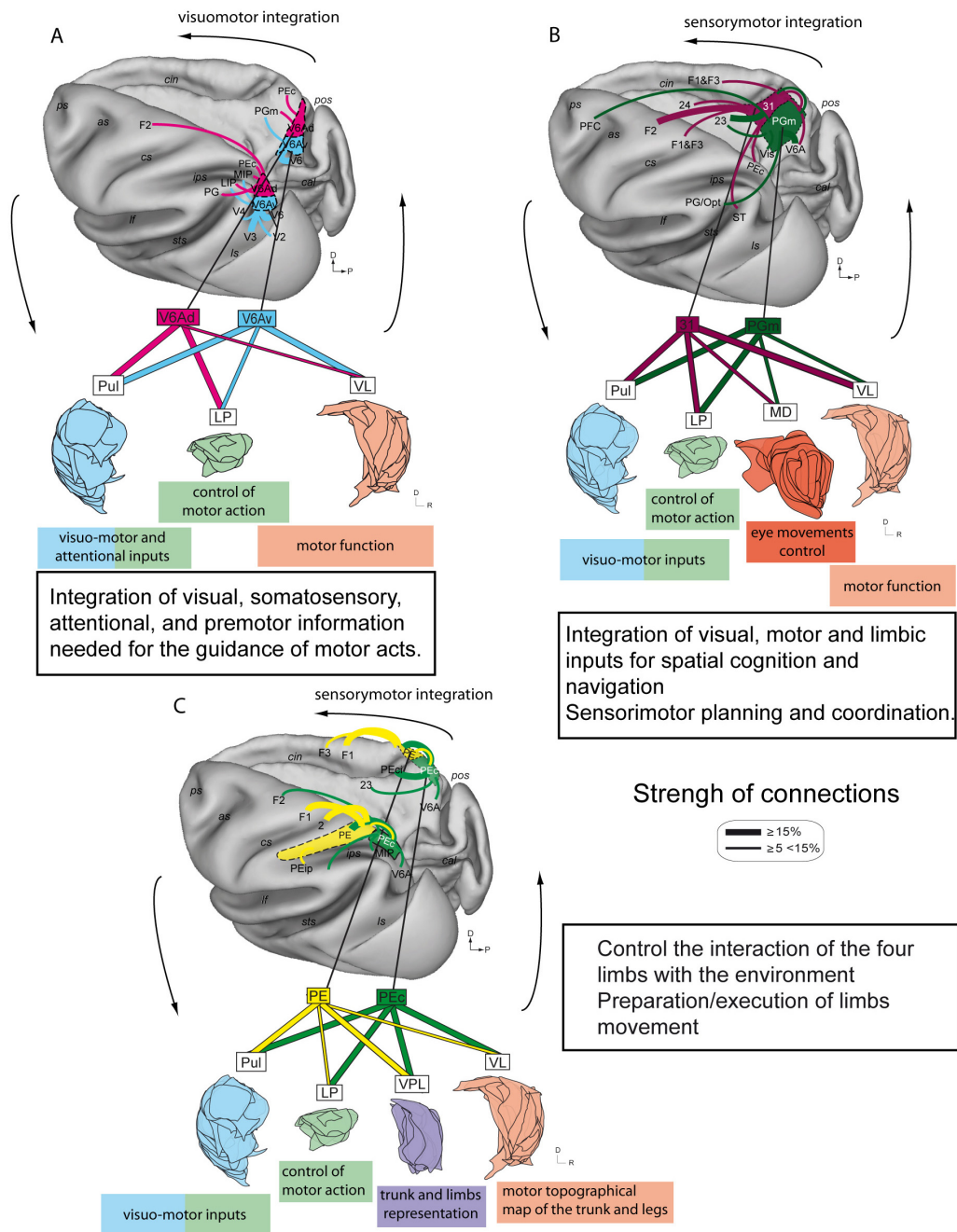
The study of cortical and subcortical connections is crucial to describe the neuronal networks in which SPL areas are involved, and their functional role. The following sections summarize current knowledge on the connectivity of this brain region with other cortical and subcortical structures to provide a short survey of the principal functional features of the macaque SPL areas.

### 2.1 Cortico-cortical connections

The caudalmost part of the SPL, on the anterior bank of the parieto-occipital sulcus, hosts area V6A [14–16] that is characterized by a cytoarchitectonic pattern typical of the parietal areas [17] and has been divided in ventral (V6Av) and dorsal (V6Ad) subsectors [18]. V6A occupies about two thirds of the anterior bank of the POs and extends to the caudalmost part of the precuneate cortex on the mesial surface of the hemisphere [15]. Overall, the extrastriate areas of the occipital lobe (V2, V3, V4, MST, V6) and the visual and visuomotor areas of the posterior parietal cortex (e.g. AIP and LIP) are the source of visual information to V6A. V6A receives also somatosensory and somatomotor inputs from PEC and MIP [19, 20] and is connected reciprocally to the dorsal premotor area F7 and with the sector of premotor area F2, that represents the upper limb. This is in line with the reaching/grasping activity and the primarily upper limb representation in V6A [21–23]. Specifically, V6Av has connections mostly with extrastriate visual areas while V6Ad with parietal and frontal areas (Fig. 2A top) [18, 24]. The flow of visual information from V6Av to V6Ad can be useful to control the movements of the upper limbs [18].

The precuneate cortex hosts also the mesial sectors of area V6A and PEC, as well as areas PGM and 31 [25–28]. The majority of inputs to PGM and 31 come from V6A and from the dorsal portion of the posterior cingulate area 23 (23e), but some differences are present. Visuomotor areas are involved in the spatial cognition (including the lateral intraparietal cortex, inferior parietal lobule, and the putative visual areas in the ventral part of the precuneus) and are strongly connected with area PGM, whereas premotor and parietal sensorimotor areas are connected with area 31. Area 31 receives additional inputs from the anterior cingulate cortex (area 24), and PGM from retrosplenial areas, located in the mesial surface of the brain (Fig. 2B top). These findings suggest for PGM a crucial role in visuospatial cognition and navigation, and for area 31 in sensorimotor planning and coordination [28].

In addition to the above-mentioned areas, the mesial surface of the SPL hosts area PEci or SSA (Supplementary Somatosensory Area) hidden into the depth of the caudal tip of the cingulate sulcus [27, 29, 30]. Cortical afferences to area PEci come from frontal (areas 4, 6, 8, F2, and 46), sensory (areas 1, 2, and 3), superior parietal (areas PE, PEa, PEc, PO), inferior parietal (areas SII, paAc, PGop, PG, Tpt, and MST), insular, and medial (areas PGM, 31, TSA, 23a/b, 24a/b, F3 and F4) cortices [27]. Interestingly, PEci has many connectional similarities with PE, but not with PEC. Like PE, PEci receives afferents from motor and premotor cortical regions and does not receive visual inputs, while PEC is connected with somatomotor and visual areas [19, 31].



**Fig. 2. Cortico-cortical and Thalamo-cortical circuits involving SPL areas.**

Representation of the main cortico-cortical and thalamo-cortical connections of areas V6Av, V6Ad, PE, PEc, PGM, 31, shown in pairs.

(A) Top: Cortical connections of areas V6Av and V6Ad, Bottom: Reconstruction of the thalamic nuclei that send afferences to areas V6Av and V6Ad obtained by superimposing all sections scanned. For each area and thalamic nucleus only projections encompassing more than 5% of the total connections of that area or nucleus are represented. The thickness of connecting arrows and lines is proportional to the strength of connections, averaged across cases with injections in the same area (middle right) (data taken from [12, 18, 24, 43]). The thalamic nuclei are highlighted with different colors: blue for Pul, green for LP, pink for VL, purple for VPL and red for MD. Area V6A is shown in the two cyto-sectors, ventral and dorsal (V6Av and V6Ad) to appreciate the differences in connectional properties, even though, currently it is considered that the two cyto-sectors of area V6A work as a single functional entity in the control of reach-to-grasp movements, V6Av mainly managing the visual aspect and V6Ad the somato-motor aspect of this control [44].

Abbreviations as in Fig. 1.

(B): Cortico-cortical connections and thalamo-cortical connectivity of areas PGM and 31 are shown, same as in A (data taken from [28, 45]).

(C): Cortico-cortical connections and thalamo-cortical connectivity of areas PE and PEc are shown, same as in A (data taken from [19, 42, 46]).

Moving laterally on the SPL, PEip rostrally and MIP caudally [32–35] occupy the medial wall of intraparietal sulcus in the lateral portion of SPL. PEip shows connections with anterior parietal, primary motor, and ventral premotor areas, and seems to be part of the parietal field that contains large representations of the distal forelimb [36, 37]. Several studies on grasping objects [38, 39], also in the case of either movements highly stereotyped or in the absence of visual information [40, 41], were carried out precisely in the rostral parts of the posterior parietal cortex, near both banks of the intraparietal sulcus. MIP receives denser input from somatosensory areas, the primary motor cortex, and the medial motor fields, as well as from visual cortex in the ventral precuneate cortex and frontal regions associated with oculomotor guidance. These connections suggest that MIP is involved in sensorimotor behaviour, being directly involved in movement planning and execution [20].

Finally in the cortical convexity of the SPL, the areas PE rostrally and PEc caudally [25] have been described, and both extend also medially and laterally into the mesial surface of the hemisphere and the medial wall of the intraparietal sulcus, respectively. Areas PEc and PE share several cortical connections (Fig. 2C top). The cortical inputs to area PE come from regions of parietal and frontal cortices with somatosensory and motor characteristics, which support the proposed functional role for this area: to plan and guide reaching movements [42]. Area PEc is mainly connected with somatosensory and somato-motor areas of parietal and frontal lobes, and receives visual information from the visuo-motor area V6A, and in particular from its dorsal subdivision [19, 34]. This connective pattern supports the involvement of area PEc in the process of locomotion and in coordination of movements in natural environments [19].

### 2.2 Thalamic afferences to the SPL areas

We provide hereafter an overview of the thalamo-cortical connections that have been recently described in detail (Fig. 2) [43, 45, 46] to gain insight and complete the neural circuitry of SPL areas and relative functional role.

Studies on the thalamo-cortical connections in macaques [47–49] and New World owl and squirrel monkeys [50] have demonstrated that posterior parietal areas are mainly connected with the lateral posterior (LP), ventral lateral (VL), and medial pulvinar (PuM) thalamic nuclei [51].

Recent studies [43] demonstrated that the major inputs of thalamic projections to area V6A as a whole come from the lateral posterior and medial pulvinar nuclei, whereas minor inputs come from the ventro-lateral nucleus (Fig. 2A bottom). The functional characteristics of area V6A [43] well agree with the role of the visuo-motor integration of lateral posterior and medial pulvinar nuclei [51], as well as the motor functions of the ventral lateral nucleus [52], and the eye-related activity of medial dorsal nucleus [53]. The consistency in the thalamo-cortical pattern supports the view of an integrative role of visual, somatosensory, attentional, and premotor information needed for the guidance of motor acts

[43].

Thalamic inputs to areas PEc and PE mostly originate from lateral posterior, medial pulvinar, ventral posterior lateral (VPL), and ventral lateral nuclei, all structures involved in visual, somatosensory, and/or sensorimotor processing (Fig. 2C bottom). VPL and VL nuclei, characterized by a precise somatotopy, show labelled neurons in regions likely to correspond to the trunk and limb representations (in particular the legs) [46]. The sensory-motor integrative nature of these posterior parietal areas PEc and PE is supported by the thalamic inputs above described [54–60], with the former area involved in the control of four limbs interaction with the environment [19], and the latter one involved in the preparation/execution of limb movement [55, 60–65]. The corticothalamo-cortical circuits including PEc and PE also suggest playing a role in supporting some degree of motor automatism, crucial in locomotion.

The medial and lateral subdivisions of the pulvinar linked to association and visual function, transmit strong inputs to area PGm, whereas area 31 receives afferents from the oral division of the pulvinar (Fig. 2B bottom). Both areas also receive input from subdivisions of the lateral thalamus linked to motor function (VL and VA nuclei), and only PGm receives important limbic association afferents, mainly via the lateral dorsal nucleus. Therefore, PGm integrates information from visual association, motor and limbic regions of the thalamus by giving support at the hypothesized role in spatial cognition, including navigation [28], and in spatial learning and memory [66]. By comparison, dorsal precuneate area 31 is more involved in sensorimotor functions, being similar to adjacent areas of the dorsal parietal cortex [45]. To date, the thalamo-cortical connections of the lateral part of the SPL are poorly understood.

The pulvinar complex and the lateral posterior nucleus constitute the numerically predominant projections of the thalamus to the parietal lobe, as described in recent and former studies [43, 45, 46, 48, 67], and thalamic connections likely reflect parietal specializations in cognition and in the planning and control of motor actions [2, 68–72]. However, they are often considered as a unique functional unit as the failure to establish a clear border between the LP and the pulvinar nuclei [73–75]. The associative nucleus LP provides information on somatic and attentional stimuli useful in the control of movements [43, 76, 77]. The medial pulvinar is a multimodal associative nucleus: it has extensive connectivity with high-order cortical systems (but not with early sensory areas) [78], it forms the subcortical component of the attentional network of the brain [79, 80] and is involved in visuospatial processing and reward-based decision making. These connective data encourage the hypothesis that the dorsal and caudomedial portion of SPL are primarily involved in the guidance of sensory-spatial behavior [45].

### 2.3 Functions of the SPL areas

The knowledge of the connectivity above summarized, indicate that areas PE, PEip, and PEci are somatomotor ar-



areas non affected by visual signals. Conversely PEc, MIP, PGm, and V6A areas are influenced by both somatomotor and visuomotor signals. All these areas of the SPL form two pathways heavily interconnected and working in opposite direction; the visual pathway moves from the posterior to the anterior areas, while the somatosensory runs contrariwise, with an overlap in the intermediate areas, typically the sensory-motor areas. These two interconnected flows of visual and somatosensory information with an overlap in sensory-motor areas, are part of neuronal networks functional to program and control the execution of reaching and grasping movements [2, 3, 12].

The proposed role of SPL areas based on cortical and subcortical connections is supported by many functional studies. In the last decades these functional studies have demonstrated that SPL is not only a structure deputed to the integration of diverse types of sensory information [54, 81, 82], particularly somatic and visual, but it also plays a role in the control of somatomotor, visuomotor, oculomotor activities, as well as in the guidance of visuospatial attention [3, 64, 83–89]. Neurons in the SPL are important in the perception and relation of the body to the external space during reaching, pointing, and grasping. In fact, arm movements performed by monkeys to reach and grasp objects in the peri-personal space, activate SPL neurons. Therefore, the areas of the SPL are implicated in processes related to arm movement planning, execution, and online control [2, 3, 21–23, 62, 83, 90–97].

### 3. The organization of human SPL

Recent structural and functional studies have evidenced a correspondence between the monkey and the human parietal cortex by proposing putative human homologues of some of the areas we have described above.

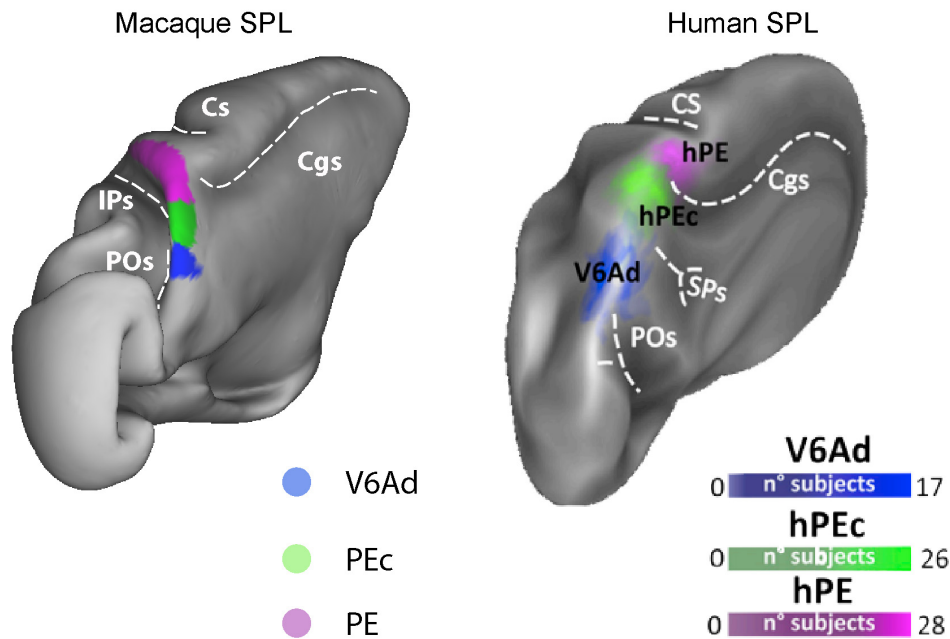
Under the structural point of view, the SPL in human is bounded anteriorly by the postcentral sulcus (PoCS), posteriorly by the lateral extension of the parieto-occipital sulcus, and laterally by the intraparietal sulcus, and involves the precuneus (PrC) located medially, but caudal of the posterior cingulate sulcus (CiS). Cytoarchitectonic analysis [7], probabilistic mapping of cytoarchitectonic areas [8] along with the investigation of the distribution of the receptors of the main neurotransmitter families [98, 99] have been recently used to characterize SPL, allowing to supersede Brodmann's [100] original subdivision into areas 5 and 7. Brodmann area 5 (BA5) has been further subdivided in two mesial areas, 5Ci (cingulate parietal) and 5M (medial parietal), and one lateral area (5L) located in the rostral bank of the post-central sulcus. Area 5L and 5M would be equivalent of macaque's area PE, while 5Ci would correspond to macaque area PEc [98, 99]. BA7 has been split into area 7PC, located in the posterior wall of the post-central sulcus, 7A and 7P in the anterior and posterior part of dorsal SPL, respectively, and 7M in the medial wall [98, 99] (Fig. 1B). The macaque equivalent of these areas would be areas MIP and/or PEip, PEc, V6A and PGm respectively [12, 89].

The onset and development of *in vivo* diffusion-weighted magnetic resonance imaging and fiber tracking algorithms have considerably advanced the structural connectivity in human brains. Diffusion tensor tractography (DTT) based on the diffusion tensor-MRI, locate and image the course of the neuronal fiber tract and its trajectory. The superior longitudinal fasciculus (SLF) is a large bundle of association fibers in the white matter of each cerebral hemisphere connecting the parietal, occipital and temporal lobes with ipsilateral frontal cortices, subdivided in five subcomponents [101]. The SLF eases the formation of a bidirectional neural network essential for core processes such as attention, memory, emotions and language [102, 103]. Studies in non-human primates have been largely used to trace long fiber pathways within the fronto-temporo-parietal region [104–112]. It has been demonstrated that connectivity of the SPL, medial SPL and precuneus in particular, follows primarily the course of the SLF I [6]. The SLF I originates in the superior and medial parietal cortex, that is located near the superior-lateral cingulum bundle on the coronal planes in each cerebral hemisphere. The SLF I extends from the superior parietal lobule along the cingulate gyrus in the superior parietal and frontal white matter (Brodmann area (BA) 7, 5, 4) rostrally to the superior frontal gyrus white matter, and terminates in the dorsal and medial cortex of the frontal lobe in the supplementary [101, 113] and premotor areas of the frontal lobe (BA 6, 8, and 9) [114].

The present understanding of human connectivity is comparable with neurotracer injections studies on non-human primates where it has been shown that all areas of SPL form a network with the areas of the frontal and premotor cortices, as we have described in section 2.

Moreover, the analysis of DTT images has indicated in the human brain a strong SPL interconnection with the posterior temporal lobe, called the SLF/AF TP-SPL, the temporo-parietal (TP) white matter connections of the superior longitudinal fasciculus/arcuate fasciculus (SLF/AF) connecting the posterior temporal lobe with the SPL. This connection has not yet been elucidated on the previous DTI or anatomical studies in non-human primates, and in human brain it may be linked to language development and may explain the higher cognitive and comprehensive language functions in humans compared with other primates.

The human parietal lobe is also largely connected with subcortical structures, especially with the thalamus. It has been demonstrated *in vivo* that posterior parietal areas target mostly a region within the thalamus corresponding to the lateral posterior nucleus and the anterior and lateral pulvinar [115, 116]. Medial SPL areas within the precuneus have prevalent connections with the dorsal pulvinar. These connections were clearly distinguishable from connections of the ventral pulvinar to early and higher visual areas [117, 118]. The human connections between thalamus and cortex are similar to those reported for non-human primates [43, 45, 46].



**Fig. 3. Homologies between some SPL areas in macaque and human brain.**

3D reconstructions of the postero-medial view of a left hemisphere of the macaque (left) and of the human (right), not in scale.

Left: Extent and location of the cytoarchitecturally defined areas V6A, PEc and PE. The borders were obtained overlapping retinotopic and functional properties of single neurons and cytoarchitectonic features in monkeys [14, 44, 136].

Right: Extent and location of hV6Ad, hPEc and hPE [10, 122]. Individual ROIs are overlapped onto Conte69 brain atlas to form group probabilistic ROIs. The color scale indicates the proportion of subjects whose ROI included that surface node, thus the probability that the node is included in the ROI.

Dotted line indicates the fundus of main sulci: Cgs, cingulate sulcus; CS, central sulcus; IPs, intraparietal sulcus; POs, parieto-occipital sulcus; SPs, sub-parietal sulcus.

Modified with permission from [10] published in Elsevier.

Despite all the aforementioned studies provide a comprehensive and multimodal representation of the network architecture of parietal areas, the cortical network and functional organization of each human SPL subregion remains largely unknown. For this reason, many functional studies with fMRI techniques have been carried out to identify putative human homologue of areas of macaque brain, in the following we focus on those studies only referring to SPL areas. Sereno and co-workers, using fMRI techniques, have identified a second somatosensory homunculus in a region of the human SPL, located in the postcentral gyrus, immediately posterior to the primary somatosensory cortex: they called it Parietal Body Area (PBA) [119, 120]. PBA contains a rough topographical map of the body resembling the one observed in the macaque area PE [36]. Another very recent neuroimaging study demonstrated that the same areas described in the macaque SPL, V6A, PEc, and PE can be found in the human medial SPL cortex, as shown in Fig. 3 where the brains of the two species are compared [10]. Human (h) V6A is located in the posterior portion of SPL, anterior to the parieto-occipital sulcus, in a cortical territory that includes the caudalmost portion of the precuneate cortex; hV6A is anterior to hV6 [121] and posterior to hPEc. The latter occupies the dorsalmost portion of the anterior precuneus, just behind to the dorsal tip of the cingulate sulcus [122]; area hPE

is anterior to hPEc and sits in the dorsomedial portion of the post-central gyrus, just over the tip of the cingulate sulcus [10]. In parallel with macaque studies, human V6A shows a clear over-representation of the contralateral lower visual field and responds only to visual stimulation of the far periphery (starting from 30°) [123]. This region activates for pointing [9, 122, 124–127] as well as for reaching and grasping movements [128–135]. The juxtaposition of the macaque-SPL and human-SPL shows a comparable structural organization, in which the anterior portion has somatosensory characteristics and the caudal part visual and somatosensory features, although more studies are needed to further decipher the still elusive functional properties of the various sectors of humans SPL.

#### 4. Effect of lesions in parietal cortex

In this section, we provide a revision of some neurological syndromes associated to lesions in both human and non-human SPL areas. The study of lesions in a specific brain area permits to understand in an indirect way its role in normal conditions starting from specific dysfunctions. In addition, it allows the understanding of the functional role of SPL areas to process distinct sensory and motor information to guide actions.

Parietal lesions result in severe impairments in the control of eye movements towards visual targets, in the guidance of reaching actions and of the grasping of nearby objects, as well as in the ability to direct attention to visual stimuli, in both human and non-human primates.

In humans, the Balint's syndrome is a manifestation of behavioural impairments specifically associated with lesion in the SPL and the parieto-occipital junction. Balint's syndrome includes difficulty in executing eye movements to capture visual targets (ocular apraxia), inability to perceive multiple objects simultaneously (simultanagnosia), and inability in reaching for visual targets (optic ataxia). These symptoms have a heavy impact onto the visuospatial skills, the visual scanning and the attentional mechanisms [137]. Simultanagnosia is the inability of the patient to perceive multiple items when visually displayed concurrently but maintaining the ability to recognize single objects. Simultanagnosia might result from an extreme form of competition between objects, which makes it difficult for attention to be detached from an object once it has been selected [138]. Patients have a narrowed spatial window of visual attention and only one object at a time can be seen [139]. As a result of this impairment, patients with simultanagnosia often fail to understand the overall meaning of a scene. After six months of rehabilitation, a sensory/motor evaluation ascertained that clinical neurological symptoms in patients with Balint's syndrome did not disappear, despite observable functional and physical improvements. Further studies are required to adequately develop effective rehabilitation protocols and demonstrate the effectiveness of rehabilitation in treating patients with Balint's syndrome [137].

Unilateral or bilateral lesions in regions of the SPL can also produce a distinct syndrome, optic ataxia [140–144] characterized by errors in reaching, particularly toward objects in the visual periphery [145], as documented in Fig. 4. Patients suffering from optic ataxia after lesions of the SPL, the parieto-occipital junction, or the intraparietal sulcus, due to stroke or surgery circumscribed to unilateral right or left hemisphere [143, 146] experience difficulty in making visually guided arm movements towards an object in the visual environment (Fig. 4). The impairment is severe when the target is located peripherally in the visual field, diminishes when the target lies in the parafoveal region, and it is negligible when the target is foveated by the patient. A worsening in the performance occurs in the use of the hand or in the reaching into the visual field both contralateral to the lesion [144, 147, 148]. Patients with optic ataxia also manifest deficits in regulating hand orientation [140] and shaping [149, 150] during visual guided grasping that may arise from a failure to transform retinal information into appropriate spatial coordinates for action [151]. The failure is due to the fact that the brain damage involves the human cortical territory of area V6A (roughly corresponding to the purple area shown in the 3D image of the bottom of Fig. 4) [3, 9, 15, 94].

Similarly, in monkeys, the evidence that brain lesions re-

stricted to area V6A produce misreaching and misgrasping during visually guided movements [152] supports the same hypothesis. In particular, V6A lesions produce underestimation of the position of reach/grasp targets, increase the reach and grasp times, with abnormality in conforming and orienting the hand towards the targets. This, overall, results in an inability of correctly reaching and grasping a visual target, especially with the arm contralateral to the lesion. The functional characteristics of V6A cells are congruent with the misreaching and misgrasping observed after V6A lesion [3].

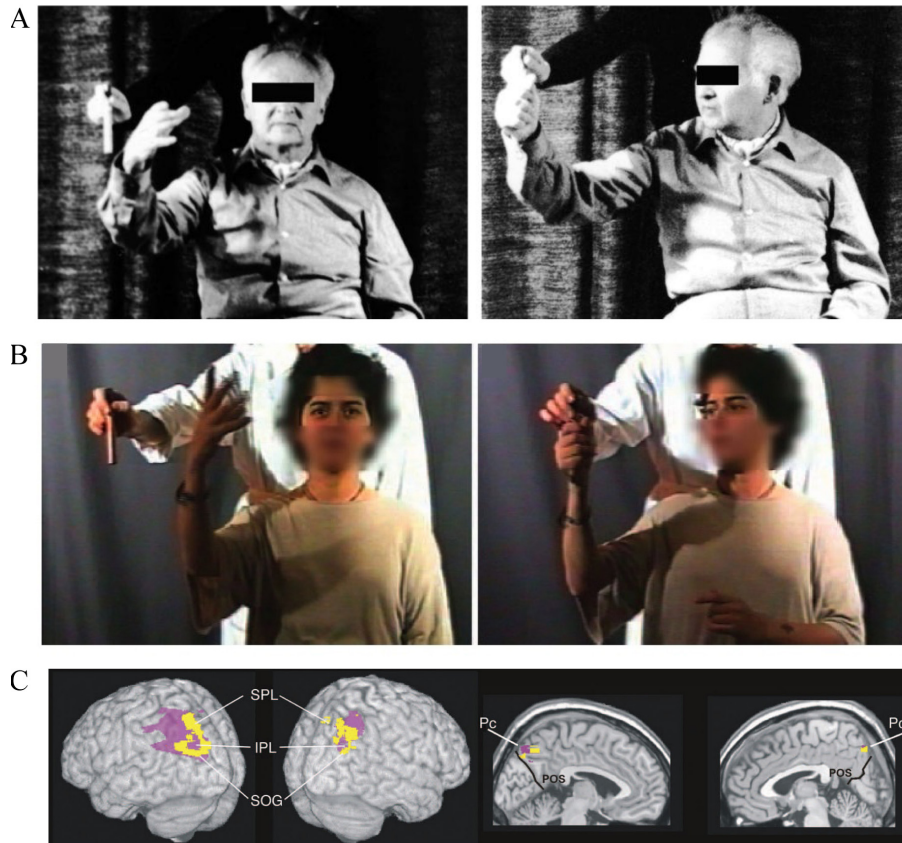
Enhancement in both reaction- and movement-times necessary to adjust the trajectory towards a target, while monkeys executed reaches and saccades to visual targets and the target position changed unexpectedly, has been showed in a study in the monkey superior parietal area 5 (PE/PEc). In this study this region of the brain was reversibly inactivated after bilateral muscimol injection [153] and the authors interpreted these findings as a deficit in the online control similar to that observed in optic ataxia patients.

Lesions in the human SPL may cause also tactile agnosia, an inability to identify familiar objects manually [154] or tactile apraxia, characterized by an isolated disturbance of hand movements for use of and interaction with an object [155]. This evidence highlights relevance of the areas of SPL in perception of the objects, spatial attention and in encoding of target location for the online control of arm movements.

It is not surprising, considering the above recalled thalamo-cortical connections, that lesion in the dorsal pulvinar in both human and non-human primates leads to a constellation of deficits involving the selection of eye and hand movement targets and coordination of visually guided manual reaching and grasping [156, 157] very similar to that observed after V6A lesion. In macaque monkeys, reversible inactivation of the dorsal pulvinar with muscimol injection resulted in a spatial neglect syndrome accompanied by visuo-motor deficits including optic ataxia during visually guided limb movements [156]. In humans, the patient with a lesion centred on the medial portion of the dorsal pulvinar exhibited: reach and grasp difficulties, problems to form a precision grip, reach deficits expressed in decreased accuracy, delayed initiation and prolonged movement durations. Reach deficits were similar in foveal and extrafoveal viewing conditions and in both visual hemifields but were stronger with the right hand [157]. These findings highlight the importance of the dorsal aspect of the pulvinar nucleus as a critical hub for spatial attention, visual cognition and selection of visually guided actions, according to the thalamo-cortical network described in section 2.

The comparison of the lesions in SPL in the two species of primates is not trivial and creates greater difficulties in making comparisons than relying on the other techniques described in this review. Brain lesions in fact differ in the two species for at least two aspects: the extent of the cortical lesion and the duration of the functional recovery. The extent of human lesions is caused by pathological situations that of-

## Optic ataxia syndrome



**Fig. 4. Reaching for a target in two exemplary patients with optic ataxia.**

(A-B): Left: patients showed misreaching for a target in peripheral vision, when they had to fixate the camera lens in front of them. Right: the patients showed normal reaching under foveal vision when they had to orient eyes and head towards the object while reaching for it. Typically, such ataxic reaches were shown most frequently with the contralesional hand in contralesional space. (C): Location of the centre of the lesion that causes optic ataxia, in lateral and mesial views. Subtracted superimposed lesions of 10 left and 6 right optic ataxia patients minus 2 brain-damaged control groups, matched either for associated symptoms (pink area) or for lesion location, primarily involving the parietal lobe (yellow area).

IPL, inferior parietal lobule; Pc, precuneus; SOG, superior occipital gyrus; SPL, superior parietal lobule. The parieto-occipital sulcus (POS) is shown in black on the medial views. Adapted with permission from [143, 160] published in Oxford University Press and in SAGE journals.

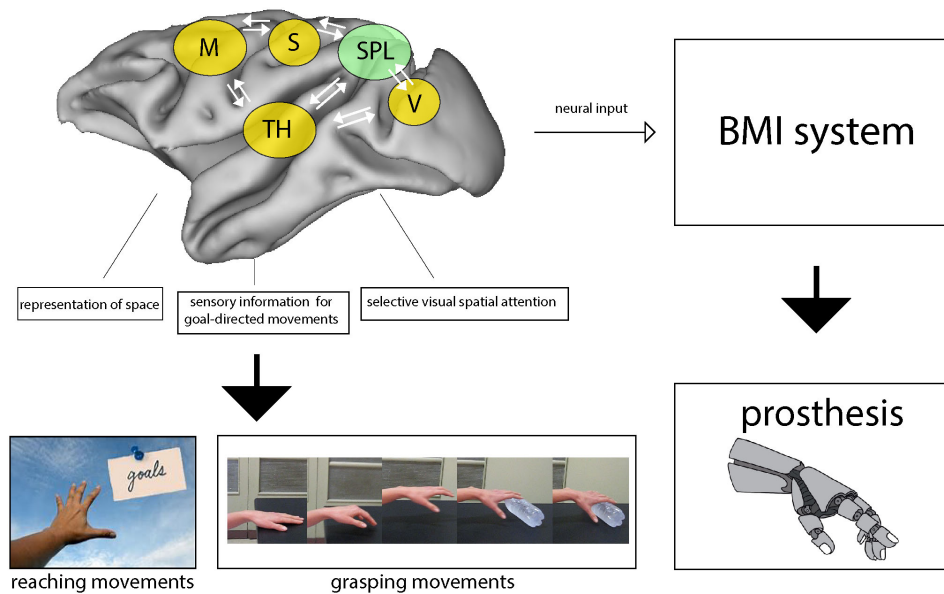
ten involve large territories, often including many different areas and largely diverse from one patient to the other. On the contrary, lesions in non-human primates are performed with the intent of elucidating the role of a single area, or portions of areas, so they are limited in extent and very precisely located in particular districts. Any comparison among species must consider this important difference. Regarding recovery time, in the monkey, muscimol creates lesions of few hours, and the deficits after surgical lesions often disappear in a few days (3-4 days) [152]. This fast recovery can be caused by the limited extent of the lesion, but also for other reasons, like the faster development of monkey brains and their greater plasticity [158]. Furthermore, areas distant from the core of the lesion can play an important role during the early post-recovery period, whereas the perilesional areas contribute to functional recovery especially during the late post-recovery period [159]. For this reason, the lesion in the monkey can likely have a shorter recovery time as being more limited in

its spatial extent. On the contrary, in human the lesions can involve large parts of the brain and the variability between individuals can be high, by delaying or preventing a full recovery of the patients. Despite differences in the two models, the pathological effects of the SPL lesions described in this chapter are comparable. Therefore, the proposed homology between human and monkey SPL could help to understand the role of this part of the brain tapping from animal studies to find out possible therapeutic applications for human health.

### 5. Exploiting SPL neurophysiology to restore human health

The homology between human and monkey SPL, discussed in previous sections, could find applications also in the field of neural prostheses and brain-machine interfaces (BMIs). BMIs are designed to circumvent lesions and repair human cognitive or sensory-motor functions [161].





**Fig. 5. The Superior Parietal lobule of primates: a sensory-motor hub for interaction with the environment useful for improving human health.** Simplified scheme showing a network of areas of the macaque brain that are reciprocally connected with the areas of SPL and the thalamus, involved in the guidance of arm-reaching and reach-to-grasp movements. The SPL acts as a hub for exchange of sensory and motor-related information crucial for guiding arm actions towards targets in the environment and for adjusting hand shape to objects so to grasp them. The knowledge about this network in the macaque can help to conceive brain machine interfaces able to use neural signals from human SPL to guide prosthesis in tetraplegic patients. Abbreviations: M, motor areas; S, somatic areas; SPL, superior parietal lobule areas; TH, thalamus; V, visual areas.

In the past decade, in order to guide robotic limbs in monkeys and humans, the majority of studies has investigated the signals to reconstruct reach trajectories from primary motor and premotor cortex [162–165]. Today the new field of investigation has moved towards the posterior parietal cortex in humans and monkeys as a good source of different kinds of signals, such as those related to movement intentions and goals. Information about reach-endpoints [166, 167], trajectories [168], and grips [169] are encoded from the monkey posterior parietal cortex. Translated to humans, these studies produced comparable and promising results [170], together with reliable hand shape decoding [170]. Among the posterior parietal areas, studies by Filippini and colleagues [171–173] have shown that grasping and reaching signals and also multiple task- and intention-related variables could be decoded simultaneously from population activity in area V6A. Area V6A is a good source of information on the guidance of grasping movement with or without visual information and on the control of the interaction between hands and object. Information that can be decoded and used in preparation and execution of movement of prehension [171] and for the offline decoding of reach goals located at different depths and directions, mimicking everyday life conditions [172]. Filippini used two different tasks, one in which the monkeys fixated the goal of reaching movement, which is the most common physiological condition [174, 175] and another where gaze and reaching targets did not coincide. In both conditions, the accuracy of decoding was optimal from early target fixa-

tion to the end of the reaching task and supports a strong spatial tuning in V6A reach-related activity when gaze is dissociated from the reach target position [176]. The results suggest that V6A could be a source for BMIs both when the patient can move his or her eyes to the reaching target and also in the absence of ocular motility [172]. From V6A population activity, it is also possible to decode simultaneously information regarding the target position, the required movement type and the time interval as the task progresses [173]. A metric estimation of the target positions has been derived via maximum likelihood estimation that when compared with the Naïve Bayes classifier, allowed obtaining a classification of task type. Finally, by using a Bayesian decoder, the posterior probabilities of free, delay and movement states could be obtained [173]. Therefore, neurons in V6A encode several types of information such as spatial position, intention for a specific motor response and progress of the task in the same population. Additionally, they support the idea that neurons are not simply tuned to a single feature, but they encode several task-relevant variables at the same time [177]. In terms of invasiveness and accuracy, decoding multiple parameters from the same area could be advantageous for both BMI and neuroprosthetic applications [171, 177] by allowing a single electrode array to decode multiple action scenarios (Fig. 5).

## 6. Conclusions

We have summarized the anatomical subdivision, the cortical and thalamic connections of the macaque SPL, we have

compared their functional properties and summarized the organization of the human SPL in physiological and injured situations. Despite the methodological differences in the study of macaque and human brains, the results obtained over the years show independent and convergent evidence that the human and macaque brain as a whole are similar and similarly wired. In fact, starting from the consolidated models in the monkey and from the large amount of data collected over decades, and with the help of new high spatial resolution techniques (e.g., fMRI, diffusion tensor imaging, tractography) experimental models in human and non-human primates show a high level of comparability. This strengthens and underlines the importance of looking for homologies, as in the cases previously discussed, where the proposed homology with the monkey brain has guided the study of the organization of the human SPL.

The rich set of inputs reaching the SPL merge to serve different goals, involving the representation of space, grasping actions, and the use of the sensory information for goal-directed movements. Areas of the SPL elaborate also higher-level cognitive functions, like selective visual spatial attention. All these properties are building neuronal networks useful in the sensory-cognitive interplay, essential in the correct execution of reaching and grasping movements (Fig. 5). Moreover, the parallel between macaque and human SPL described here supports the view of an analogous functional organization, with a somatosensory-dominated anterior sector and a bimodal, visual-somatosensory caudal part, both contributing to vision-for-action and spatial functions. The suggested interspecies homology could address forthcoming research in humans and monkeys aimed to improve the knowledge about brain structure, function and disease, useful for clinical applications and novel therapies of nervous system diseases, or brain-machine interface technologies.

Neuronal circuitry of the areas of the SPL as described above, mediate sensory-motor transformations, encode the spatial coordinates for reaching goals, hand position and movements, and other spatial variables. The new challenges for the next decades of neuroscience and neuro-engineering research will be how to encode and better implement the different kinds of information processed by the SPL areas in brain-machine interfaces to control both goal-directed movements and cognitive functions and how to decode efficiently the neural signals to be used in order to move neural prostheses with the aim of regaining motor function in patients with motor disabilities.

## Abbreviations

### Macaque cortical areas:

1, Brodmann area 1; 2, Brodmann area 2; 3, Brodmann area 3; 4, Brodmann area 4; 6, Brodmann area 6; 8, Brodmann area 8; 23e, Area 23, external subdivision; 23a/b, Area 23 external and internal subdivision; 24a/b, Area 24 external and internal subdivision; 31, Area 31; 46, Brodmann area 46; AIP, Anterior intraparietal area; F2, Frontal area 2; F3, Frontal

area 3; F4, Frontal area 4; F7, Frontal area 7; LIP, Lateral intraparietal area; MIP, Medial intraparietal area; MST, Medial superior temporal area; PE, Area PE; PEa, Area PE anterior; PEc, Area PE caudal; PEci, Area PE cingulate portion; PEip, Area PE intraparietal portion; PG, Area PG; PGm, Area PG mesial; PGop, Area PG opercular; PO, Parieto occipital area; SII, Secondary somatosensory cortex; SPL, Superior parietal lobule; SSA, Supplementary Somatosensory Area; Tpt, Temporoparietal transition area; TSA, Transitional sensory area; V2, Area V2; V3, Area V3; V4, Area V4; V6, Area V6; V6Ad, Area V6A, dorsal portion; V6Av, Area V6A, ventral portion.

### Human cortical areas:

5Ci, Area 5, cingulate parietal; 5L, Area 5, lateral; 5M, Area 5, medial parietal; 7A, Area 7, anterior; 7M, Area 7, mesial; 7P, Area 7, posterior; 7PC, Area 7, postero-caudal; BA5, Brodmann area 5; BA7, Brodmann area 7; hPE, Human PE; hPEc, Human PEc; hV6, Human V6; hV6A, Human V6A; PBA, Parietal Body Area.

### Thalamic nuclei:

LP, Lateral posterior; PuM, Medial pulvinar; VA, Ventral anterior; VL, Ventral lateral; VPL, Ventral posterior lateral.

### Others:

BMIs, Brain-machine interfaces; DTT, Diffusion tensor tractography; fMRI, Functional magnetic resonance imaging; MRI, Magnetic resonance imaging; SLF, Superior longitudinal fasciculus; SLF/AF, Superior longitudinal fasciculus/arcuate fasciculus; TP, Temporo-parietal white matter connections.

## Author contributions

LP wrote the manuscript. LP, MG and PF contributed to editorial changes in the manuscript.

LP, MG and PF read and approved the final manuscript.

## Ethics approval and consent to participate

This article does not contain any new, previously unpublished study with human participants or animals performed by the authors.

## Acknowledgment

The manuscript benefited by the comments and suggestions of the editors and three anonymous reviewers that greatly improved this work.

## Funding

This work was supported by grants from Ministero dell'Università e della Ricerca (2017KZNLN), and Fondazione Cassa di Risparmio di Bologna (Bando Internazionalizzazione), Italy, and partially supported by the European Commission funded project, "HumanE AI Network - HumanE-AI-Net", Grant Agreement n. 952026, H2020-MSCA-734227-PLATYPUS, H2020-EIC-FETPROACT-2019-951910-MAIA. The support is gratefully acknowledged.

## Conflict of interest

The authors declare that they have no conflict of interest.

## References

- [1] Purves D, Brannon E, Cabeza R, Huettel S, LaBar K, Platt M, *et al.* Principles of Cognitive Neuroscience. 2009.
- [2] Galletti C, Fattori P. The dorsal visual stream revisited: stable circuits or dynamic pathways? *Cortex*. 2018; 98: 203-217.
- [3] Galletti C, Kutz DF, Gamberini M, Breveglieri R, Fattori P. Role of the medial parieto-occipital cortex in the control of reaching and grasping movements. *Experimental Brain Research*. 2003; 153: 158-170.
- [4] Goodale MA, Milner AD. Separate visual pathways for perception and action. *Trends in Cognitive Sciences* 1992; 15: 20-25.
- [5] Rizzolatti G, Matelli M. Two different streams form the dorsal visual system: anatomy and functions. *Experimental Brain Research*. 2003; 153: 146-157.
- [6] Caspers S, Zilles K. Chapter 3-Microarchitecture and connectivity of the parietal lobe. In: Vallar G, Coslett HBBT-H of CN, editors. *The Parietal Lobe* (pp. 53-72). Elsevier. 2018.
- [7] Scheperjans F, Hermann K, Eickhoff SB, Amunts K, Schleicher A, Zilles K. Observer-independent cytoarchitectonic mapping of the human superior parietal cortex. *Cerebral Cortex*. 2008; 18: 846-867.
- [8] Scheperjans F, Eickhoff SB, Homke L, Mohlberg H, Hermann K, Amunts K, *et al.* Probabilistic maps, morphometry, and variability of cytoarchitectonic areas in the human superior parietal cortex. *Cerebral Cortex*. 2008; 18: 2141-2157.
- [9] Pitzalis S, Sereno MI, Committeri G, Fattori P, Galati G, Tosoni A, *et al.* The human homologue of macaque area V6A. *NeuroImage*. 2013; 82: 517-530.
- [10] Pitzalis S, Serra C, Sulpizio V, Di Marco S, Fattori P, Galati G, *et al.* A putative human homologue of the macaque area PEc. *NeuroImage*. 2019; 202: 116092.
- [11] Pereira-Pedro AS, Bruner E. Sulcal pattern, extension, and morphology of the precuneus in adult humans. *Annals of Anatomy - Anatomischer Anzeiger*. 2016; 208: 85-93.
- [12] Gamberini M, Passarelli L, Fattori P, Galletti C. Structural connectivity and functional properties of the macaque superior parietal lobule. *Brain Structure and Function*. 2020; 225: 1349-1367.
- [13] Impieri D, Zilles K, Niu M, Rapan-Jankovic L, Schubert N, Galletti C, *et al.* Receptor density pattern confirms and enhances the anatomic-functional features of the macaque superior parietal lobule areas. *Brain Structure and Function*. 2019; 224: 2733-2756.
- [14] Galletti C, Fattori P, Battaglini PP, Shipp S, Zeki S, Battaglini PP, *et al.* Functional demarcation of a border between areas v6 and v6A in the superior parietal gyrus of the macaque monkey. *European Journal of Neuroscience*. 1996; 8: 30-52.
- [15] Galletti C, Fattori P, Kutz DF, Gamberini M. Brain location and visual topography of cortical area V6A in the macaque monkey. *European Journal of Neuroscience*. 1999; 11: 575-582.
- [16] Galletti C, Gamberini M, Kutz DF, Baldinotti I, Fattori P. The relationship between V6 and PO in macaque extrastriate cortex. *European Journal of Neuroscience*. 2005; 21: 959-970.
- [17] Luppino G, Hamed SB, Gamberini M, Matelli M, Galletti C. Occipital (V6) and parietal (V6A) areas in the anterior wall of the parieto-occipital sulcus of the macaque: a cytoarchitectonic study. *European Journal of Neuroscience*. 2005; 21: 3056-3076.
- [18] Passarelli L, Rosa MGP, Gamberini M, Bakola S, Burman KJ, Fattori P, *et al.* Cortical connections of area V6Av in the Macaque: a visual-input node to the eye/hand coordination system. *Journal of Neuroscience*. 2011; 31: 1790-1801.
- [19] Bakola S, Gamberini M, Passarelli L, Fattori P, Galletti C. Cortical connections of parietal field PEc in the macaque: linking vision and somatic sensation for the control of limb action. *Cerebral Cortex*. 2010; 20: 2592-2604.
- [20] Bakola S, Passarelli L, Huynh T, Impieri D, Worthy KH, Fattori P, *et al.* Cortical afferents and myeloarchitecture distinguish the medial intraparietal area (MIP) from neighboring subdivisions of the macaque cortex. *eNeuro*. 2017; 4: ENEURO.0344-17.
- [21] Fattori P, Gamberini M, Kutz DF, Galletti C. 'Arm-reaching' neurons in the parietal area V6A of the macaque monkey. *European Journal of Neuroscience*. 2001; 13: 2309-2313.
- [22] Fattori P, Kutz DF, Breveglieri R, Marzocchi N, Galletti C. Spatial tuning of reaching activity in the medial parieto-occipital cortex (area V6A) of macaque monkey. *European Journal of Neuroscience*. 2005; 22: 956-972.
- [23] Fattori P, Breveglieri R, Raos V, Bosco A, Galletti C. Vision for action in the macaque medial posterior parietal cortex. *Journal of Neuroscience*. 2012; 32: 3221-3234.
- [24] Gamberini M, Passarelli L, Fattori P, Zucchelli M, Bakola S, Luppino G, *et al.* Cortical connections of the visuomotor parietooccipital area V6Ad of the macaque monkey. *The Journal of Comparative Neurology*. 2009; 513: 622-642.
- [25] Pandya DN, Seltzer B. Intrinsic connections and architectonics of posterior parietal cortex in the rhesus monkey. *The Journal of Comparative Neurology*. 1982; 204: 196-210.
- [26] Cavada C, Goldman-Rakic PS. Posterior parietal cortex in rhesus monkey: II. Evidence for segregated corticocortical networks linking sensory and limbic areas with the frontal lobe. *The Journal of Comparative Neurology*. 1989; 287: 422-445.
- [27] Morecraft RJ, Cipolloni PB, Stilwell-Morecraft KS, Gedney MT, Pandya DN. Cytoarchitecture and cortical connections of the posterior cingulate and adjacent somatosensory fields in the rhesus monkey. *The Journal of Comparative Neurology*. 2004; 469: 37-69.
- [28] Passarelli L, Rosa MGP, Bakola S, Gamberini M, Worthy KH, Fattori P, *et al.* Uniformity and diversity of cortical projections to precuneate areas in the macaque monkey: what defines area PGm? *Cerebral Cortex*. 2018; 28: 1700-1717.
- [29] Duffy FH, Burchfiel JL. Somatosensory system: organizational hierarchy from single units in monkey area 5. *Science*. 1971; 172: 273-275.
- [30] Murray EA, Coulter JD. Supplementary Sensory Area. In: Woolsey CN, editor. *Cortical Sensory Organization: Volume 1: Multiple Somatic Areas* (pp. 167-195). Totowa, NJ: Humana Press. 1981.
- [31] Murray EA, Coulter JD. Organization of corticospinal neurons in the monkey. *The Journal of Comparative Neurology*. 1981; 195: 339-365.
- [32] Colby CL, Gattass R, Olson CR, Gross CG. Topographical organization of cortical afferents to extrastriate visual area PO in the macaque: a dual tracer study. *The Journal of Comparative Neurology*. 1988; 269: 392-413.
- [33] Colby CL, Duhamel JR. Heterogeneity of extrastriate visual areas and multiple parietal areas in the macaque monkey. *Neuropsychologia*. 1991; 29: 517-537.
- [34] Matelli M, Govoni P, Galletti C, Kutz DF, Luppino G. Superior area 6 afferents from the superior parietal lobule in the macaque monkey. *The Journal of Comparative Neurology*. 1998; 402: 327-352.
- [35] Lewis JW, Van Essen DC. Mapping of architectonic subdivisions in the macaque monkey, with emphasis on parieto-occipital cortex. *The Journal of Comparative Neurology*. 2000; 428: 79-111.
- [36] Seelke AMH, Padberg JJ, Disbrow E, Purnell SM, Recanzone G, Krubitzer L. Topographic maps within Brodmann's area 5 of macaque monkeys. *Cerebral Cortex*. 2012; 22: 1834-1850.
- [37] Rathelot J, Dum RP, Strick PL. Posterior parietal cortex contains a command apparatus for hand movements. *Proceedings of the National Academy of Sciences*. 2017; 114: 4255-4260.
- [38] Gardner EP, Babu KS, Reitzen SD, Ghosh S, Brown AS, Chen J, *et al.* Neurophysiology of prehension. I. Posterior parietal cortex and object-oriented hand behaviors. *Journal of Neurophysiology*. 2007; 97: 387-406.
- [39] Baumann MA, Fluet M-, Scherberger H. Context-specific grasp movement representation in the macaque anterior intraparietal area. *Journal of Neuroscience*. 2009; 29: 6436-6448.

- [40] Evangeliou MN, Raos V, Galletti C, Savaki HE. Functional imaging of the parietal cortex during action execution and observation. *Cerebral Cortex*. 2009; 19: 624-639.
- [41] Nelissen K, Vanduffel W. Grasping-related functional magnetic resonance imaging brain responses in the macaque monkey. *Journal of Neuroscience*. 2011; 31: 8220-8229.
- [42] Bakola S, Passarelli L, Gamberini M, Fattori P, Galletti C. Cortical connectivity suggests a role in limb coordination for macaque area PE of the superior parietal cortex. *Journal of Neuroscience*. 2013; 33: 6648-6658.
- [43] Gamberini M, Bakola S, Passarelli L, Burman KJ, Rosa MGP, Fattori P, *et al.* Thalamic projections to visual and visuomotor areas (V6 and V6A) in the Rostral Bank of the parieto-occipital sulcus of the Macaque. *Brain Structure and Function*. 2016; 221: 1573-1589.
- [44] Gamberini M, Galletti C, Bosco A, Breveglieri R, Fattori P. Is the medial posterior parietal area V6A a single functional area? *Journal of Neuroscience*. 2011; 31: 5145-5157.
- [45] Gamberini M, Passarelli L, Impieri D, Worthy KH, Burman KJ, Fattori P, *et al.* Thalamic afferents emphasize the different functions of macaque precuneate areas. *Brain Structure and Function*. 2020; 225: 853-870.
- [46] Impieri D, Gamberini M, Passarelli L, Rosa MGP, Galletti C. Thalamo-cortical projections to the macaque superior parietal lobule areas PEc and PE. *Journal of Comparative Neurology*. 2018; 526: 1041-1056.
- [47] Yeterian EH, Pandya DN. Corticothalamic connections of the posterior parietal cortex in the rhesus monkey. *The Journal of Comparative Neurology*. 1985; 237: 408-426.
- [48] Schmahmann JD, Pandya DN. Anatomical investigation of projections from thalamus to posterior parietal cortex in the rhesus monkey: a WGA-HRP and fluorescent tracer study. *The Journal of Comparative Neurology*. 1990; 295: 299-326.
- [49] Yeterian EH, Pandya DN. Corticothalamic connections of extrastriate visual areas in rhesus monkeys. *The Journal of Comparative Neurology*. 1997; 378: 562-585.
- [50] Gharbawie OA, Stepniewska I, Burish MJ, Kaas JH. Thalamocortical connections of functional zones in posterior parietal cortex and frontal cortex motor regions in new world monkeys. *Cerebral Cortex*. 2010; 20: 2391-2410.
- [51] Grieve KL, Acuña C, Cudeiro J. The primate pulvinar nuclei: vision and action. *Trends in Neurosciences*. 2000; 23: 35-39.
- [52] Ilinsky IA, Kultas-Ilinsky K. Sagittal cytoarchitectonic maps of the Macaca mulatta thalamus with a revised nomenclature of the motor-related nuclei validated by observations on their connectivity. *The Journal of Comparative Neurology*. 1987; 262: 331-364.
- [53] Watanabe Y, Funahashi S. Neuronal activity throughout the primate mediodorsal nucleus of the thalamus during oculomotor delayed-responses. I. Cue-, delay-, and response-period activity. *Journal of Neurophysiology*. 2004; 92: 1738-1755.
- [54] Mountcastle VB, Lynch JC, Georgopoulos A, Sakata H, Acuna C. Posterior parietal association cortex of the monkey: command functions for operations within extrapersonal space. *Journal of Neurophysiology*. 1975; 38: 871-908.
- [55] Burbaud P, Doegle C, Gross C, Bioulac B. A quantitative study of neuronal discharge in areas 5, 2, and 4 of the monkey during fast arm movements. *Journal of Neurophysiology*. 1991; 66: 429-443.
- [56] Breveglieri R, Galletti C, Gamberini M, Passarelli L, Fattori P. Somatosensory cells in area PEc of Macaque Posterior Parietal cortex. *Journal of Neuroscience*. 2006; 26: 3679-3684.
- [57] Breveglieri R, Galletti C, Monaco S, Fattori P. Visual, somatosensory, and bimodal activities in the macaque parietal area PEc. *Cerebral Cortex*. 2008; 18: 806-816.
- [58] Padberg J, Franca JG, Cooke DF, Soares JGM, Rosa MGP, Fiorani M, *et al.* Parallel evolution of cortical areas involved in skilled hand use. *Journal of Neuroscience*. 2007; 27: 10106-10115.
- [59] Krubitzer L, Disbrow E. The evolution of parietal areas involved in hand use in primates. *The senses: a comprehensive reference* (pp. 183-214). Elsevier Inc.. 2008.
- [60] Bremner LR, Andersen RA. Coding of the reach vector in parietal area 5d. *Neuron*. 2012; 75: 342-351.
- [61] Ferraina S, Bianchi L. Posterior parietal cortex: functional properties of neurons in area 5 during an instructed-delay reaching task within different parts of space. *Experimental Brain Research*. 1994; 99: 175-178.
- [62] Ferraina S, Garasto MR, Battaglia-Mayer A, Ferraresi P, Johnson PB, Lacquaniti F, *et al.* Visual control of hand-reaching movement: activity in parietal area 7m. *European Journal of Neuroscience*. 1997; 9: 1090-1095.
- [63] Lacquaniti F, Guigon E, Bianchi L, Ferraina S, Caminiti R. Representing spatial information for limb movement: role of area 5 in the monkey. *Cerebral Cortex*. 1995; 5: 391-409.
- [64] Kalaska JF. Parietal cortex area 5 and visuomotor behavior. *Canadian Journal of Physiology and Pharmacology*. 1996; 74: 483-498.
- [65] Ferraina S, Brunamonti E, Giusti MA, Costa S, Genovesio A, Caminiti R. Reaching in depth: hand position dominates over binocular eye position in the rostral superior parietal lobule. *Journal of Neuroscience*. 2009; 29: 11461-11470.
- [66] Aggleton JP, Nelson AJD. Why do lesions in the rodent anterior thalamic nuclei cause such severe spatial deficits? *Neuroscience & Biobehavioral Reviews*. 2015; 54: 131-144.
- [67] Cappe C, Morel A, Rouiller EM. Thalamocortical and the dual pattern of corticothalamic projections of the posterior parietal cortex in macaque monkeys. *Neuroscience*. 2007; 146: 1371-1387.
- [68] Battaglia-Mayer A, Ferraina S, Genovesio A, Marconi B, Squatrito S, Molinari M, *et al.* Eye-hand coordination during reaching. II. An analysis of the relationships between visuomanual signals in parietal cortex and parieto-frontal association projections. *Cerebral Cortex*. 2001; 11: 528-544.
- [69] Hadjimitsakis K, Dal Bo' G, Breveglieri R, Galletti C, Fattori P. Overlapping representations for reach depth and direction in caudal superior parietal lobule of macaques. *Journal of Neurophysiology*. 2015; 114: 2340-2352.
- [70] Hadjimitsakis K, Bakola S, Wong YT, Hagan MA. Mixed spatial and movement representations in the primate posterior parietal cortex. *Frontiers in Neural Circuits*. 2019; 13: 15.
- [71] Hadjimitsakis K, Ghodrati M, Breveglieri R, Rosa MGP, Fattori P. Neural coding of action in three dimensions: task- and time-invariant reference frames for visuospatial and motor-related activity in parietal area V6A. *The Journal of Comparative Neurology*. 2020; 528: 3108-3122.
- [72] Andersen RA, Kellis S, Klaes C, Aflalo T. Toward more versatile and intuitive cortical brain-machine interfaces. *Current Biology*. 2014; 24: R885-R897.
- [73] Acuña C, Cudeiro J, Gonzalez F. Lateral-posterior (LP) and pulvinar unit activity related to intentional upper limb movements directed to spatially separated targets, in behaving Macaca nemestrina monkeys. *Revue Neurologique*. 1986; 142: 354-361.
- [74] Acuña C, Cudeiro J, Gonzalez F, Alonso JM, Perez R. Lateral-posterior and pulvinar reaching cells—comparison with parietal area 5a: a study in behaving Macaca nemestrina monkeys. *Experimental Brain Research*. 1990; 82: 158-166.
- [75] Cudeiro J, Gonzalez F, Pérez R, Alonso JM, Acuña C. Does the pulvinar-LP complex contribute to motor programming? *Brain Research*. 1989; 484: 367-370.
- [76] Kamishina H, Yurcisin GH, Corwin JV, Reep RL. Striatal projections from the rat lateral posterior thalamic nucleus. *Brain Research*. 2008; 1204: 24-39.
- [77] Kamishina H, Conte WL, Patel SS, Tai RJ, Corwin JV, Reep RL. Cortical connections of the rat lateral posterior thalamic nucleus. *Brain Research*. 2009; 1264: 39-56.
- [78] Homman-Ludiye J, Bourne JA. The medial pulvinar: function, origin and association with neurodevelopmental disorders. *Journal of Anatomy*. 2019; 235: 507-520.
- [79] Shipp S. The functional logic of cortico-pulvinar connections. *Philosophical Transactions of the Royal Society of London. Series B: Biological Sciences*. 2003; 358: 1605-1624.



- [80] Saalmann YB, Pinsk MA, Wang L, Li X, Kastner S. The pulvinar regulates information transmission between cortical areas based on attention demands. *Science*. 2012; 337: 753-756.
- [81] Leinonen L, Hyvärinen J, Nyman G, Linnankoski I. I. Functional properties of neurons in lateral part of associative area 7 in awake monkeys. *Experimental Brain Research*. 1979; 34: 299-320.
- [82] Hyvärinen J. Posterior parietal lobe of the primate brain. *Physiological Reviews*. 1982; 62: 1060-1129.
- [83] Andersen RA, Snyder LH, Bradley DC, Xing J. Multimodal representation of space in the posterior parietal cortex and its use in planning movements. *Annual Review of Neuroscience*. 1997; 20: 303-330.
- [84] Gottlieb J. From thought to action: the parietal cortex as a bridge between perception, action, and cognition. *Neuron*. 2007; 53: 9-16.
- [85] Filimon F. Human cortical control of hand movements: parietofrontal networks for reaching, grasping, and pointing. *The Neuroscientist*. 2010; 16: 388-407.
- [86] Sereno MI, Huang R. Multisensory maps in parietal cortex. *Current Opinion in Neurobiology*. 2014; 24: 39-46.
- [87] Pisella L. Visual perception is dependent on visuospatial working memory and thus on the posterior parietal cortex. *Annals of Physical and Rehabilitation Medicine*. 2017; 60: 141-147.
- [88] Galletti C, Breveglieri R, Lappe M, Bosco A, Ciavarro M, Fattori P. Covert shift of attention modulates the ongoing neural activity in a reaching area of the macaque dorsomedial visual stream. *PLoS ONE*. 2010; 5: e15078.
- [89] Caminiti R, Innocenti GM, Battaglia-Mayer A. Organization and evolution of parieto-frontal processing streams in macaque monkeys and humans. *Neuroscience & Biobehavioral Reviews*. 2015; 56: 73-96.
- [90] Galletti C, Fattori P, Kutz DF, Battaglini PP. Arm Movement-related Neurons in the Visual Area V6A of the macaque superior parietal lobule. *European Journal of Neuroscience*. 1997; 9: 410-413.
- [91] Fattori P, Breveglieri R, Marzocchi N, Filippini D, Bosco A, Galletti C. Hand orientation during reach-to-grasp movements modulates neuronal activity in the medial posterior parietal area V6A. *Journal of Neuroscience*. 2009; 29: 1928-1936.
- [92] Andersen RA, Cui H. Intention, action planning, and decision making in parietal-frontal circuits. *Neuron*. 2009; 63: 568-583.
- [93] Fattori P, Breveglieri R, Amoroso K, Galletti C. Evidence for both reaching and grasping activity in the medial parieto-occipital cortex of the macaque. *European Journal of Neuroscience*. 2004; 20: 2457-2466.
- [94] Fattori P, Breveglieri R, Bosco A, Gamberini M, Galletti C. Vision for prehension in the medial parietal cortex. *Cerebral Cortex*. 2017; 27: 1149-1163.
- [95] Battaglia-Mayer A, Ferraina S, Mitsuda T, Marconi B, Genovesio A, Onorati P, *et al*. Early coding of reaching in the parietooccipital cortex. *Journal of Neurophysiology*. 2000; 83: 2374-2391.
- [96] Batista AP, Andersen RA. The parietal reach region codes the next planned movement in a sequential reach task. *Journal of Neurophysiology*. 2001; 85: 539-544.
- [97] Kalaska JF, Scott SH, Cisek P, Sergio LE. Cortical control of reaching movements. *Current Opinion in Neurobiology*. 1997; 7: 849-859.
- [98] Scheperjans F, Palomero-Gallagher N, Grefkes C, Schleicher A, Zilles K. Transmitter receptors reveal segregation of cortical areas in the human superior parietal cortex: relations to visual and somatosensory regions. *NeuroImage*. 2005; 28: 362-379.
- [99] Scheperjans F, Grefkes C, Palomero-Gallagher N, Schleicher A, Zilles K. Subdivisions of human parietal area 5 revealed by quantitative receptor autoradiography: a parietal region between motor, somatosensory, and cingulate cortical areas. *NeuroImage*. 2005; 25: 975-992.
- [100] Brodmann K. Vergleichende Lokalisationslehre der Grosshirnrinde in ihren Prinzipien dargestellt auf Grund des Zellenbaues. Leipzig, Bart. 1909. (In German)
- [101] Schmahmann JD, Smith EE, Eichler FS, Filley CM. Cerebral white matter. *Annals of the New York Academy of Sciences*. 2008; 1142: 266-309.
- [102] Mesulam M. From sensation to cognition. *Brain*. 1998; 121: 1013-1052.
- [103] Petrides M, Pandya DN. Comparative cytoarchitectonic analysis of the human and the macaque ventrolateral prefrontal cortex and corticocortical connection patterns in the monkey. *European Journal of Neuroscience*. 2002; 16: 291-310.
- [104] Makris N, Pandya DN. The extreme capsule in humans and rethinking of the language circuitry. *Brain Structure and Function*. 2009; 213: 343-358.
- [105] Schmahmann JD, Pandya DN, Wang R, Dai G, D'Arceuil HE, de Crespigny AJ, *et al*. Association fibre pathways of the brain: parallel observations from diffusion spectrum imaging and autoradiography. *Brain*. 2007; 130: 630-653.
- [106] Bernal B, Altman N. The connectivity of the superior longitudinal fasciculus: a tractography DTI study. *Magnetic Resonance Imaging*. 2010; 28: 217-225.
- [107] Koch G, Cercignani M, Pecchioli C, Versace V, Oliveri M, Caltagirone C, *et al*. *In vivo* definition of parieto-motor connections involved in planning of grasping movements. *NeuroImage*. 2010; 51: 300-312.
- [108] Petrides M, Pandya DN. Projections to the frontal cortex from the posterior parietal region in the rhesus monkey. *The Journal of Comparative Neurology*. 1984; 228: 105-116.
- [109] Seltzer B, Pandya DN. Further observations on parieto-temporal connections in the rhesus monkey. *Experimental Brain Research*. 1984; 55: 301-312.
- [110] Borra E, Belmalih A, Calzavara R, Gerbella M, Murata A, Rozzi S, *et al*. Cortical connections of the macaque anterior intraparietal (AIP) area. *Cerebral Cortex*. 2008; 18: 1094-1111.
- [111] Luppino G, Murata A, Govoni P, Matelli M. Largely segregated parietofrontal connections linking rostral intraparietal cortex (areas AIP and VIP) and the ventral premotor cortex (areas F5 and F4). *Experimental Brain Research*. 1999; 128: 181-187.
- [112] Rozzi S, Calzavara R, Belmalih A, Borra E, Gregoriou GG, Matelli M, *et al*. Cortical connections of the inferior parietal cortical convexity of the macaque monkey. *Cerebral Cortex*. 2006; 16: 1389-1417.
- [113] Haines DE. *Neuroanatomy: an atlas of structures, sections, and systems*. Lippincott: Williams & Wilkins. 2004.
- [114] Kamali A, Flanders AE, Brody J, Hunter JV, Hasan KM. Tracing superior longitudinal fasciculus connectivity in the human brain using high resolution diffusion tensor tractography. *Brain Structure and Function*. 2014; 219: 269-281.
- [115] Behrens TEJ, Johansen-Berg H, Woolrich MW, Smith SM, Wheeler-Kingshott CAM, Boulby PA, *et al*. Non-invasive mapping of connections between human thalamus and cortex using diffusion imaging. *Nature Neuroscience*. 2003; 6: 750-757.
- [116] Traynor C, Heckemann RA, Hammers A, O'Muircheartaigh J, Crum WR, Barker GJ, *et al*. Reproducibility of thalamic segmentation based on probabilistic tractography. *NeuroImage*. 2010; 52: 69-85.
- [117] Arcaro MJ, Pinsk MA, Kastner S. The anatomical and functional organization of the human visual pulvinar. *The Journal of Neuroscience*. 2015; 35: 9848-9871.
- [118] Bridge H, Leopold DA, Bourne JA. Adaptive pulvinar circuitry supports visual cognition. *Trends in Cognitive Sciences*. 2016; 20: 146-157.
- [119] Huang R, Sereno MI. Multisensory and sensorimotor maps. *Handbook of Clinical Neurology*. 2018; 151: 141-161.
- [120] Huang RS, Chen CF, Tran AT, Holstein KL, Sereno MI. Mapping multisensory parietal face and body areas in humans. *Proceedings of the National Academy of Sciences*. 2012; 109: 18114-18119.
- [121] Pitzalis S, Galletti C, Huang R-, Patria F, Comitteri G, Galati G, *et al*. Wide-field retinotopy defines human cortical visual area V6. *Journal of Neuroscience*. 2006; 26: 7962-7973.

- [122] Tosoni A, Pitzalis S, Committeri G, Fattori P, Galletti C, Galati G. Resting-state connectivity and functional specialization in human medial parieto-occipital cortex. *Brain Structure and Function*. 2015; 220: 3307-3321.
- [123] Pitzalis S, Sdoia S, Bultrini A, Committeri G, Di Russo F, Fattori P, *et al*. Selectivity to translational egomotion in human brain motion areas. *PLoS ONE*. 2013; 8: e60241.
- [124] Simon O, Mangin J, Cohen L, Le Bihan D, Dehaene S. Topographical layout of hand, eye, calculation, and language-related areas in the human parietal lobe. *Neuron*. 2002; 33: 475-487.
- [125] Astafiev SV, Shulman GL, Stanley CM, Snyder AZ, Van Essen DC, Corbetta M. Functional organization of human intraparietal and frontal cortex for attending, looking, and pointing. *The Journal of Neuroscience*. 2003; 23: 4689-4699.
- [126] Connolly JD, Andersen RA, Goodale MA. FMRI evidence for a 'parietal reach region' in the human brain. *Experimental Brain Research*. 2003; 153: 140-145.
- [127] Tosoni A, Galati G, Romani GL, Corbetta M. Sensory-motor mechanisms in human parietal cortex underlie arbitrary visual decisions. *Nature Neuroscience*. 2008; 11: 1446-1453.
- [128] Beurze SM, de Lange FP, Toni I, Medendorp WP. Integration of target and effector information in the human brain during reach planning. *Journal of Neurophysiology*. 2007; 97: 188-199.
- [129] Beurze SM, de Lange FP, Toni I, Medendorp WP. Spatial and effector processing in the human parietofrontal network for reaches and saccades. *Journal of Neurophysiology*. 2009; 101: 3053-3062.
- [130] Vesia M, Prime SL, Yan X, Sergio LE, Crawford JD. Specificity of human parietal saccade and reach regions during transcranial magnetic stimulation. *Journal of Neuroscience*. 2010; 30: 13053-13065.
- [131] Gallivan JP, McLean DA, Valyear KF, Pettepiece CE, Culham JC. Decoding action intentions from preparatory brain activity in human parieto-frontal networks. *Journal of Neuroscience*. 2011; 31: 9599-9610.
- [132] Konen CS, Mruczek REB, Montoya JL, Kastner S. Functional organization of human posterior parietal cortex: grasping- and reaching-related activations relative to topographically organized cortex. *Journal of Neurophysiology*. 2013; 109: 2897-2908.
- [133] Filimon F, Nelson JD, Huang R-, Sereno MI. Multiple parietal reach regions in humans: cortical representations for visual and proprioceptive feedback during on-line reaching. *Journal of Neuroscience*. 2009; 29: 2961-2971.
- [134] Cavina-Pratesi C, Monaco S, Fattori P, Galletti C, McAdam TD, Quinlan DJ, *et al*. Functional magnetic resonance imaging reveals the neural substrates of arm transport and grip formation in reach-to-grasp actions in humans. *Journal of Neuroscience*. 2010; 30: 10306-10323.
- [135] Galati G, Committeri G, Pitzalis S, Pelle G, Patria F, Fattori P, *et al*. Intentional signals during saccadic and reaching delays in the human posterior parietal cortex. *European Journal of Neuroscience*. 2011; 34: 1871-1885.
- [136] Gamberini M, Dal Bò G, Breveglieri R, Briganti S, Passarelli L, Fattori P, *et al*. Sensory properties of the caudal aspect of the macaque superior parietal lobule. *Journal of Neuroscience*. 2018; 223: 1863-1879.
- [137] Zgaljardic DJ, Yancy S, Levinson J, Morales G, Masel BE. Balint's syndrome and post-acute brain injury rehabilitation: a case report. *Brain Injury*. 2011; 25: 909-917.
- [138] Dalrymple KA, Bischof WF, Cameron D, Barton JJS, Kingstone A. Simulating simultanagnosia: spatially constricted vision mimics local capture and the global processing deficit. *Experimental Brain Research*. 2010; 202: 445-455.
- [139] Jackson GM, Shepherd T, Mueller SC, Husain M, Jackson SR. Dorsal simultanagnosia: an impairment of visual processing or visual awareness? *Cortex*. 2006; 42: 740-749.
- [140] Perenin M, Vighetto A. Optic ataxia: a specific disruption in visuomotor mechanisms. *Brain*. 1988; 111: 643-674.
- [141] Pisella L, Gréa H, Tilikete C, Vighetto A, Desmurget M, Rode G, *et al*. An 'automatic pilot' for the hand in human posterior parietal cortex: toward reinterpreting optic ataxia. *Nature Neuroscience*. 2000; 3: 729-736.
- [142] Pisella L, Michel C, Gréa H, Tilikete C, Vighetto A, Rossetti Y. Preserved prism adaptation in bilateral optic ataxia: strategic versus adaptive reaction to prisms. *Experimental Brain Research*. 2004; 156: 399-408.
- [143] Karnath H, Perenin M. Cortical control of visually guided reaching: evidence from patients with optic ataxia. *Cerebral Cortex*. 2005; 15: 1561-1569.
- [144] Khan AZ, Pisella L, Vighetto A, Cotton F, Luauté J, Boisson D, *et al*. Optic ataxia errors depend on remapped, not viewed, target location. *Nature Neuroscience*. 2005; 8: 418-420.
- [145] Garcin R, Rondot P, de Recondo J. Optic ataxia localized in 2 left homonymous visual hemifields (clinical study with film presentation). *Revue Neurologique*. 1967; 116: 707-714. (In French)
- [146] Martin JA, Karnath H, Himmelbach M. Revisiting the cortical system for peripheral reaching at the parieto-occipital junction. *Cortex*. 2015; 64: 363-379.
- [147] Khan AZ, Crawford JD, Blohm G, Urquizar C, Rossetti Y, Pisella L. Influence of initial hand and target position on reach errors in optic ataxic and normal subjects. *Journal of Vision*. 2007; 7: 8.1-816.
- [148] Blangero A, Gaveau V, Luauté J, Rode G, Salemme R, Guinard M, *et al*. A hand and a field effect in on-line motor control in unilateral optic ataxia. *Cortex*. 2008; 44: 560-568.
- [149] Jeannerod M. Mechanisms of visuomotor coordination: a study in normal and brain-damaged subjects. *Neuropsychologia*. 1986; 24: 41-78.
- [150] Jakobson LS, Archibald YM, Carey DP, Goodale MA. A kinematic analysis of reaching and grasping movements in a patient recovering from optic ataxia. *Neuropsychologia*. 1991; 29: 803-809.
- [151] Buxbaum LJ, Coslett HB. Subtypes of optic ataxia: reframing the disconnection account. *Neurocase*. 1997; 3: 159-166.
- [152] Battaglini PP, Muzur A, Galletti C, Skrap M, Brovelli A, Fattori P. Effects of lesions to area V6A in monkeys. *Experimental Brain Research*. 2002; 144: 419-422.
- [153] Battaglia-Mayer A, Ferrari-Toniolo S, Visco-Comandini F, Archambault PS, Saberi-Moghadam S, Caminiti R. Impairment of online control of hand and eye movements in a monkey model of optic ataxia. *Cerebral Cortex*. 2013; 23: 2644-2656.
- [154] Kubota S, Yamada M, Satoh H, Satoh A, Tsujihata M. Pure Amorphagnosia without tactile object agnosia. *Case Reports in Neurology*. 2017; 9: 62-68.
- [155] Binkofski F, Kunesch E, Classen J, Seitz RJ, Freund HJ. Tactile apraxia. *Brain*. 2001; 124: 132-144.
- [156] Wilke M, Turchi J, Smith K, Mishkin M, Leopold DA. Pulvinar inactivation disrupts selection of movement plans. *Journal of Neuroscience*. 2010; 30: 8650-8659.
- [157] Wilke M, Schneider L, Dominguez-Vargas A-U, Schmidt-Samoa C, Miloserdov K, Nazzari A, *et al*. Reach and grasp deficits following damage to the dorsal pulvinar. *Cortex*. 2018; 99: 135-149.
- [158] Kiorpes L. Understanding the development of amblyopia using macaque monkey models. *Proceedings of the National Academy of Sciences*. 2019; 116: 26217-26223.
- [159] Maeda K, Ishida H, Nakajima K, Inase M, Murata A. Functional properties of parietal hand manipulation-related neurons and mirror neurons responding to vision of own hand action. *Journal of Cognitive Neuroscience*. 2015; 27: 560-572.
- [160] Clavagnier S, Prado J, Kennedy H, Perenin M-T. How humans reach: distinct cortical systems for central and peripheral vision. *The Neuroscientist*. 2007; 13: 22-27.
- [161] Krucoff MO, Rahimpour S, Sutzky MW, Edgerton VR, Turner DA. Enhancing nervous system recovery through neurobiologics, neural interface training, and neurorehabilitation. *Frontiers in Neuroscience*. 2016; 10: 584.
- [162] Velliste M, Perel S, Spalding MC, Whitford AS, Schwartz AB. Cortical control of a prosthetic arm for self-feeding. *Nature*. 2008; 453: 1098-1101.

- [163] Wessberg J, Stambaugh CR, Kralik JD, Beck PD, Laubach M, Chapin JK, *et al.* Real-time prediction of hand trajectory by ensembles of cortical neurons in primates. *Nature*. 2000; 408: 361-365.
- [164] Collinger JL, Wodlinger B, Downey JE, Wang W, Tyler-Kabara EC, Weber DJ, *et al.* High-performance neuroprosthetic control by an individual with tetraplegia. *The Lancet*. 2013; 381: 557-564.
- [165] Hochberg LR, Bacher D, Jarosiewicz B, Masse NY, Simeral JD, Vogel J, *et al.* Reach and grasp by people with tetraplegia using a neurally controlled robotic arm. *Nature*. 2012; 485: 372-375.
- [166] Musallam S. Cognitive control signals for neural prosthetics. *Science*. 2004; 305: 258-262.
- [167] Serruya M, Fellows M, Paninski L, Donoghue J, Hatsopoulos N. Robustness of neuroprosthetic decoding algorithms. *Biological Cybernetics*. 2003; 88: 219-228.
- [168] Mulliken GH, Musallam S, Andersen RA. Decoding trajectories from posterior parietal cortex ensembles. *Journal of Neuroscience*. 2008; 28: 12913-12926.
- [169] Schaffelhofer S, Agudelo-Toro A, Scherberger H. Decoding a wide range of hand configurations from macaque motor, premotor, and parietal cortices. *Journal of Neuroscience*. 2015; 35: 1068-1081.
- [170] Aflalo T, Kellis S, Klaes C, Lee B, Shi Y, Pejsa K, *et al.* Decoding motor imagery from the posterior parietal cortex of a tetraplegic human. *Science*. 2015; 348: 906-910.
- [171] Filippini M, Breveglieri R, Akhras MA, Bosco A, Chinellato E, Fattori P. Decoding information for grasping from the macaque dorsomedial visual stream. *The Journal of Neuroscience*. 2017; 37: 4311-4322.
- [172] Filippini M, Breveglieri R, Hadjidimitrakis K, Bosco A, Fattori P. Prediction of reach goals in depth and direction from the parietal cortex. *Cell Reports*. 2018; 23: 725-732.
- [173] Filippini M, Morris AP, Breveglieri R, Hadjidimitrakis K, Fattori P. Decoding of standard and non-standard visuomotor associations from parietal cortex. *Journal of Neural Engineering*. 2020; 17: 46027.
- [174] Hayhoe MM, Shrivastava A, Mruczek R, Pelz JB. Visual memory and motor planning in a natural task. *Journal of Vision*. 2003; 3: 49-63.
- [175] Neggers SF, Bekkering H. Gaze anchoring to a pointing target is present during the entire pointing movement and is driven by a non-visual signal. *Journal of Neurophysiology*. 2001; 86: 961-970.
- [176] Bosco A, Breveglieri R, Hadjidimitrakis K, Galletti C, Fattori P. Reference frames for reaching when decoupling eye and target position in depth and direction. *Scientific Reports*. 2016; 6: 21646.
- [177] Diomedes S, Vaccari FE, Filippini M, Fattori P, Galletti C. Mixed selectivity in macaque medial parietal cortex during eye-hand reaching. *iScience*. 2020; 23: 101616.