

Enucleation of a multilocular odontogenic keratocyst using sagittal osteotomy: A case report

Ugo Consolo^a, Sara Tognacci^{b,*}, Carlo Barausse^b, Attilio Carlo Salgarelli^c, Pierantonio Bellini^d

^a Head of Surgical, Medical and Dental Department of Morphological Sciences related to Transplant, Oncology and Regenerative Medicine, Director of Postgraduate School of Oral Surgery, University of Modena and Reggio Emilia, Modena, Italy

^b Resident in Postgraduate School of Oral Surgery, University of Modena and Reggio Emilia, Modena, Italy

^c Head of Maxillofacial Unit, Hospital "Carlo Poma", Mantova, Italy

^d Professor of Postgraduate School of Oral Surgery, University of Modena and Reggio Emilia, Modena, Italy

ARTICLE INFO

Keywords:

Odontogenic cyst
Keratocyst
Marsupialization
Conservative treatment
Sagittal osteotomy
Lateral corticotomy

ABSTRACT

Odontogenic keratocysts are significant cysts of the jaw that are characterized by aggressive behavior and a high tendency to recur. The treatments of choice may be radical or conservative, and in the literature a debate is still open about the gold standard in the treatment of OKCs. This report describes a wide multilocular OKC extended in the right mandibular ramus and illustrates atypical behavior of a cystic lobe after marsupialization, not found to our knowledge in the previous literature. Moreover, an orthognathic procedure, consisting of sagittal osteotomy was chosen for the excision of the cyst to preserve as much bone as possible and the integrity of the inferior alveolar nerve.

1. Introduction

Odontogenic keratocysts are significant cysts of the jaw that are characterized by aggressive behavior and a high tendency to recur [1]. Odontogenic keratocysts are histologically divided into two sub-types: those that are orthokeratinized (OOCs), considered the less aggressive variant, and those that are parakeratinized (OKCs), which are more aggressive and correlated with a higher incidence of recurrences (compared to OOCs) [2].

Diagnosis is often delayed because of silent symptomatology, so OKCs are frequently discovered as high-volume lesions involving different anatomic structures; consequently, a three-dimensional presurgical study of the lesion is mandatory [3,4].

The treatments of choice may be radical or conservative, and in the literature a debate is still open about the gold standard in the treatment of OKCs. Radical approaches include resection (marginal or en bloc). Conservative treatments include simple cyst excision or marsupialization/decompression, which can be followed by a second surgery. Although conservative approaches allow for minimally invasive surgery with a low rate of post-surgical discomfort, radical treatments are correlated with a lower rate of recurrence. Nevertheless, this kind of treatment often results in aesthetic and functional deficits [5].

This report describes a wide multilocular OKC extended in the right mandibular ramus and illustrates atypical behavior of a cystic lobe after marsupialization, not found to our knowledge in the previous literature. In addition, the surgical approach was chosen to

* Corresponding author. Policlinico di Modena-Azienda Ospedaliera-Universitaria di Modena Largo del Pozzo, 71, 41125, Modena, MO, Italy.

E-mail addresses: ugo.consolo@unimore.it (U. Consolo), sara.tognacci@unimore.it (S. Tognacci), carlo.barausse@studio.unibo.it (C. Barausse), attiliocarlosalgarelli@asst-mantova.it (A. Carlo Salgarelli), pierantonio.bellini@unimore.it (P. Bellini).

<https://doi.org/10.1016/j.omsc.2020.100154>

Received 3 April 2020; Received in revised form 30 April 2020; Accepted 6 May 2020

Available online 8 May 2020

2214-5419/© 2020 Published by Elsevier Inc. This is an open access article under the CC BY-NC-ND license

(<http://creativecommons.org/licenses/by-nc-nd/4.0/>).

preserve as much bone as possible and the integrity of the inferior alveolar nerve (IAN).

2. Presentation of the case

A 27-year-old man was referred to our operative division by his private dentist because of an osteolytic lesion found incidentally during routine panoramic radiography (OPT). The patient was in good health and didn't report any symptoms. The panoramic radiograph showed a wide multilocular radiolucent lesion extended in the left ramus, and the body of the mandible was associated with an impacted 4.8.

Cone beam computed tomography (CBCT) was requested, which revealed a wide multilocular lesion, composed of four lobes. Axial scans revealed the expansion and thinning of the cortical bone on the lingual side, which in some areas appeared discontinuous. In addition, this osteolytic lesion compressed and displaced the canal of the IAN (Fig. 1A).

A hypothetical diagnosis of OKC or ameloblastoma was formulated based on radiographic features, so a first surgery was planned. Hence, the patient underwent marsupialization of the lesion and extraction of the 4.8. In particular, a lateral corticotomy was performed as described by Alling and Alling [6]. Moreover, a portion of the cystic wall was removed and sent for histological analysis. The bone portion was then replaced and fixed with an osteosynthesis plate and screws. The flap was sutured, leaving a large opening in the oral cavity. The lesion was filled with a gauze soaked with gentamycin (Fig. 2). The pathological result revealed that the lesion was an OKC.

After marsupialization, a control CBCT was performed at 3 and 8 months in which a periosteal reaction along the posterior and lateral outline of the mandibular ramus was noted, with signs of bone deposition and progressive reduction in lesion volume (Fig. 1B).

The follow-up continued until a CBCT, performed at 20 months after the marsupialization, revealed the disappearance of the osteoblastic reaction. In addition, an obvious observation was that the lobe of the OKC located on the posterior border of the mandible in the angle region was increasing instead of diminishing (Fig. 1C).

Consequently, a second surgery was scheduled to remove the cysts. The pre-surgical study of the CBCT highlighted that the routine approach to the cyst, lateral osteotomy, would cause difficulties in cyst removal, with reduced view of the surgical field, an increased risk of IAN injury, and the sacrifice of a large amount of bone. Furthermore, because of weakening of the mandible structure, a risk of post-operative mandible fracture was present. In this situation, the idea of approaching the problem with sagittal osteotomy arose. This surgical procedure, normally performed in orthognathic surgery, consists of opening the two mandible portions, allowing the surgeon

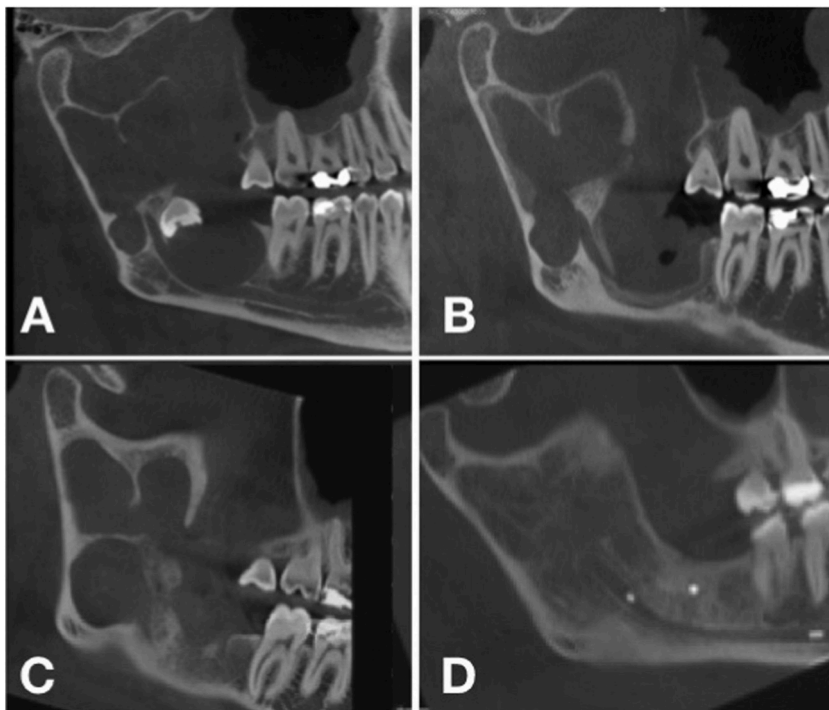


Fig. 1. Radiographic images of the multilocular odontogenic keratocyst (OKC): A) CBCT scan at the radiographic diagnosis: the lesion appears as multilocular, includes part of the impacted third molar and involves the IAN; B) CBCT scan 8 months after marsupialization (first surgical approach) with signs of bone deposition and progressive reduction in lesion volume; C) Radiographic control (CBCT) 20 months after marsupialization showing as the lobe of the OKC located on the posterior border of the mandible was increasing instead of diminishing; D) CBCT scan taken 12 months from the second surgical treatment (radical excision) with a good bone healing and incorporation of the osteosynthesis plate. CBCT= Cone Beam Computed Tomography, IAN = Inferior Alveolar Nerve, OKC = Odontogenic Keratocyst.

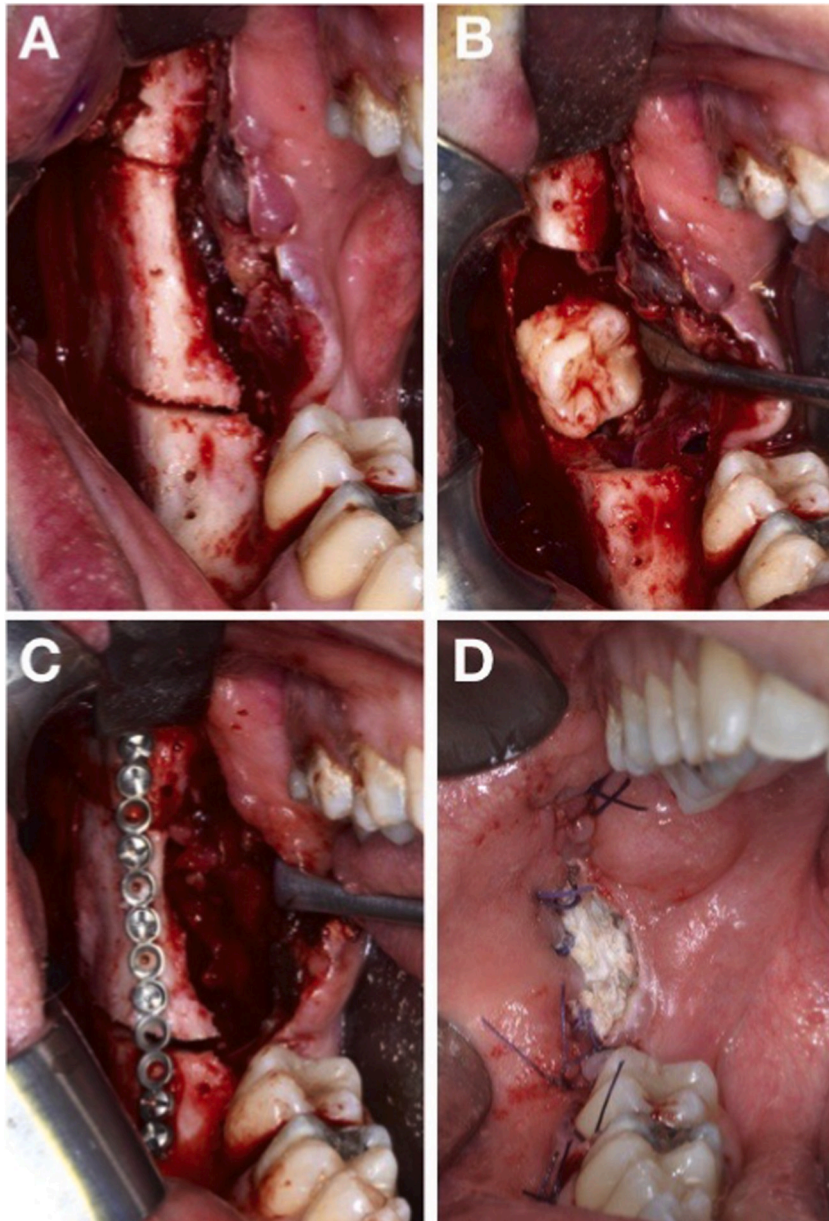


Fig. 2. Clinical images of the first surgery approach performed in order to marsupialize the cyst. A) Lateral osteotomy made to reach the lesion and the impacted tooth B) Extraction of the wisdom 4.8 tooth. C) Repositioning of the previously removed bone portion using microplates and titanium screws. D) Marsupialization of the lesion. The pathological result revealed that the lesion was an OKC.

to reach deeper areas without losing bone and enucleation of all lobes of the cyst, including the lobe located in the mandibular angle under the IAN canal (Fig. 3). The removed cysts were sent for histological analysis. An osteosynthesis plate was positioned to reconnect the body and ramus portion. The patient was released after 2 days with elastic intermaxillary fixation that was fitted for 21 days. The histological analysis confirmed the initial diagnosis of a keratocyst, but with an orthokeratinized epithelium. Neither neurological damage nor aesthetic consequences resulted from this surgical approach.

A strict follow-up was conducted, and at 12 months after the second surgery a CBCT was performed, where the complete “restitutio ad integrum” of the bone was seen, with good incorporation of the osteosynthesis plate (Fig. 1D). At 24 months after the enucleation, an OPT was done. This exam confirmed the stability of the situation and the absence of recurrence.

A CBCT, executed at 3 years after the enucleation, showed the absence of recurrences, the incorporation of the plate with no signs of inflammation, and bone remodeling. The patient will continue follow-up with radiological exams in accordance with recommendations in the literature [3].

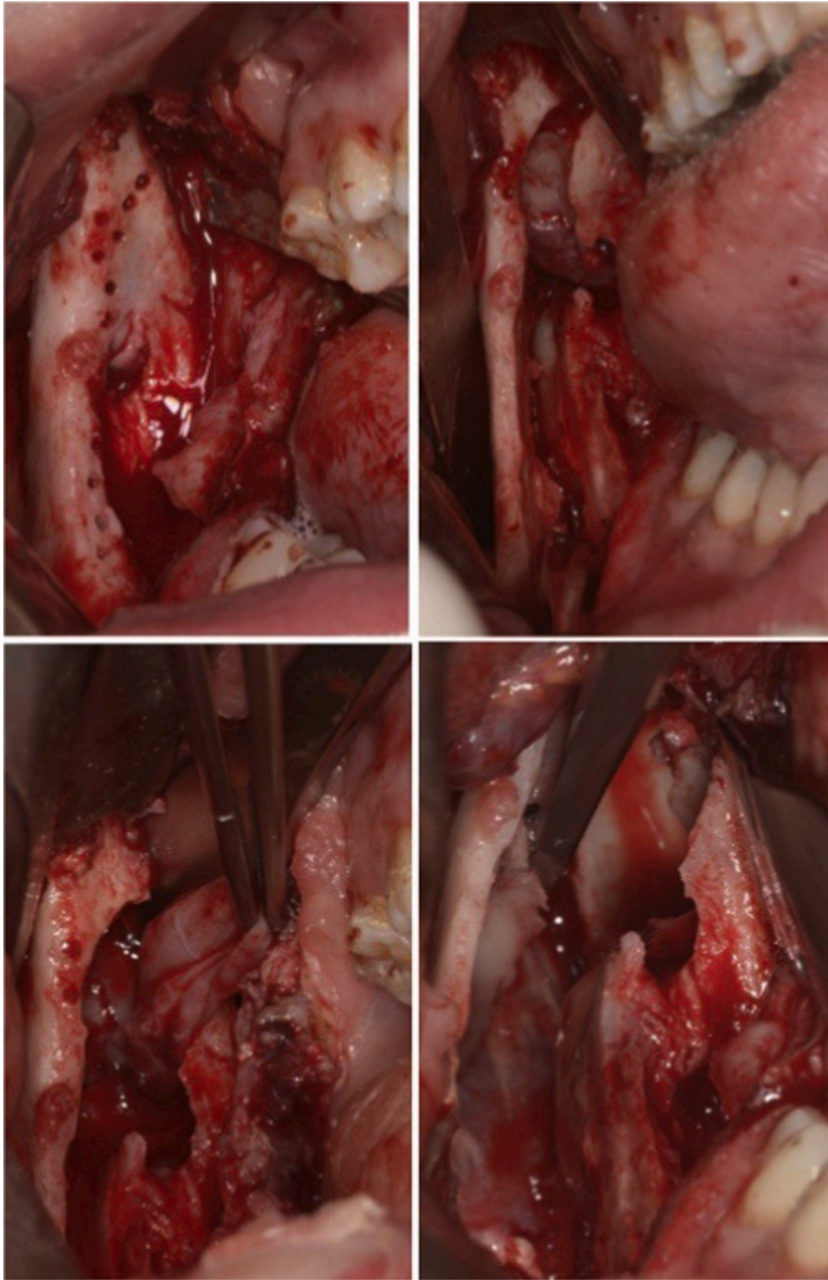


Fig. 3. Clinical images of the second surgery stage performed in order to totally remove the cyst: a sagittal osteotomy was made to conservatively enucleate the lesion.

3. Discussion

Radical and conservative approaches can be both used for the treatment of OKCs [7,8]. In this case, the possible surgical approaches were resection with a contextual reconstruction or cystic enucleation, or marsupialization followed by enucleation in a second surgery. However, ideal guidelines about choosing the right treatment for every situation have not been formulated, and the decision about treatment is often influenced by the experience of the surgeon with a surgical technique. In this case, resection was not considered the treatment of choice because of the young age of the patient. In fact, resection, even that associated with bone reconstruction, would have led to the loss of a large amount of bone, the sacrifice of the IAN, and facial asymmetry, resulting in important aesthetic and functional consequences. Due to the massive volume of the lesion, the absence of the lingual cortical bone, and the osteotomy necessary to remove the whole lesion, even enucleation was eliminated from possible treatment alternatives. Indeed, this option would have created severe bone loss, with the possible risk of mandible fracture, and probably injury to the IAN.

Therefore, marsupialization was considered the best option in this situation, and during this procedure, wide communication between all the lobes of the lesion and the oral cavity was made. In addition, this approach allowed biopsy of the lesion, which showed that it was a parakeratinized variant of keratocysts. This reinforced the suitability of marsupialization as initial treatment because it has been reported in the literature that an OKC, when marsupialized for at least 9 months, tends to turn into the orthokeratinized variant [9,10]. Therefore, we planned to marsupialize the OKC to reduce lesion volume, recreate the cortical bone, isolate the nerve bundle, and then to enucleate the residual lesion. However, during follow-up after the marsupialization, a lobe of the lesion started to increase instead of decrease in size. This behavior has never been described in the literature and in our opinion can be explained in two ways. The first hypothesis is the coexistence of multiple OKCs, the distinction of which was not detectable in the radiographs. This concept is supported by cases reporting multiple lesions in non-syndromic patients [11] even if in those cases the OKCs were in different regions of the oral cavity. The second hypothesis was inspired by the work of Kubota et al. [12], which concluded that large cysts experience a faster volume reduction than smaller ones. Applying this mechanism to each lobe of the lesion, larger ones should shrink faster than smaller ones, causing the deeper and less voluminous lobe to be obstructed and thus isolated. These hypotheses could explain why marsupialization did not have much of an effect on that lobe, but they remain unconfirmed.

In this situation, it was necessary to determine how to preserve as much bone as possible and avoid neurological damage as the lesion was still voluminous. An orthognathic procedure was chosen, consisting of sagittal osteotomy that was allowed to reach the deeper cyst in the mandible angle, reducing neurological damage. In addition, all the bone was preserved, allowing bone healing without gaps or dehiscence [13].

Follow-up played a crucial role, allowing the identification of the unusual behavior of the lesion after marsupialization and excluding recurrence after the excision. Stoeltinga [3] underlined the necessity of lifelong radiological follow-up performed every year in the first 5 years and every 2 years thereafter. This strict follow-up should be applied regardless of the treatment so that early surgical intervention can take place, in case of recurrence, with less invasive consequences, a less extended second surgery, and less morbidity.

4. Conclusion

In conclusion, the presented case highlights how careful pre-operative study can lead to the consideration of options other than routine ones as conservative therapeutic solutions. This is a case of orthognathic sagittal osteotomy of the mandible that is considered conservative not from the surgical point of view but from the biological point of view. In addition, the unusual behavior an OKC lobe exhibited in this case serves as a warning that any multilocular massive OKC can manifest this course.

Consent statement

Formal consents was not elaborated and obtained because the figures used are completely anonymized and without any marks that can make the patient identifiable.

Declaration of competing interest

The authors declare no conflict of interest.

References

- [1] Pitak-Arnop P, Chaine A, Oprean N, Dhanuthai K, Bertrand JC, Bertolus C. Management of odontogenic keratocysts of the jaws: a ten-year experience with 120 consecutive lesions. *J Cranio-Maxillo-Fac Surg* 2010;38:358.
- [2] Crowley TE, Kaugars GE, Gunsolley JC. Odontogenic keratocysts: a clinical and histologic comparison of the parakeratin and orthokeratin variants. *J Oral Maxillofac Surg* 1992;50:22.
- [3] Stoeltinga PJW. Long-term follow-up on keratocysts treated according to a defined protocol. *Int J Oral Maxillofac Surg* 2001;30:14.
- [4] Koçak-Berberoğlu H, Çakarar S, Brkić A, Gürkan-Koseoglu B, AltuğAydil B, Keskin C. Three-dimensional cone-beam computed tomography for diagnosis of keratocystic odontogenic tumours; evaluation of four cases. *Med Oral Patol Oral Cir Bucal* 2012;17:e1000.
- [5] Antonoglou GN, et al. Non-syndromic and syndromic keratocystic odontogenic tumors: systematic review and meta-analysis of recurrences. *J Cranio-Maxillo-Fac Surg* 2014;42:e364.
- [6] Alling R, Alling III CC. Removal of impacted teeth and lesion from unusual locations. *Oral Maxillofac Surg Clin* 1993;5:111.
- [7] Chrcanovic BR, Gomez RS. Recurrence probability for keratocystic odontogenic tumors: an analysis of 6427cases. *J Cranio-Maxillo-Fac Surg* 2017;45(2):244–51.
- [8] Pogrel MA. The keratocystic odontogenic tumor. *Oral Maxillofac Surg Clin* 2013;25(1):21–30.
- [9] August M, Faquin WC, Troulis MJ, Kaban LB. Dedifferentiation of odontogenic keratocyst epithelium after cyst decompression. *J Oral Maxillofac Surg* 2003;61(6):678–83.
- [10] Pogrel MA. Decompression and marsupialization as a treatment for the odontogenic keratocyst. *Oral and Maxillofacial Surgery Clinics* 2003;15(3):415–27.
- [11] Fidele NB, Zhao Y, Wu T, Sun Y, Man Q, Liu B. Treatment of multiple odontogenic keratocysts involving Chinese patients. *J Oral Maxillofac Surg* 2019;77:2044.
- [12] Kubota Y, Imajo I, Itonaga R, Takenoshita Y. Effects of the patient's age and the size of the primary lesion on the speed of shrinkage after marsupialisation of keratocystic odontogenic tumours, dentigerous cysts, and radicular cysts. *Br J Oral Maxillofac Surg* 2013;51:358.
- [13] Scolozzi P, Lombardi T, Jaques B. Le fort I type osteotomy and mandibular sagittal osteotomy as a surgical approach for removal of jaw cysts. *J Oral Maxillofac Surg* 2007;65:1419–26. <https://doi.org/10.1016/j.joms.2005.11.085>.