

# Mutations in the m-AAA proteases AFG3L2 and SPG7 are causing isolated dominant optic atrophy

Majida Charif, PhD, Arnaud Chevrollier, PhD, Naïg Gueguen, PhD, Céline Bris, PhD, David Goudenège, PhD, Valérie Desquiret-Dumas, PhD, Stéphanie Leruez, MD, Estelle Colin, MD, PhD, Audrey Meunier, MD, Catherine Vignal, MD, PhD, Vasily Smirnov, MD, Sabine Defoort-Dhellemmes, MD, Isabelle Drumare Bouvet, MD, Cyril Goizet, MD, PhD, Marcela Votruba, MD, PhD, Neringa Jurkute, MD, PhD, Patrick Yu-Wai-Man, MD, PhD, Francesca Tagliavini, PhD, Leonardo Caporali, PhD, Chiara La Morgia, MD, PhD, Valerio Carelli, MD, PhD, Vincent Procaccio, MD, PhD, Xavier Zanlonghi, MD, Isabelle Meunier, MD, PhD, Pascal Reynier, MD, PhD, Dominique Bonneau, MD, PhD, Patrizia Amati-Bonneau, MD, PhD, and Guy Lenaers, PhD

**Correspondence**  
Dr. Lenaers  
guy.lenaers@inserm.fr

*Neurol Genet* 2020;6:e428. doi:10.1212/NXG.000000000000428

## Abstract

### Objective

To improve the genetic diagnosis of dominant optic atrophy (DOA), the most frequently inherited optic nerve disease, and infer genotype-phenotype correlations.

### Methods

Exonic sequences of 22 genes were screened by new-generation sequencing in patients with DOA who were investigated for ophthalmology, neurology, and brain MRI.

### Results

We identified 7 and 8 new heterozygous pathogenic variants in *SPG7* and *AFG3L2*. Both genes encode for mitochondrial matricial AAA (m-AAA) proteases, initially involved in recessive hereditary spastic paraplegia type 7 (HSP7) and dominant spinocerebellar ataxia 28 (SCA28), respectively. Notably, variants in *AFG3L2* that result in DOA are located in different domains to those reported in SCA28, which likely explains the lack of clinical overlap between these 2 phenotypic manifestations. In comparison, the *SPG7* variants identified in DOA are interspersed among those responsible for HSP7 in which optic neuropathy has previously been reported.

### Conclusions

Our results position *SPG7* and *AFG3L2* as candidate genes to be screened in DOA and indicate that regulation of mitochondrial protein homeostasis and maturation by m-AAA proteases are crucial for the maintenance of optic nerve physiology.

From the MitoLab Team (M.C., A.C., C.B., D.G., V.D.-D., S.L., V.P., P.R., D.B., P.A.-B., G.L.), UMR CNRS 6015—INSERM U1083, Institut MitoVasc, Angers University and Hospital; Genetics and immuno-cell therapy Team (M.C.), Mohammed First University, Oujda, Morocco; Departments of Biochemistry and Genetics (C.B., D.G., V.D.-D., E.C., V.P., P.R., D.B., P.A.-B.), University Hospital Angers; Department of Ophthalmology (A.M.), Centre Hospitalier Universitaire Saint-Pierre, Brussels, Belgium; Neuroophthalmology Department (C.V.), Rothschild Ophthalmologic Foundation, Paris; Exploration of Visual Function and Neuro-Ophthalmology Department (V.S., S.D.-D., I.D.B.), Lille University Hospital, Rue Emilie Laine, Lille Cedex; CHU Bordeaux (C.G.), Service de Génétique Médicale, Centre de Référence « Neurogénétique » and Université de Bordeaux, INSERM U 1211, Laboratoire Maladies Rares, Génétique et Métabolisme (MRGM) Bordeaux; School of Optometry and Vision Sciences (M.V.), Cardiff University and Cardiff Eye Unit, University Hospital of Wales; NIHR Biomedical Research Centre at Moorfields Eye Hospital and UCL Institute of Ophthalmology (N.J., P.Y.-W.-M.), London; Department of Clinical Neurosciences (P.Y.-W.-M.), Cambridge Centre for Brain Repair and MRC Mitochondrial Biology Unit, University of Cambridge; Cambridge Eye Unit (P.Y.-W.-M.), Addenbrooke's Hospital, Cambridge University Hospitals, UK; IRCCS Istituto Delle Scienze Neurologiche di Bologna (F.T., L.C., C.L.M., V.C.), Bellaria Hospital; Unit of Neurology (C.L.M., V.C.), Department of Biomedical and NeuroMotor Sciences (DIBINEM), University of Bologna, Italy; Centre de Compétence Maladies Rares (X.Z.), Clinique Pluridisciplinaire Jules Verne, Nantes; and National Centre in Rare Diseases (I.M.), Genetics of Sensory Diseases, University Hospital, Montpellier, France.

Go to [Neurology.org/NG](https://www.neurology.org/NG) for full disclosures. Funding information is provided at the end of the article.

The Article Processing Charge was funded by the authors.

This is an open access article distributed under the terms of the Creative Commons Attribution-NonCommercial-NoDerivatives License 4.0 (CC BY-NC-ND), which permits downloading and sharing the work provided it is properly cited. The work cannot be changed in any way or used commercially without permission from the journal.

## Glossary

**DOA** = dominant optic atrophy; **HSP7** = hereditary spastic paraplegia; **OCT** = optical coherence tomography; **RGC** = retinal ganglion cell; **RNFL** = retinal nerve fiber layer; **SCA28** = spinocerebellar ataxia.

Dominant optic atrophy (DOA, MIM\*605290) is the most commonly inherited optic neuropathy, leading to irreversible loss of retinal ganglion cells (RGCs), optic nerve degeneration, and central visual loss.<sup>1,2</sup> More than 400 *OPA1* variants were identified in DOA individuals,<sup>3–6</sup> resulting in excess of mitochondrial fission.<sup>7,8</sup> Surprisingly, a similar clinical presentation was also reported in individuals with dominant *DNM1L* mutations<sup>9</sup> (MIM603850) and mitochondrial network hyperfusion, thus providing evidence that alterations of both fusion and fission compromise RGC survival. This hypothesis was further supported by the identification in syndromic DOA families of dominant mutations in *MFN2* (MIM608507)<sup>10</sup> and *OPA3* (MIM606580),<sup>11</sup> 2 additional genes acting on mitochondrial dynamics. More recently, a single *SPG7* (MIM602783) mutation and a single *AFG3L2* (MIM604581) mutation were reported in DOA families,<sup>12–14</sup> although mutations in these genes are commonly known to be responsible for the recessive hereditary spastic paraplegia type 7 (HSP7)<sup>15</sup> and dominant spinocerebellar ataxia 28 (SCA28),<sup>16</sup> respectively. In addition, the occurrence of heterozygous variants in *SPG7* and *AFG3L2* was identified in a patient affected with DOA and parkinsonism,<sup>17</sup> a clinical presentation found in few patients with *OPA1*.<sup>18</sup> *SPG7* and *AFG3L2* are paralogue genes encoding mitochondrial matricial AAA (m-AAA)-proteases involved in protein homeostasis and the cleavage of the OMA1 and YME1L mitochondrial proteases, which control the shift between profusion long and profission short *OPA1* isoforms.<sup>19</sup>

This prompted us to screen *SPG7* and *AFG3L2* exonic sequences in patients with DOA without molecular diagnosis. We report the identification of pathogenic variants in these 2 genes in nonsyndromic patients with DOA.

## Methods

### Standard protocol approvals, registrations, and patient consents

Written informed consent to perform genetic analyses was obtained from each subject involved in this study or from the parents of individuals younger than 18 years of age, according to the protocols approved by the ethical committees of the different institutes involved in this study and in agreement with the Declaration of Helsinki (Institutional Review Board Committee of the University Hospital of Angers, Authorization number: AC-2012-1507).

### Genetic analysis

Genomic DNA was extracted from peripheral blood cells from multinational cohorts of DOA and sporadic cases of

optic atrophy, initially screened for *OPA1*, *OPA3*, and *WFS1* exonic sequences and the 3 primary Leber hereditary optic neuropathy mutations. Cases negative after this primary screening were analyzed by resequencing a panel of 22 genes (table e-1, [links.lww.com/NXG/A260](https://links.lww.com/NXG/A260)) involved in inherited optic neuropathies or in mitochondrial dynamics. Library preparation for each sample was performed using an Ion AmpliSeq Library Kit 2.0 (Cat. no. 4480441) according to the manufacturer's protocol (Thermo Fisher Scientific, MAN0006735). Sample emulsion PCR, emulsion breaking, and enrichment were performed using the Ion S40 Kit–Chef (Cat. no. A27759) according to the manufacturer's instructions (Thermo Fisher Scientific, MAN0010851). Sequencing was performed using a 540 ChIPs on an Ion S5 Sequencer using the barcoded samples. Sequencing data were processed using our own dedicated bioinformatics pipeline, as described elsewhere.<sup>20</sup> Candidate pathogenic variants were validated by Sanger sequencing, and their segregation was assessed in DNAs from other members of the families, when available.

### Cell studies

Fibroblasts from *AFG3L2* individuals P1: III:2 and P2: II:1 from family 9 and 15, respectively, were generated from skin biopsies and cultured in 2/3 Dulbecco's Minimum Essential Medium (DMEM, Gibco) supplemented with 1/3 AmnioMAX (Gibco), 10% fetal calf serum (Lonza), and 1% Penicillin-Streptomycin-Amphotericin B (Lonza). Mitochondrial network analysis, respiratory chain enzymatic activities, and mtDNA copy number were assessed as described.<sup>9</sup>

### Data availability

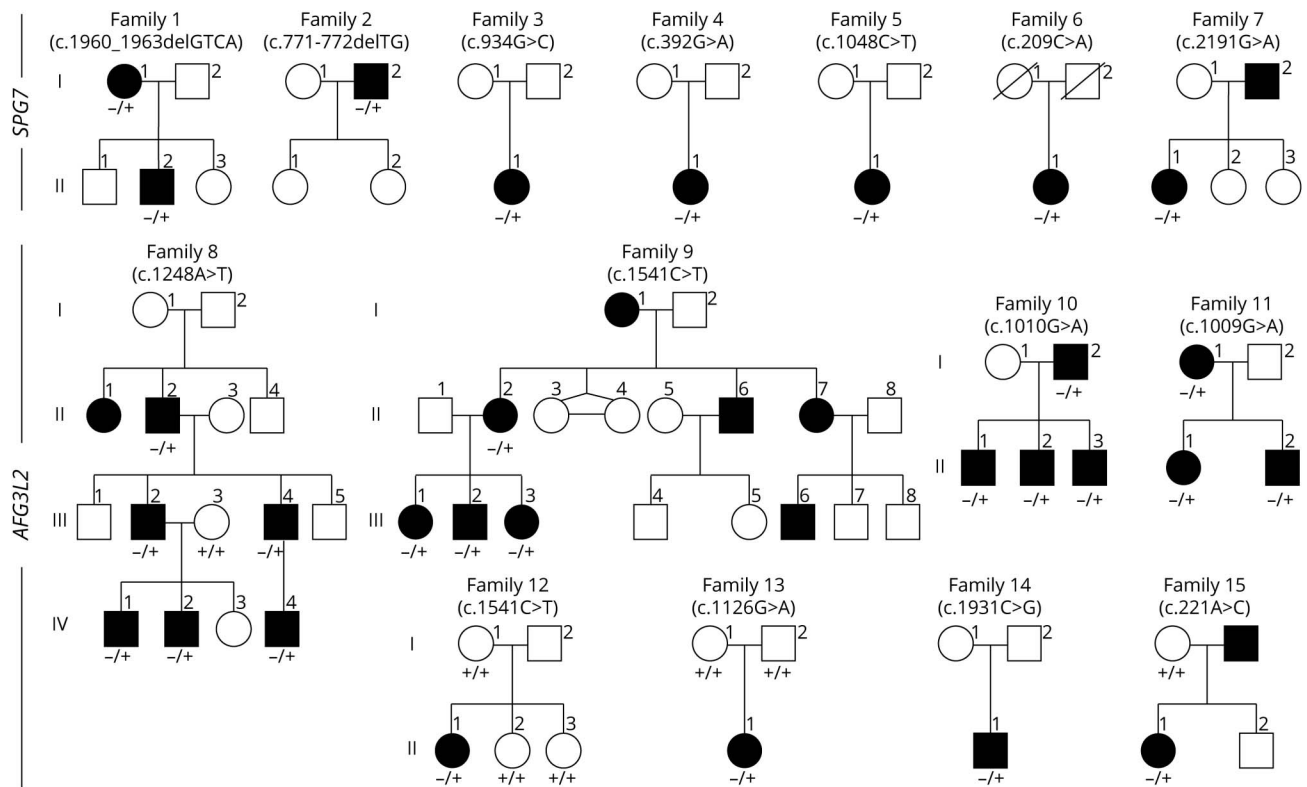
All data relevant to this study are contained within the article.

## Results

### Identification of *SPG7* and *AFG3L2* pathogenic variants in individuals with DOA or isolated optic atrophy using a targeted sequencing panel

Six hundred cases without positive result after screening *OPA1*, *OPA3*, and *WFS1* exonic sequences and the 3 primary Leber hereditary optic neuropathy mutations were included in a resequencing program focused on 22 genes, among which were those already firmly established for DOA and recessive optic atrophy and candidate genes encoding actors of the mitochondrial dynamics. After eliminating frequent (>1/10,000) and nonpathogenic variants, according to the SIFT, PolyPhen, MutationTaster, and LRT prediction tools, we identified 7 and 8 individuals harboring a *SPG7* or an

**Figure 1** *SPG7* and *AFG3L2* pedigrees



Description of the pedigrees with *SPG7* (top) and *AFG3L2* (middle and bottom) mutations and their segregation among the DOA families. DOA = dominant optic atrophy.

*AFG3L2* pathogenic heterozygous variant, respectively. These variants were confirmed by Sanger sequencing and analyzed for segregation whenever possible in the respective families. Segregation of the 15 variants fitted with the clinical features of affected individuals for whom DNA samples were available (Figure 1). In family 13, the c.1126G > A variant in *AFG3L2* was not found in both parents, suggesting that it occurred *de novo*.

### Phenotypic manifestations of *SPG7* and *AFG3L2* mutation carriers

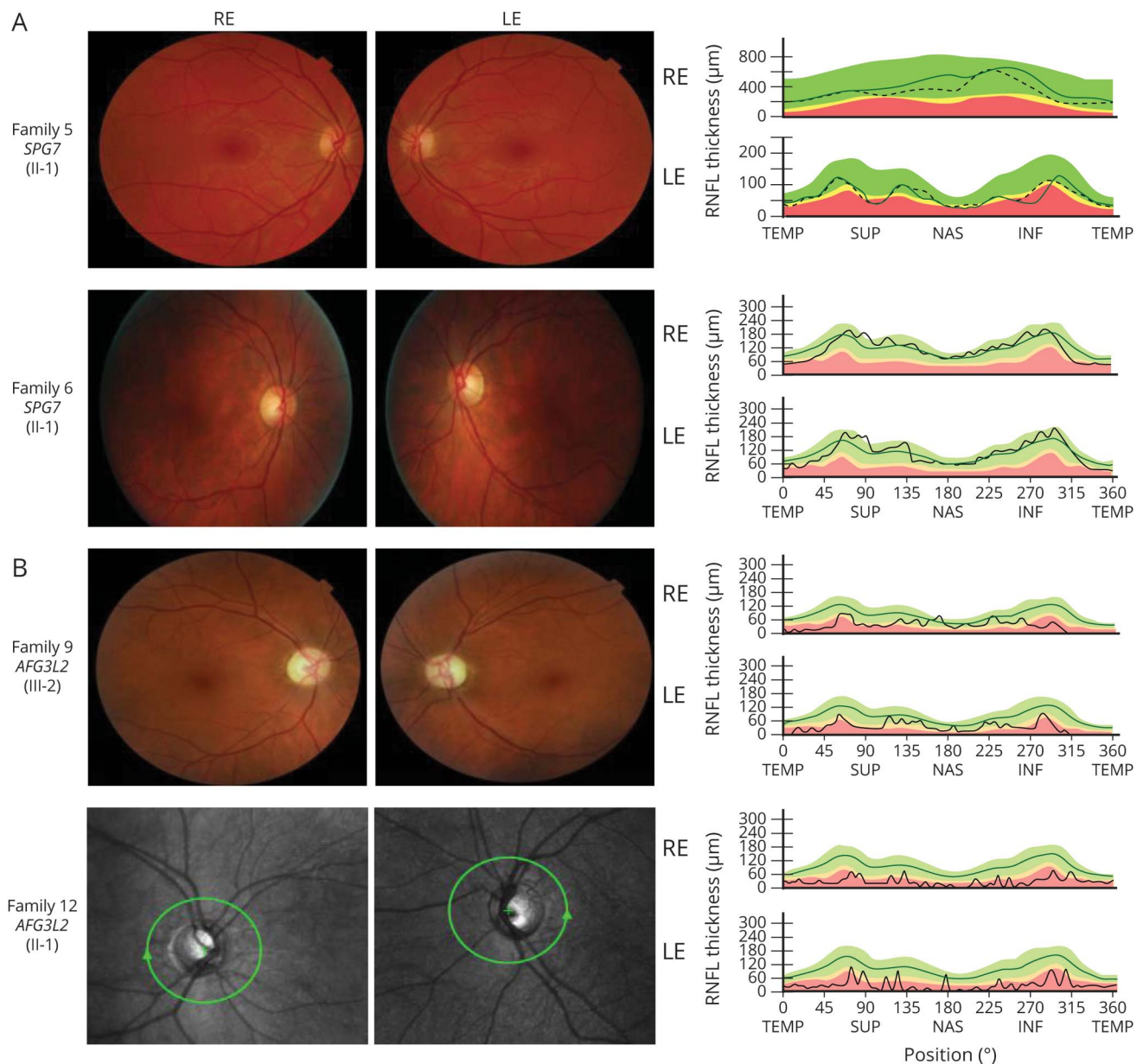
All individuals included were referred to ophthalmology departments for visual acuity impairment. At inclusion, none of them complained of spastic paraplegia or SCA, and in all cases but one, the brain MRI was normal. All patients with *SPG7* presented optic disk pallor and accordingly, reduced retinal nerve fiber layer (RNFL) at optical coherence tomography (OCT) scanning, mainly on the temporal side (figure 2A). Nevertheless, their visual acuity alterations were mild, with scores ranging from 3/10 to 10/10 (table 1) and occurring during midlife for all individuals except one (family 3, II-1). Patient II.1 from family 4 with the best visual acuity only presented a significant reduction of the RNFL at the OCT examination. No additional symptom was observed for the index cases and their relatives when the clinical data were available, except for a hearing impairment in family 5 (table 1).

Conversely, all *AFG3L2* mutated individuals disclosed a severe optic atrophy with visual acuities ranging from 0.2/10 to 2/10, except for the 3 members of family 7 who had visual acuity scores above 4/10 (table 1). First ophthalmologic examination occurred in a broad range of age, with some individuals being affected early during the first 2 decades, as reported for patients with *OPA1*.<sup>1</sup> All patients disclosed optic nerve pallor and highly reduced RNFL at OCT scanning (figure 2B). Similar to *SPG7*, no brain MRI abnormality was reported in investigated patients, except for patient II.1 from family 14, who had a pituitary adenoma without cerebellar atrophy. This individual had a hearing impairment in addition to a very low visual acuity (table 1).

### Functional consequences of *SPG7* and *AFG3L2* mutations

*SPG7* and *AFG3L2* encode highly similar proteins with 5 conserved domains (figure 3). Four of the DOA mutations in *SPG7* are referenced with a frequency close to 1e-05 in the GnomAD database, whereas the 3 others were not referenced. All *SPG7* variants responsible for DOA are interspersed with the recessive variants responsible for HSP7, and 2 of them are deletions leading to a frameshift at positions 258 and 654. These latter data suggest that *SPG7* haploinsufficiency might be the primary causal pathologic process in DOA. Surprisingly, other heterozygote composite frameshift mutations were

**Figure 2** Ophthalmologic exploration of *SPG7* and an *AFG3L2* affected individuals



Left: Eye fundus pictures of individuals with *SPG7* (A, family 5, II.1 and family 6 II.1) and individuals with *AFG3L2* (B, family 9, III:2 and family 12, II.1) revealing the temporal pallor of the optic discs in both REs and LEs. Right: RNFL by optic coherence tomography in individuals, disclosing the mild reduction of RNFL thickness in the individuals with *SPG7* (A) and the severe one in the individuals with *AFG3L2* (B). The green area defines the 5th to 95th, the yellow area the 1st to 5th, and the red area below the 1st percentiles. INF = inferior quadrants; LE = left eye; NAS = nasal; RE = right eye; RNFL = retinal nerve fiber layer assessment; SUP = superior; TEMP = temporal.

reported to cause HSP7, even at an earlier position toward the N-end of the protein (figure 3A). Unfortunately, no individual with a *SPG7* variant accepted to provide a skin biopsy to infer fibroblasts for functional validation.

Seven out of the 8 *AFG3L2* variants identified in this study were not referenced in any database. They result in missense amino acid changes (table 1), and all but one (p.Thr644Ser from family 14) are located in domains different from the one involved in SCA28 individuals, suggesting that they affect another *AFG3L2* function than the one responsible for

the SCA28 phenotype (figure 3B). Two fibroblast cell lines were established from individuals III:2 from family 9 and II:1 from family 15 to assess their mitochondrial shape and physiology. A tendency toward mitochondrial fragmentation was observed in *AFG3L2* fibroblasts (figure e-1, links.lww.com/NXG/A261), together with a significant reduction of CI, CIII, and CIV enzymatic activities, which correlated with a significant citrate synthase decreased activity, suggesting a reduction of the mitochondrial mass. This prompted the analysis of mitochondrial DNA copy number (figure e-1), which showed a significant 50% reduction in *AFG3L2* cells.



**Table 1** Clinical data of the patients with *SPG7* and *AFG3L2*

| Family | Patient | Sex | Age | VA     | Other symptoms     | Brain MRI          | Gene          | ORF mutation       | Protein change   | rs #         | GnomAD Freq. |
|--------|---------|-----|-----|--------|--------------------|--------------------|---------------|--------------------|------------------|--------------|--------------|
| 1      | I.1     | F   | 42  | 4/10   | —                  | Normal             | <i>SPG7</i>   | c.1960_1963delGTCA | p.Val654Profs*7  | Unknown      |              |
| 2      | II.1    | M   | 43  | 3/10   | Liver cirrhosis    | ND                 | <i>SPG7</i>   | c.773-774delITG    | p.Val258Glyfs*30 | rs768136171  | 8.03e-06     |
| 3      | II.1    | F   | 8   | 5/10   | —                  | Normal             | <i>SPG7</i>   | c.934G>C           | p.Ala312Pro      | Unknown      |              |
| 4      | II.1    | F   | 66  | 10/10  | —                  | Normal             | <i>SPG7</i>   | c.392G>A           | p.Arg131His      | rs985921704  | 7.99e-06     |
| 5      | II.1    | F   | 31  | 9/10   | Hearing impairment | ND                 | <i>SPG7</i>   | c.1048C>T          | p.Pro350Ser      | rs199789849  | 2 e-05       |
| 6      | II.1    | F   | 64  | 5/10   | —                  | Normal             | <i>SPG7</i>   | c.209C>A           | p.Pro70His       | Unknown      |              |
| 7      | II.1    | F   | 62  | 2&9/10 | —                  | Normal             | <i>SPG7</i>   | c.2191G>A          | p.Ala731Thr      | rs747521455  | 3.19e-5      |
| 8      | III.2   | M   | 36  | 5/10   | —                  | Normal             | <i>AFG3L2</i> | c.1248A>T          | p.Arg416Ser      | Unknown      |              |
|        | IV.1    | M   | 7   | 5/10   | —                  | Normal             | <i>AFG3L2</i> | c.1248A>T          | p.Arg416Ser      |              |              |
|        | IV.4    | M   | 8   | 4/10   | —                  | Normal             | <i>AFG3L2</i> | c.1248A>T          | p.Arg416Ser      |              |              |
| 9      | II.2    | F   | 47  | 2/10   | —                  | Normal             | <i>AFG3L2</i> | c.1541C>T          | p.Pro514Leu      | Unknown      |              |
|        | III.1   | F   | 26  | 1/10   | —                  | Normal             | <i>AFG3L2</i> | c.1541C>T          | p.Pro514Leu      |              |              |
|        | III.2   | M   | 22  | 1/10   | —                  | Normal             | <i>AFG3L2</i> | c.1541C>T          | p.Pro514Leu      |              |              |
|        | III.3   | F   | 15  | 1/10   | —                  | Normal             | <i>AFG3L2</i> | c.1541C>T          | p.Pro514Leu      |              |              |
| 10     | I.2     | M   | 80  | 1/10   | —                  | ND                 | <i>AFG3L2</i> | c. 1010 G>A        | p.Gly337Glu      | Unknown      |              |
|        | II.1    | M   | 61  | 1.6/10 | —                  | ND                 | <i>AFG3L2</i> | c. 1010 G>A        | p.Gly337Glu      |              |              |
|        | II.2    | M   | 60  | 1.6/10 | —                  | ND                 | <i>AFG3L2</i> | c. 1010 G>A        | p.Gly337Glu      |              |              |
|        | II.3    | M   | 58  | 1.6/10 | —                  | ND                 | <i>AFG3L2</i> | c. 1010 G>A        | p.Gly337Glu      |              |              |
| 11     | I.1     | F   | 46  | 0.5/10 | —                  | Normal             | <i>AFG3L2</i> | c.1009G>A          | p.Gly337Arg      | Unknown      |              |
|        | II.1    | F   | 13  | 0.5/10 | —                  | Normal             | <i>AFG3L2</i> | c.1009G>A          | p.Gly337Arg      |              |              |
|        | II.2    | M   | 7   | 0.8/10 | —                  | Normal             | <i>AFG3L2</i> | c.1009G>A          | p.Gly337Arg      |              |              |
| 12     | II.1    | F   | 25  | 0.2/10 | —                  | Normal             | <i>AFG3L2</i> | c.1541C>T          | p.Pro514Leu      | Unknown      |              |
| 13     | II.1    | F   | 9   | 1.3/10 | —                  | Normal             | <i>AFG3L2</i> | c.1126G>A          | p.Glu376Lys      | Unknown      |              |
| 14     | II.1    | M   | 59  | 1.6/10 | —                  | Normal             | <i>AFG3L2</i> | c.1931C>G          | p.Thr644Ser      | rs1226952405 | 3.98e-06     |
| 15     | II.1    | F   | 19  | 0.5/10 | Hearing impairment | Pituitary adenomas | <i>AFG3L2</i> | c.221A>C           | p.Glu74Ala       | Unknown      |              |

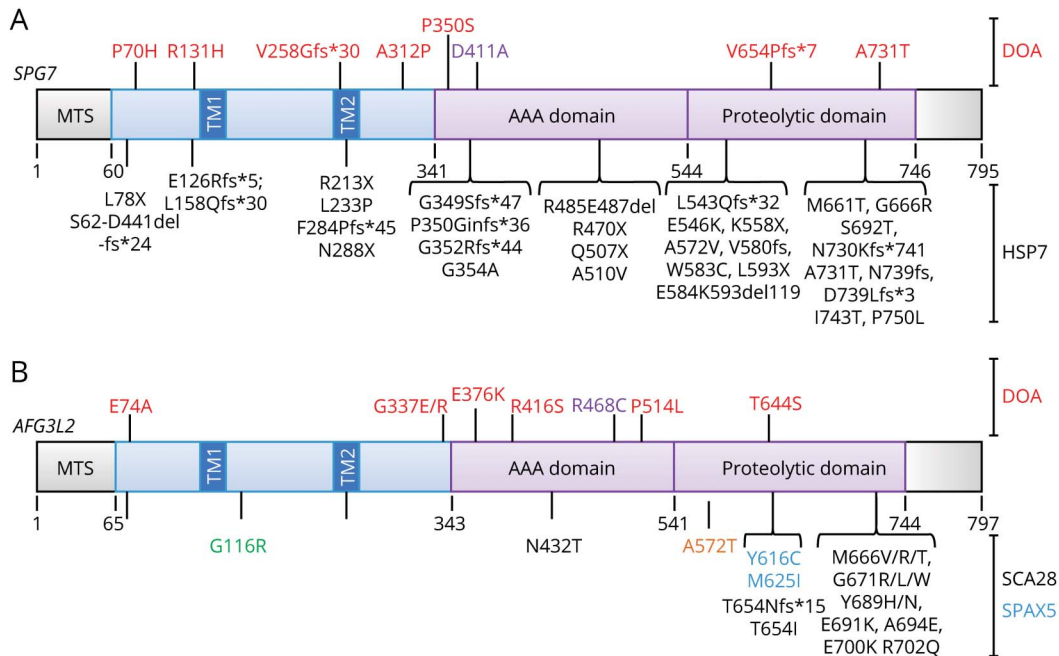
Abbreviations: GnomAD Freq. = frequency in the genome aggregation database; ND = not done; ORF = open reading frame; rs # = reference sequence number; VA = visual acuity.

## Discussion

Dominant *SPG7* and *AFG3L2* mutations can result in isolated optic nerve involvement with a clinical phenotype

indistinguishable from that seen in patients with DOA harboring dominant *OPA1* mutations. As in *OPA1*-positive DOA, *SPG7* and *AFG3L2* mutation carriers can present with a broad spectrum of visual impairment ranging from asymptomatic

**Figure 3** Structural representation of SPG7 and AFG3L2 amino acid changes related to mutations in individuals with DOA, HSP7, and SCA28/SPAX5



(A): Structure and domains of the SPG7 protein with the amino acid changes associated with DOA (top) and HSP7 (bottom); red, mutations identified in this study; purple, a DOA mutation previously reported; and black: HSP7 published mutations. (B): Structure and domains of the AFG3L2 protein with the amino acid changes associated with DOA (top) and to other diseases (bottom); red, mutations identified in this study; purple, a previously reported DOA mutation; black, published mutations responsible for SCA28; blue, published mutations responsible for recessive spastic ataxia SPAX5; in green, myoclonus and pyramidal signs; and in orange, microcephaly, early onset seizures, spasticity, and basal ganglia atrophy. DOA = dominant optic atrophy; SCA28 = spinocerebellar ataxia; SPAX5 = spastic ataxia-neuropathy syndrome.

mutation carriers to legal blindness and, in some of them, to a more severe syndromic manifestation with sensorineural deafness.<sup>21</sup>

It is intriguing that *SPG7* mutations can behave both dominantly and recessively with variable tissue specificity. Of interest, in a previous work reporting novel *SPG7* mutations, 10 affected individuals underwent an ophthalmologic examination and all of them had evidence of a mild optic neuropathy with bilateral optic disc pallor and thinning of the peripapillary RNFL on OCT imaging.<sup>12</sup> Conversely, the neurologic examination by the same team of the first-identified *SPG7*-related DOA family did not evidence any gait or walking difficulties in mutation carriers. In addition, the *SPG7* variants that we identified in individuals with DOA are interspersed with the recessive variants resulting in HSP7, and in both diseases frameshift variants are contributing to the pathophysiologic mechanism. Altogether, these data suggest a clinical overlap related to *SPG7* mutations between DOA on one end and HSP7 on the other end and all possible mixed phenotype inbetween. These observations should prompt to perform a systematic neuroophthalmological examination of individuals with HSP7 and their heterozygous parents. Similarly, DOA individuals with a *SPG7* variant should have a neurologic follow-up, particularly older than the age of 40 years, to evaluate the eventual occurrence of spasticity and also cognitive impairment, epilepsy, and cerebellar atrophy.

Dominant mutations in *AFG3L2* were initially found in individuals affected with SCA28 and do localize in exons 15 and 16, in addition to one in exon 10.<sup>22</sup> Recessive consanguineous *AFG3L2* mutations in exon 15 were also identified in a spastic ataxia-neuropathy syndrome<sup>23</sup> (SPAX5), whereas 2 additional dominant *AFG3L2* variants were identified in an individual affected with myoclonus and pyramidal signs<sup>24</sup> and a recessive mutation in another family affected with microcephaly, early onset seizures, spasticity, and basal ganglia atrophy.<sup>25</sup> Of interest, the 8 missense *AFG3L2* variants that we identified in individuals with DOA are involving other domains than those identified earlier, thus explaining the absence of clinical overlap between all the symptoms previously described for *AFG3L2* mutations and the optic atrophy found in this study. This is reinforced by the normality of the brain MRI and the absence of ataxia in *AFG3L2*-related patients with DOA. Nevertheless, we suggest that the ophthalmologic follow-up of these individuals should be accompanied by a neurologic examination to eventually diagnose early manifestations of cerebellar ataxia or any other clinical symptoms.

The 2 m-AAA proteases encoded by *SPG7* and *AFG3L2* genes have been described as promoting OPA1 cleavage to its short profession isoforms.<sup>19</sup> This activity is under the control of OMA1 and YME1L proteases that directly process

the cleavage of OPA1.<sup>26</sup> Our data suggest that this mechanism might be affected by the dominant variants in both genes, although at different levels, depending on the mutated gene. Indeed, AFG3L2 forms both homopolymers and heteropolymers with SPG7; therefore, pathogenic variants should affect the activity of both types of polymers. Conversely, SPG7 can only form heteropolymers with AFG3L2, but not homopolymers, implying that pathogenic variants should only affect the activity of the AFG3L2-SPG7 heteropolymers. This might explain the relatively mild visual deficits in individuals with SPG7 variants, contrasting with the more severe visual loss observed in individuals with AFG3L2 variants and the syndromic DOA plus phenotype found in a patient harboring concurrent mutations in both genes. It further questions the possible specificity of these mutations for the regulation of OPA1 processing. In this respect, mitochondrial dynamic might be affected by the other SPG7 mutations but overwhelmed by the severe HSP7 phenotype, whereas it is apparently not affected by the AFG3L2 variants involved in SCA28. This reflects the fact that no optic atrophy has been yet reported in the mouse models harboring *Spg7* or *Afg3l2* mutations.

Thus, we provide compelling evidence that heterozygous SPG7 and AFG3L2 mutations should be considered in the cases of isolated DOA, more so when already found to be OPA1-negative. Our findings stress the central role mediated by m-AAA proteases in the regulation of mitochondrial dynamics and how dysfunction of these pathways compromise the RGC integrity and survival, resulting in optic neuropathy.

## Acknowledgment

The authors are indebted to Dr. Vittoria Petruzzella, Silvana Guerriero, Anna Maria De Negri, and Michele Carbonelli for clinical investigations and thank Dr. Menetou for stimulating critical discussions.

## Study funding

The authors are indebted for the financial support to the Université d'Angers, CHU d'Angers, the Région Pays de la Loire, Angers Loire Métropole, the Fondation Maladies Rares, the Fondation VISIO, Kjer-France, Ouvrir Les Yeux, Retina France, UNADEV, Fondation de France, and Association Française contre les Myopathies.

## Disclosure

P. Yu-Wai-Man is supported by a Clinician Scientist Fellowship Award (G1002570) from the Medical Research Council (UK) and also receives funding from Fight for Sight (UK), the Isaac Newton Trust (UK), the UK National Institute of Health Research (NIHR) as part of the Rare Diseases Translational Research Collaboration, and the NIHR Biomedical Research Centre based at Moorfields Eye Hospital NHS Foundation Trust and UCL Institute of Ophthalmology. L. Caporali is supported by the Grant GR-2016-

02361449 and VC by the “Ricerca Corrente” funding, both from the Italian Ministry of Health. The views expressed are those of the author(s) and not necessarily those of the NHS, the NIHR, or the Department of Health. M. Charif, A. Chevrollier, N. Gueguen, C. Bris, D. Goudenège, V. Desquirit-Dumas, S. Leruez, E. Colin, A. Meunier, C. Vignal, V. Smirnov, S. Defoort-Dhellemmes, I. Drumare Bouvet, C. Goizet, M. Votruba, N. Jurkute, P. Yu-Wai-Man, F. Tagliavini, L. Caporali, C. La Morgia, V. Carelli, V. Procaccio, X. Zanlonghi, I. Meunier, P. Reynier, D. Bonneau, P. Amati-Bonneau, and G. Lenaers report no disclosures relevant to the manuscript. Go to [Neurology.org/NG](http://Neurology.org/NG) for full disclosures.

## Publication history

Received by *Neurology: Genetics* November 22, 2019. Accepted in final form April 6, 2020.

## Appendix Authors

| Name                                | Location  | Contribution  |
|-------------------------------------|---|---|
| <b>Majida Charif, PhD</b>           | University of Angers, France                        | Acquisition and analysis of the data and drafting a significant portion of the manuscript and figures |
| <b>Arnaud Chevrollier, PhD</b>      | University of Angers, France                        | Acquisition and analysis of the data  |
| <b>Naïg Gueguen, PhD</b>            | University and Hospital of Angers, France           | Acquisition and analysis of the data  |
| <b>Céline Bris, PhD</b>             | University and Hospital of Angers, France           | Acquisition and analysis of the data  |
| <b>David Goudenège, PhD</b>         | University and Hospital of Angers, France           | Acquisition and analysis of the data  |
| <b>Valérie Desquirit-Dumas, PhD</b> | University and Hospital of Angers, France           | Acquisition and analysis of the data  |
| <b>Stéphanie Leruez, MD</b>         | University and Hospital of Angers, France           | Clinical investigation and phenotyping  |
| <b>Estelle Colin, MD, PhD</b>       | University and Hospital of Angers, France           | Clinical investigation and phenotyping  |
| <b>Audrey Meunier, MD</b>           | University and Hospital of Brussels, Belgium        | Clinical investigation and phenotyping  |
| <b>Catherine Vignal, MD, PhD</b>    | Rothschild Ophthalmologic Foundation, Paris, France | Clinical investigation and phenotyping  |
| <b>Vasily Smirnov, MD</b>           | University and Hospital of Lille, France            | Clinical investigation and phenotyping  |

Continued

## Appendix (continued)

| Name                                   | Location                                    | Contribution  |
|--|---|---|
| <b>Sabine Defoort-Dhellemmes, MD</b>   | University and Hospital of Lille, France    | Clinical investigation and phenotyping  |
| <b>Isabelle Drumare Bouvet, MD</b>     | University and Hospital of Lille, France    | Clinical investigation and phenotyping  |
| <b>Cyril Goizet, MD, PhD,</b>          | University and Hospital of Bordeaux, France | Clinical investigation and phenotyping  |
| <b>Marcela Votruba, MD, PhD</b>        | University and Hospital of Cardiff, UK      | Clinical investigation and phenotyping  |
| <b>Neringa Jurkute, MD, PhD</b>        | University College of London, UK            | Clinical investigation and phenotyping  |
| <b>Patrick Yu-Wai-Man, MD, PhD</b>     | University College of London, UK            | Clinical investigation and phenotyping  |
| <b>Francesca Tagliavini, PhD</b>       | University of Bologna, Italy                | Acquisition and analysis of the data  |
| <b>Leonardo Caporali, PhD</b>          | University of Bologna, Italy                | Acquisition and analysis of the data  |
| <b>Chiara La Morgia, MD, PhD</b>       | University and Hospital of Bologna, Italy   | Clinical investigation and phenotyping  |
| <b>Valerio Carelli, MD, PhD</b>        | University and Hospital of Bologna, Italy   | Clinical investigation and phenotyping  |
| <b>Vincent Procaccio, MD, PhD</b>      | University and Hospital of Angers, France   | Clinical investigation and phenotyping  |
| <b>Xavier Zanlonghi, MD,</b>           | Clinique Jules Verne, Nantes, France        | Clinical investigation and phenotyping  |
| <b>Isabelle Meunier, MD, PhD</b>       | Hospital of Montpellier, France             | Clinical investigation and phenotyping  |
| <b>Pascal Reynier, MD, PhD</b>         | University and Hospital of Angers, France   | Clinical investigation and phenotyping; Acquisition and analysis of the data                        |
| <b>Dominique Bonneau, MD, PhD,</b>     | University and Hospital of Angers, France   | Clinical investigation and phenotyping and revised the manuscript for intellectual content          |
| <b>Patrizia Amati-Bonneau, MD, PhD</b> | University and Hospital of Angers, France   | Conception and design of the study and acquisition and analysis of the data                         |
| <b>Guy Lenaers, PhD</b>                | University and Hospital of Angers, France   | Conception and design of the study and drafting a significant portion of the manuscript and figures |

## References

- Lenaers G, Hamel C, Delettre C, et al. Dominant optic atrophy. *Orphanet J Rare Dis* 2012;7:46.
- Yu-Wai-Man P, Chinnery PF. Dominant optic atrophy: novel OPA1 mutations and revised prevalence estimates. *Ophthalmology* 2013;120:1712.
- Alexander C, Votruba M, Pesch UE, et al. OPA1, encoding a dynamin-related GTPase, is mutated in autosomal dominant optic atrophy linked to chromosome 3q28. *Nat Genet* 2000;26:211–215.
- Delettre C, Lenaers G, Griffoin JM, et al. Nuclear gene OPA1, encoding a mitochondrial dynamin-related protein, is mutated in dominant optic atrophy. *Nat Genet* 2000;26:207–210.
- Ferré M, Caignard A, Milea D, et al. Improved locus-specific database for OPA1 mutations allows inclusion of advanced clinical data. *Hum Mutat* 2015;36:20–25.
- Le Roux B, Lenaers G, Zanlonghi X, et al. OPA1: 516 unique variants and 831 patients registered in an updated centralized Variome database. *Orphanet J Rare Dis* 2019;14:214.
- Olichon A, Landes T, Arnauné-Pelloquin L, et al. Effects of OPA1 mutations on mitochondrial morphology and apoptosis: relevance to ADOA pathogenesis. *J Cell Physiol* 2007;211:423–430.
- Bertholet AM, Delerue T, Millet AM, et al. Mitochondrial fusion/fission dynamics in neurodegeneration and neuronal plasticity. *Neurobiol Dis* 2016;90:3–19.
- Gerber S, Charif M, Chevrollier A, et al. Mutations in DNM1L, as in OPA1, result in dominant optic atrophy despite opposite effects on mitochondrial fusion and fission. *Brain* 2017;140:2586–2596.
- Rouzier C, Bannwarth S, Chaussonet A, et al. The MFN2 gene is responsible for mitochondrial DNA instability and optic atrophy 'plus' phenotype. *Brain* 2012;135:23–34.
- Reynier P, Amati-Bonneau P, Verny C, et al. OPA3 gene mutations responsible for autosomal dominant optic atrophy and cataract. *J Med Genet* 2004;41:e110.
- Klebe S, Depienne C, Gerber S, et al. Spastic paraplegia gene 7 in patients with spasticity and/or optic neuropathy. *Brain* 2012;135:2980–2993.
- Charif M, Roubertie A, Salime S, et al. A novel mutation of AFG3L2 might cause dominant optic atrophy in patients with mild intellectual disability. *Front Genet* 2015;6:311.
- Colavito D, Maritan V, Suppiej A, et al. Non-syndromic isolated dominant optic atrophy caused by the p.R468C mutation in the AFG3 like matrix AAA peptidase subunit 2 gene. *Biomed Rep* 2017;7:451–454.
- Casari G, De Fusco M, Ciarmatori S, et al. Spastic paraplegia and OXPHOS impairment caused by mutations in paraplegin, a nuclear-encoded mitochondrial metalloprotease. *Cell* 1998;93:973–983.
- Di Bella D, Lazzaro F, Brusco A, et al. Mutations in the mitochondrial protease gene AFG3L2 cause dominant hereditary ataxia SCA28. *Nat Genet* 2010;42:313–321.
- Magri S, Fracasso V, Plumari M, et al. Concurrent AFG3L2 and SPG7 mutations associated with syndromic parkinsonism and optic atrophy with aberrant OPA1 processing and mitochondrial network fragmentation. *Hum Mutat* 2018;39:2060–2071.
- Carelli V, Musumeci O, Caporali L, et al. Syndromic parkinsonism and dementia associated with OPA1 missense mutations. *Ann Neurol* 2015; 78: 21–38.
- Ehnes S, Raschke I, Mancuso G, et al. Regulation of OPA1 processing and mitochondrial fusion by m-AAA protease isoenzymes and OMA1. *J Cell Biol* 2009; 187: 1023–1036.
- Felhi R, Sfaïhi L, Charif M, et al. Next generation sequencing in family with MNGIE syndrome associated to optic atrophy: novel homozygous POLG mutation in the C-terminal sub-domain leading to mtDNA depletion. *Clin Chim Acta* 2019;488:104–110.
- Yu-Wai-Man P, Griffiths PG, Gorman GS, et al. Multi-system neurological disease is common in patients with OPA1 mutations. *Brain* 2010; 133: 771–786.
- Cagnoli C, Stevanin G, Brussino A, et al. Missense mutations in the AFG3L2 proteolytic domain account for ~1.5% of European autosomal dominant cerebellar ataxias. *Hum Mutat* 2010;31:1117–1124.
- Pierson TM, Adams D, Bonn F, et al. Whole-exome sequencing identifies homozygous AFG3L2 mutations in a spastic ataxia-neuropathy syndrome linked to mitochondrial m-AAA proteases. *PLoS Genet* 2011;7:e1002325.
- Mancini C, Orsi L, Guo Y, et al. An atypical form of AOA2 with myoclonus associated with mutations in SETX and AFG3L2. *BMC Med Genet* 2015;16:16.
- Eskandrani A, AlHashem A, Ali ES, et al. Recessive AFG3L2 mutation causes progressive microcephaly, early onset seizures, spasticity, and basal ganglia involvement. *Pediatr Neurol* 2017;71:24–28.
- Anand R, Wai T, Baker MJ, et al. The i-AAA protease YME1L and OMA1 cleave OPA1 to balance mitochondrial fusion and fission. *J Cell Biol* 2014;204:919–929.



# Neurology<sup>®</sup> Genetics

**Mutations in the m-AAA proteases AFG3L2 and SPG7 are causing isolated dominant optic atrophy**

Majida Charif, Arnaud Chevrollier, Naïg Gueguen, et al.

*Neurol Genet* 2020;6;

DOI 10.1212/NXG.0000000000000428

**This information is current as of May 20, 2020**

*Neurol Genet* is an official journal of the American Academy of Neurology. Published since April 2015, it is an open-access, online-only, continuous publication journal. Copyright © 2020 The Author(s). Published by Wolters Kluwer Health, Inc. on behalf of the American Academy of Neurology. All rights reserved. Online ISSN: 2376-7839.



|   |  |
|---|--|
| <b>Updated Information &amp; Services</b> | including high resolution figures, can be found at:<br><a href="http://ng.neurology.org/content/6/3/e428.full.html">http://ng.neurology.org/content/6/3/e428.full.html</a>   |
| <b>References</b>                         | This article cites 26 articles, 3 of which you can access for free at:<br><a href="http://ng.neurology.org/content/6/3/e428.full.html##ref-list-1">http://ng.neurology.org/content/6/3/e428.full.html##ref-list-1</a>  |
| <b>Citations</b>                          | This article has been cited by 1 HighWire-hosted articles:<br><a href="http://ng.neurology.org/content/6/3/e428.full.html##otherarticles">http://ng.neurology.org/content/6/3/e428.full.html##otherarticles</a>  |
| <b>Subspecialty Collections</b>           | This article, along with others on similar topics, appears in the following collection(s):<br><b>Mitochondrial disorders</b><br><a href="http://ng.neurology.org/cgi/collection/mitochondrial_disorders">http://ng.neurology.org/cgi/collection/mitochondrial_disorders</a><br><b>Optic nerve</b><br><a href="http://ng.neurology.org/cgi/collection/optic_nerve">http://ng.neurology.org/cgi/collection/optic_nerve</a><br><b>Optic neuritis; see Neuro-ophthalmology/Optic Nerve</b><br><a href="http://ng.neurology.org/cgi/collection/optic_neuritis">http://ng.neurology.org/cgi/collection/optic_neuritis</a><br><b>Spinocerebellar ataxia</b><br><a href="http://ng.neurology.org/cgi/collection/spinocerebellar_ataxia">http://ng.neurology.org/cgi/collection/spinocerebellar_ataxia</a><br><b>Visual loss</b><br><a href="http://ng.neurology.org/cgi/collection/visual_loss">http://ng.neurology.org/cgi/collection/visual_loss</a> |
| <b>Permissions &amp; Licensing</b>        | Information about reproducing this article in parts (figures, tables) or in its entirety can be found online at:<br><a href="http://ng.neurology.org/misc/about.xhtml#permissions">http://ng.neurology.org/misc/about.xhtml#permissions</a>  |
| <b>Reprints</b>                           | Information about ordering reprints can be found online:<br><a href="http://ng.neurology.org/misc/addir.xhtml#reprintsus">http://ng.neurology.org/misc/addir.xhtml#reprintsus</a>  |

*Neurol Genet* is an official journal of the American Academy of Neurology. Published since April 2015, it is an open-access, online-only, continuous publication journal. Copyright © 2020 The Author(s). Published by Wolters Kluwer Health, Inc. on behalf of the American Academy of Neurology. All rights reserved. Online ISSN: 2376-7839.

