

Atypical fibroxanthoma associated with differentiated-type vulvar intraepithelial neoplasia: Case report of an unusual entity



Antonio De Leo, MD,^{a,b} Costantino Ricci, MD,^a Patrizia Terzano, MD,^c
Donatella Santini, MD,^a and Barbara Corti, MD^a
Bologna, Italy

Key words: atypical fibroxanthoma; differentiated-type vulvar intraepithelial neoplasia; sarcoma; skin; vulva.

INTRODUCTION

The term *atypical fibroxanthoma* (AFX) was first used in 1963 by Helwig et al¹⁻³ to indicate a typically nodular ulcerative tumor arising on sun-exposed skin of the head and neck of the elderly. Furthermore, AFX has been described after radiation therapy and in immunosuppressed patients, specifically in transplant patients or in HIV-positive patients.^{4,5} A diagnosis of AFX requires most caution, because it implies a biologically benign lesion that must be differentiated from malignant cutaneous tumors.⁶⁻⁹

Here we underline the problems of differential diagnosis and therapeutic management of AFX in a previously unrecognized site, providing a description of its clinical and pathologic features, which could assist both the clinician and pathologist in avoiding misdiagnosis and relative unnecessary treatment.

CASE REPORT

An 82-year-old woman with a history of vulvar lichen sclerosus and differentiated-type vulvar intraepithelial neoplasia (dVIN), presented at our gynecology unit for a painless, nonbleeding, 1 cm nodule on the right labium minus. The patient underwent an excisional biopsy of the vulva. Macroscopically, the lesion appeared as a solid, nonhemorrhagic, dome-shaped greyish-brown nodule of 1 cm in maximum diameter (Fig 1, A). Microscopic examination found an

Abbreviations used:

AFX: atypical fibroxanthoma
dVIN: differentiated-type vulvar intraepithelial neoplasia
UPS: undifferentiated pleomorphic sarcoma

extensive mesenchymal intradermal proliferation of highly atypical cells, arranged in a haphazard or vaguely fascicular pattern, diffusely infiltrating the dermis without extension in the subcutis or involvement of skin appendages. The overlying epidermis showed a dVIN (Fig 1, B). No lymphovascular invasion was observed. Histologically, the tumor resembled an undifferentiated pleomorphic sarcoma (UPS) with pleomorphic spindle-shaped, round or histiocyte-like cells with scattered multinucleated giant cells. The tumor cells displayed large, irregular and hyperchromatic nuclei; prominent nucleoli; and abundant, eosinophilic, or foamy cytoplasm. Multinucleated giant cells also exhibited bizarre and atypical nuclei (Fig 1, C). The mean mitotic count was 7 mitoses per 10 high-power fields, with many atypical mitoses (Fig 1, C). Secondary changes included focal hemorrhage with hemosiderin deposition, focal myxoid stroma, and mild chronic inflammatory infiltrate. The underlying dVIN was completely excised, and the adjacent skin showed features of lichen sclerosus. Immunohistochemically, tumor cells were positive for vimentin and for CD10

From the Pathology Unit^a and the Gynecology Unit,^c S. Orsola-Malpighi Hospital and the Department of Experimental, Diagnostic and Specialty Medicine, University of Bologna.^b

Drs De Leo and Ricci contributed equally to the work.

Funding sources: None.

Conflicts of interest: None disclosed.

Correspondence to: Antonio De Leo, MD, Department of Experimental, Diagnostic and Specialty Medicine, Pathology Unit, S. Orsola-Malpighi Hospital, University of Bologna, Bologna, Italy. E-mail: antonio.deleo@studio.unibo.it.

JAAD Case Reports 2019;5:448-50.

2352-5126

© 2019 by the American Academy of Dermatology, Inc. Published by Elsevier, Inc. This is an open access article under the CC BY-NC-ND license (<http://creativecommons.org/licenses/by-nc-nd/4.0/>).

<https://doi.org/10.1016/j.jcdr.2019.03.003>

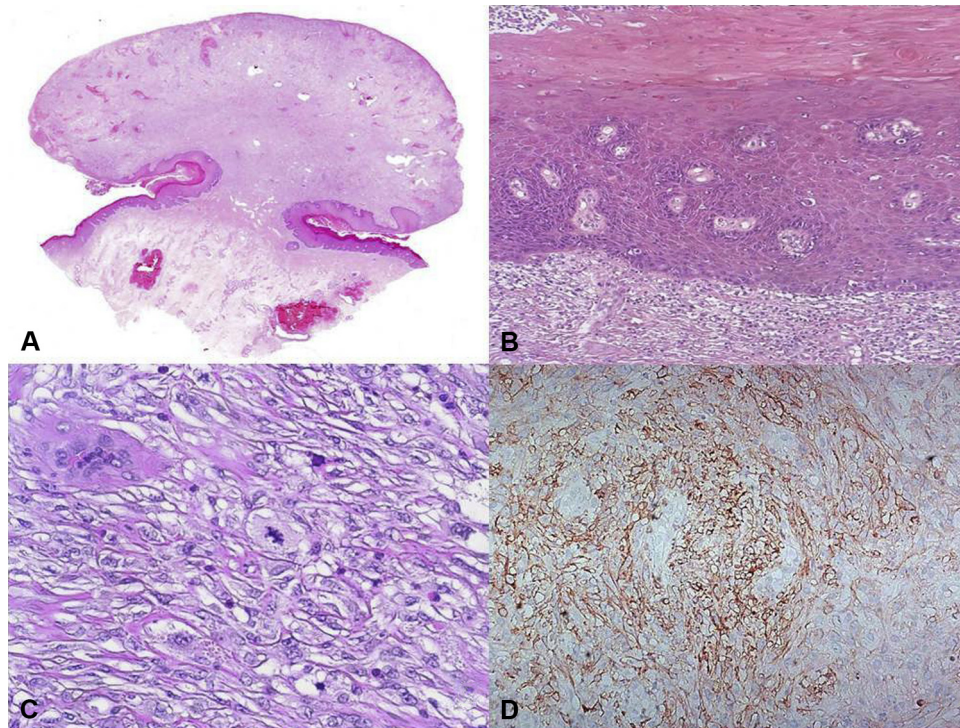


Fig 1. **A**, Whole-mount histology of the entire tumor. **B**, AFX associated with dVIN. **C**, Histopathologic features of the tumor with striking nuclear pleomorphism and atypical mitoses. **D**, Heterogeneous immunoreactivity for CD10. (**A**, **B**, and **C**, Hematoxylin-eosin stain; **D**, Immunohistochemistry stain; original magnifications: **A**, $\times 5$; **B**, $\times 100$; **C** and **D**, $\times 200$.)

(Fig 1, D), and negative for all low- and high-molecular-weight cytokeratins, EMA, p63, S100 protein, HMB-45, Melan-A, CD99, CD117, SMA, desmin, CD34, CD31, ERG, ALK protein, WT-1, calretinin, and CD68. P53 was overexpressed. Based on these findings, a final diagnosis of atypical fibroxanthoma of the vulvar skin was made. After the diagnosis, the patient was referred to our gynecology unit for follow-up, and she is currently alive with no evidence of disease 24 months after the excision.

DISCUSSION

AFX is a cutaneous undifferentiated pleomorphic sarcoma arising on sun-damaged skin of the elderly, although other predisposing factors have been reported: burns, trauma, radiotherapy, immunosuppression treatment after cardiac and renal transplant, and AIDS.¹⁻⁵ Its superficial location within the dermis has been credited with its excellent prognosis after conservative surgery. In most instances, it appears as a rapidly enlarging solitary dome-shaped skin-colored or ulcerated nodule measuring less than 2 cm. Histologically, AFX is characterized by a high number of pleomorphic, spindle, and multinucleated giant cells resembling those of pleomorphic sarcoma of other sites. Despite its morphology, AFX is

considered a tumor with a benign clinical course, with an exceedingly low risk for local recurrence and no metastatic potential.⁶⁻⁹ Therefore, AFX is a diagnosis of exclusion that should be made in an appropriate clinical setting.

AFX must be differentiated from other benign and malignant cutaneous tumors, mainly atypical fibrous histiocytoma, UPS, leiomyosarcoma, melanoma, and spindle cell squamous cell carcinoma.

Atypical fibrous histiocytoma, a lesion already described in the vulva and other cutaneous sites by Kaddu et al,⁶ differs from AFX in its predilection for younger individuals (<40 years), anatomic distribution that favors the extremities, absence of previous skin damage, and lack of classic features of fibrous histiocytoma (eg, entrapped hyalinized collagen bundles, aneurismal changes, epidermal hyperplasia). UPS is histologically indistinguishable from AFX, but it represents a neoplasm with an aggressive behavior, with high risk of local recurrence and metastasis, and requires a different therapeutic management (surgery and adjuvant chemotherapy). According to most of investigators,⁶⁻⁹ if a neoplasm is larger than 2 cm and extensively involves the subcutis, muscle, or other deep structures with necrosis or vascular invasion, it should be diagnosed as UPS.

In assessing the differential diagnosis with other pleomorphic malignancies of the skin, the immunohistochemistry is essential to rule out carcinoma, melanoma, leiomyosarcoma, and angiosarcoma.

Even though there are no immunohistochemical markers specific for AFX, a panel of antibodies including S100 protein, cytokeratins, EMA, HMB-45, MART-1, CD31, and CD34 should always be done. Immunohistochemical positivity for vimentin and negativity for cytokeratins and EMA confirm the mesenchymal nature of the lesion, whereas negativity for S-100, MART-1, and HMB45 excludes a melanoma. In this case, negativity for cytokeratins and EMA was doubly useful to exclude spindle cell squamous cell carcinoma, given the presence of a dVIN in the overlying epidermis. Negativity for SMA, desmin, CD34, CD31, ERG, ALK protein, WT-1, and CD68 excluded other cutaneous sarcoma that could arise in the vulva, such as leiomyosarcoma (SMA and desmin positive), angiosarcoma (CD34, CD31, ERG and WT-1 diffusely positive), dermatofibrosarcoma protuberans (usually CD34 positive), and several histiocytic neoplasms (almost every one CD68 positive). P53 overexpression ruled out a postoperative spindle cell nodule and other pseudosarcomatous reactive proliferations. Another lesion in the differential diagnosis, based on its occurrence in the female genital tract, includes a rare entity called *cellular pseudosarcomatous fibroepithelial stromal polyp*.¹⁰ Although plump epithelioid cells and multinucleate cells can be seen in either cellular pseudosarcomatous fibroepithelial stromal polyp or AFX, features like the pattern of growth, the infiltrative margins, the negativity for desmin, and SMA confirm the diagnosis of AFX.

This is the first reported case, to our knowledge, of AFX associated with dVIN and lichen sclerosis. It is well known that lichen sclerosis is related with increased risk of dVIN and cancer. The pathogenesis include mutations in TP53 and inflammation-associated damage to DNA (such as oxidative damage) that influence cell survival, growth, proliferation, and differentiation.¹¹ Therefore, we believe that the dysfunction of tumor suppressor gene *p53* and the chronic inflammation of lichen

may contribute to the development of AFX in our patient.

CONCLUSION

Despite its pleomorphic histology, AFX has a biologically benign behavior, with possibility of recurrence and no risk of distant metastasis.⁶⁻⁹ It is extremely important that clinicians are aware of this rare entity to avoid inappropriately aggressive treatments. Interestingly, in our case, AFX was combined with vulvar squamous intraepithelial neoplasia and lichen sclerosis, a previously unrecognized association.

REFERENCES

1. Helwig EB. Atypical fibroxanthoma: proceedings of the 18th Annual Tumour Seminar San Antonio Society of Pathologists, 1961. *Tex State J Med*. 1963;59:664-667.
2. Fretzin DF, Helwig EB. Atypical fibroxanthoma of the skin: a clinicopathologic study of 140 cases. *Cancer*. 1973;31(6):1541-1552.
3. Helwig EB, May D. Atypical fibroxanthoma of the skin with metastasis. *Cancer*. 1986;57:368-376.
4. Dei Tos AP, Maestro R, Doglioni C, et al. Ultraviolet-induced p53 mutations in atypical fibroxanthoma. *Am J Pathol*. 1994;145(1):11-17.
5. Sakamoto A, Oda Y, Itakura E, et al. Immunoexpression of ultraviolet photoproducts and p53 mutation analysis in atypical fibroxanthoma and superficial malignant fibrous histiocytoma. *Mod Pathol*. 2001;14(6):581-588.
6. Kaddu S, McMenamin ME, Fletcher CD. Atypical fibrous histiocytoma of the skin: clinicopathologic analysis of 59 cases with evidence of infrequent metastasis. *Am J Surg Pathol*. 2002;26:35.
7. Luzar B, Calonje E. Morphological and immunohistochemical characteristics of atypical fibroxanthoma with a special emphasis on potential diagnostic pitfalls: a review. *J Cutan Pathol*. 2010;37:301-309.
8. Beer TW. Atypical fibroxanthoma: a histological and immunohistochemical review of 171 cases. *Am J Dermatopathol*. 2010;32(6):533-540.
9. Brenn T. Pleomorphic dermal neoplasms: a review. *Adv Anat Pathol*. 2014;21(2):108-130. 13.
10. Nucci MR, Young RH, Fletcher CD. Cellular pseudosarcomatous fibroepithelial stromal polyps of the lower female genital tract: an underrecognized lesion often misdiagnosed as sarcoma. *Am J Surg Pathol*. 2000;24(2):231-240.
11. Trietsch MD, Nooij LS, Gaarenstroom KN, van Poelgeest MIE. Genetic and epigenetic changes in vulvar squamous cell carcinoma and its precursor lesions: A review of the current literature. *Gynecol Oncol*. 2015;136(1):143-157.