

Alma Mater Studiorum Università di Bologna
Archivio istituzionale della ricerca

Inoculation of specific pathogen-free chickens with an infectious bursal disease virus of the ITA genotype (G6) leads to a high and persistent viral load in lymphoid tissues and to a delayed antiviral response

This is the final peer-reviewed author's accepted manuscript (postprint) of the following publication:

Published Version:

Inoculation of specific pathogen-free chickens with an infectious bursal disease virus of the ITA genotype (G6) leads to a high and persistent viral load in lymphoid tissues and to a delayed antiviral response /
Silveira F.; Felice V.; Franzo G.; Mescolini G.; Catelli E.; Cecchinato M.; Berto G.; Listorti V.; Lupini C.. - In:
VETERINARY MICROBIOLOGY. - ISSN 0378-1135. - STAMPA. - 235:(2019), pp. 136-142.
[10.1016/j.vetmic.2019.06.014]

Availability:

This version is available at: <https://hdl.handle.net/11585/722516> since: 2020-11-25

Published:

DOI: <http://doi.org/10.1016/j.vetmic.2019.06.014>

Terms of use:

Some rights reserved. The terms and conditions for the reuse of this version of the manuscript are specified in the publishing policy. For all terms of use and more information see the publisher's website.

This item was downloaded from IRIS Università di Bologna (<https://cris.unibo.it/>).
When citing, please refer to the published version.

(Article begins on next page)

This is the final peer-reviewed accepted manuscript of:

Inoculation of specific pathogen-free chickens with an Infectious bursal disease virus of the ITA genotype (G6) leads to a high and persistent viral load in lymphoid tissues and to a delayed antiviral response

Flavio Silveira, Viviana Felice, Giovanni Franzo, Giulia Mescolini, Elena Catelli, Mattia Cecchinato, Giacomo Berto, Valeria Listorti, Caterina Lupini

The final published version is available online at: <https://doi.org/10.1016/j.vetmic.2019.06.014>

Rights / License:

The terms and conditions for the reuse of this version of the manuscript are specified in the publishing policy. For all terms of use and more information see the publisher's website.

This item was downloaded from IRIS Università di Bologna (<https://cris.unibo.it/>)

When citing, please refer to the published version.

Inoculation of specific pathogen-free chickens with an Infectious bursal disease virus of the ITA genotype (G6) leads to a high and persistent viral load in lymphoid tissues and to a delayed antiviral response

Flavio Silveira^a, Viviana Felice^a, Giovanni Franzo^b, Giulia Mescolini^{a*}, Elena Catelli^a, Mattia Cecchinato^b, Giacomo Berto^c, Valeria Listorti^a, Caterina Lupini^a

^a Department of Veterinary Medical Sciences, University of Bologna, Via Tolara di Sopra, 50, 40064, Ozzano dell'Emilia (BO), Italy

^b Department of Animal Medicine, Production and Health, University of Padua, Viale dell'Università, 16, 35020, Legnaro (PD), Italy

^c CEVA Salute Animale, Viale Bartolomeo Colleoni, 15, 20864, Agrate Brianza (MB), Italy

*corresponding author: Giulia Mescolini, Department of Veterinary Medical Sciences - University of Bologna, Via Tolara di Sopra, 50; 40064 – Ozzano dell'Emilia (BO) ITALY; Phone +39 051 2097560; e-mail: giulia.mescolini3@unibo.it

Abstract

Infectious Bursal Disease Virus (IBDV) of the ITA genotype (G6) was shown to have peculiar molecular characteristics and, despite a subclinical course, aggressiveness towards lymphoid tissues after experimental infection of specific-pathogen-free (SPF) chickens. The aim of the present study was to evaluate and compare with a Classical IBDV strain, ITA IBDV distribution and persistence in various tissues (bursa of Fabricius, spleen, thymus, bone marrow, caecal tonsils, Harderian gland, kidney, liver and proventriculus), its cloacal shedding and the involvement of gut TLR-3 in duodenum tissues. The 35-day-old SPF chickens were experimentally infected and sampled up to 28 days post infection (dpi) for IBDV detection and TLR-3 quantification by qRT-PCR. The ITA IBDV strain was detected in lymphoid and most non-lymphoid tissues up to the end of the trial, with higher loads compared to the Classical IBDV. Most of those differences were found during the first 2 weeks post-infection. Notably, bone marrow and caecal tonsils presented higher viral loads until 28 dpi, allowing to speculate that these organs may serve as non-bursal lymphoid tissues supporting virus replication. Differences in relative TLR-3 gene expression between ITA IBDV-infected birds and Classical-IBDV infected ones were observed at 4, 14 and 21 dpi, being initially higher in Classical group and later in ITA group. Our results provide new insights into IBDV pathogenesis showing that IBDV of ITA genotype leads to a high and persistent viral load in lymphoid tissues and to a delayed antiviral response.

Keywords: Infectious Bursal Disease Virus, virus distribution, qRT-PCR, TLR-3

Highlights

Significant higher load of ITA IBDV in all the tested tissues than classical IBDV;

Delayed TLR-3 expression in ITA IBDV group;

Bone marrow and caecal tonsils may support ITA IBDV replication outside the bursa.

Introduction

Infectious bursal disease (IBD) is a highly contagious immunosuppressive disease of chickens caused by an RNA virus (IBDV) belonging to the family *Birnaviridae*, genus *Avibirnavirus* (Delmas et al., 2019). The IBDV gains entry via the oral route and targets immunoglobulin M-bearing B lymphocytes of the bursa of Fabricius which is the main target organ of the virus (Sharma et al., 2000). Although infection can be clinical or subclinical, both cause immunosuppression (Etteradossi & Saif, 2008). In addition to B cells, macrophages are also susceptible to infection and are hypothesised to be responsible for dissemination of IBDV from the digestive tract to the bursa and other peripheral organs (Kaufer and Weiss, 1980; Khatri et al., 2005; Palmquist et al., 2006). Viral tissue distribution, load and persistence of different strains are often correlated to the degree of IBDV virulence (Tanimura et al., 1995; Tsukamoto et al., 1995; Elankumaran et al., 2002; Rautenshlein et al., 2003; Abdul et al., 2013; Jayasundara et al., 2017, 2018). In addition to the bursa, IBDV presence has been reported in other lymphoid organs or tissues, such as spleen, thymus and caecal tonsils and, albeit to a lesser degree, in non-lymphoid organs. (Elankumaran et al., 2002; Abdul et al., 2013). Highly pathogenic strains have been proven to grow more quickly and reach higher titres in extra-bursal lymphoid tissues compared to moderate pathogenic strains (Tanimura et al., 1995; Tsukamoto et al., 1995; Rautenshlein et al., 2003).

Toll-like receptors (TLRs) are host cell receptors involved in the recognition of foreign molecules, including viral ones, and subsequently induce an antiviral response, enabling pathogen-associated molecular patterns (Guo et al., 2012). In particular, TLR-3 receptors detect double-stranded RNA derived from viral replication into target cells and their expression increase in the bursa has been

correlated with IBDV virulence (Raj et al., 2011; Rauf et al. 2011; Guo et al., 2012; He et al., 2017). Recently, Li et al. (2018) have focused on the modification occurring in gut-associated lymphoid tissue (GALT) after IBDV experimental infection, confirming its importance in IBDV immune-pathogenesis (Rautenschlein et al., 2007; Wang et al., 2009; Carballeda et al., 2011). However, the importance of TLRs in chicken GALT, after experimental IBDV infection, has not yet been fully investigated.

In 2011, a new genotype of IBDV, named ITA, was detected in IBD-live vaccinated Italian broilers (Lupini et al., 2016) and a recently proposed classification for IBDV into genogroups placed the ITA genotype into genogroup 6 (G6) (Michel & Jackwood, 2017). Full genome characterisation showed that the ITA-IBDV genotype has peculiar molecular characteristics in key positions that may be virtually associated with major changes in virus properties (Felice et al., 2017). Experimental infection of specific-pathogen-free (SPF) chickens with a strain belonging to the ITA genotype has revealed its aggressiveness towards lymphoid tissues, despite a subclinical course (Lupini et al., 2017).

The present study aimed to evaluate, via quantitative reverse transcription PCR (qRT-PCR), the tissue distribution, persistence and cloacal shedding of IBDV following experimental infection of SPF chickens with an ITA genotype strain. Furthermore, in order to preliminary investigate the involvement of the IBDV gut TLRs, TLR-3 was quantified in the duodenum via qRT-PCR.

MATERIAL AND METHODS

SPF chickens and viruses

SPF chickens were used and housed in HEPA-filtered isolators for the duration of the study and food and water were given *ad libitum*. The trial was performed in agreement with national regulations on animal experiments and animal welfare, according to authorization N°635/2015-PR, obtained by the Italian Ministry of Health.

Two isolates of IBDV were used in this study, named, according with the new nomenclature proposed by Jackwood et al., (2018) IBDV 1/chicken/Italy/1829/11/(G6) (ITA genotype, genogroup 6) and IBDV 1/chicken/Italy/24II/12/(G1a) (genogroup 1a). The virus IBDV 1/chicken/Italy/24II/12/(G1a) was used for comparative purposes as belonging to Classical genogroup. Virus isolation and titration were performed in SPF embryonated eggs as previously described (Senne, 2008) and titres were calculated according to the method of Reed and Muench (1938). Briefly, virus isolation was obtained from bursal homogenates that tested positive for IBDV ITA or Classical genotypes by RT-PCR and sequencing (Jackwood et al., 2018). Inocula were prepared as a 20% (weight/volume) suspension of positive bursae in minimal essential medium (MEM) containing antibiotics and antimycotics (penicillin, streptomycin and amphotericin B; Applied Biosystems, CA, USA). The supernatant (0.2 ml/egg) was used to inoculate ten 12-day-old SPF chicken embryonated eggs via the chorioallantoic membrane (CAM) route. The eggs were incubated at 37.7 °C until embryo death was recorded, or up to 7 days post-inoculation. From the eggs suspected of being infected, due to embryo death or the presence of embryo lesions, the CAMs were aseptically harvested, homogenised, pooled and prepared as 20% (w/v) suspensions. IBDV isolation was confirmed by RT-PCR (Jackwood et al., 2008).

Afterwards, viruses were titrated by inoculation of 10-fold serial dilutions of the viral suspensions in SPF eggs as previously described and at 7 days post-inoculation the number of infected or dead eggs were recorded and used for the calculation of the fifty per cent eggs infectious dose (EID₅₀) according to the method of Reed and Muench (1938).

Viral stocks were tested by PCR to exclude contamination with avian adenovirus (Raue & Hess, 1998) and chicken anemia virus (Imai et al., 1998).

Virus inoculation and sampling

Birds were divided at hatch into three groups: ITA-IBDV group (30 birds), G1a-IBDV group (30 birds) and negative control group (18 birds) and housed in separate poultry isolators. At 35 days of age, groups ITA-IBDV and G1a-IBDV were orally inoculated with 10^{4.5} EID₅₀ of IBDV 1/Italy/1829/11/(G6) or IBDV 1/Italy/24II/12/(G1a) strains, respectively. The control group received sterile PBS.

At 2, 4, 7, 14, 21 and 28-days post inoculation (dpi), five birds from ITA-IBDV and G1a-IBDV groups and three birds of the control group were humanely sacrificed. Cloacal swabs and tissue samples of bursa of Fabricious, spleen, thymus, bone marrow, caecal tonsils, Harderian gland, kidney, liver and proventriculus, were aseptically collected and stored for subsequent IBDV detection and quantification by qRT-PCR. Furthermore, at 2, 4, 7, 14 and 21 dpi a piece of 5 cm of the medium region of the duodenum was collected for relative quantification of TLR-3 gene expression by qRT-PCR.

Samples processing

After sampling, the cloacal swabs were dried under laminar flow cabinet for 30 min. For elution each swab was dipped in a tube containing 250 µl of PBS and centrifuged at 4,500 rpm for 5 minutes at +4 °C. The swab was then removed from the tube and the eluted was stored at -80°C until RNA extraction.

Tissue samples were weighed, and, to obtain a 10% suspension weight/volume, sterile PBS was added in accordance with the following formula: $\text{PBS (ml)} = \text{weight of the tissue (g)} \times 9$. Tissues were homogenized using T10 basic ULTRA-TURRAX® (IKA®-Werke GmbH & Co. KG, Staufen, Germany) supplied with sterile disposable plastic probes to prevent sample-to-sample cross-contamination. The homogenized tissues were centrifuged at 2,000 rpm for 15 minutes at +4 °C and the supernatant was collected and used for RNA extraction.

Total RNA extraction

RNA was extracted from 200 µl of supernatant or eluate, using the High Pure RNA Isolation Kit (Roche Diagnostic, Marnes La Coquette, France) according to the manufacturer's instructions.

qRT-PCR for IBDV

For IBDV detection and quantification, samples were tested in duplicates using two different qRT- PCR protocols, developed to specifically detect and quantify the genomes of IBDV 1/Italy/1829/11/(G6) or IBDV 1/Italy/24II/12/(G1) strains. Primers and probes were designed (Table 1) on the sequences of the variable region of VP2 gene. The assay was performed using SuperScript® III Platinum® One-Step qRT-PCR Kit (Invitrogen™, Carlsbad, CA, USA) on LightCycler® Nano Instrument (Roche, Basel, Switzerland) following the manufacturer's instructions. The qRT-PCR thermal profile was: 50 °C for 15 min, 95 °C for 2 min followed by 45 cycles of 95 °C for 15 sec, and 60 °C for 30 sec. The assay was validated using titrated virus

suspensions ($10^{5.4}$ EID₅₀/mL for IBDV 1/Italy/24II/12/(G1a) strain, or $10^{5.2}$ EID₅₀/mL for IBDV 1/Italy/1829/11/(G6) strain). The qRT-PCR limit of detection (LoD₅₀) was evaluated using serial 10-fold virus dilutions in negative matrices, performed in quadruplicate, ranging from the undiluted virus to a final 10^{-7} dilution. LoD₅₀ was defined as the lowest viral amount detectable in at least 50% of the replicates. LoD₅₀ was $10^{0.54}$ EID₅₀/mL and $10^{0.52}$ EID₅₀/mL for Classical and ITA strains respectively. Standard curves generated for each titrated IBDV strain were obtained and used for quantification by fitting a linear regression relating C_p values and viral titers expressed as EID₅₀/mL. Additionally, the curves allowed to evaluate reaction efficiencies, which were proven to be 92% (IBDV-Classical) and 103% (IBDV-ITA), and the coefficient of determination resulted to be higher than 0.97 for both strains.

qRT-PCR for relative quantification of TLR-3 gene expression

For quantification of TLR-3 gene expression, RT was carried out using SuperScript™ III Reverse Transcriptase (Invitrogen, Carlsbad, California, US) in a 10 µl final volume as recommended by the manufacturer. Briefly, 0.5 µl of Oligo(dT)₂₀ primer (50 µM) (Invitrogen, Carlsbad, California, US), 0.5 µl of dNTP (10 mM), 3 µl of nuclease-free water and 2.5 µl of RNA were incubated at 65 °C for 5 minutes and on ice for 1 minute. A mix composed by 2 µl of 5X first strand buffer, 0.5 µl (0.1 M) DTT, 0.5 µl of 40 U/µl RNaseOUT™ Recombinant Ribonuclease Inhibitor (Invitrogen, Carlsbad, California, US) and 0.5 µl of SuperScript™ III RT (200 U/µl) was then added to each sample. The RT mixture was incubated at 50°C for 30 min. The RT was inactivated by heating at 70°C for 15 minutes.

qPCR was performed on a LightCycler® nano system (Roche, Basel, Switzerland) using the QuantiTect SYBR® Green PCR Kit (Qiagen, Hilden, Germania) in order to quantify TLR-3 (target

gene) and Beta-Actin (housekeeping gene). The amplification was performed in a total volume of 10 µl, containing 5 µl of SYBR Green PCR Mix, 0.5 µl of forward primer and reverse primer (10µM), 2 µl of water and 2 µl of c-DNA template. The primers sequences were TLR2-for (5'-GCCGCAGCATAGCATCATAC-3') and TLR2-rev (5'-TGAGTGAGGTGACAGCAAGG-3') (Raj et al., 2011), for TLR-3 quantification, and ActinF (5'-GCACCACACTTTCTACAATGAG-3') and ActinR (5'-ACGACCAGAGGCATACAGG-3') for Beta-Actin quantification. For each sample, specific target gene qPCR was performed in duplicate in independent wells. The efficiency of both qPCR was estimated using a 10-fold sample dilution in biology-grade water and used to calculate efficiency-corrected Cq values, which allowed to analyze the relative gene expression calculating the ratio between the average TLR-3 and Beta-Actin quantity. All analysis were performed using the LightCycler®nano Software V1.1 (Roche, Basel, Switzerland).

Statistical analysis

Count of positive samples among different groups and tissues were analyzed using Fisher exact test. The viral genome quantity means were transformed to Log₁₀, and then the non-parametric Wilcoxon test was performed (SPSS, IBM) to assay statistical differences in RNA loads between groups and time points. For TLR3 the Wilcoxon signed-rank test for independent samples were performed to assess the difference between uninfected and infected groups. For all tests, the significance level was set to $p < 0.05$.

RESULTS

Detection and quantification of IBDV by qRT-PCR

The results of IBDV detection in samples collected from birds of the ITA-IBDV or G1a-IBDV groups are reported in Table 2. The IBDV RNA was not found in any sample from the birds of the control group.

Lymphoid tissues

Bursa of Fabricius. No statistically significant differences between virus-inoculated groups were found in the number of bursa IBDV-positive birds per days of sampling (Table 2). Quantification of viral RNA in bursal tissues showed that at 4 and 7 dpi, the mean of the RNA load in the ITA-IBDV group was significantly higher ($p < 0.05$) than the mean RNA load in the G1a-IBDV group (Fig. 1).

Spleen. At 2 dpi, spleens of virus-inoculated birds were all positive for IBDV (Table 2), although the quantification showed that the ITA-IBDV group had a higher RNA load ($p < 0.05$) compared to the G1a-IBDV group (Fig. 2). At 14 dpi, a higher number of positive birds and a higher viral load ($p < 0.05$) were also observed in the ITA-IBDV group compared to the G1a-IBDV group. At 28 dpi, the G1a-IBDV group showed a higher number of positive birds ($p < 0.05$) compared to the ITA-IBDV group (Table 2), but the viral load was not statistically different between groups (Fig. 2).

Thymus. A significantly higher number of IBDV-positive birds ($p < 0.05$) was observed in the ITA-IBDV group at 14 dpi compared to the G1a-IBDV group. Furthermore, at 2, 4, 7 and 14 dpi, the ITA-IBDV group had a significantly higher RNA load in the thymus ($p < 0.05$) compared to the G1a-IBDV group (Fig. 2).

Bone marrow. In bone marrow, IBDV RNA was more frequently detected, and at a higher load ($p < 0.05$) in the ITA-IBDV group than in the G1a-IBDV group at 2, 4, 7, 14 and 28 dpi (Table 2, Fig. 2).

Caecal tonsils. No statistically significant differences between IBDV-inoculated groups were found in the number of caecal tonsil-positive birds, per day of sampling. Quantification of viral RNA showed that at 14, 21 and 28 dpi, the ITA-IBDV group had a higher mean RNA load in caecal tonsils ($p < 0.05$) compared to the G1a-IBDV group (Fig. 2).

Harderian gland. Only at 2 dpi, the ITA-IBDV group showed a higher RNA load ($p < 0.05$) in Harderian glands compared to the G1a-IBDV group (Fig. 2).

Non-lymphoid tissues

Kidney. A statistically higher number of kidney-positive birds ($p < 0.05$) was observed at 14 dpi in the ITA-IBDV group compared to the G1a-IBDV group. Furthermore, at 4, 7 and 14 dpi, kidneys of the birds of the ITA-IBDV group had a higher RNA load ($p < 0.05$) compared to kidneys of birds of the G1a-IBDV group (Fig. 3).

Liver. Only at 4 dpi, the ITA-IBDV group showed a statistically higher RNA load in the liver ($p < 0.05$) compared to the G1a-IBDV group (Fig. 3).

Proventriculus. At 2, 4 and 28 dpi, the G1a-IBDV group showed a higher number of birds IBDV-positive in the proventriculus ($p < 0.05$) compared to the ITA-IBDV group ($p < 0.05$). At 2 dpi, a statistically higher RNA load ($p < 0.05$) was observed in the proventriculus of birds of the G1a-IBDV group compared to the ones of the ITA-IBDV group (Fig. 3).

Viral shedding

Viral shedding was statistically different between virus-inoculated groups, both in term of the number of positive birds and virus load at 4 dpi ($p < 0.05$), being higher in the G1a-IBDV group (Table 2; Fig. 4).

Relative quantification of TLR-3 gene expression

At 2 dpi, no statistically significant difference was observed among all experimental groups in terms of TLR-3 gene expression (Fig. 5). At 4 dpi TLR-3 expression was significantly higher in the G1a-inoculated group than in the control group. At 14 and 21 dpi, TLR-3 expression was significantly higher in the ITA-IBDV group than in the control group. No significant differences were observed between G1a and ITA groups at any sampling time.

DISCUSSION

The aim of this study was to evaluate, via qRT-PCR, tissue distribution and cloacal shedding of an IBDV strain of the genotype ITA (G6) up to 4 weeks after experimental infection of SPF chickens.

The ITA IBDV strain was detected in lymphoid and most non-lymphoid tissues up to the end of the trial, with the highest viral load in the bursa of Fabricious, the caecal tonsils and the bone marrow. In particular, the bursa of Fabricious has been confirmed to be the most relevant site for IBDV detection (Kauffer and Weiss, 1980). The virus persisted less and at lower titres in non-lymphoid tissues, as previously reported by Abdul et al. (2013).

However, ITA-inoculated birds showed significantly higher viral loads, comparing the Classical (G1a)-inoculated group in all tested tissues, except for the proventriculus. Most part of those differences were found during the first 2 weeks post-infection in the bursa, thymus, bone marrow, caecal tonsils and kidney. Notably, bone marrow and caecal tonsils displayed a higher

viral load until 28 dpi, leading us to infer that these organs may serve as non-bursal lymphoid tissues supporting virus replication in the advanced stage of the viral infection.

The failure of ITA IBDV to be cleared from non-bursal lymphoid tissues, observed in our study, together with the high bone marrow viral load, lends credibility to the hypothesis that a persistent and productive niche for IBDV replication exists in cells of the lymphoid system, probably belonging to the monocyte-macrophage lineage, which has previously been demonstrated to efficiently support *in vivo* and *in vitro* IBDV replication (Bulow and Klasen, 1983; Burkhardt and Müller, 1987; Elankumaran et al., 2002).

Based on previous studies, IBDV infection induces the activation of immune transcriptional patterns, including TLRs, also in the duodenum and the caecal tonsils (Rautenschlein et al., 2007; Carballeda et al., 2011), and their over-expression is correlated with strain virulence (He et al., 2017).

In the present study, there were significant differences in the relative gene expression of TLR-3 in the duodenum of ITA IBDV-infected birds or G1a IBDV-infected birds, compared with the control birds, at 4, 14 and 21 dpi, being initially higher in the G1a group and later in the ITA group. The delay in the antiviral response in the ITA IBDV-inoculated birds could be adduced as an explanation for the earlier and more severe bursal atrophy observed after ITA IBDV inoculation of SPF birds (Lupini et al., 2017) and for the high overall tissue viral load observed in the present study. An early impairment of the gut mucosal immunity has also been reported during infection with very virulent IBDV strains (Wang et al., 2009). Although TLR-3 has been considered the major pattern recognition receptor after IBDV infection (He et al., 2017), our preliminary results need to be supplemented by evaluating the involvement of other important pro-inflammatory

parameters, such as TLR-7 or other antiviral mediators such as IFN- β or IL-8, proven to be involved in IBDV immune-pathogenesis (Sharma et al., 2000).

The IBDV faecal shedding is short-lasting after infection (Zhao et al., 2013); this is confirmed by our results for both tested viruses, although the cloacal shedding of the ITA IBDV strain is even shorter, with the virus being excreted only in the first 48 hours post-infection.

The emergence of IBDV strains belonging to new genetic lineages is continuously occurring worldwide (Michel and Jackwood, 2017) and those causing subclinical forms can represent a relevant challenge to poultry health, since they can lead, through immunosuppression, to secondary infections and impairment of immune response to vaccinations (Fan et al., 2019).

Our results provide new insights into IBDV pathogenesis, showing that IBDV of the ITA genotype (G6) leads to a high and persistent viral load in lymphoid tissues and to a delayed antiviral response. Moreover, protection conferred by the existing commercial vaccines to ITA IBDV genotype infection is still unknown and needs to be further investigated through *in vivo* cross-protection studies in order to implement efficacious vaccination plans in commercial poultry farms.

REFERENCES

Abdul, R., Murgia, M. V, Rodriguez-Palacios, A., Lee, C.-W., Saif, Y.M., 2013. Persistence and tissue distribution of infectious bursal disease virus in experimentally infected SPF and commercial broiler chickens. Avian Dis. 57, 759–66. doi:10.1637/10448-110812-Reg.1

Bülow, V. Von, Klasen, A., 1983. Effects of avian viruses on cultured chicken bone-marrow-derived macrophages. *Avian Pathol.* 12, 179–198. doi:10.1080/03079458308436162

Burkhardt, E., Müller, H., 1987. Susceptibility of chicken blood lymphoblasts and monocytes to infectious bursal disease virus (IBDV). *Arch. Virol.* 94, 297–303.

Carballeda, J.M., Zoth, S.C., Gómez, E., Gravisaco, M.J., Berinstein, A., 2011. Activation of the immune response against Infectious Bursal Disease Virus after intramuscular inoculation of an intermediate strain. *Immunobiology* 216, 1028–1033. doi:10.1016/j.imbio.2011.03.003

Delmas, B., Attoui, H., Ghosh, S., Malik, Y.S., Mundt, E., Vakharia, V.N., Ictv Report Consortium, 2019. ICTV virus taxonomy profile: Birnaviridae. *J. Gen. Virol.* 100, 5–6. doi:10.1099/jgv.0.001185

Elankumaran, S., Heckert, R.A., Moura, L., 2002. Pathogenesis and tissue distribution of a variant strain of infectious bursal disease virus in commercial broiler chickens. *Avian Dis.* 46, 169–76. doi:10.1637/0005-2086(2002)046[0169:PATDOA]2.0.CO;2

Etteradossi, N. & Y.M., Saif. 2013. Infectious Bursal Disease In Disease of Poultry. Ames, Iowa State Press. pp. 219-246.

Fan, L., Wu, T., Hussain, A., Gao, Y., Zeng, X., Wang, Yulong, Gao, L., Li, K., Wang, Yongqiang, Liu, C., Cui, H., Pan, Q., Zhang, Y., Liu, Y., He, H., Wang, X., Qi, X., 2019. Novel variant strains of infectious bursal disease virus isolated in China. *Vet. Microbiol.* 230, 212–220. doi:10.1016/j.vetmic.2019.01.023

Felice, V., Franzo, G., Catelli, E., Di Francesco, A., Bonci, M., Cecchinato, M., Mescolini, G., Giovanardi, D., Pesente, P., Lupini, C., 2017. Genome sequence analysis of a distinctive Italian infectious bursal disease virus. *Poult. Sci.* 96. doi:10.3382/ps/pex278

Guo, X., Wang, L., Cui, D., Ruan, W., Liu, F., Li, H., 2012. Differential expression of the Toll-like receptor pathway and related genes of chicken bursa after experimental infection with infectious bursa disease virus. *Arch. Virol.* 157, 2189–99. doi:10.1007/s00705-012-1403-y

He, X., Chen, Y., Kang, S., Chen, G., Wei, P., 2017. Differential Regulation of chTLR3 by Infectious Bursal Disease Viruses with Different Virulence In Vitro and In Vivo. *Viral Immunol.* 30, 490–499. doi:10.1089/vim.2016.0134

Imai, K., Mase, M., Yamaguchi, S., Yuasa, N., Nakamura, K., 1998. Detection of chicken anaemia virus DNA from formalin-fixed tissues by polymerase chain reaction. *Res. Vet. Sci.* 64, 205–8.

Jayasundara, J., Walkden-Brown, S., Islam, A., Katz, M., Renz, K., 2018. Tissue distribution, shedding and environmental detection of infectious bursal disease virus genome following infection of meat chickens at two ages. *Aust. Vet. J.* 96, 167–175. doi:10.1111/avj.12691

Jayasundara, J.M.K.G.K., Walkden-Brown, S.W., Katz, M.E., Islam, A.F.M.F., Renz, K.G., McNally, J., Hunt, P.W., 2017. Pathogenicity, tissue distribution, shedding and environmental detection of two strains of IBDV following infection of chickens at 0 and 14 days of age. *Avian Pathol.* 46, 242–255. doi:10.1080/03079457.2016.1248898

Jackwood, D. J., Schat, K. A., Michel, L. O., de Wit, S., 2018 A proposed nomenclature for infectious bursal disease virus isolates. *Avian Pathol.* 47, 576–584. doi: 10.1080/03079457.2018.1506092.

Käufer, I., Weiss, E., 1980. Significance of bursa of Fabricius as target organ in infectious bursal disease of chickens. *Infect. Immun.* 27, 364–7.

Khatri, M., Palmquist, J.M., Cha, R.M., Sharma, J.M., 2005. Infection and activation of bursal macrophages by virulent infectious bursal disease virus. *Virus Res.* 113, 44–50. doi:10.1016/j.virusres.2005.04.014

Li, L., Kubasová, T., Rychlik, I., Hoerr, F.J., Rautenschlein, S., 2018. Infectious bursal disease virus infection leads to changes in the gut associated-lymphoid tissue and the microbiota composition. *PLoS One* 13, e0192066. doi:10.1371/journal.pone.0192066

Lupini, C., Giovanardi, D., Pesente, P., Bonci, M., Felice, V., Rossi, G., Morandini, E., Cecchinato, M., Catelli, E., 2016. A molecular epidemiology study based on VP2 gene sequences reveals that a new genotype of infectious bursal disease virus is dominantly prevalent in Italy. *Avian Pathol.* 45. doi:10.1080/03079457.2016.1165792

Lupini, C., Silveira, F., Felice, V., Berto, G., Franzo, G., Cecchinato, M., Mescolini, G., Catelli, E. 2017. Pathogenicity of a new Italian genotype of infectious bursal disease virus in SPF chickens. XXth World Veterinary Poultry association Congress, Abstract Book. Edinburgh 4-8 September 2017. pp. 212.

Michel, L.O., Jackwood, D.J., 2017. Classification of infectious bursal disease virus into genogroups. *Arch. Virol.* 162, 3661–3670. doi:10.1007/s00705-017-3500-4

OIE (2016) Infectious Bursal Disease. In: *Manual of Diagnostic Tests and Vaccines for Terrestrial Animals* OIE, Paris. Chapter 2.3.12.

Palmquist, J.M., Khatri, M., Cha, R.M., Goddeeris, B.M., Walcheck, B., Sharma, J.M., 2006. In vivo activation of chicken macrophages by infectious bursal disease virus. *Viral Immunol.* 19, 305–15. doi:10.1089/vim.2006.19.305

Raj, G.D., Rajanathan, T.M.C., Kumanan, K., Elankumaran, S., 2011. Changes in the Cytokine and Toll-Like Receptor Gene Expression Following Infection of Indigenous and Commercial Chickens With Infectious bursal disease virus. *Indian J. Virol.* 22, 146–51. doi:10.1007/s13337-011-0053-0

Raue, R., Hess, M., 1998. Hexon based PCRs combined with restriction enzyme analysis for rapid detection and differentiation of fowl adenoviruses and egg drop syndrome virus. *J. Virol. Methods* 73, 211–217. doi:10.1016/S0166-0934(98)00065-2

Rauf, A., Khatri, M., Murgia, M. V, Jung, K., Saif, Y.M., 2011. Differential modulation of cytokine, chemokine and Toll like receptor expression in chickens infected with classical and variant infectious bursal disease virus. *Vet. Res.* 42, 85. doi:10.1186/1297-9716-42-85

Rautenschlein, S., von Samson-Himmelstjerna, G., Haase, C., 2007. A comparison of immune responses to infection with virulent infectious bursal disease virus (IBDV) between specific-pathogen-free chickens infected at 12 and 28 days of age. *Vet. Immunol. Immunopathol.* 115, 251–260. doi:10.1016/j.vetimm.2006.11.002

Rautenschlein, S., Yeh, H.Y., Sharma, J.M., 2003. Comparative immunopathogenesis of mild, intermediate, and virulent strains of classic infectious bursal disease virus. *Avian Dis.* 47, 66–78. doi:10.1637/0005-2086(2003)047[0066:CIOMIA]2.0.CO;2

Reed, D., & Muench, H. 1938. A simple method of estimating fifty percent endpoints. *American Journal of Epidemiology*, 27, 493–497.

Senne, D. A. (2008). Virus propagation in embryonating eggs. In *A Laboratory Manual for the Isolation, Identification and Characterization of Avian Pathogens*. Madison, WI: American Association of Avian Pathologists. pp. 204–208

Sharma, J.M., Kim, I.J., Rautenschlein, S., Yeh, H.Y., 2000. Infectious bursal disease virus of chickens: pathogenesis and immunosuppression. *Dev. Comp. Immunol.* 24, 223–35.

Tanimura, N., Tsukamoto, K., Nakamura, K., Narita, M., Maeda, M., 1995. Association between pathogenicity of infectious bursal disease virus and viral antigen distribution detected by immunohistochemistry. *Avian Dis.* 39, 9–20.

Tsukamoto, K., Tanimura, N., Mase, M., Imai, K., 1995. Comparison of virus replication efficiency in lymphoid tissues among three infectious bursal disease virus strains. *Avian Dis.* 39, 844–52.

Wang, D., Zhou, X., She, R., Xiong, J., Sun, Q., Peng, K., Liu, L., Liu, Y., 2009. Impaired intestinal mucosal immunity in specific-pathogen-free chickens after infection with very virulent infectious bursal disease virus. *Poult. Sci.* 88, 1623–1628. doi:10.3382/ps.2009-00124

Zhao, Y., Aarnink, A.J.A., Cambra-Lopez, M., Fabri, T., 2013. Viral shedding and emission of airborne infectious bursal disease virus from a broiler room. *Br. Poult. Sci.* 54, 87–95. doi:10.1080/00071668.2012.762505

Table 1. Primers and probes designed and used for the detection and the quantification by qRT-PCR of the inoculated IBDV strains.

Primer	Sequence (5'-3')	Position in genome
G1a genotype		
Forward	TGGAGACTATGGGCATCTAC	2715-2734 ^a
Reverse	CGGTATTTCTCGTGTGTTCT	2805-2824 ^a
Probe	FAM-TAGCACTCAATGGGCACCGA-BHQ1	2754-2773 ^a
ITA genotype		
Forward	CTCAGCCTGCCCACATCATA	389-408 ^b
Reverse	CGTTACCCACCTTGTTGGT	549-568 ^b
Probe	HEX-AGGCTTGGWGACCCCATTC-BHQ1	425-444 ^b

^a Based on the sequence of IBDV strain 150127/0.2 (GenBank accession no.: MF969107).

^b Based on the sequence of IBDV strain IBDV/Italy/1829/2011 (GenBank accession no.: KY930929.1).

Table 2. IBDV RNA detection in lymphoid and non-lymphoid tissues, and in swabs collected from virus-inoculated experimental groups.

Sample	2 dpi ^a		4 dpi		7 dpi		14 dpi		21 dpi		28 dpi	
	G1a	ITA	G1a	ITA	G1a	ITA	G1a	ITA	G1a	ITA	G1a	ITA
Lymphoid tissues												
<i>Bursa</i>	5/5 ^b	5/5	5/5	5/5	5/5	5/5	4/5	5/5	4/5	5/5	4/5	4/5
<i>Spleen</i>	5/5	5/5	5/5	3/5	5/5	5/5	1/5*	4/5*	2/5	3/5	5/5*	1/5*
<i>Thymus</i>	4/5	5/5	5/5	5/5	4/5	5/5	1/5*	5/5*	0/5	0/5	2/5	2/5
<i>Bone marrow</i>	4/5	4/5	5/5	5/5	3/5	5/5	3/5	5/5	0/5	3/5	0/5*	5/5*
<i>Caecal tonsils</i>	5/5	4/5	5/5	5/5	5/5	3/5	2/5	4/5	4/5	5/5	3/5	5/5
<i>Harderian gland</i>	3/5	3/5	5/5	3/5	1/5	2/5	2/5	3/5	0/5	1/5	2/5	3/5
Non-lymphoid tissues												
<i>Kidney</i>	5/5	2/5	4/5	4/5	4/5	5/5	0/5*	5/5*	0/5	1/5	1/5	0/5
<i>Liver</i>	5/5	5/5	5/5	4/5	3/5	3/5	3/5	1/5	0/5	0/5	0/5	0/5
<i>Proventriculus</i>	4/5*	0/5*	5/5*	1/5*	1/5	1/5	1/5	0/5	0/5	1/5	4/5*	0/5*
Shedding												
<i>Swabs</i>	5/5	4/5	4/5*	0/5*	3/5	1/5	0/5	0/5	0/5	0/5	0/5	1/5

^a Day post-infection.

^b Number of birds/total birds sampled from which viral RNA was detected.

* Statistically significant difference (p<0.05)

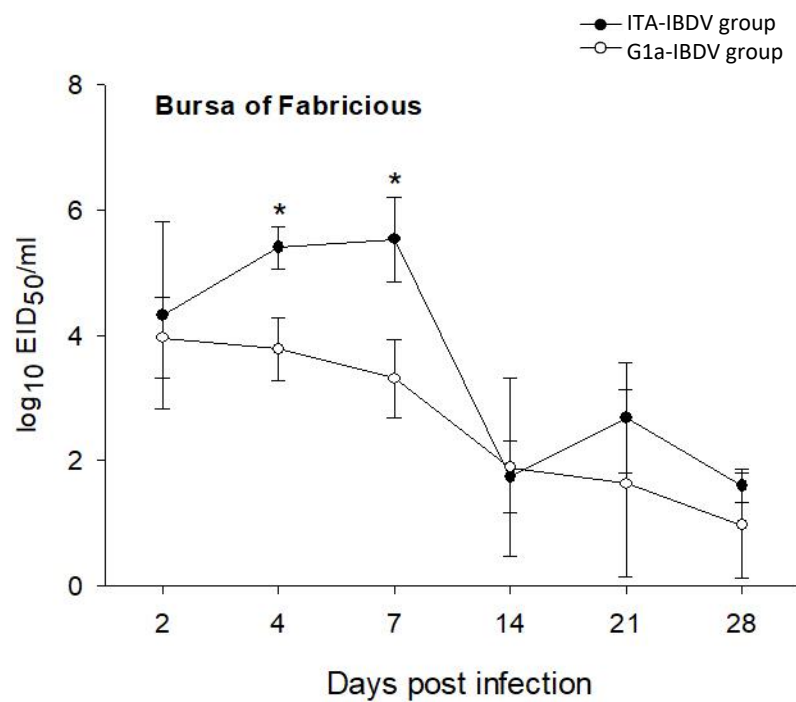


Figure 1. Mean IBDV load in bursa of Fabricious of birds of virus-inoculated experimental groups. The asterisk (*) indicates a statistically significant difference ($p < 0.05$) between groups.

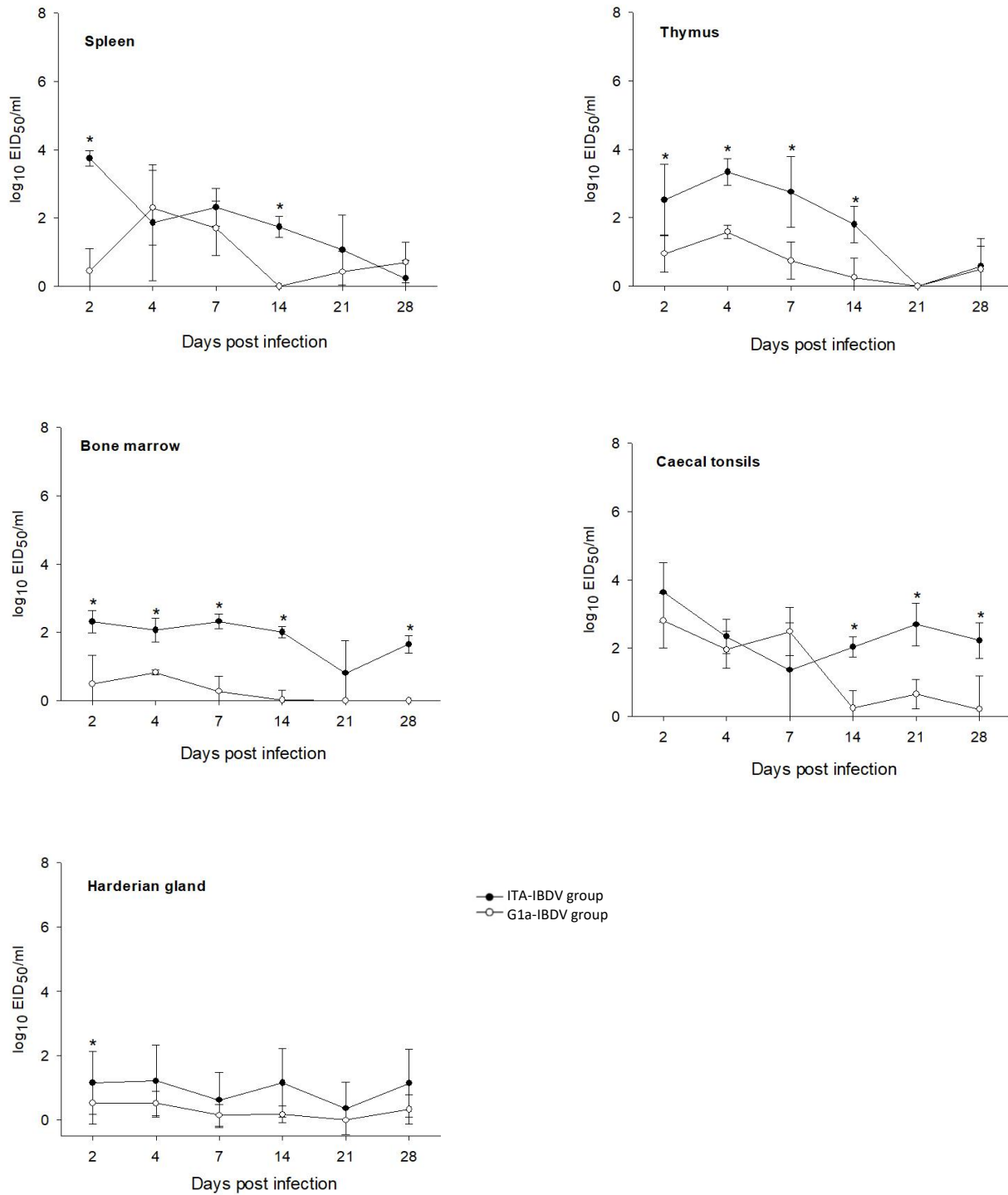


Figure 2. Mean IBDV load in lymphoid tissues of birds of virus-inoculated experimental groups. The asterisk (*) indicates a statistically significant difference ($p < 0.05$) between groups.

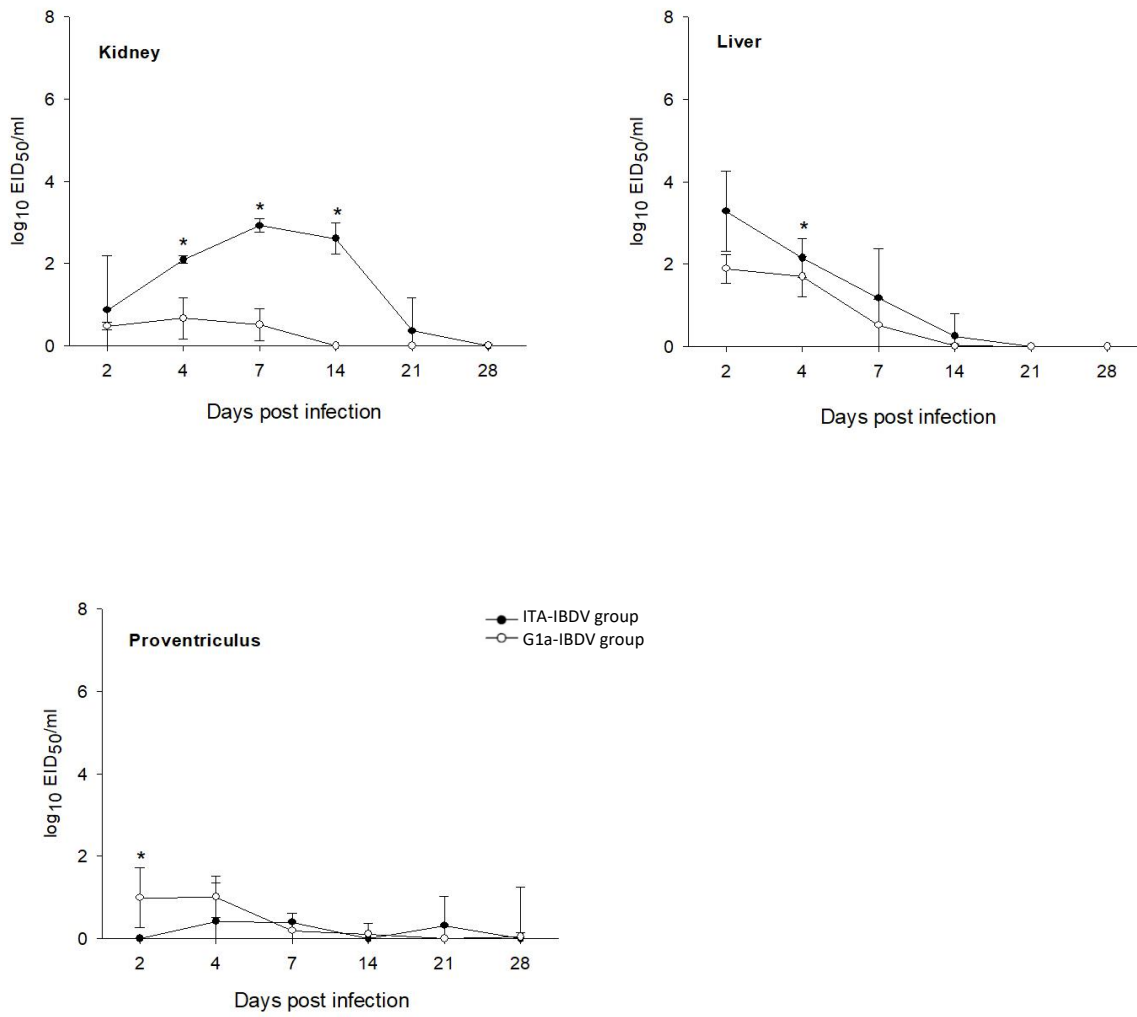


Figure 3. Mean IBDV load in non-lymphoid tissues of birds of virus-inoculated experimental groups. The asterisk (*) indicates a statistically significant difference ($p < 0.05$) between groups.

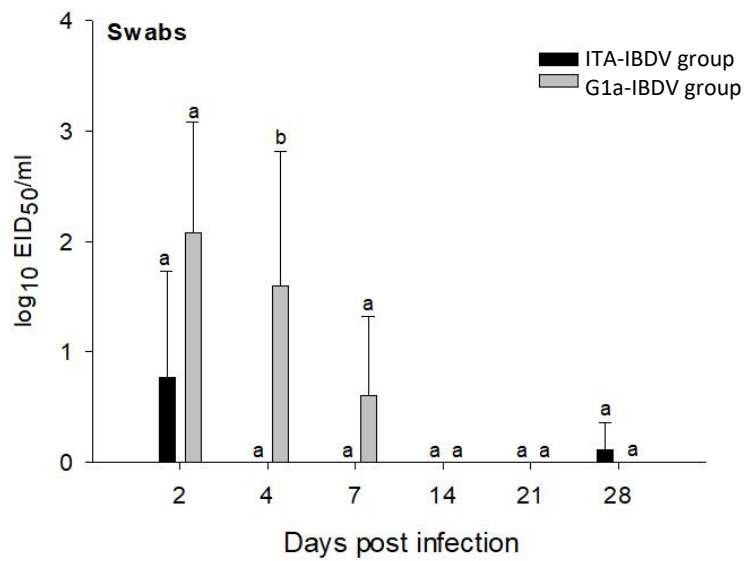


Figure 4. Mean viral shedding in ITA-IBDV or G1a-IBDV inoculated groups.

Different letters indicate statistically significant differences ($p < 0.05$) between groups.

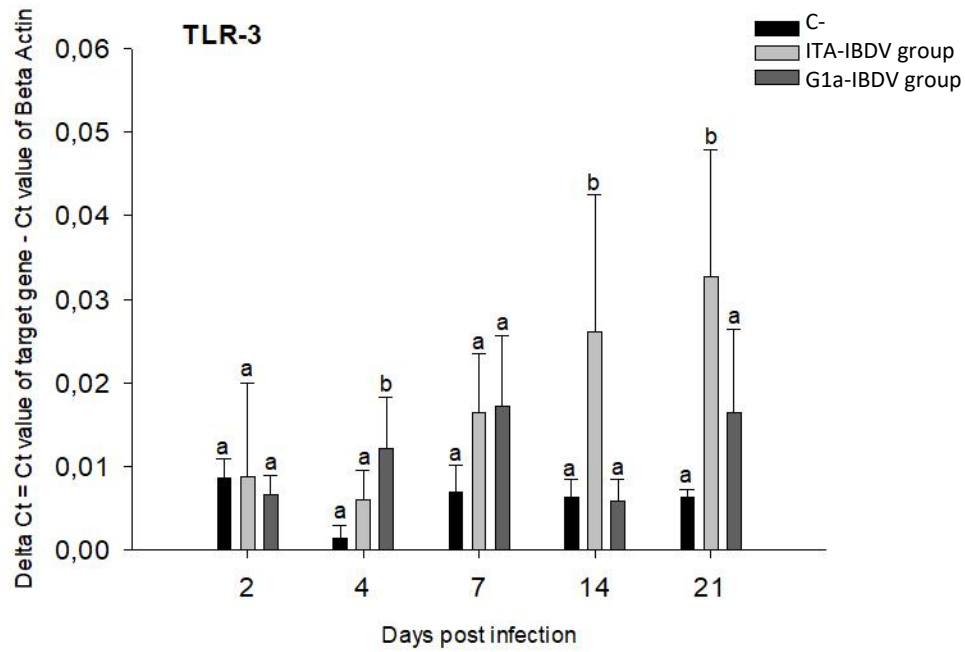


Figure 5. Relative TLR-3 gene expression in duodenum tissues. Different letters indicate statistically significant differences ($p < 0.05$) between groups.