ALMA MATER STUDIORUM
UNIVERSITÀ DI BOLOGNA

ARCHIVIO ISTITUZIONALE
DELLA RICERCA

Alma Mater Studiorum Università di Bologna
Archivio istituzionale della ricerca

Pre-operative management of Pleomorphic and florid lobular carcinoma in situ of the breast: Report of a large multi-institutional series and review of the literature

This is the final peer-reviewed author's accepted manuscript (postprint) of the following publication:

Published Version:
Foschini M.P., Miglio R., Fiore R., Baldovini C., Castellano I., Callagy G., et al. (2019). Pre-operative management of Pleomorphic and florid lobular carcinoma in situ of the breast: Report of a large multi-institutional series and review of the literature. EUROPEAN JOURNAL OF SURGICAL ONCOLOGY, 45(12), 2279-2286 [10.1016/j.ejso.2019.07.011].

Availability:
This version is available at: https://hdl.handle.net/11585/721256 since: 2020-02-04

Published:
DOI: http://doi.org/10.1016/j.ejso.2019.07.011

Terms of use:

Some rights reserved. The terms and conditions for the reuse of this version of the manuscript are specified in the publishing policy. For all terms of use and more information see the publisher's website.

This item was downloaded from IRIS Università di Bologna (https://cris.unibo.it/).
When citing, please refer to the published version.

(Article begins on next page)

12 October 2024

This is the accepted manuscript of:

Foschini MP, Miglio R, Fiore R, Baldovini C, Castellano I, Callagy G, Bianchi S, Kaya H, Amendoeira I, Querzoli P, Poli F, Scatena C, Cordoba A, Pietribiasi F, Kovács A, Faistova H, Cserni G, Quinn C.

Pre-operative management of Pleomorphic and florid lobular carcinoma in situ of the breast: Report of a large multi-institutional series and review of the literature. Eur J Surg Oncol. 2019 Dec;45(12):2279-2286

Final peer reviewed version available at: https://doi.org/10.1016/j.ejso.2019.07.011

Rights / License:

The terms and conditions for the reuse of this version of the manuscript are specified in the publishing policy. For all terms of use and more information see the publisher's website.

This item was downloaded from IRIS Università di Bologna (https://cris.unibo.it/)

When citing, please refer to the published version.

Pre-operative management of Pleomorphic and Florid lobular carcinoma in situ of the breast: Report of a large multi-institutional series and review of the literature.

Maria P. Foschini [1], Rossella Miglio [2], Roberta Fiore [1], Chiara Baldovini [1], Isabella Castellano [3], Grace Callagy [4], Simonetta Bianchi [5], Handan Kaya [6], Isabel Amendoeira [7], Patrizia Querzoli [8], Francesca Poli [9], Cristian Scatena [10], Alicia Cordoba [11], Francesca Pietribiasi [12], Anikó Kovács [13], Hana Faistova [14], Gábor Cserni [15], Cecily Quinn [16].

1) Department of Biomedical and Neuromotor Sciences, University of Bologna, Unit of Anatomic Pathology at Bellaria Hospital, Bologna (Italy). C. Baldovini present address is Anatomic Pathology Unit, Santa Maria delle Croci Hospital, Viale Randi 5, 48121, Ravenna (Italy).mariapia.foschini@unibo.it roberta.fiore@studio.unibo.it; c.baldovini@gmail.com
2) Department of Statistical Sciences, University of Bologna, Via Belle Arti 42, 40100, Bologna, Italy. rossella.miglio@unibo.it
3) Department of Medical Sciences, Pathology Unit, University of Turin, Via Santea 7, 10126, Turin, Italy. isabella.castellano@unito.it
4) Discipline of Pathology, Lambe Institute for Translational Research, NUI Galway, Costello Road, Galway, Ireland. grace.callagy@nuigalway.ie
5) Department of Surgery and Translational Medicine, Section of Pathological Anatomy, Careggi University Hospital, Largo G. Alessandro Brambilla, 3, 50134 Firenze Florence, Italy. Simonetta.bianchi@unifi.it
6) Department of Pathology, Marmara University Hospital, Istanbul, 81190, Turkey. hkaya@marmara.edu.tr
7) Department of Pathology, University Hospital of S. João, Porto and Ipatimup, 4200-319, Porto, Portugal isabelamendoeira@gmail.com
8) Department of Morphology, Surgery and Experimental Medicine, University of Ferrara, Unit of Anatomic Pathology, St Anna University Hospital, Via A. Moro 8, 44124, Ferrara, Italy. Patrizia.querzoli@unife.it
9) Pathology Unit, Ospedale Nuovo "S.Maria della Scaletta", via Montericco 4, 40026 Imola (Bologna)., Italy. f.poli@ausl.imola.bo.it
10) Division of Pathology, Department of Translational Research and New Technologies in Medicine and Surgery, University of Pisa, 56126 Pisa, Italy. Cristian.scatena@unipi.it
11) Department of Pathology Section A, Navarra Health Service, Hospital Complex of Navarra, Irunlarrea 4, 31008, Pamplona, Spain. alicia.cordoba.iturriagagoitia@navarra.es
12) Pathology Division, Santa Croce Hospital, Vicolo Tiziano 5 10024 Moncalieri (TO). pietribiasi.francesca@aslto5.piemonte.it
13) Department of Clinical Pathology, Sahlgrenska University Hospital, Gothenburg, Sweden. aniko.kovacs@vgregion.se
14) The Fingerland Department of Pathology, Charles University Faculty of Medicine and University Hospital Hradec Králové, Sokolská 581, Hradec Králové, 500 03, Czech Republic. chiotcurieux@gmail.com
15) Bacs-Kiskun County Teaching Hospital, Nyiriut 38, Kecskemet, 6000, Hungary and Department of Pathology, University of Szeged, Allomas u. 1, Szeged, 6720, Hungary. csernig@hotmail.com
16) Department of Histopathology, St. Vincent's University Hospital, Dublin, and School of Medicine, University College Dublin, Ireland. cquinn@svhg.ie

Running title: P/F LCIS in pre-operative biopsies.

Corresponding Author

Maria P. Foschini, MD

Anatomic Pathology

Bellaria Hospital

Via Altura 3

40139 Bologna, Italy.

Mail: mariapia.foschini@unibo.it; mariapia.foschini@ausl.bologna.it

Tel. ++39 0516225750; ++ 39 0516225523

Fax ++39 0516225759

Abstract

Background: Pleomorphic and Florid Lobular carcinoma in situ (P/F LCIS) are rare variants of LCIS, the exact nature of which is still debated.

Aim: To collect a large series of P/F LCIS diagnosed on preoperative biopsies and evaluate their association with invasive carcinoma and high grade duct carcinoma in situ (DCIS). Data obtained were compared with those reported in the literature.

Methods: A multi-institutional series of P/F LCIS was retrieved. All cases were diagnosed on pre-operative biopsies, which was followed by an open surgical excision. Data on post-operative histopathology were available. A literature review was performed.

Results: A total of 117 cases were collected; invasive carcinoma and/or DCIS was present in 78/117 cases (66.7%). Seventy cases of P/F LCIS were pure on biopsy and 31 of these showed pathological upgrade in post-surgical specimens. Pre-operative biopsy accuracy was 47/78 (60.3%); pre-operative biopsy underestimation of cancer was 31/78 (39,7.%). In the literature review papers, invasive carcinoma or DCIS was associated with 274 of 418 (65.5%) cases of P/F LCIS. Pre- operative biopsy accuracy was 66% (181/274) whereas pre-operative biopsy underestimation of cancer was 33.9% (93/274).

Conclusions: The data presented here indicate that P/F LCIS is frequently associated with invasive carcinoma or high grade DCIS and that pre-operative biopsy is associated with an underestimation of malignancy. Open surgery is indicated when P/F LCIS is diagnosed pre-operatively.

Key words: Lobular carcinoma in situ, Pleomorphic lobular carcinoma in situ; Florid lobular carcinoma in situ; pre-operative biopsy; breast cancer screening.

Highlights:

- Pleomorphic and lobular carcinoma in situ (P/F LCIS) are associated with invasive carcinoma and / or high nuclear grade in situ duct carcinoma in more than 60% of the cases.
- Pre-operative biopsies of P/F LCIS can frequently under-estimate the presence of invasive carcinoma.
- Open surgery with clear resection margins is recommended in cases of P/F LCIS.

Introduction

Lobular carcinoma in situ (LCIS), classical variant (C-LCIS), is considered a non-obligate precursor of invasive carcinoma[1]. The risk of developing an invasive carcinoma in patients affected by C- LCIS varies from 8 to 10 times relative risk when compared to the general population[2]. When C- LCIS is present in pre-operative biopsies, the risk of upgrading to invasive carcinoma varies from 8 to 40%, greatly dependent on the related mammographic findings[2]. These data suggest that surgical excision of C-LCIS may be necessary only if mammographically detected anomalies are not completely removed during the pre-operative procedures[2]. In addition to C-LCIS, LCIS may present in variant forms, as Florid LCIS (F-LCIS) and Pleomorphic LCIS (P-LCIS), each characterized by enlarged and usually aggregated terminal duct lobular units (TDLUs), filled and distended with neoplastic cells [3,4,5,6]. Necrosis and microcalcifications are often present [3,4,5,6]. F-LCIS and P-LCIS are composed of different types of cells. In P-LCIS, neoplastic cells are larger than those of C- LCIS, showing marked nuclear atypia, and bi- or multinucleated cells are a frequent finding[3]. P- LCIS should be differentiated from high grade ductal in situ carcinoma (DCIS) [3]. E-Cadherin is markedly reduced or absent in P-LCIS and assists the differential diagnosis [3,4,5].

F-LCIS and P-LCIS are relatively rare and current knowledge of their biological potential is based on relatively small series. Data published to present, indicate that these LCIS variants have a close relationship with invasive carcinoma. Nevertheless, due to the scarcity of available data, the AJCC staging manual 8th Edition, does not categorise F-LCIS and P-LCIS as in situ carcinoma [7,8]. Since the introduction of the AJCC cancer staging manual 8th Edition, several papers have been published focusing on the relation between F-LCIS and P-LCIS and invasive carcinoma, all producing data supporting the concept that these variants are high risk lesions [9-14].

At the present time, the management of screen detected F-LCIS and P-LCIS remains controversial.

The purpose of this study was to evaluate pre-operative biopsy accuracy and cancer underestimation in a large multi-institutional series of F- and P- LCIS diagnosed on pre-operative biopsy. Data were retrieved in order to evaluate the association between F-LCIS / P-LCIS and invasive carcinoma and to evaluate the need for surgery following the diagnosis of these LCIS variants on pre-operative biopsy. A literature review is also presented.

Materials and methods.

Cases were retrospectively retrieved from 15 European breast units, all involved in breast screening programs. Most of the participants are part of the European Working Group on Breast Screening Pathology (EWGBSP, http://www.ewgbsp.org/). The Ferrara, Imola and Pisa centres are not part of the EWGBSP, but share with the Bologna centre the same diagnostic protocols.

All the participants agreed on the following definitions of F-LCIS and P-LCIS, established according to previously established criteria [1,3,4,5,6].

Specifically, F-LCIS was diagnosed when it showed: a) markedly expanded ductules or TDLUs with little intervening stroma (Fig. 1A); b) neoplastic cells were not cohesive, showing both type A

(cells with uniform slightly enlarged nuclei) or type B (cells with larger cytoplasm, more atypical nuclei and more prominent nucleoli [1]) of morphology (Fig. 1B); c) necrosis was present.

P-LCIS was diagnosed when it showed: a) markedly expanded ductules or TDLUs with little intervening stroma (Fig. 1C); b) the neoplastic cells showed marked atypia, similar to that observed in high grade DCIS. In addition, in P-LCIS, bi- or multinucleated neoplastic cells were frequently present (fig. 1D). c) necrosis was present.

All the cases showed lack or marked reduction of E-cadherin immunostaining.

Cases were enrolled in the study when the following criteria were fulfilled: A) F-LCIS and P-LCIS presented with screen detected alterations (most often microcalcifications, distortions, dense areas). B) Diagnosis was performed on needle core biopsy or vacuum assisted biopsy. C) Pre-operative diagnosis was followed by open surgical resection and information on post-surgical histology was available. Specifically, surgical excision was offered to all patients after the diagnosis of F/P LCIS. Patients who did not receive surgery for co-morbidities or moved to other Breast Units were not included in the study.

In each case, the following parameters were collected: mammographic findings including site(s) of biopsy and microcalcification extent where appropriate, association with invasive carcinoma or high nuclear grade DCIS in the pre-operative biopsy and / or post-operative specimen. When invasive carcinoma was present, the histological type, grade, TNM parameters and biomarker profile were recorded. The presence of lympho-vascular invasion (LVI) and peri-neural invasion (PNI) was also recorded.

Pre-operative biopsy underestimation of cancer was defined as an invasive carcinoma or DCIS in the excision specimen that was not present on pre-operative biopsy according to Elsheikh and Silverman [6].

Pre-operative biopsy accuracy was defined as the ratio between the number of cancers (DCIS and or invasive carcinoma) detected on pre-operative biopsy and the total number of cancers.

Literature review

A search on PubMed was performed applying the following key words: F-LCIS, P-LCIS, LCIS with necrosis, LCIS with calcifications. Papers were considered eligible for the present review when they reported F-LCIS and or P-LCIS diagnosed on pre-operative biopsies followed by surgical excision. In several studies that included rare cases of F-LCIS and P-LCIS in large series of C-LCIS, only data regarding the F-LCIS and P-LCIS cases were considered.

Statistical analyses

All available variables were first compared between the two groups defined as pure F/P-LCIS on pre-operative biopsies and F/P-LCIS with invasive carcinoma on pre-operative biopsies.

The comparisons were made using the Chi-squared test or Fisher exact test for categorical variables and with t-test for the continuous variable age. A significance level α equal to 0.05 was considered and the p-value reported only if this value was below this predefined level α.

Pre-operative biopsy variables were analysed using logistic regression model only considering pure F/P LCIS in biopsy. The outcome variable is represented by the pathological upgrade. As independent variables, we considered: microcalcification linear extent, biopsy site (quadrant) and age.

Ethical considerations

The present retrospective study did not modify the patients' treatment and was conducted anonymously. The study protocol was approved by the Bologna Ethical Committee (protocol n. 17181).

Results

A total of 117 cases were retrieved, all of which were in adult female patients, aged from 31 to 83 (average 56.7). Invasive carcinoma and/or DCIS was detected in 78/117 of cases (66.7%).

Cases were subdivided as follows:

Group A: Pure F/P-LCIS on pre-operative biopsies (n=70). Pathological upgrade in post-surgical specimens was observed in 31of 70 cases (44.3%) presenting as pure F/P-LCIS, comprising 28 invasive carcinomas and 3 cases of DCIS. One case of P-LCIS that remained 'pure' after open surgery showed positive margins. At the time of surgery, no specific guidelines were available and a 'wait and see' policy was adopted. The patient developed invasive lobular carcinoma (ILC) with axillary metastasis two years after the initial presentation. Therefore, it was included in the present group, among the cases with pathological upgrade.

Group B: F/P-LCIS with invasive carcinoma on pre-operative biopsies (n=47).

Table 1 summarizes and compares the clinical and pathological features of the two groups.

Pre-operative biopsy accuracy, defined as the ratio between the number of cancers (DCIS and/ or invasive carcinoma) detected on pre-operative biopsy and the total number of cancers, was 47/78 (60.3%).

Pre-operative biopsy underestimation of cancer, considered as missing an invasive carcinoma or DCIS on pre-operative biopsy (as defined by Elsheikh and Silverman[6]), was 31/78 (39.7%).

P-LCIS was frequently diagnosed in both groups, with a slight prevalence in Group B, associated with invasive carcinoma in pre-operative biopsy.

Invasive carcinoma histotype was similar in the two groups, with invasive lobular carcinoma being the most frequently diagnosed type. Most of the cases were grade 2 and 3 according to current guidelines [15].

Cases presenting invasive carcinoma in pre-operative biopsies, showed a higher pT category; pT2/pT3 cases were 2/28 (7.4%) and 19/41 (47.5%) respectively in Group A and Group B. Similarly, LVI and PNI were more common in Group B. Axillary lymph node metastases were similar in the two groups (57.1% and 45.5% in Group A and B, respectively. In both groups, most of the invasive carcinomas were positive for oestrogen receptor (ER) and progesterone receptor (PR). HER2 positivity was slightly more frequent in Group B invasive carcinomas.

Data on mammographic presentation were available in 85 cases. In both groups, microcalcification was the most frequent presentation (Group A: 87.1% and Group B: 66.7%).

Microcalcification linear extent was available in 51 cases for the Group A and in 16 cases for Group B and ranged from less than 1 mm to 110 mm. Most cases in both groups showed a limited microcalcification extent, being less than 10 mm in 45% of the cases. By multivariate analysis (table 2), microcalcification extent was the only parameter associated with the risk of pathological upgrade in post-operative specimens. Specifically, as seen in table 3, all the cases presenting microcalcification linear extent greater than 20mm had invasive carcinoma on post-operative specimens.

Differences between P-LCIS and F-LCIS (table 4).

No differences between P-LCIS and F-LCIS were noted with regard to age and type of presentation. Both conditions affected adult female patients, within the same age range, and presented mainly with microcalcification.

When P-LCIS presented in pure form (Group A) on the pre-operative biopsy the risk of subsequent pathological upgrade was higher than that observed for F-PLCIS (50% compared with 37.5% respectively). In addition, the subsequent pathological upgrade was more frequently to an invasive carcinoma for P-LCIS than for F-LCIS (18 invasive carcinomas associated with P-LCIS versus 10 invasive carcinomas associated with F-LCIS).

A higher percentage of cases of P-LCIS compared to F-LCIS were in Group B, presenting with an associated invasive carcinomas on the pre-operative biopsy (43.3% versus 36% respectively).

Histotype and grading of the associated invasive carcinoma, did not differ between P-LCIS and F-LCIS, as most of the tumours were ILC, grade 2/3. Nevertheless, it should be noted that 10 of the 12 cases of P-ILC were associated with P-LCIS. Similarly, the pT categories did not differ between the two groups, with pT2/pT3 cases constituting 28.9% (13/45) and 33.3% (8/24) of the invasive carcinomas associated with P-LCIS and F-LCIS, respectively. Invasive carcinoma associated with P-LCIS showed more frequent LVI (27.9% vs 8.7%) and PNI (18.6% vs 14.3%) compared with F-LCIS, although this difference did not reach statistical significance. In addition, axillary node involvement was more frequent in the upgraded P-LCIS group compared to the upgraded F-LCIS group (45.5% vs. 30.8% respectively).

Hormone receptor profile was similar in the two groups; whereas all of the HER2 positive invasive carcinomas were associated with P-LCIS.

Literature review.

Nineteen publications met the inclusion criteria for this study (table 5)[6, 9-14,16-27]. For each paper, only those cases of F/P LCIS for which both pre-operative biopsy and post-surgical resection data were presented, were retained for review.

In total, 418 cases of F/P LCIS were eligible. Invasive carcinoma and/or DCIS was present in 181 cases on pre-operative biopsy and was detected in 93 (of the remaining 237 cases) on post-surgical specimens. Therefore, a total of 274/418 (65.5%) cases reported invasive carcinoma and/or DCIS associated with F/P LCIS. Pre-operative biopsy accuracy was 66% (181/274) while pre-operative biopsy underestimation of cancer was 33.9% (93/274).

The type and grade of the invasive carcinoma were not reported in all papers. When present, they were consistent with those observed in the present series, being composed mainly of invasive lobular carcinoma, grade 2/3.

Discussion:

F-LCIS and P-LCIS are rare variants of LCIS, the biological nature and significance of which is still debated. Due to the disputed malignant potential of F-LCIS and P-LCIS (AJCC 2018), the present multi-institutional study examined the association with carcinoma at the time of diagnosis (pre-operative or operative). This study, that comprises 117 cases and is the largest reported series to date, observed co-existent invasive carcinoma, at the time of diagnosis of these LCIS variants in 78 of 117 cases (66.7%). Nevertheless, pre-operative biopsy accuracy, defined as the ratio between the number of cancers (DCIS and/or invasive carcinoma) detected on pre-operative biopsy and the total number of cancers was 47/78 (60.3%). Pre-operative biopsy accuracy was slightly better in the literature review, where it reached 66%. Pre-operative biopsy underestimation of cancer, considered as missing an invasive carcinoma or DCIS (as defined by Elsheikh and Silverman[6]), was 39.7%, slightly higher than that reported in the literature where it was limited to 33.9%. In spite of minor differences (see supplementary materials, table 6, for comparison between the present series and the literature review), which are most likely related to the limited number of cases reported and to the lack of uniform diagnostic criteria, all of the data collected, from the literature review and from the present series, indicate that preoperative biopsy is associated with a high risk of underestimation of carcinoma in F-LCIS and P-LCIS presenting through mammographic screening programs.

In the present series, clinical data were analysed in order to identify features that may be predictive of a higher risk of associated invasive carcinoma following a diagnosis of pure F-LCIS and P-LCIS on pre-operative biopsy. Microcalcification linear extent and the histotype P-LCIS were associated with a higher risk of pathological upgrade to carcinoma (DCIS or invasive carcinoma) on surgical excision. Microcalcification linear extent greater than 20 mm was always associated with the presence of invasive carcinoma in this series. Post-surgical pathological upgrade was also higher for

P-L CIS than for F-LCIS (50% vs 37.5%). However, the risk of pathological upgrade is not negligible for limited microcalcification linear extent and for F-LCIS. Carcinoma was present in 33.3% of cases showing microcalcifications linear extent less than 10 mm and pathological upgrade was observed in 37.5% of pure F-LCIS cases. The risk of pathological upgrade observed for P- LCIS and F-LCIS here, is similar to that observed in cases of high nuclear grade DCIS [28].

The most frequent type of invasive carcinoma associated with F-LCIS and P-LCIS is ILC, both classical and pleomorphic variants. ILC is a diffusely infiltrative tumour, which despite the increased sensitivity of modern radiological tools and advances in knowledge, may yield false negative mammography in up to 30% of cases [29]. ILC may be associated with an aggressive clinical course if diagnosed at an advanced stage. It is usually hormone sensitive and prognosis is improved by early detection with survival rates of 90% for T1 and T2 tumours [30]. The pleomorphic variant of ILC (P-ILC) is a more aggressive histotype, with higher tendency to local and metastatic spread [31,32]. In the present series P-ILC was the second most common histotype detected and it was more frequently found in association with P-LCIS (10/12 cases of P-ILC).

Another question often faced during multidisciplinary evaluation of LCIS is the prognostic value of resection margin involvement. Currently available knowledge indicates that in cases of C-LCIS a 'wait and see' policy is adequate even in cases with positive resection margins [33]. On the contrary, very limited data are available on the importance of resection margins involvement by F-LCIS and P-LCIS and recurrences [34]. In the series published by De Brot et al [35], 4 of 7 patients with positive or close margins developed invasive carcinoma, on average, 54 months (range 46-67) after primary surgery. The present series did not include follow-up data. However, one patient, who had positive margins after open excision, developed invasive carcinoma with axillary metastases two years after primary surgery, suggesting that residual P-LCIS and F-LCIS may be associated with disease progression.

The genetic profile of LCIS has been studied in order to establish the possible relation with ILC. C-LCIS and ILC share the same genetic mutations and a clonal relation has been demonstrated [36,37], supporting the concept that C-LCIS is a non-obligate precursor of ILC. P-LCIS and F-LCIS share with C-LCIS the same genetic alterations, most commonly recurrent chromosome gains in 1q and losses at 16q [38,39]. However P-LCIS and F-LCIS present a higher degree of genomic instability, a higher number of DNA copy number modifications and higher gene amplification. The HER2 gene is more frequently amplified and p53 gene more frequently mutated in P-LCIS than in C-LCIS[5,38]. Therefore, the molecular data on P-LCIS and F-LCIS indicate that these latter variants of LCIS constitute more advanced precursor lesions of invasive carcinoma than C-LCIS.

In conclusion, the pathological association between P-LCIS and F-LCIS observed in the present series and in the literature review strongly supports the concept that these LCIS variants should be regarded as high risk precursor lesions of invasive carcinoma. Pre-operative biopsy accuracy in detecting carcinoma associated with P-LCIS and F-LCIS varies from 60.3% to 66%, while the risk of underestimating the presence of carcinoma ranges from 33.9% to 39.7%. Invasive carcinoma associated with P-LCIS and F-LCIS is usually ILC, both classical and P-ILC. The latter is an aggressive type of invasive carcinoma that may carry a poor prognosis. On the basis of these data, in our opinion, F-LCIS or P-LCIS diagnosed on pre-operative biopsy should be followed by open surgical excision for full histological evaluation. The B5a biopsy classification of these entities (in

contrast to the B3 classification of C-LCIS and atypical lobular hyperplasia, i.e. classical lobular neoplasia) is justified. [2,40]

Conflict of interest statement: No conflict of interest to be disclosed.

Acknowledgements: The present study did not have any financial support as it is based on a retrospective case series and literature review.

References

1. Wen HY, Brogi E. Lobular Carcinoma In Situ. Surgical Pathology Clinics 2018:11, 123-145. doi: 10.1016/j.path.2017.09.009.

2. Rageth CJ, O'Flynn EAM, Pinker K, Kubik-Huch RA, Mundinger A, Decker T, Tausch C, Dammann F, Baltzer PA, Fallenberg EM, Foschini MP, Dellas S, Knauer M, Malhaire C, Sonnenschein M, Boos A, Morris E, Varga Z. Second International Consensus Conference on lesions of uncertain malignant potential in the breast (B3 lesions). Breast Cancer Res. Treat. 2019;174, 279–296. doi: 10.1007/s10549-018-05071-1.

3. Ginter PS, D'Alfonso TM. Current Concepts in Diagnosis, Molecular Features, and Management of Lobular Carcinoma In Situ of the Breast With a Discussion of Morphologic Variants. Archives of Pathology & Laboratory Medicine 2017: 141, 1668–1678. doi: 10.5858/arpa.2016- 0421-RA.

4. Sapino A, Frigerio A, Peterse JL, Arisio R, Coluccia C, Bussolati G. Mammographically detected in situ lobular carcinomas of the breast. Virchows Archiv 2000;436, 421–430. PMID: 10881735

5. Shin SJ, Lal A, De Vries S, Suzuki J, Roy R, Hwang ES, Schnitt SJ, Waldman FM, Chen YY. Florid lobular carcinoma in situ: molecular profiling and comparison to classic lobular carcinoma in situ and pleomorphic lobular carcinoma in situ. Human Pathology 2013;44, 1998– 2009. doi: 10.1016/j.humpath.2013.04.004.

6. Elsheikh TM, Silverman JF. Follow-up Surgical Excision Is Indicated When Breast Core Needle Biopsies Show Atypical Lobular Hyperplasia or Lobular Carcinoma In Situ. Am J Surg Pathol 2005; 29: 534-543. PMID: 15767810

7. Amin MB, Edge S, Greene FL. AJCC Cancer Staging Manual. 8th ed. New York: Springer; 2016.

8. Giuliano AE, Connolly JL, Edge SB, Mittendorf EA, Rugo HS, Solin LJ, Weaver DL, Winchester DJ, Hortobagyi GN. Breast cancer-major changes in the American Joint Committee on Cancer eighth edition cancer staging manual. CA Cancer J Clin. 2017;67(4):290–303. doi: 10.3322/caac.21393

9. Fasola CE, Chen JJ, Jensen KC, Allison KH, Horst KC. Characteristics and clinical outcomes of pleomorphic lobular carcinoma in situ of the breast. The Breast Journal 2018;24, 66–69. doi: 10.1111/tbj.12843.

10. Savage JL, Jeffries DO, Noroozian M, Sabel MS, Jorns JM, Helvie MA. Pleomorphic Lobular Carcinoma In Situ: Imaging Features, Upgrade Rate, and Clinical Outcomes. American Journal of Roentgenology2018; 211, 462–467. doi: 10.2214/AJR.17.19088.

11. Desai AA, Jimenez RE, Hoskin TL, Day CN, Boughey JC, Hieken TJ. Treatment Outcomes for Pleomorphic Lobular Carcinoma In Situ of the Breast. Annals of Surgical Oncology 2018;25, 3064–3068. doi: 10.1245/s10434-018-6591-6

12. Nakhlis F, Harrison BT, Giess CS, Lester SC, Hughes KS, Coopey SB, King TA. Evaluating the Rate of Upgrade to Invasive Breast Cancer and/or Ductal Carcinoma In Situ Following a Core Biopsy Diagnosis of Non-classic Lobular Carcinoma In Situ. Annals of Surgical Oncology 2019;26, 55–61. doi: 10.1245/s10434-018-6937-0

13. Shamir ER, Chen YY, Chu T, Pekmezci M, Rabban JT, Krings G. Pleomorphic and Florid Lobular Carcinoma In Situ Variants of the Breast: A Clinicopathologic Study of 85 Cases With and Without Invasive Carcinoma From a Single Academic Center. The American Journal of Surgical Pathology 2019;43, 399–408. doi: 10.1097/PAS.0000000000001191.

14. Masannat YA, Husain E, Roylance R, Heys SD, Carder PJ, Ali H, Maurice Y, Pinder SE, Sawyer E, Shaaban AM. Pleomorphic LCIS what do we know? A UK multicenter audit of pleomorphic lobular carcinoma in situ. The Breast 2018;38, 120–124. doi: 10.1016/j.breast.2017.12.011.

15. Elston CW, Ellis IO. Pathological prognostic factors in breast cancer. I. The value of histological grade in breast cancer: experience from a large study with long-term follow-up. Histopathology 1991;19, 403–410. PMID: 1757079

16. Georgian-Smith D, Lawton TJ. Calcifications of Lobular Carcinoma In Situ of the Breast: Radiologic—Pathologic Correlation. American Journal of Roentgenology 2001;176, 1255- 1259. DOI: 10.2214/ajr.176.5.1761255

17. Mahoney MC, Robinson-Smith TM, Shaughnessy EA. Lobular Neoplasia at 11-Gauge Vacuum-Assisted Stereotactic Biopsy: Correlation with Surgical Excisional Biopsy and Mammographic Follow-Up. American Journal of Roentgenology 2006;187, 949–954. DOI: 10.2214/AJR.05.0710

18. Lavoué V, Graesslin O, Classe JM, Fondrinier E, Angibeau H, Levegue J. Management of lobular neoplasia diagnosed by core needle biopsy: Study of 52 biopsies with follow-up surgical excision. The Breast 2007;16, 533–539. DOI: 10.1016/j.breast.2007.04.005

19. Chivukula M, Haynik DM, Brufsky A, Carter G, Dabbs DJ. Pleomorphic Lobular Carcinoma In Situ (PLCIS) on Breast Core Needle Biopsies: Clinical Significance and Immunoprofile. The Am J Surg Pathol. 2008;32(11):1721-6. doi: 10.1097/PAS.0b013e31817dc3a6.

20. Hwang H, Barke LD, Mendelson EB, Susnik B. Atypical lobular hyperplasia and classic lobular carcinoma in situ in core biopsy specimens: routine excision in not necessary. Modern Pathology 2008;21(10):1208-16. doi: 10.1038/modpathol.2008.134.

21. Carder PJ, Shaaban A, Alizadeh Y, Kumarasuwamy V, Liston JC, Sharma N. Screen-detected pleomorphic lobular carcinoma in situ (PLCIS): risk of concurrent invasive malignancy following a core biopsy diagnosis: Core biopsy diagnosis of pleomorphic lobular carcinoma in situ (PLCIS). Histopathology 2010;57, 472-478. doi: 10.1111/j.1365-2559.2010.03634.x.

22. Sullivan ME, Khan SA, Sullu Y, Schiller C, Susnik B. Lobular Carcinoma In Situ Variants in Breast Cores. Arch Pathol Lab Med 2010; 134:1024-8. doi: 10.1043/2009-0300-OA.1.

23. Lewis JL, Lee DY, Tartter PI. The Significance of Lobular Carcinoma In Situ and Atypical Lobular Hyperplasia of the Breast. Annals of Surgical Oncology 2012;19, 4124–4128. doi: 10.1245/s10434-012-2538-5.

24. Niell B, Specht M, Gerade B, Rafferty E. Is Excisional Biopsy Required After a Breast Core Biopsy Yields Lobular Neoplasia? American Journal of Roentgenology 2012;199, 929–935. DOI: 10.2214/AJR.11.8447

25. Flanagan MR, Rendi MH, Calhoun KE, Anderson BO, Javid SH. Pleomorphic Lobular Carcinoma In Situ: Radiologic–Pathologic Features and Clinical Management. Ann Surg Oncol. 2015;22(13):4263-9. doi: 10.1245/s10434-015-4552-x.

26. Guo T, Wang Y, Shapiro N, Fineberg S. Pleomorphic Lobular Carcinoma in Situ Diagnosed by Breast Core Biopsy: Clinicopathologic Features and Correlation With Subsequent Excision. Clin Breast Cancer 2018;18, e449–e454 doi: 10.1016/j.clbc.2017.10.00

27. Szynglarewicz B, Kasprzak P, Hałoń A, Matkowski R. Lobular carcinoma in situ of the breast – correlation between minimally invasive biopsy and final pathology. Arch Med Sci. 2017 Apr 1;13(3):617-623. doi: 10.5114/aoms.2016.61815.

28. Maxwell AJ, Clements K, Hilton B, Dodwell DJ, Evans A, Kearins O, Pinder SE, Thomas J, Wallis MG, Thompson AM, Sloane Project Steering Group. Risk factors for the development of invasive cancer in unresected ductal carcinoma in situ. Eur J Surg Oncol 2018;44, 429–435. doi: 10.1016/j.ejso.2017.12.007.

29. Porter AJ, Evans EB, Foxcroft LM, Simpson PT, Lakhani SR. Mammographic and ultrasound features of invasive lobular carcinoma of the breast. J Med Imaging Radiat Oncol 2014;58, 1–10. doi: 10.1111/1754-9485.12080.

30. Wang K, Zhu GO, Si Y, Li ZY, Zhang X, Li Hy. Long-Term Survival Differences Between T1-2 Invasive Lobular Breast Cancer and Corresponding Ductal Carcinoma After Breast-Conserving Surgery: A Propensity-Scored Matched Longitudinal Cohort Study. Clin. Breast Cancer 2019;19, e101–e115. doi: 10.1016/j.clbc.2018.10.010

31. Eusebi V, Magalhaes F, Azzopardi JG. Pleomorphic lobular carcinoma of the breast: an aggressive tumor showing apocrine differentiation. Hum Pathol. 1992;23(6):655-62. PMID: 1592388

32. Orvieto E, Maiorano E, Bottiglieri L, Maisonneuve P, Rotmensz N, Galimberti V, Luini A, Brenelli F, Gatti G, Viale G. Clinicopathologic characteristics of invasive lobular carcinoma of the breast: results of an analysis of 530 cases from a single institution. Cancer 2008;113, 1511–1520. doi: 10.1002/cncr.23811.

33. Ciocca, RM, Li T, Freedman GM., Morrow, M. Presence of lobular carcinoma in situ does not increase local recurrence in patients treated with breast-conserving therapy. Ann. Surg. Oncol. 2008;15, 2263–2271. doi: 10.1245/s10434-008-9960-8.

34. Pieri A, Harvey J, Bundred N. Pleomorphic lobular carcinoma in situ of the breast: Can the evidence guide practice? World J Clin Oncol. 2014; 10;5(3):546-53. doi: 10.5306/wjco.v5.i3.546.

35. De Brot M, Koslow Mautner S, Muhsen S, Andrade VP, Mamtani A, Murray M, Giri D, Sakr RA, Brogi E, King TA. Pleomorphic lobular carcinoma in situ of the breast: a single institution experience with clinical follow-up and centralized pathology review. Breast Cancer Res. Treat. 2017;165, 411–420. doi: 10.1007/s10549-017-4334-1

36. Morandi L, Marucci G, Foschini MP, Cattani MG, Pession A, Riva C, Eusebi V. Genetic similarities and differences between lobular in situ neoplasia (LN) and invasive lobular carcinoma of the breast. Virchows Archiv 2006;449, 14–23. DOI: 10.1007/s00428-006-0192-7

37. Reis-Filho JS, Simpson PT, Jones C, Steele D, Mackay A, Iravani M, Fenwick K, Valgeirsson H, Lambros M, Ashworth A, Palacios J, Schmitt F, Lakhani SR. Pleomorphic lobular carcinoma of the breast: role of comprehensive molecular pathology in characterization of an entity. J. Pathol. 2005;207, 1–13. DOI: 10.1002/path.1806

38. Boldt V, Stacher E, Halbwedl I, Popper H, Hultschig C, Moinfar F, Ullmann R, Tavassoli FA. Positioning of necrotic lobular intraepithelial neoplasias (LIN, grade 3) within the sequence of breast carcinoma progression. Genes Chromosomes Cancer 2010;49, 463–470. DOI: 10.1002/gcc.20756

39. Chen YY, Hwang ES, Roy R, DeVries S, Anderson J, Wa C, Fitzgibbons PL, Jacobs TW, MacGrogan G, Peterse H, Vincent-Salomon A, Tokuyasu T, Schnitt SJ, Waldman FM. Genetic and phenotypic characteristics of pleomorphic lobular carcinoma in situ of the breast. Am. J. Surg. Pathol. 2009;33, 1683–1694. doi: 10.1097/PAS.0b013e3181b18a89.

40. Amendoeira I, Apostolikas N, Bellocq JP, Bianchi S, Boecker W, Borisch B, Bussolati G, Connolly CE, Cserni **G**, Decker T, Dervan P, Drijkoningen M, Ellis IO, Elston CW, Eusebi V, Faverly D, Heikkila P, Holland R, Kerner H, Kulka J, Jacquemier J, Lacerda M, Martinez-Penuela J, De Miguel C, Nordgren H, Peterse JL, Rank F, Regitnig P, Reiner A, Sapino A, Sigal-Zafrani B, Tanous AM, Thorstenson S, Zozaya E, Wells CA; EC Working Group on Breast Screening Pathology. (Wells CA ed). Quality assurance guidelines for pathology. In: Perry N, Broeders M, de Wolf C, Törnberg S, Holland R, von Karsa L (eds.). European guidelines for quality assurance in breast cancer screening and diagnosis. 4th edition. European Comission, Luxemburg, 2006; pp 219- 311.

Table 1: Summary of the cases with comparison between Group A and Group B

		Group A **F/P LCIS** **pure in biopsy**	**Group B** **F/P LCS +** **Invasive ca in biopsy**
Total case Number		70	47
Age (range)		57,4 (36 – 73)	55,7 (31 – 83)
Presentation	Microcalcifications Dense area NA	61/70 9/70 0	24/47 12/47 11/47
Microcalcification linear extent	≤ 1 mm 1-10 mm 10,1-20 mm 20,1-30 mm > 30 mm NA	10/61 17/61 14/61 2/61 6/61 12/61	5/24 6/24 1/24 1/24 3/24 8/24
LCIS type	P F	38 32	29 18
Pathological upgrade		31/70 (44,3%) 28 Invasive carcinoma 3 DCIS	-
DCIS		10/70 (14,3%)	3/47 (6,4%)
Invasive carcinoma type	ILC IC NST P-ILC Ductal-lobular NA	23/28 1/28 3/28 1/28	26/41 12/41 3/41
Invasive	G1	3/28	1/41

carcinoma grade	G2 G3 NA	21/28 3/28 1/28	20/41 19/41 1/41
Invasive carcinoma T size	T1mi T1a T1b T1c T2 T3 NA	5/28 9/28 6/28 5/28 2/28 1/28	2/41 4/41 2/41 13/41 14/41 5/41 1/41
LVI	Positive NA	1/28 2/28	13/41 1/41
PNI	Positive NA	0/28 4/28	11/41 1/41
SN	Positive NA	6/28 2/28	12/40 * (30%)
ALN mets	Positive NA	4/7 2/28	5/11 (45,5%)
Invasive carcinoma ER	Positive NA	24/28 3/28	33/47 Positive 9/47 NA
Invasive carcinoma PR	Positive NA	16/28 4/28	20/47 Positive 10/47 NA
Invasive carcinoma HER-2	Positive NA	3/28 4/28	7/47 5/47

Legend:

LCIS: lobular carcinoma in situ; P: Pleomorphic; F: Florid; N: Number; NA: not available; DCIS; Duct carcinoma in situ; ER: Oestrogen Receptor; PR: Progesterone Receptor; HER2 +: HER 2 evaluated either on immunohistochemistry or on in situ hybridization, according to the ASCO CAP guidelines; ILC: invasive lobular carcinoma; IC NST: invasive carcinoma no special type; LVI: lymphovascular invasion; PNI: peri-neural invasion; G: grade; Mets: metastases.

* One case underwent ALN dissection without prior SN biopsy.

Table 2

Table 2. Multivariate logistic regression model in F/P LCIS pure in biopsy: dependent variable pathological upgrade

Pathological upgrade	Odds Ratio	[95% Conf. Interval]	
Microcalcif Extend			
<=1 (reference)			
1-|10	.861	.117	6.354
10-|20	.530	.062	4.535
20-|30	omitted		
30.01 +	omitted		
Missing	.128	.007	2.392
LCIS			
F (reference)			
P.	1.746	.405	7.530
Quadrant number			
1 (reference)			
2 or more quadrant	8.683	.314	240.133
Quadrant type			
External(reference)			
Retroalveoral	3.608	.337	38.594
Other.	.236	.047	1.194
age	.913	.820	1.016
Intercept.	103.782	.116	93175.31

note: Microcalfication extent over 20mm predicts pathological upgrade perfectly and 11 observation were not been used in the analysis

Table 3: Microcalcification linear extent and risk of post-surgical pathological upgrade in F/P LCIS pure in biopsy

Microcalcification extent	N. cases	N. pathological upgrade	Type of upgrade
≤ 10 mm	28/61 (45.9%)	10/27 (37%)	8 Invasive ca 2 DCIS
10 – 20 mm	14/61 (23%)	5/14 (35,7%)	4 Invasive ca 1 DCIS
20-30 mm	2/61 (3.3%)	2/2 (100%)	2 Invasive ca
> 30 mm	7/61 (11.5%)	7/7 (100%)	7 Invasive ca
Linear extent not available	10/61 (16.4%)	-	-

Table 4: Comparison between P-LCIS and F-LCIS

	P-LCIS	F-LCIS
N of cases	67	50
Age	56,7 (31-83)	56,7 (36-73)
Presentation	46 Microcalcifications 11 Dense area 10 NA	39 Microcalcifications 10 Dense area 1 NA
Group A Pure LCIS in biopsy	38/67 (56,7 %)	32/50 (64%)
Group B Invasive carcinoma in biopsy	29/67 (43,3 %)	18/50 (36%)
Pathological upgrade	19/38 (50%) 18 Invasive carcinoma 1 DCIS	12/32 (37,5%) 10 Invasive carcinoma 2 DCIS
DCIS in surgical resection	5/38 (13,2%)	5/32 (15,6%)
Invasive carcinoma in surgical resection	18/38 (47,4%)	10/32 (31,3%)
Invasive carcinoma type	28/45 ILC 10/45 P-ILC 1/45 IC NST 5/45 Ductal-lobular 1/45 NA	21/24 ILC 2/24 P-ILC 1/24 Ductal-lobular
Invasive carcinoma grade	1/45 G1 24/45 G2 18/45 G3	3/24 G1 17/24 G2 4/24 G3

	2/45 NA	
Invasive carcinoma T size	6/45 T1mi 9/45 T1a 6/45 T1b 10/45 T1c 10/45 T2 3/45 T3 1/45 NA	1/24 T1mi 4/24 T1a 2/24 T1b 8/24 T1c 6/24 T2 2/24 T3 1/24 NA
LVI	12/45 Positive 2/45 NA	2/24 Positive 1/24 NA
PNI	8/45 Positive 2/45 NA	3/24 Positive 3/24 NA
SN	12/48 Positive (25%)#	6/26 Positive (23,1%)#
ALN mets	5/11 Positive (45,5%) 2 NA	4/13 Positive (30,8%) 2 NA
Invasive carcinoma ER	35/46 Positive° (76,1%) 5 NA	22/25 Positive° (88%) 3 NA
Invasive carcinoma PR	24/46 Positive° (52,2%) 6 NA	12/25 Positive° (48%) 4 NA
Invasive carcinoma HER-2 amplified**	10/46 (21,7%) 4 NA	0/25 2 NA

Legend:

LCIS: lobular carcinoma in situ; P: Pleomorphic; F: Florid; N: Number; NA: not available; DCIS; Duct carcinoma in situ; ER: Oestrogen Receptor; PR: Progesterone Receptor; HER2 +: HER 2 evaluated either 3+ on immunohistochemistry or amplified on in situ hybridization, according to the ASCO CAP guidelines; ILC: invasive lobular carcinoma; IC NST: invasive carcinoma no special type; LVI: lymph-vascular invasion; PNI: peri-neural invasion; G: grade; SN: sentinel node.

SN was examined in 5 cases (3 P-LCIS and 2 F-LCIS) of pure LCIS, without invasive component.

° Positivity was considered when more than 1% of the neoplastic cells were stained.

* One case underwent ALN dissection without prior SN biopsy.

** Difference reaching statistical significance (p 0.011).

Table 5: Literature review

Authors	Number of P/F LCIS	IC in pre-op bx	DCIS in pre-op bx	P/F LCIS pure in pre-op bx	Path-Up-grade	IC post-op	DCIS-post op	IC type
Georgian-Smith e Lawton [16]	5	0	0	5	2/5	2	0	ILC 2
Elsheick et al[6]	2	0	0	2	1/2	1	1	IC NST 1
Mahoney et al[17]	2	0	0	2	1/2	1	0	ILC 1
Lavoué et al[18]	10	0	0	10	3/10	3	0	ILC 3
Chivukula et al[19]	12	0	0	12	3/12	3	1	ILC 3
Hwang et al[20]	13	0	0	13	6/13	2	4	ILC 1 NA 1
Carder et al[21]	10	2	0	8	2/8	3	0	ILC 4
Sullivan et al[22]	28	0	0	28	10/28	7	3	ILC 7
Lewis et al[23]	2	0	0	2	0/2	0	0	/
Niell et al[24]	4	0	0	4	4/4	3	1	ILC 2 IC NST 1
Flanagan et al[25]	48	22	5	21	11/21	7	4	ILC 5 IC DL 2
Guo et al[26]	34	9 (micro)	0	25	16/25	16	0	ILC 16
Szynglarewicz et al[27]	5	0	0	5	5/5	5	N.A.	N.A.

Fasola et al[9]	37	17		20	6/20	4	2	ILC 3 P ILC 1
Savage et al[10]	15	0	0	15	4/15	2	2	ILC 2
Desai et al[11]	15	0	0	15	3/15	3	0	N.A.
Nakhlis et al[12]	4	0	0	4	3/4	2	1	N.A.
Shamir et al[13]	85	56	5	24	5/24	4	1	ILC 3 P- ILC 1
Masannat et al[14]	87	65		22	8/22	7	1	N.A.
Total	418	181		237	93/237	75	21 2 N.A.	ILC 51 P ILC 2 IC DL 2 IC NST 2 NA 18

Legend:

DCIS: ductal carcinoma in situ, high grade; LCIS: lobular carcinoma in situ: P: pleomorphic; F: Florid; IC: Invasive carcinoma; ILC: invasive lobular carcinoma; IC NST: invasive carcinoma no special type; DL: invasive carcinoma mixed type, ductal and lobular; NA: not available. Path: pathological; pre-op bx: pre-operative biopsy.

Figure legends:

Figure 1:

A: At low power, F-LCIS is composed of distended acini filled with neoplastic cells, separated by scant stroma. Necrosis is present.

B: At high power, F-LCIS is composed of type A and B neoplastic cells.

C: At low power, P-LCIS architecture is similar to F LCIS, being composed of closely packed, distended acini, filled with neoplastic cells. Necrosis is present.

D: At high power, P-LCIS is composed of more atypical cells, sometimes bi-nucleated (arrow).

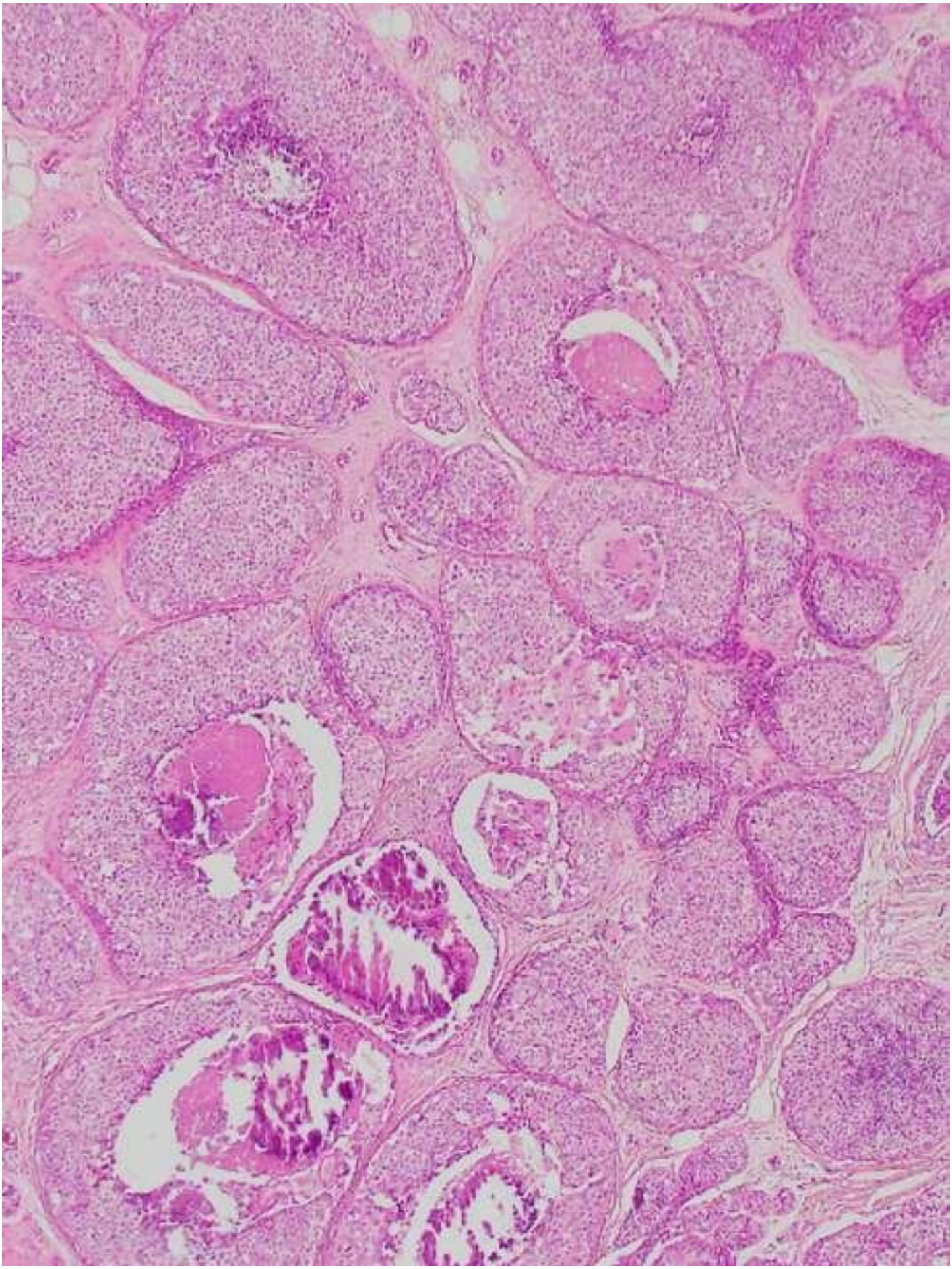

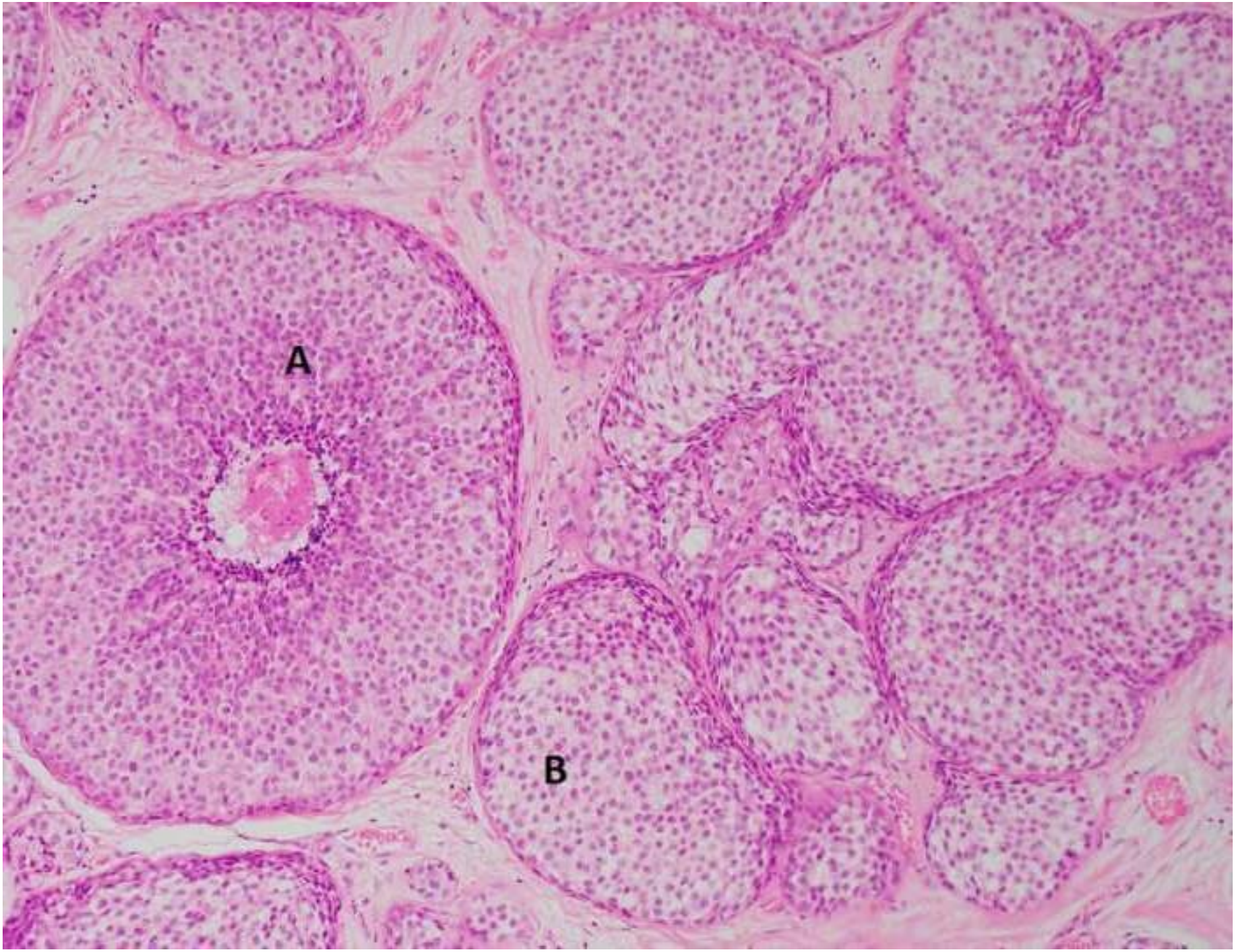
A
B

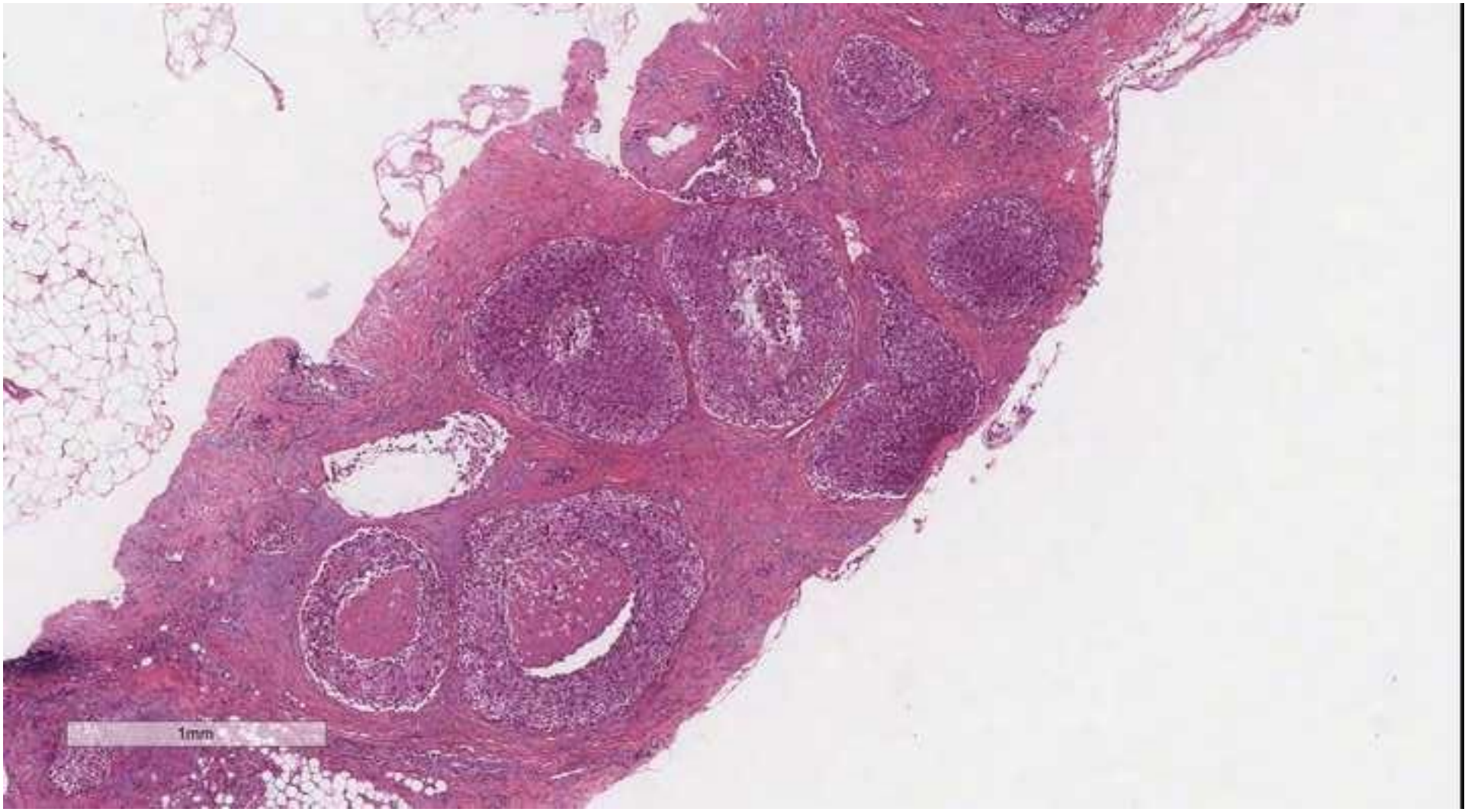
1mm

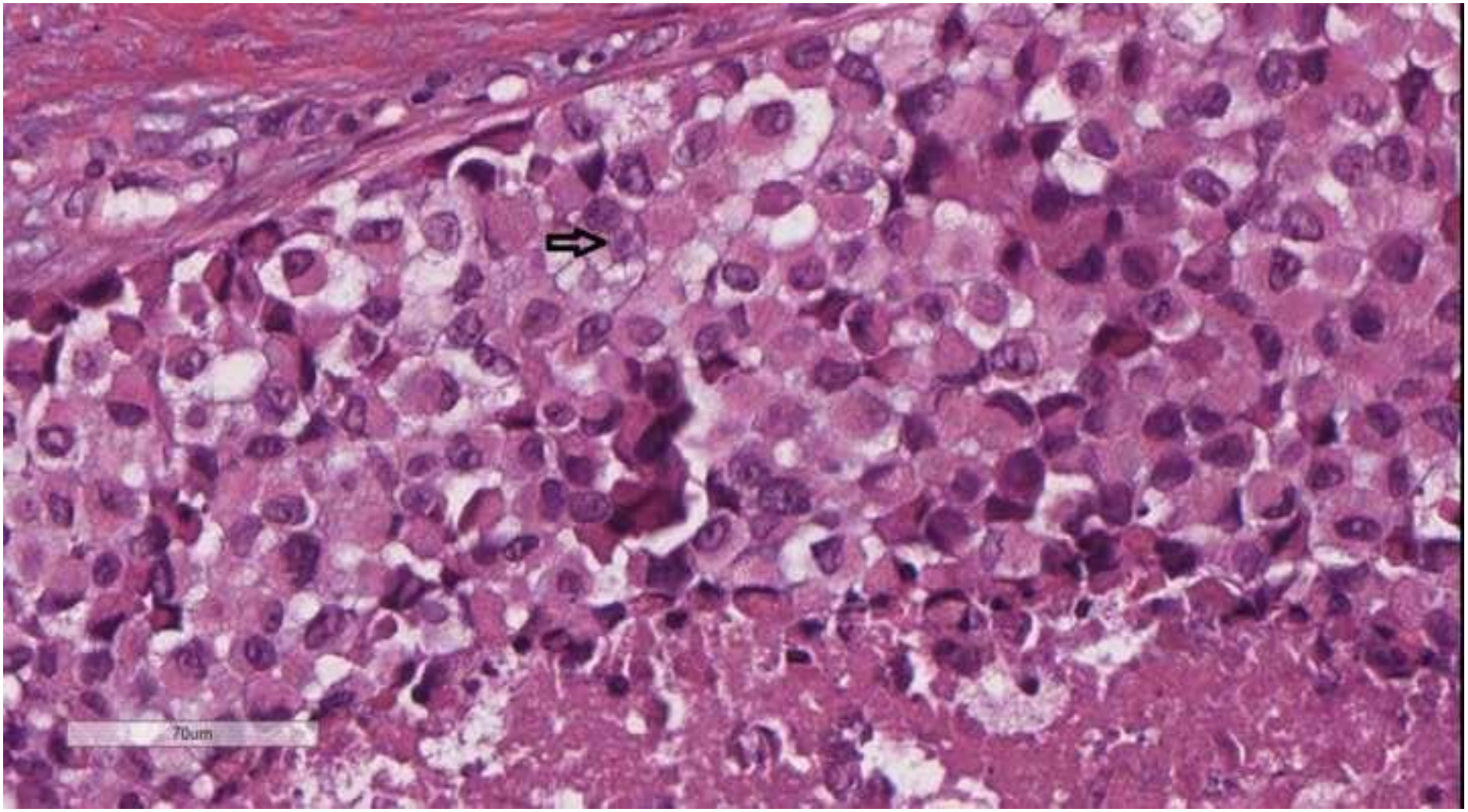
70um