



## Avian Pneumovirus infection in turkey and broiler farms in Italy: a virological, molecular and serological field survey

Elena Catelli, Mattia Cecchinato, Martino Cassandro, Mauro Delogu, Patrizia De Matteo, Carlo Franciosi, Maria Alessandra De Marco & Clive John Naylor

To cite this article: Elena Catelli, Mattia Cecchinato, Martino Cassandro, Mauro Delogu, Patrizia De Matteo, Carlo Franciosi, Maria Alessandra De Marco & Clive John Naylor (2016) Avian Pneumovirus infection in turkey and broiler farms in Italy: a virological, molecular and serological field survey, Italian Journal of Animal Science, 3:3, 287-292, DOI: [10.4081/ijas.2016.287](https://doi.org/10.4081/ijas.2016.287)

To link to this article: <https://doi.org/10.4081/ijas.2016.287>



Copyright 2016 Taylor and Francis Group  
LLC



Published online: 01 Mar 2016.



Submit your article to this journal [↗](#)



Article views: 42



Citing articles: 3 View citing articles [↗](#)



## SHORT COMMUNICATION

# Avian Pneumovirus infection in turkey and broiler farms in Italy: a virological, molecular and serological field survey

Elena Catelli<sup>1</sup>, Mattia Cecchinato<sup>1</sup>, Mauro Delogu<sup>1</sup>,  
Patrizia De Matteo<sup>1</sup>, Giovanni Ortali<sup>3</sup>, Carlo Franciosi<sup>1</sup>,  
Maria Alessandra De Marco<sup>2</sup>, Clive John Naylor<sup>4</sup>

<sup>1</sup> Dipartimento di Sanità Pubblica veterinaria e Patologia animale. Università di Bologna, Italy

<sup>2</sup> Istituto Nazionale per la Fauna Selvatica. Ozzano Emilia (BO), Italy

<sup>3</sup> Azienda "Tre Valli". Verona, Italy

<sup>4</sup> Department of Veterinary Pathology. University of Liverpool, UK

*Corresponding author:* Dr. Elena Catelli. Dipartimento di Sanità Pubblica veterinaria e Patologia animale. Facoltà di Medicina Veterinaria, Università di Bologna. Via Tolara di Sopra 50, 40064 Ozzano dell'Emilia (BO), Italy – Tel. +39 051 2097080 - Fax: +39 051 2097039 - Email: catelli@vet.unibo.it

---

*Paper received January 7, 2004; accepted February 13, 2004*

---

## ABSTRACT

Avian Pneumovirus (APV) is the casual agent of Turkey Rhinotracheitis (TRT), and also causes a respiratory infection in chickens, which can result in Swollen Head Syndrome. A survey of APV infection in Italian turkey and broiler farms, in a highly populated area of Northern Italy (Verona Province) is reported. Nine turkey farms and 6 broiler farms were sampled. Sixteen birds from each group were doubly swabbed from the choanal cleft for virus isolation on tracheal organ cultures (TOC) and RT nested PCR (A and B type specific) using extracted RNA. At the same time blood samples were collected for a blocking ELISA serological assay. The broiler samples for virological assays were treated with infectious bronchitis virus (IBV) antiserum raised against serotypes prevalent in the areas sampled, thus avoiding competitive growth of IBV on TOC. Ciliostasis on TOC was taken as the indicator of the presence of the virus, and confirmation was by indirect immunofluorescence. APV was isolated and detected by RT-PCR in 19 day-old turkeys, and in 34, 42 and 48 day-old broilers. All APV strains were found to be type B. All turkeys of more than 4 weeks old were APV positive by ELISA. APV infection was found to be widely spread in the area sampled and the protocol used for virus isolation was shown to be effective. Turkey rhinotracheitis first appeared in Italy in the late 1980s, and the APV isolates involved were subsequently characterised as B types. Our results confirm APV B type to be present in Italy, but the limited findings to date need to be extended by further surveys of other Italian regions.

*Key words:* Turkey Rhinotracheitis (TRT), Avian Pneumovirus (APV), Turkeys, Broilers, Reverse transcriptase - Polymerase chain reaction (RT-PCR)

## RIASSUNTO

INFEZIONE DA PNEUMOVIRUS AVIARE NEL TACCHINO DA CARNE E NEL BROILER IN ITALIA:  
INDAGINI DI CAMPO MEDIANTE TECNICHE VIROLOGICHE, SIEROLOGICHE E MOLECOLARI

*Il Pneumovirus aviare (APV) è causa nel tacchino di una infezione delle prime vie respiratorie nota come Rinotracheite*

del tacchino (TRT), mentre nel pollo è responsabile di una forma respiratoria lieve, a volte inapparente, che può sfociare nella Sindrome della Testa Gonfia. Nel presente lavoro è riportata una indagine virologica, sierologica e molecolare sulla presenza di APV in allevamenti di tacchini e polli da carne della provincia di Verona (Italia). Sono stati considerati a tale scopo 9 allevamenti di tacchini e 6 di polli. Sono stati eseguiti tamponi rinofaringei da 16 soggetti/gruppo, per isolamento virale su colture di anelli tracheali di embrione di pollo (TOC) ed RT- nested PCR sottotipo specifica. Dagli stessi soggetti sono stati raccolti campioni di sangue allo scopo di evidenziare anticorpi per APV mediante test ELISA di tipo blocking. I campioni per gli esami virologici, prelevati dai polli da carne, erano previamente trattati con antisieri specifici nei riguardi dei ceppi di virus della bronchite infettiva (IBV) prevalenti nell'area campionata o utilizzati come vaccino, allo scopo di inibire la crescita competitiva di IBV sulle TOC. Le colture erano considerate positive se si osservava ciliostasi, e la conferma dell'isolamento virale era ottenuta mediante immunofluorescenza indiretta. *Pneumovirus aviari* appartenenti al sottotipo B sono stati isolati e contemporaneamente evidenziati mediante RT- nested PCR in tacchini di 19 giorni di età e polli di 34, 42, e 48 giorni di età. Tutti i gruppi di tacchini di età superiore a 4 settimane erano positivi sierologicamente. Dai risultati ottenuti si evince che la infezione da APV è ampiamente diffusa nell'area campionata ed il protocollo utilizzato per l'isolamento virale efficace. La Rinotracheite del tacchino è comparsa per la prima volta in Italia alla fine degli anni '80 e gli isolati coinvolti sono stati in seguito caratterizzati come sottotipo B. I nostri risultati confermano la presenza di questo sottotipo in Italia, ma sarà necessario completare i dati epidemiologici ancora limitati estendendo l'indagine ad altre regioni.

Parole chiave: Rinotracheite del tacchino (TRT), *Pneumovirus Aviare* (APV), Tacchino, Pollo da carne, Trascrizione inversa - Reazione a catena della polimerasi (RT-PCR)

## Introduction

Avian Pneumovirus (APV) is a negative sense RNA virus, envelope virus which is the type species in the new genus *Metapneumovirus* in the *Paramyxoviridae* family. It is the casual agent of Turkey Rhinotracheitis (TRT), and also causes a respiratory infection in chickens, which can result in Swollen Head Syndrome (SHS). The first APV virus isolation in Italy were made in the late 1980s (Fabris and D'Aprile, 1990). TRT and SHS were then diagnosed serologically (Massi, 1997; Fabris *et al.*, 1998); moreover, serological evidences of Avian Pneumovirus infection were reported in reared and free living pheasants (Catelli *et al.*, 2001). Since 1990 there have not been other reports of APV virus isolation from any susceptible species. Successful isolation of APV from the field is rare because the virus persists for only a short time after infection hence virus isolation must be attempted at the very first sign of clinical disease. Moreover, infectious bronchitis virus (IBV) (field strains as well as vaccine strains) has been shown to interfere with APV replication in tracheal organ cultures and in vivo (Jones *et al.*, 1998; Cook *et al.*, 2001) leading to increased difficulties in recovering the virus when IBV is present in the flock. At present four APV subtypes have been characterised: the A and B European types (Juhasz and

Easton, 1994), the United States C type (Seal, 1998) and a new type, referred to as D, which includes two old French isolates (Bayon-Auboyer *et al.*, 2000). Little information is available on APV subtypes circulating in Italy, except for the data regarding the first Italian isolates that were shown to be B types (Juhasz and Easton, 1994).

The survey aimed to detect APV infection in Italian turkey and broiler farms using virus isolation, type specific RT- nested PCR and serology.

## Material and methods

### Sampling

The survey was performed in a highly populated area of Northern Italy (Verona Province) in farms belonging to a large Italian poultry company, which had reported frequent TRT outbreaks. Nine turkey flocks (A-I) and 6 broiler flocks (L-Q), not vaccinated for TRT but coming from APV vaccinated parents, were sampled once. The groups were chosen so as to cover the whole broiler life span and for turkeys, up to 73 days, the periods where APV isolations are most likely. Because of the high infectivity of APV in poultry (Stuart, 1989), the expected seroprevalence was set at 25%. In each flock the population of birds was  $\geq 3500$ , so 16 samples/group were required to be 99% certain of detecting the infection (Cannon and Roe, 1982).

Any gross respiratory disease experienced by the birds was recorded. Each bird were doubly swabbed from the choanal cleft, and bled for serology. Wet swabs were collected for virus isolation and dry swabs for molecular tests. The swabs for both tests were processed in 2 pools of 8. The wet swabs were immediately immersed in the transport medium and kept on ice until the inoculation of tracheal organ cultures. The swabs for the molecular testing were dried for approximately 30 minutes then kept at room temperature prior to processing. Four broiler flocks (M, O, P and Q) were bled again two weeks later. When the flocks were found to show respiratory disease, birds exhibiting the first clinical signs were sampled. It is known that APV is present in both turkeys and chickens for only a very short time after initial infection (with peak titres being found approximately 3 to 5 days post infection [Cook *et al.*, 1991; Catelli *et al.*, 1998]) while first obvious clinical signs occur after 5 days.

#### *Virus isolation*

Virus isolation was performed in chicken embryo tracheal organ cultures (TOC) (Cook *et al.*, 1976). Ciliostasis was taken as the indicator of the presence of the virus, and confirmation was by indirect immunofluorescence (IIF) (Jones *et al.*, 1988) on cryostatic sections of those positive TOCs. When ciliostasis was not observed, the samples were given three blind passages in TOCs at 3 or 4-day intervals. Collected virological samples from broiler farms were treated with infectious bronchitis virus (IBV) antisera to suppress any potential competitive growth of IBV. Serotypes used were 624/I and 793/B which are prevalent in the areas sampled, and M41 which was used as vaccine. APV strains were then typed by RT-nested PCR as described below.

#### *RT-nested PCR*

A type specific RT-nested PCR, based on G gene sequence and able to differentiate A and B subtypes, was used to detect APV from dry swabs and to type the isolates. RNA was extracted from dry swabs and cDNA prepared following the method described by Cavanagh *et al.* (1999). The viral RNA was extracted from the TOC medium

(QIAamp viral miny Kit, Quiagen) and a nested PCR designed to detect A and B subtype APV was performed according to Naylor *et al.* (1997a). The inner PCR used a single reverse oligonucleotide (G5-) common to both virus subtypes, one forward oligonucleotide specific for subtype A (G8+A, generating a cDNA of 268 bp) and another specific for subtype B (G9+B, generating a cDNA of 361 bp). These products were analysed by agarose gel electrophoresis and visualised by ethidium bromide staining.

#### *Serology*

A kit based on a blocking enzyme immunoassay (Svanovir®, Avian Pneumovirus-Ab EIA Test Kit; SVANOVA Biotech) was used for detection of APV-specific antibodies. The test was run according to the manufacturer's instruction.

## Results and discussion

The results of the survey performed in turkeys are reported in Table 1. APV was isolated on TOCs (Figure 1) and B type viral RNA detected by RT-nested PCR, in 19 day-old turkeys showing clinical signs typical of Turkey Rhinotracheitis. All the flocks were seropositive, and all the birds more than 4 weeks old had experienced respiratory signs before sampling. APV was isolated and detected in 34, 42 and 48 day-old broilers (Table 2). At the time of sampling the infected birds were all negative by ELISA, and then showed seroconver-

Figure 1. Tracheal organ culture, cryostatic section. Indirect Immunofluorescence stain positive for APV.

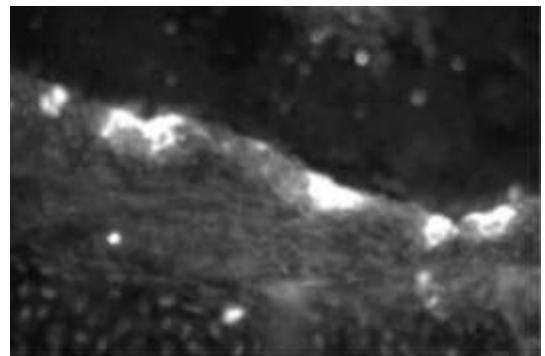


Table 1. Results of diagnostic testing on turkey farms.

Flock	Age at sampling (days)	Concurrent respiratory signs	RT- PCR on swabs	APV virus isolation	ELISA +/s^ %
A	13	No	- §	-	100
B	19	Yes	+* Type B	+ Type B	92
C	26	No	-	-	15
D	37	No (before)	-	-	100
E	43	No (before)	-	-	100
F	50	No (before)	-	-	100
G	56	No (before)	-	-	100
H	62	No (before)	-	-	100
I	73	No (before)	-	-	100

§ negative; \* positive; ^ positive/sampled

Table 2. Results of diagnostic testing on broiler farms.

Flock	Age at sampling (days)	Concurrent respiratory signs	RT- PCR on swabs	APV virus isolation	ELISA +/s^ %	
					1°	2° (15 d.l.)
L	15	no	- §	-	50	nd
M	21	Yes	+* Type B	-	0	0
N	28	Yes	-	-	0	nd
O	34	No (later)	+ Type B	+ Type B	0	100
P	42	No (later)	+ Type B	+ Type B	0	100
Q	48	No (later)	+ Type B	+ Type B	0	100

§ negative; \* positive; ^ positive/sampled; d.l. = days later; nd = not done

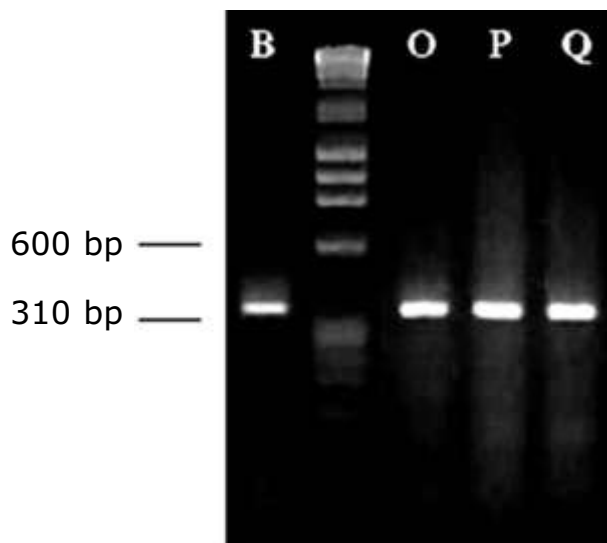
sion two weeks later. During this time mild respiratory disease and rare cases of swollen head syndrome were observed. Flock M showed RT-PCR positive for APV from swabs without 15 days later seroconversion. All APV strains were found to be B types by RT-nested PCR test (Figure 2).

APV infection was found to be widely spread in the area sampled. The protocol used for virus isolation was shown to be effective, as reported by other authors, and results were almost entirely in keeping with the RT-nested PCR results, for the same period (Cook *et al.*, 2001). One APV positive PCR (21 day old chickens - Flock M) was not confirmed by virus isolation on TOCs, nor by ELISA so tends to suggest that this represent a false pos-

itive result. Another apparent inconsistency may appear to be the finding that birds of group B were ELISA positive yet were not protected against APV infection, both in terms of virus detection and clinical disease. It is possible that this seropositivity was due to maternal antibody which has been previously shown not to protect against virulent challenge (Naylor *et al.*, 1997b).

Reports of APV virus isolations from chickens in the field are rare, because it is difficult to recognise the virus infection from clinical signs, probably due to most infections only producing subclinical disease. Our results confirm these findings as the virus was only recovered from birds prior to appearance of respiratory signs. The success in

Figure 2. Agarose gel electrophoresis showing 361bp products of the RT nested PCR specific for B subtype APV. Lane 1: Strain from turkey flock B. Lane 2: DNA size marker, with the most useful sizes shown in the left-hand side of the gel. Lines 3, 4, 5: Strains from broiler flocks O, P and Q.



virus isolation is also to be attributed, in our opinion, to handling methodology. Samples were concentrated in a small amount of transport medium, kept on ice and used to inoculate TOCs, all within a period of 1 day. Turkey Rhinotracheitis first appeared in Italy in the late 1980s and the APV isolates involved were subsequently characterised as B types. Our results confirm APV B type to be present in Italy, but the limited findings to date need to be extended by further surveys of other Italian regions.

*Part of the results were presented at the 41<sup>st</sup> Annual Congress of the Italian Society of Avian Pathology (SIPA), October 3-4, 2002, Forlì (Italy) and at the 13<sup>th</sup> Congress of the World Veterinary Poultry Association, July 19-23, 2003, Denver-Colorado (USA).*

---

Research supported by MURST (ex grant 60%)

---

## REFERENCES

- BAYON-AUBOYER, M.H., ARNAULD, C., TOQUIN, D., ETERRADOSSI, N., 2000. Nucleotide sequences of the F, L and G protein genes of two non-A/non-B avian pneumovirus (APV) reveal a novel APV subgroup. *J. Gen. Vir.* 81: 2723-2733.
- CANNON, R.M., ROE, R.T., 1982. *Livestock disease surveys: a field manual for veterinarians.* Australian Bureau of Animal Health. Canberra, Australian Government Publishing Service, Australia.
- CATELLI, E., COOK, J.K.A., CHESHER, J., ORBELL, S.J., WOODS, M.A., BAXENDALE, W., HUGGINS, M.B., 1998. The use of virus isolation, histopathology and immunoperoxidase technique to study the dissemination of a chicken isolate of avian pneumovirus in chickens. *Avian Pathol.* 27:632-640.
- CATELLI, E., DE MARCO, M.A., DELOGU, M., TERREGINO, C., GUBERTI, V., 2001. Serological evidence of avian pneumovirus infection in reared and free-living pheasants. *Vet. Rec.* 149: 56-58.
- CAVANAGH, D., MADWITT, K., BRITTON, P., NAYLOR, C.J., 1999. Longitudinal field studies of infectious bronchitis virus and avian pneumovirus in broilers using type-specific polymerase chain reactions. *Avian Pathol.* 28: 593-605.
- COOK, J.K.A., DARBYSHIRE, J.H., PETER, R.W., 1976. The use of chicken tracheal organ cultures for the isolation and assay of avian infectious bronchitis virus. *Arch. Virol.* 50:109-118.

- COOK, J.K.A., ELLIS, M.M., HUGGINS, M.B., 1991. The pathogenesis of turkey rhinotracheitis virus in turkey poults inoculated with a virus alone or together with two strains of bacteria. *Avian Pathol.* 20:155-166.
- COOK, J.K.A., HUGGINS, M.B., ORBELL, S.J., MADWITT, K., CAVANAGH, D., 2001. Infectious bronchitis vaccine interferes with the replication of avian pneumovirus vaccine in domestic fowl. *Avian Pathol.* 30:233-242
- FABRIS, G., D'APRILE, P.N., 1990. Rinotracheite infettiva del tacchino: osservazioni sul campo ed indagini di laboratorio. *Zootecnica Int.* 1(6): 36-40.
- FABRIS, G., DELLA VALENTINA, M., GAVAZZI, L., GOZZINI, P., 1998. TRT nei tacchini. Indagine sierologica in animali vaccinati e non vaccinati. *Selez. Vet.* 39: 645-654.
- JONES, R.C., WILLIAMS, R.A., BAXTER-JONES, C., SAVAGE, C.E., WILDING, G.P., 1988. Experimental infection of laying turkeys with rhinotracheitis virus: distribution of virus in the tissues and serological response. *Avian Pathol.* 17:841-850.
- JONES, R.C., KHEHERA, R.S., NAYLOR, C.J., CAVANGH, D., 1998. Dual infection of tracheal organ cultures and chicks with infectious bronchitis and avian pneumovirus. pp 97-105 in *Proc. Int. Symp. on Infectious Bronchitis and Avian Pneumovirus Infections in Poultry*, Rauischholhausen, Germany.
- JUHASZ, K., EASTON, A.J., 1994. Extensive sequence variation in the attachment (G) protein gene of avian pneumovirus: evidence for two distinct subgroups. *J. Gen. Virol.* 75:2873-2880.
- MASSI, P., 1997. Riepilogo delle principali patologie aviarie osservate nel corso del 1996 nelle diverse regioni italiane. *Selez. Vet.* 38:537-541.
- NAYLOR, C.J., SHAW, K., BRITTON, P., CAVANAGH, D., 1997a. Appearance of type B avian pneumovirus in Great Britain. *Avian Pathol.* 26:327-338.
- NAYLOR, C.J., WORTHINGTON, K.J., JONES, R.C., 1997b. Failure of maternal antibodies to protect young turkey poults against challenge with turkey rhinotracheitis virus. *Avian Dis.* 41: 968-971.
- SEAL, B.S., 1998. Matrix protein gene nucleotide and predicted amino acid sequence demonstrate that the first US avian pneumovirus isolate is distinct from European strains. *Virus Res.* 58:45-52.
- STUART, J. C., 1989. Turkey rhinotracheitis (TRT) in Great Britain. In: C. Nixey, T. C. Grey (eds.) *Recent advances in turkey science*. Butterworths & Co. Publishers Ltd., London, UK, pp 217-224.