



ARCHIVIO ISTITUZIONALE DELLA RICERCA

Alma Mater Studiorum Università di Bologna Archivio istituzionale della ricerca

Hemostatic powder for the intraductal treatment of biliary cancer bleeding

This is the final peer-reviewed author's accepted manuscript (postprint) of the following publication:

Published Version:

Hemostatic powder for the intraductal treatment of biliary cancer bleeding / Fuccio L.; Sansone V.; Mosconi C.; Golfieri R.; Bazzoli F.. - In: VIDEOGIE. - ISSN 2468-4481. - ELETTRONICO. - 4:12(2019), pp. 565-566. [10.1016/j.vgie.2019.08.008]

This version is available at: <https://hdl.handle.net/11585/709720> since: 2019-12-19

Published:

DOI: <http://doi.org/10.1016/j.vgie.2019.08.008>

Terms of use:

Some rights reserved. The terms and conditions for the reuse of this version of the manuscript are specified in the publishing policy. For all terms of use and more information see the publisher's website.

(Article begins on next page)

This item was downloaded from IRIS Università di Bologna (<https://cris.unibo.it/>).
When citing, please refer to the published version.

Hemostatic powder for the intraductal treatment of biliary cancer bleeding



Lorenzo Fuccio, MD,¹ Vito Sansone, MD,¹ Cristina Mosconi, MD,² Rita Golfieri, MD,² Franco Bazzoli, MD³

Biliary tract bleedings are rare cases of upper-GI bleeding¹ that are usually self-limited; otherwise, viable treatment options are represented by transarterial embolization, balloon tamponade, biliary stent placement,² and argon plasma coagulation.³

Hemospray (TC-325; Cook Medical, Bloomington, Ind, USA) is an inorganic powder approved for the treatment of upper-GI bleeding.⁴ Nevertheless, reports on its use for biliary tract bleeding due to biliary cancer are lacking.

We report the case of an 87-year-old-woman who was admitted to our hospital for hyperbilirubinemia (18.7 mg/dL) and weight loss. According to CT and magnetic resonance imaging, a type IIIA Corlette-Bismuth Klatskin cholangiocarcinoma was diagnosed (Figs. 1 and 2). Despite the absence of metastases, the patient was deemed not suitable for curative resection because of her comorbidities and age.

After an unsuccessful attempt to obtain complete biliary drainage by ERCP, bilateral percutaneous transhepatic cholangiography (Figs. 3A-C), followed by internal-external biliary drainage positioning, was performed. In a second procedure, 2 uncovered metallic stents (Wallstent; Boston Scientific Corp, Marlborough, Mass, USA) were placed (Fig. 4).

Twelve days later, the patient became hemodynamically unstable with a sudden drop of hemoglobin level to 5.8 g/dL and melena. Endoscopic examination showed active arterial oozing and a huge blood clot, almost completely involving the 2 stents. Because of partial distal dislodgment

of uncovered stents, it was not possible to place covered stents within them. Thus, we decided to insert the Hemospray cannula inside the left stent, up to the hilum, and spray the powder while withdrawing the cannula down to the papilla (Video 1, available online at www.VideoGIE.org). Active bleeding stopped thereafter, and the patient did not experience immediate adverse events. The patient remained asymptomatic after the procedure, and follow-up examinations showed a rise of the hemoglobin level, whereas the bilirubin value remained just above normal (1.41 mg/dL). Because no curative options could be offered to the patient, she was discharged 16 days later.

To our knowledge, this is the first reported case of hemostatic powder used to treat a malignant intraductal bleeding, which was successful without any major adverse events. Reasons of concern about the safety of this procedure are the impossibility of obtaining a direct view of the bleeding site and of targeting the powder application. Therefore, the risk of biliary obstruction cannot be ruled out completely. However, in an acute setting with a patient

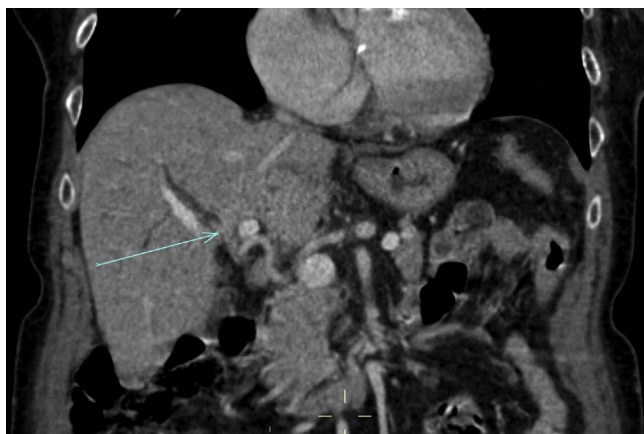


Figure 1. CT scan of Klatskin cholangiocarcinoma.

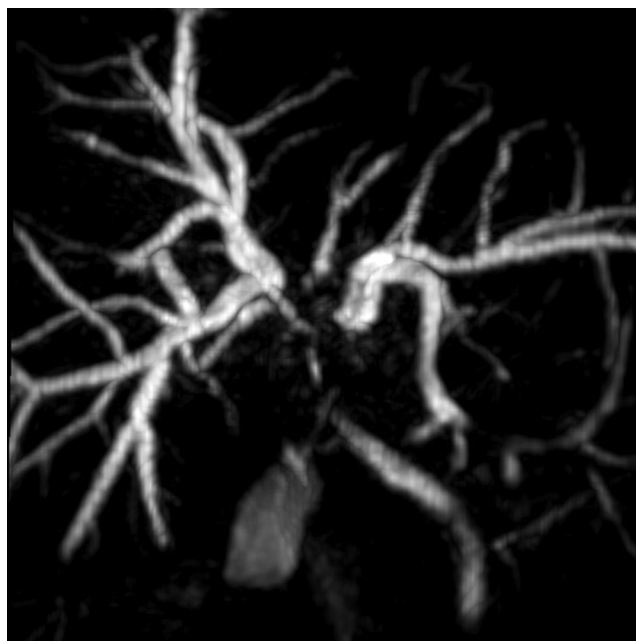


Figure 2. Magnetic resonance image of Klatskin cholangiocarcinoma.

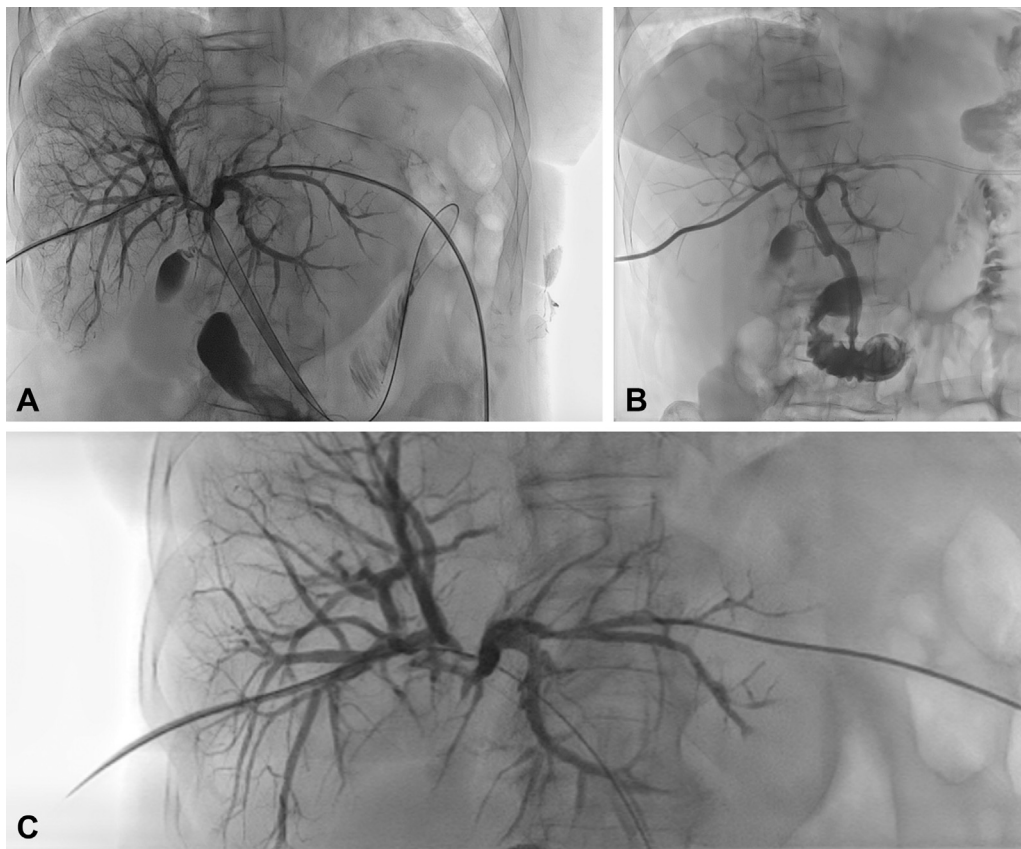


Figure 3. A, B, C, Angiographic views of the malignant stricture.

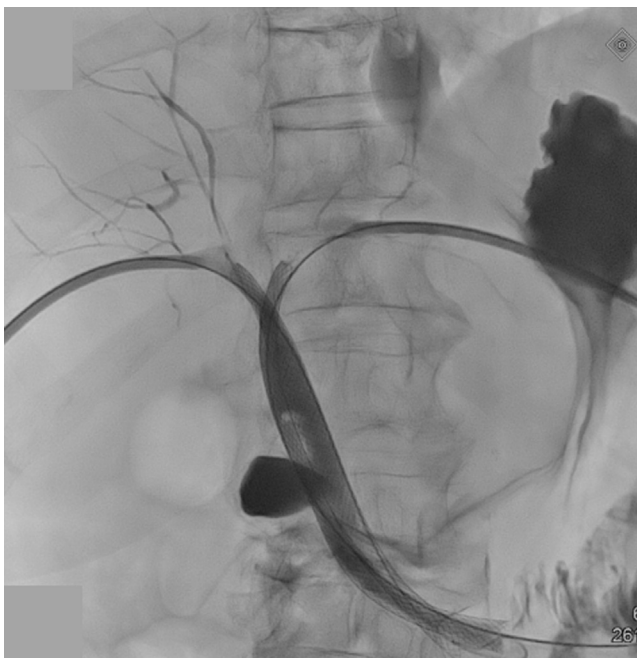


Figure 4. Fluoroscopic image of biliary stent placement; guidewire in the left stent.

in unstable condition, where other treatment options are not feasible, this could be considered a valuable rescue procedure.

DISCLOSURE

All authors disclosed no financial relationships relevant to this publication.

REFERENCES

1. Green MHA, Duell RM, Johnson CD, et al. Haemobilia. *Br J Surg* 2001;88:773-86.
2. Zhornitskiy A, Berry R, Han JY, et al. Hemobilia: historical overview, clinical update, and current practices. *Liver Int* 2019;39:1378-88.
3. Anderloni A, Auriemma F, Fugazza A, et al. Intrahepatic argon plasma coagulation hemostasis by direct cholangioscopy for a tricky post-ERCP bleeding. *Endoscopy* 2018;50:287-9.
4. Arena M, Masci E, Eusebi LH, et al. Hemospray for treatment of acute bleeding due to upper gastrointestinal tumours. *Dig Liver Dis* 2017;49:514-7.

Gastroenterology Unit, Department of Medical and Surgical Sciences (1), Radiology Unit, Department of Experimental, Diagnostic, and Specialty Medicine (2), Gastroenterology Unit, Department of Medical and Surgical Sciences (3), S. Orsola-Malpighi University Hospital, Bologna, Italy.

Copyright © 2019 American Society for Gastrointestinal Endoscopy. Published by Elsevier Inc. This is an open access article under the CC BY-NC-ND license (<http://creativecommons.org/licenses/by-nc-nd/4.0/>).

<https://doi.org/10.1016/j.vgie.2019.08.008>