

Alma Mater Studiorum Università di Bologna
Archivio istituzionale della ricerca

Spondylotarsal synostosis syndrome: “Bat wings” spinal fusions and “ladybug” carpal coalitions

This is the final peer-reviewed author’s accepted manuscript (postprint) of the following publication:

Published Version:

Bazzocchi A., Spinnato P., Aparisi Gomez M.P., Mercatelli D., Albinetti U. (2019). Spondylotarsal synostosis syndrome: “Bat wings” spinal fusions and “ladybug” carpal coalitions. *PEDIATRICS & NEONATOLOGY*, 60(4), 469-470 [10.1016/j.pedneo.2018.08.007].

Availability:

This version is available at: <https://hdl.handle.net/11585/709048> since: 2020-04-23

Published:

DOI: <http://doi.org/10.1016/j.pedneo.2018.08.007>


Terms of use:

Some rights reserved. The terms and conditions for the reuse of this version of the manuscript are specified in the publishing policy. For all terms of use and more information see the publisher's website.

This item was downloaded from IRIS Università di Bologna (<https://cris.unibo.it/>).
When citing, please refer to the published version.

(Article begins on next page)

AUTHOR QUERY FORM

 ELSEVIER	Journal: PEDN Article Number: 861	Please e-mail your responses and any corrections to: E-mail: corrections.esch@elsevier.tnq.co.in
--	--	--

Dear Author,

Please check your proof carefully and mark all corrections at the appropriate place in the proof (e.g., by using on-screen annotation in the PDF file) or compile them in a separate list. **It is crucial that you NOT make direct edits to the PDF using the editing tools as doing so could lead us to overlook your desired changes.** Note: if you opt to annotate the file with software other than Adobe Reader then please also highlight the appropriate place in the PDF file. To ensure fast publication of your paper please return your corrections within 48 hours.

For correction or revision of any artwork, please consult <http://www.elsevier.com/artworkinstructions>.


Any queries or remarks that have arisen during the processing of your manuscript are listed below and highlighted by flags in the proof.

Location in article	Query / Remark: Click on the Q link to find the query's location in text Please insert your reply or correction at the corresponding line in the proof
Q1	Of the two article title given, we have retained the article title provided along the manuscript. Kindly check and amend if necessary.
Q2	Please check that the affiliations link the authors with their correct departments, institutions, and locations, and correct if necessary.
Q3	Of the two title pages provided, we have followed the title page provided along the manuscript. Kindly check and amend if necessary.
Q4	Correctly acknowledging the primary funders and grant IDs of your research is important to ensure compliance with funder policies. We could not find any acknowledgement of funding sources in your text. Is this correct?
Q5	Please check the section "Conflicts of interest" and amend if necessary.
Q6	Please confirm that given names and surnames have been identified correctly and are presented in the desired order and please carefully verify the spelling of all authors' names.
Q7	For figure(s) 2, the resolution is too low to be used. Please provide better quality figure of 300 dpi. <div data-bbox="304 1623 895 1804" style="border: 1px solid black; padding: 5px;"> <p>Please check this box or indicate your approval if you have no corrections to make to the PDF file</p> <div style="text-align: right;"> <input data-bbox="791 1683 876 1764" type="checkbox"/> </div> </div>

Thank you for your assistance.

Available online at www.sciencedirect.com

ScienceDirect

journal homepage: <http://www.pediatr-neonatology.com>

Images

Spondylocarpotarsal synostosis syndrome: “Bat wings” spinal fusions and “ladybug” carpal coalitions

Q1

Q6

Alberto Bazzocchi^{a,*}, Paolo Spinnato^a,
 Maria Pilar Aparisi Gómez^{b,c}, Daniele Mercatelli^a,
 Ugo Albisinni^a

Q2

Q3

^a Diagnostic and Interventional Radiology, IRCCS Istituto Ortopedico Rizzoli, Via G. C. Pupilli 1, 40136 Bologna, Italy

^b Department of Radiology, Auckland City Hospital, 2 Park Road, Grafton, Auckland, 1023, New Zealand

^c Department of Radiology, Hospital Nueve de Octubre, Calle Valle de la Ballestera, 59, 46015, Valencia, Spain

Received May 2, 2018; received in revised form Jul 5, 2018; accepted Aug 28, 2018

Available online ■ ■ ■

A pediatrician noticed a hump in a 1-year-old girl during a chest examination for cough and fever. The girl had suffered from intrauterine growth retardation and had been born preterm at 34 weeks, through a caesarean section, in the context of preeclampsia. The child's weight was 1.88 kg at birth. Growth rate was slower than expected for age (at 2 years and 6 months, height was on the 2.9th percentile and weight was on the 1.8th percentile; at 3 years and 6 months, there was slowing in growth with height on the 0.4th percentile and weight on the 1.8th percentile; and at 4 years and 6 months, there was further slowing in growth with height on the 0.1th percentile and weight on the 0.4th percentile). Radiographs of the spine were taken, and in view of the findings, computed tomography (CT) was performed and surveillance was extended to the remainder of the skeleton. Radiographs of the spine demonstrated left convex thoracolumbar scoliosis, with a left rib hump (Fig. 1). CT demonstrated multiple vertebral

fusions (the fusion of posterior elements resembling bats with their wings expanded on 3D reconstruction, Fig. 2A). Surveillance of the hands demonstrated bilateral symmetric double osseous carpal coalitions (CC) of the hamate-capitate and lunate-triquetral bones, resembling a “ladybug” (Fig. 2B).

The association of these findings suggests the clinical–radiological diagnosis of spondylocarpotarsal synostosis syndrome (SCT), an extremely rare skeletal disorder characterized by progressive vertebral, carpal, and tarsal fusions. Individuals with SCT are short, have frontal bossing, scoliosis and/or kyphosis, anteverted nares, and potentially a cleft palate and in some cases hearing loss, problems with tooth enamel, or hyperlaxity.¹ The majority of affected individuals show mutations in the FLNB gene, which encodes a cytoskeletal protein known as filamin B. The result of the mutation is an abnormally short filamin B protein that is unstable and breaks down, acting as a stimulus for

* Corresponding author. Fax: +39 051 6366280.
 E-mail address: abazzo@inwind.it (A. Bazzocchi).

<https://doi.org/10.1016/j.pedneo.2018.08.007>

1875-9572/Copyright © 2018, Taiwan Pediatric Association. Published by Elsevier Taiwan LLC. This is an open access article under the CC BY-NC-ND license (<http://creativecommons.org/licenses/by-nc-nd/4.0/>).

Please cite this article in press as: Bazzocchi A, et al., Spondylocarpotarsal synostosis syndrome: “Bat wings” spinal fusions and “ladybug” carpal coalitions, Pediatrics and Neonatology (2018), <https://doi.org/10.1016/j.pedneo.2018.08.007>

61
62
63
64
65
66
67
68
69
70
71
72
73
74
75
76
77
78
79
80
81
82
83
84
85
86
87
88
89
90
91
92
93
94
95
96
97
98
99
100
101
102
103
104
105
106
107
108
109
110
111
112
113
114
115
116
117
118
119
120
121
122

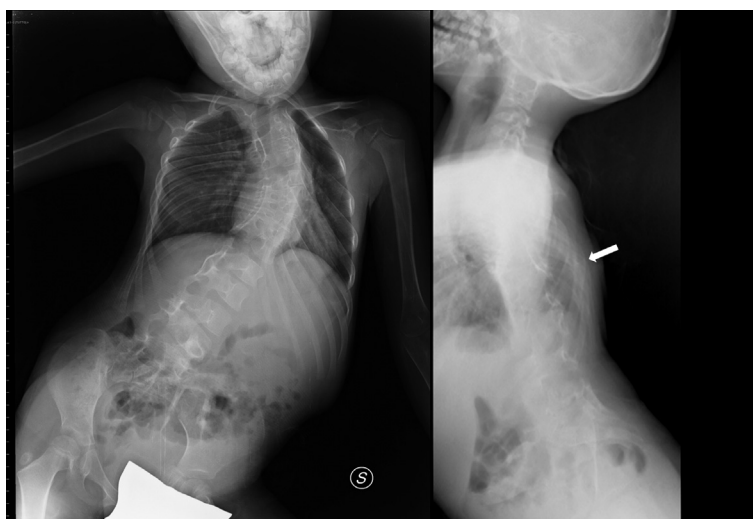

Figure 1 Conventional radiograph of the spine (posterior-anterior and lateral view) showing scoliosis with rib hump (white arrow).

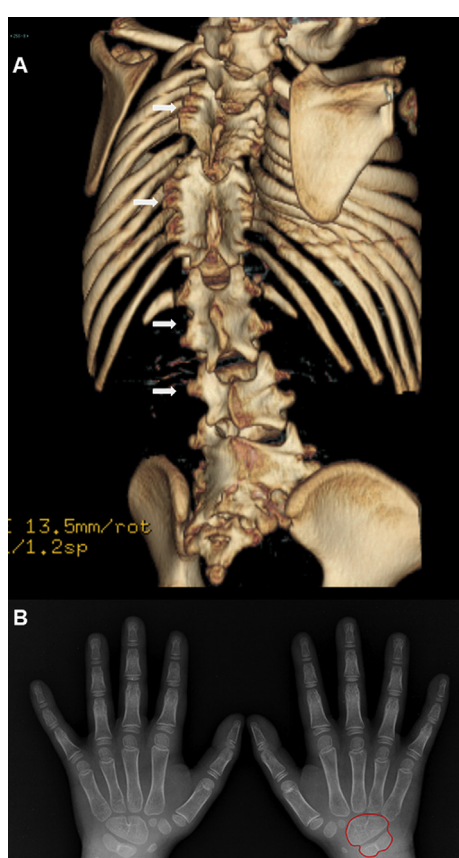


Figure 2 A) 3D reconstruction of a CT scan showing multiple vertebral body fusions. The fusion of posterior elements resembles bats with their wings expanded (white arrows); B) conventional radiograph of the hands (posterior-anterior projection) showing a bilateral identical carpal coalition of the hamate-capitate and lunar-triquetral bones that resembles ladybug shape.

the ossification of cartilage. SCT due to FLNB mutations exhibits an autosomal recessive inheritance pattern. In a few individuals with no FLNB mutations, the syndrome exhibited an autosomal dominant inheritance pattern.² Mutations in MYH3, which encodes embryonic myosin heavy chain 3, have been detected in some families with autosomal dominant SCT.³ However, in some cases, the specific genetic mutation remains unknown.² Our patient underwent genetic study, with testing for mutation of the FLNB gene, but no specific genetic mutation could be demonstrated.

Routine skeletal surveillance should be considered in children with congenital scoliosis to avoid missing a number of bony dysplasias and complex syndromic causes. Thus, SCT may potentially represent an underdiagnosed syndrome.

Conflicts of interest

All authors have contributed to the manuscript and approved the final submission. All authors have no funding or conflict of interest to declare.

References

1. Salián S, Shukla A, Shah H, Bhat SN, Bhat VR, Nampoothiri S, et al. Seven additional families with spondylcarpotarsal synostosis syndrome with novel biallelic deleterious variants in FLNB. *Clin Genet* 2018;**94**:159–64.
2. Isidor B, Cormier-Daire V, Le Merrer M, Lefrançois T, Hamel A, Le Caignec C, et al. Autosomal dominant spondylcarpotarsal synostosis syndrome: phenotypic homogeneity and genetic heterogeneity. *Am J Med Genet A* 2008;**146A**:1593–7.
3. Zieba J, Zhang W, Chong JX, Forlenza KN, Martin JH, Heard K, et al. A postnatal role for embryonic myosin revealed by MYH3 mutations that alter TGFβ signaling and cause autosomal dominant spondylcarpotarsal synostosis. *Sci Rep* 2017;**7**:41803.