ALMA MATER STUDIORUM
UNIVERSITÀ DI BOLOGNA

ARCHIVIO ISTITUZIONALE
DELLA RICERCA

Alma Mater Studiorum Università di Bologna
Archivio istituzionale della ricerca

Detection of the intranuclear microsporidian Enterospora nucleophila in gilthead sea bream by in situ hybridization

This is the final peer-reviewed author's accepted manuscript (postprint) of the following publication:

Published Version:
Ahmed, N.H., Caffara, M., Sitjà-Bobadilla, A., Fioravanti, M.L., Mazzone, A., Aboulezz, A.S., et al. (2019). Detection of the intranuclear microsporidian Enterospora nucleophila in gilthead sea bream by in situ hybridization. JOURNAL OF FISH DISEASES, 42(6), 809-815 [10.1111/jfd.12993].

Availability:
This version is available at: https://hdl.handle.net/11585/688648 since: 2019-10-29

Published:
DOI: http://doi.org/10.1111/jfd.12993

Terms of use:

Some rights reserved. The terms and conditions for the reuse of this version of the manuscript are specified in the publishing policy. For all terms of use and more information see the publisher's website.

This item was downloaded from IRIS Università di Bologna (https://cris.unibo.it/).
When citing, please refer to the published version.

(Article begins on next page)

12 October 2024

THIS IS THE PEER REVIEWED VERSION OF THE FOLLOWING ARTICLE:

DETECTION OF THE INTRANUCLEAR MICROSPORIDIAN *ENTEROSPORA NUCLEOPHILA* IN GILTHEAD SEA BREAM BY *IN SITU* HYBRIDIZATION,

WHICH HAS BEEN PUBLISHED IN FINAL FORM AT *JOURNAL OF FISH DISEASES* DOI: 10.1111/JFD.12993.

THIS ARTICLE MAY BE USED FOR NON-COMMERCIAL PURPOSES IN ACCORDANCE WITH WILEY TERMS AND CONDITIONS FOR USE OF SELF-ARCHIVED VERSIONS.

Title: Detection of the Intranuclear Microsporidian *Enterospora nucleophila* in Gilthead Sea Bream by *In situ* Hybridization

Short running title: ISH detection of *E. nucleophila*

Authors:

Ahmed, N. H. [1, 2](*), Caffara, M. [3] (*), Sitjà-Bobadilla, A. [1], Fioravanti, M.L.[3], Mazzone, A. [3], Aboulezz, A. S. [2], Metwally, A.M. [4], Omar M.A.,[4]; Palenzuela, O. [1].

(*) N. H. Ahmed and M. Caffara contributed equally to this work.

Affiliations:

(1) Institute of Aquaculture "Torre de la Sal" (IATS-CSIC), Castellón, Spain.

(2) National Institute of Oceanography and Fisheries (NIOF), Hurghada, Egypt.

(3) Department of Veterinary Medical Sciences, University of Bologna, Italy.

(4) Department of Parasitology, Faculty of Veterinary Medicine, South Valley University, Qena, Egypt.

ACKNOWLEDGEMENTS:

This work has been carried out with financial support from the Spanish MINECO under project AGL2013-48560-C2-2-R. Additional funding was provided by the European Union, through the Horizon H2020 research and innovation programme grant agreement 634429 (ParaFishControl). This publication reflects only the authors' view and the European Union cannot be held responsible for any use that may be made of the information contained herein. N. H. Ahmed was recipient of a fellowship from the Egyptian Cultural Office in Spain. We kindly thank G. Albinyana and A. Girons, (Immunovet, Barcelona, Spain) for their collaboration in the exchange of samples and epidemiological data.

ABSTRACT

Enterospora nucleophila is an intranuclear microsporidian responsible for emaciative microsporidiosis of gilthead sea bream (GSB). Its minute size and cryptic nature make it easily misdiagnosed. An *In situ* hybridization (ISH) technique based on antisense oligonucleotide probes specific for the parasite was developed and used in clinically infected GSB in combination with calcofluor white stain (CW) and other histopathological techniques. The ISH method was found to label very conspicuously the cells containing parasite stages, with the signal concentrating in merogonial and sporogonial plasmodia within the infected cell nuclei. Comparison with CW demonstrated limited ISH signal in cells containing mature spores, that was attributed mostly to the scarcity of probe targets present in these stages. Although spores were detected in other organs of the digestive system as well as in the peripheral blood, proliferative stages or parasite reservoirs were not found in this work outside the intestines. The study demonstrated a frequent disassociation between the presence of abundant spores and the intensity of the infections as determined by the parasite activity. The ISH allows confirmatory diagnosis of GSB microsporidiosis and estimation of infection intensity, and will be a valuable tool for a more precise determination of parasite dissemination pathways and pathogeny mechanisms.

Keywords: Parasite, Microsporidia, Enterospora, In-situ Hybridization, Diagnostics

INTRODUCTION

Microsporidians are minute intracellular parasites that infect all animal phyla and even protists like amoebae and gregarines (Larsson 2000, Scheid et al. 2008). Over half of the known genera infect aquatic organisms (Stentiford et al. 2016). With a close phylogenetic relationship with fungi, they share biological features such as the presence of chitin in the spores, the use of trehalose as the main sugar reserve or some similarities during mitosis and meiosis (Han and Weiss, 2017). Like in the Rozellomycota, adaption to obligate intracellular parasitism has led to gene loss, genome reduction and dependence upon the host for cell function (Quandt et al, 2017, Ndikumana et al., 2017). While many species tend to be considered secondary pathogens or linked to immunocompromised condition in human or veterinary medicine, numerous microsporidioses are involved in serious losses in aquaculture settings (El Alaoui et al, 2006, Kent et al. 2014, Palenzuela et al. 2014, Stentiford et al. 2016).

Multiple species of microsporidians have been reported in gilthead sea bream, *Sparus aurata* (GSB) (Faye et al. 1988, Abela et al. 1996, Athanassopoulou 1998, Morsy et al. 2013, Mathieu-Daude et al.) but seldom related to clinical diseases in aquaculture settings. An intranuclear species was found in Spanish GSB farms since the 00s, and its association with emaciative disease and dropping mortality was further established as new cases appeared in different facilities. This parasite was described as *Enterospora nucleophila* and its closest known relative is *Enterocytozoon hepatopenaei* (Palenzuela et al. 2014), a serious shrimp pathogen widespread in Asia (Thitamadee et al. 2016, Rajendran et al. 2016) and, recently, in South America (Tang et al. 2018). Since the emergency of the disease, it has been also detected in Italian and Greek GSB farms,

25 and in different facilities including on-growing net cages and land-based GSB nurseries
26 (Caffara et al. 2014 and authors' unpublished data). However, clinical infections only
27 affect certain fish lots or cages and they are not usually widespread within a given
28 facility. In addition, clinical presentation does not always correlate with detection of
29 microsporidian spores in large quantities and, likewise, presence of the parasite has
30 been registered in the absence of clinical symptoms. While specific PCR tests are an
31 invaluable tool for parasite surveillance and epidemiology, interpretation of the
32 disease dynamics and risk assessment are difficult to approach without deep
33 knowledge of the parasite development and pathogenesis.
34 The diagnosis of *E. nucleophila* is quite challenging due to its tiny size (spore width is
35 about 1 µm) and relatively sparse intranuclear development in certain intestinal
36 epithelial cells. The detection in histology slides is mainly limited to the spore stage,
37 and even these are difficult to identify in routine slides except when present in large
38 quantities. Use of fluorescent brighteners binding to chitin (e.g. calcofluor white) for
39 the detection of microsporidians largely improves the sensitivity in these contexts
40 (Freeman et al. 2013, Palenzuela et al. 2014, Alarcón et al. 2016, Herrero et al. 2018),
41 yet it only facilitates the detection of spores which is the only stage stained. In situ
42 hybridization techniques have been successfully used to circumvent similar limitations
43 in the closely related microsporidian *Enterocytozoon hepatopenaei* (Tang et al. 2015,
44 Rajendran et al. 2016), or in *Desmozoon lepeophtherii* (syn. *Paranucleospora theridion*)
45 (Weli et al. 2017). The main objective of this work was to develop an ISHbased
46 technique to detect *E. nucleophila* stages, getting insights into the development of the
47 parasite and the pathogenesis of GSM emaciative microsporidiosis.
48

MATERIALS AND METHODS

Fish

Sparus aurata specimens were collected from a Spanish GSB offshore net pen farm located at Southern Castellón (Comunidad Valenciana region). The facility had a background of *E. nucleophila* infections detected in previous surveys by our laboratory. During the winter season of 2016, a cage showing clear growth retardation and anorexia, abnormally high mortality rate and size segregation within the stock, which are signs of presumptive *E. nucleophila* infection in GSB (Palenzuela et al., 2004), was sampled. Fish were harvested using nets and the smaller, wasted fish were handpicked by the pathologists. Approximately 250 specimens (average weight: 43.4 g) were transferred alive to the Institute of Aquaculture "Torre de La Sal" (IATS) and maintained in 500L fiberglass tanks supplied with a flow-through natural water supply. The specimens were anaesthetized, sacrificed and sampled following routine procedures in compliance with European (86/609/EEC) and National (Royal Decree RD1201/2005) for the protection of animals used in scientific experiments, and approved by the CSIC ethics committee and IATS Review Board. A total of 60 individual fish were euthanized and sampled for downstream analyses. During the necropsies, small pieces of the anterior, middle and posterior intestine were dissected. Samples from different organs were also collected (liver, spleen, stomach, skeletal muscle, gall bladder, brain, gonads, head kidney and trunk kidney). Tissue pieces were immediately transferred to histology cassettes and fixed in 10% neutral buffered formalin for 1-2 weeks, before embedding into paraffin blocks following routine histological procedures. Some subsamples of tissue were embedded into methacrylate resin Technovit 7100 (Kultzer, Werheim, Germany).

73 Histology and calcofluor white staining.

74 Paraffin sections (5 µm thickness) corresponding to the organs of 60 fish were cut and
75 mounted onto electrostatically charged glass slides (Superfrost-Plus, Thermo Fisher
76 Scientific, Spain). They were stained with 0.1% calcofluor white M2R stain (CW) in
77 ddH2O with a drop of 10% potassium hydroxide, for 1 min. The slides were rinsed
78 immediately with 30% ethanol. A light counterstaining was achieved with 0.1% Evans
79 blue solution containing a few drops of glacial acetic acid for 1 min. Slides were
80 examined using an Olympus BX51 fluorescence microscope under UV excitation light.
81 Plastic sections (1 µm) were routinely stained with toluidine blue and examined under
82 visible light.

83

84 *E. nucleophila* probes design and In Situ Hybridization (ISH) procedure

85 The small subunit ribosomal DNA sequences of *E. nucleophila* isolates (Palenzuela et al.
86 2014) were used as target. A dataset containing all the sequences available under the
87 category "microsporidia" (2,450 entries, 209 Enterocytozoonidae) in the SSU_r132
88 database release by SILVA (Pruesse et al. 2007, www.arb-silva.de) was downloaded.
89 The alignment was pruned to the closest related Enterocytozoonidae sequences and
90 then refined manually according to secondary structure criteria using ARB software
91 (Ludwig 2004). Unique *E. nucleophila* oligonucleotide segments, or segments with
92 sufficient variation with respect to the closest taxa, were visually identified in the
93 alignment. Oligonucleotide antisense probes were designed to hybridize with the
94 positive strand of the gene (i.e., binding to both rDNA and rRNA of the parasite) at
95 these regions. Choice of the best probes according to specificity and thermodynamic
96 properties was aided by the software package OLIGO-7 (Rychlik 2007). Two

97 oligonucleotides were chosen: Enu_725L25 (5'TCC CAC ACC AA CAC CAC TTT CAT A-3')
98 and Enu_101L25 (5'-ATC CGT TCC GCC ATC TAT GTA CAT C-3'). They were modified
99 with 5' digoxigenin labels and sourced from a commercial supplier (Metabion Int.,
100 Germany), suspended at 100 uM in TE, and mixed in equimolar amounts as a
101 concentrated stock.
102 A panel of 32 samples was chosen representing individuals with assorted infection
103 status as determined by the results of the histopathological examination, including
104 Individuals in which few or no microsporidian spores were detected with CW. The ISH
105 procedure was carried out with these probes as described previously for other fish
106 parasites (Palenzuela & Bartholomew 2002, Cuadrado et al. 2007, Constenla et al.
107 2016), with some modifications. Deparaffinized and hydrated sections were treated
108 with 15 $\mu g.ml^{-1}$ proteinase K (45 minutes at 37 ^{o}C). They were then washed, denatured,
109 and incubated overnight at 37 ^{o}C with the mixture of probes diluted 1:500 in
110 hybridization buffer. Stringency washes were made twice in each decreasing
111 concentrations of SSC buffer (2x, 1x, and 0.25x), for 20 min each, at 40 ^{o}C under a
112 gentle rocking motion. The slides were equilibrated in 1x Genius Buffer at RT and the
113 immunological detection was conducted with AP-conjugated Fab fragments from
114 AntiDig sheep antiserum (Roche Diagnostics, Manheim, Germany), diluted 1:750 in
115 blocking solution and incubated for 2 hours at RT. The colorimetric reaction was
116 performed with NBT/BCIP substrate (nitro-blue tetrazolium chloride/ 5-bromo 4-
117 chloro- 3'indoly phosphate- p toluidine salt) for 2-8 hours at room temperature, until
118 optimum signal with low background was achieved. The slides were counterstained
119 with light green (1%), mounted in permanent medium and observed by light
120 microscopy.

121

122 RESULTS AND DISCUSSION

123 The histopathological study of clinically infected samples stained with fluorescent
124 brightener calcofluor white M2R clearly showed the localization of *E. nucleophila*
125 spores within the nuclei of enterocytes and rodlet cells (RCs), typically bunched in a
126 berrylike pattern clustering up to 25 spores (Fig. 1A). Spores were also detected in the
127 connective tissue and submucosae, either scattered or in large clusters, the later most
128 often within or around melanomacrophage centers (MMCs) (Fig. 1B). The findings
129 were consistent with previous histopathological and ultrastructural studies of this
130 infection (Palenzuela et al. 2014) demonstrating the primary intranuclear development
131 of the parasite in epithelial cells and its presence in cytoplasmic position within other
132 cells, including phagocytes at subepithelial layers. However, the increased sensitivity of
133 the fluorescent stain facilitated the detection of scattered spores in other locations, as
134 a consequence of degenerative changes in the epithelium, spore detachment, and host
135 cellular immune responses (Palenzuela et al. 2014, Sitja-Bobadilla et al. 2016). Scarce
136 spores were found in stomach, gall bladder, peripheral blood, or liver samples (Figs.
137 1C, 1D, and data not shown). Calcofluor white M2R is widely used to detect
138 microsporidian species due to the high affinity of this compound to bind the chitin
139 present at the microsporidia endospore membrane (Han and Weiss, 2017). Other
140 chemofluorescent agents, mostly stilbene derivatives typically used as whiteners in
141 detergents and in paper and fabrics manufacture, present similar properties acting as
142 chitin-specific stains (e.g., Hoch et al 2005, Rüchel & Schaffrinski 1999). Their use is
143 considered a credible technique for the diagnosis of microsporidians (Didier et al 1995,
144 García, 2002). However, these stains only bind to spores and not to other stages of

145 microsporidian cells devoid of chitin, and therefore other strategies are needed to
146 study microsporidian cells development in the host (Chen et al, 2017).
147 The ISH procedure produced intense blue-purple signals in clinically infected fish,
148 particularly in the intestinal mucosa (Fig. 1E). Detailed examination and double staining
149 with ISH and CW showed that the bulk of the ISH signal concentrated in cells
150 containing microsporidians under proliferative, pre-sporogony development phase and
151 in which *E. nucleophila* spores were not present (Fig. 1F). Indeed, scarce ISH signal was
152 present in mature spores which appeared mostly unstained when present (Fig.1G).
153 This pattern resulted quite revealing for the confirmation of the infection in samples
154 presenting the typical epithelial hypercellularity and nuclei alterations (Fig. 1H) often
155 associated to the *E. nucleophila* infection (Palenzuela et al. 2014), but in which
156 confirmatory diagnosis was not possible due to the absence of spores in routine
157 histopathological examination or in calcofluor-stained sections. The staining was a
158 clear result of the design of antisense probes targeting parasite rRNA present in the
159 infected host cells, most often within the nuclei (Fig 1I). This approach resulted in
160 enhanced sensitivity and, more importantly, in the ability to detect metabolically
161 active parasite stages containing many ribosomes. Light but noticeable ISH background
162 was present in some samples from infected stocks in which neither spores nor clearly
163 ISH-positive cells were present, but presenting large numbers of granulocytes and
164 other histopathological alterations associated to the infection (not shown). Since
165 background signal was never present in control uninfected samples or in control slides
166 without probes, it was interpreted to be caused by parasite remnants present in late
167 infections. However, it was not possible to determine if these patterns indicated a

168 recovery stage or a covert infection from which the parasite development could be
169 reactivated.
170 The scarce or absent ISH signal in mature spores is most likely related to a low number
171 of probe targets. Since scarce or null protein synthesis activity is present in mature
172 spores, the signal is mostly limited to parasite genomic rDNA copies. Some
173 microsporidians have extremely condensed genomes and scarce ribosomal gene
174 arrays, like *Encephalitozoon intestinalis* with the smallest known nuclear genome
175 (2.3Mbp) and only 11 rDNA arrays per haploid genome (Corradi et al. 2010).
176 Enterocytozoonidae species closely related to *E. nucleophila* are included in this trend,
177 with recent genome assemblies of 3.1 and 3.26 Mbp in *Enterospora canceri* and
178 *Enterocytozoon hepatopenaei*, respectively (Wiredu Boakye et al. 2017). However, the
179 low signal intensity observed in spores could also be partly related to incomplete
180 permeabilization of their shells. A very similar ISH staining pattern was described with
181 anti-sense RNA probes for the salmon microsporidian *Desmozoon lepeophtherii*, which
182 labelled strongly ribosome-rich merogonial and plasmodial stages (Weli et al. 2017). In
183 our procedure, the use of pre-labelled synthetic oligonucleotide probes instead of
184 longer lab-made RNA probes and has obvious advantages for practical purposes. Even
185 though ISH allowed clear detection of *E. nucleophila* developmental stages in GSB
186 tissues, these were not found in other organs except the intestine. Using CW staining,
187 however, microsporidian spores were occasionally found isolated or in small clusters in
188 peripheral blood, skeletal muscle, gall bladder, liver and stomach in some clinically
189 infected fish. These appear to be related to systemic spreading of advanced infections
190 and parasite clearing mechanisms more than to previously unidentified parasite
191 development niches in the fish. This observation is consistent with the pathogeny of

192 the disease, which is mostly evidenced as a chronic severe emaciation and growth
193 arrestment due to intestinal dysfunction. By ISH, it was evidenced that heavy
194 infections in clinically infected fish are not consistently associated with the presence of
195 large numbers of spores and, likewise, these tend to be present more abundantly in
196 samples with limited overall parasite activity. The limited epidemiological data on
197 emaciative microsporidiosis of GSB points to it as a chronic condition, as it results in
198 size segmentation of infected and uninfected fish within the same cage, reaching levels
199 equivalent to year-class differences in some cases (Palenzuela et al. 2014 and author's
200 unpublished observations). This suggests either a very slow development cycle or an
201 equilibrium between clearing of spores and reinfection of regenerated epithelia. The
202 development in the intestinal mucosa certainly opens the path for a direct release and
203 dispersion with fecal matter as in shrimp *E. hepatopenaei* (Tang et al. 2016). However,
204 extensive detachment of the epithelium and sloughing of tissue ribbons, like in the
205 GSB-infecting myxozoan *Enteromyxum leei* (Sitja-Bobadilla & Palenzuela 2011) are not
206 commonly observed in this infection. More likely, the results point to a late and
207 relatively modest sporulation prolificacy within the fish. Clearance of spores by
208 phagocytes and accumulation in MMC was observed, but it was mostly found in
209 advanced infections with little parasite load and activity. Although *E. nucleophila* is
210 rooted in a clade of crustacean-infecting enterocytozoonids (Palenzuela et al. 2014) in
211 which copious sporulation is the norm, the existence of alternate hosts for this species
212 is yet unknown.
213 In summary, the ISH procedure developed in this work appears as a valuable tool for
214 the confirmatory diagnosis of *E. nucleophila* infections in GSB. Although calcofluor
215 staining is an easy method to detect spores, their presence and amount was often

found to be disassociated of the true infection intensity in terms of number of infected host cells. Using the ISH in combination with calcofluor fluorescence staining and conventional histopathological techniques in a stock of clinically infected GSB, we found that the parasite restricts its proliferation and development to the intestine epithelium although isolated spores can reach peripheral blood, and occasionally other digestive and blood-rich organs. Determination of more precise parasite dissemination pathways and pathogeny mechanisms depend on the ability to conduct experimental infections and time-course infection analyses with this parasite.

CONFLICT OF INTEREST STATEMENT

The Authors declare that there is no conflict of interest.

REFERENCES

Abela M, Brinch-Iversen J, Tanti J, Le Breton A (1996) Occurrence of a new histozoic microsporidian (Protozoa, Microspora) in cultured gilt head sea bream *Sparus aurata* L. Bull Eur Ass Fish Pathol 16: 196–199.

Alarcón M, Thoen E, Poppe TT, Bornø G, Mohammad SN, Hansen H (2016) Co-infection of *Nucleospora cyclopteri* (Microsporidia) and *Kudoa islandica* (Myxozoa) in farmed lumpfish, *Cyclopterus lumpus* L., in Norway: a case report. J Fish Dis 39: 411–418

Athanassopoulou F (1998) A case report of *Pleistophora* SP. infection in cultured sea bream (*Sparus aurata* L.) in Greece. Bull Eur Ass Fish Pathol 18: 19–21

239 Caffara M, Sirri R, Mandrioli L, Gustinelli A, Fioravanti ML (2014) Sindrome emaciativa
240 da *Enterospora nucleophila* (Microsporidia) in orate (*Sparus aurata*) allevate in
241 Italia**.** Proceedings of the XX Convegno Nazionale SIPI **(**Certosa di Calci**,** Pisa), p 44.
242 Chen J, Guo W, Dang X, Huang Y, Liu F, Meng X, An Y, Long M, Bao J, Zhou Z, Xiang Z,
243 Pan G (2017) Easy labeling of proliferative phase and sporogonic phase of
244 microsporidia *Nosema bombycis* in host cells. PloS one *12*(6), e0179618.
245 Constenla M, Padros F, del Pozo R, Palenzuela O (2016) Development of different
246 diagnostic techniques for *Endolimax piscium* (archamoebae) and their applicability
247 in *Solea senegalensis* clinical samples. J Fish Dis 39: 1433-1443.
248 Corradi N, Pombert J-F, Farinelli L, Didier ES, Keeling PJ (2010) The complete sequence
249 of the smallest known nuclear genome from the microsporidian *Encephalitozoon*
250 *intestinalis*. Nat Commun 1: 77.
251 Cuadrado M, Albinyana G, Padros F, Redondo MJ, Sitja-Bobadilla A, Alvarez-Pellitero P,
252 Palenzuela O, Diamant A, Crespo S (2007) An unidentified epi-epithelial
253 myxosporean in the intestine of gilthead sea bream *Sparus aurata* L. Parasitol Res
254 101: 403–411.
255 Didier ES, Orenstein JM, Aldras A, Bertucci D, Rogers LB, Janney FA (1995) Comparison
256 of three staining methods for detecting microsporidia in fluids. J Clin Microbiol,
257 *33*(12): 3138–3145.
258 El Alaoui H, Grésoviac SJ, Vivarès CP (2006) Occurrence of the microsporidian parasite
259 *Nucleospora salmonis* in four species of salmonids from the Massif Central of
260 France. Folia Parasitol. 53(1): 37-43.

261 Faye N, Tohuebaye BS, Bouix G (1988) Ultrastructure and development of *Pleistophora*
262 *senegalensis* sp. nov. (Protozoa, Microspora) from the gilt-head sea bream, *Sparus*
263 *aurata* L. (Teleost, Sparidae) from the coast of Senegal. J Fish Dis 13:179–192.
264 Freeman MA, Kasper JM, Kristmundsson Á (2013) *Nucleospora cyclopteri* n. sp., an
265 intranuclear microsporidian infecting wild lumpfish, *Cyclopterus lumpus* L., in
266 Icelandic waters. Parasites & Vectors 6:49.
267 Garcia L S (2002) Laboratory identification of the microsporidia. J Clin Microbiol *40*
268 (6): 1892–1901.
269 Han B, Weiss LM (2017) Microsporidia: Microsporidia: Obligate Intracellular
270 Pathogens Within the Fungal Kingdom, p 97-113. In Heitman J, Howlett B,
271 Crous P, Stukenbrock E, James T, Gow N (ed), The Fungal Kingdom. ASM Press,
272 Washington, DC (DOI: 10.1128/microbiolspec.FUNK-0018-2016).
273 Herrero A, Thompson KD, Ashby A, Rodger HD, Dagleish MP (2018) Complex Gill
274 Disease: an Emerging Syndrome in Farmed Atlantic Salmon (*Salmo salar* L.). J
275 Comp Pathol 163: 23–28.
276 Hoch HC, Galvani CD, Szarowski DH, Turner J (2005) Two new fluorescent dyes
277 applicable for visualization of fungal cell walls. Mycologia 97: 580-588.
278 Kent ML, Shaw RW, Sanders JL (2014) Microsporidia in Fish. In: Weiss LM, Becnel JJ
279 (eds) Microsporidia: Pathogens of Opportunity: First Edition. John Wiley & Sons,
280 Inc., Chichester, UK, p 493–520.
281 Larsson JI (2000) The hyperparasitic microsporidium *Amphiacantha longa* Caullery et
282 Mesnil, 1914 (Microspora: Metchnikovellidae) - description of the cytology,
283 redescription of the species, emended diagnosis of the genus *Amphiacantha* and
284 establishment of the new family Amphiacanthidae. Folia Parasitol 47: 241–256.

285 Ludwig W (2004) ARB: a software environment for sequence data. Nucleic Acids Res
286 32: 1363–1371.
287 Mathieu-Daude F, Faye N, Coste F, Monier JF, Marques A, Bouix G (1992) Occurence of
288 a microsporidiosis in marine cultured gilt-head sea bream from the Languedoc
289 coast: a problem of specificity in the genus *Glugea* (Protozoa, Microspora). Bull Eur
290 Ass Fish Pathol 12(2): 67-70.
291 Morsy K, Bashtar AR, Abdel-Ghaffar F, Al-Quraishy S (2013) Morphological and
292 phylogenetic description of a new xenoma-inducing microsporidian,
293 *Microsporidium aurata* nov. sp., parasite of the gilthead seabream *Sparus aurata*
294 from the Red Sea. Parasitol Res 112: 3905–3915.
295 Ndikumana S, Pelin A, Williot A, Sanders JL, Kent M, Corradi N (2017) Genome analysis
296 of *Pseudoloma neurophilia*: a microsporidian parasite of zebrafish (*Danio rerio*). J
297 Euk Microbiol 64:18– 30.
298 Palenzuela O, Bartholomew JL (2002) Molecular Tools for the Diagnosis of *Ceratomyxa*
299 *Shasta* (Myxozoa). In: C O Cunningham (ed) Molecular Diagnosis of Salmonid
300 Diseases, chapter 11, p 285–298. Springer Netherlands, Dordrecht.
301 Palenzuela O, Redondo MJ, Cali A, Takvorian PM, Alonso-Naveiro M, Alvarez-Pellitero
302 P, Sitja-Bobadilla A (2014) A new intranuclear microsporidium, *Enterospora*
303 *nucleophila* n. sp., causing an emaciative syndrome in a piscine host (*Sparus*
304 *aurata*), prompts the redescription of the family Enterocytozoonidae. Int J
305 Parasitol 44: 189–203.
306 Pruesse E, Quast C, Knittel K, Fuchs BM, Ludwig W, Peplies J, Glöckner FO (2007) SILVA:
307 a comprehensive online resource for quality checked and aligned ribosomal RNA
308 sequence data compatible with ARB. Nucleic Acids Res 35: 7188–7196.

309 Rüchel R, Schaffrinski M (1999) Versatile fluorescent staining of fungi in clinical
310 specimens by using the optical brightener Blankophor**.** J Clin Microbiol 37(8): 2694-
311 2696.
312 Quandt CA, Beaudet D, Corsaro D, Walochnik J , Michel R , Corradi N, James TY (2017)
313 The genome of an intranuclear parasite, *Paramicrosporidium saccamoebae*,
314 reveals alternative adaptations to obligate intracellular parasitism. eLife
315 2017;6:e29594 (DOI: 10.7554/eLife.29594).
316 Rajendran KV, Shivam S, Ezhil Praveena P, Joseph Sahaya Rajan J, Sathish Kumar T,
317 Avunje S, Jagadeesan V, Prasad Babu SVANV, Pande A, Navaneeth Krishnan A,
318 Alavandi SV, Vijayan KK (2016) Emergence of *Enterocytozoon hepatopenaei* (EHP)
319 in farmed Penaeus (*Litopenaeus vannamei*) in India. Aquaculture 454: 272–280.
320 Rychlik W (2007) OLIGO 7 primer analysis software. Methods Mol Biol 402: 35–60.
321 Scheid P, Zöller L, Pressmar S, Richard G, Michel R (2008) An extraordinary
322 endocytobiont in *Acanthamoeba* sp. isolated from a patient with keratitis.
323 Parasitol Res 102: 945–950.
324 Sitja-Bobadilla A, Estensoro I, Perez-Sanchez J (2016) Immunity to gastrointestinal
325 microparasites of fish. Dev Comp Immunol 64: 187–201.
326 Stentiford GD, Becnel JJ, Weiss LM, Keeling PJ, Didier ES, Williams BAP, Bjornson S,
327 Kent ML, Freeman MA, Brown MJF, Troemel ER, Roesel K, Sokolova Y, Snowden KF,
328 Solter L (2016) Microsporidia – Emergent Pathogens in the Global Food Chain.
329 Trends Parasitol 32:3 36–348.
330 Tang K, Aranguren F, Han JE, Maskaykina I, Schmidt M, Lightner DV, Lightner D (2017)
331 Histopathology and in situ detection of the microsporidian *Enterocytozoon*

hepatopenaei (EHP) In *Penaeus vannamei* cultured in a Latin America country. Proc. Aquaculture America 2017 (WAS-AA), San Antonio, Texas (USA), p 481.

Tang KFJ, Han JE, Aranguren LF, White-Noble B, Schmidt MM, Piamsomboon P, Risdiana E, Hanggono B (2016) Dense populations of the microsporidian *Enterocytozoon hepatopenaei* (EHP) in feces of *Penaeus vannamei* exhibiting white feces syndrome and pathways of their transmission to healthy shrimp. J Invert Pathol 140: 1–7.

Tang KFJ, Pantoja CR, Redman RM, Han JE, Tran LH, Lightner DV (2015) Development of in situ hybridization and PCR assays for the detection of *Enterocytozoon hepatopenaei* (EHP), a microsporidian parasite infecting penaeid shrimp. J Invert Pathol 130:37–41.

Thitamadee S, Prachumwat A, Srisala J, Jaroenlak P, Salachan PV, Sritunyalucksana K, Flegel TW, Itsathitphaisarn O (2016) Review of current disease threats for cultivated penaeid shrimp in Asia. Aquaculture 452: 69–87.

Weli SC, Dale OB, Hansen H, Gjessing MC, Rønneberg LB, Falk K (2017) A case study of *Desmozoon lepeophtherii* infection in farmed Atlantic salmon associated with gill disease, peritonitis, intestinal infection, stunted growth, and increased mortality. Parasites & Vectors 10: 370.

Wiredu Boakye D, Jaroenlak P, Prachumwat A, Williams TA, Bateman KS, Itsathitphaisarn O, Sritunyalucksana K, Paszkiewicz KH, Moore KA, Stentiford GD, Williams BAP (2017) Decay of the glycolytic pathway and adaptation to intranuclear parasitism within Enterocytozoonidae microsporidia. Environ Microbiol 19: 2077–2089.

356 FIGURE LEGENDS

357

358 Figure 1: Histology sections of gilthead sea bream tissues infected by *Enterospora*
359 *nucleophila*. A: Infected intestine epithelium showing clusters of intranuclear
360 (arrowheads) and cytoplasmatic (arrows) spores (calcofluor white stain, CW). B: Detail
361 of a melanomacrophage center (MMC) at the intestinal submucosa. Note the bright
362 calcofluor-positive material accumulated within the MMC and in some microsporidian
363 spores at the periphery (double stain with toluidine blue and CW). C & D: *Enterospora*
364 *nucleophila* spores in the gall bladder and the blood, respectively (CW). E: Panoramic
365 view of a heavily infected intestine stained with the ISH procedure, showing
366 conspicuous purple positive cells contrasting with the light green counterstain. F:
367 Panoramic view of an infected intestine. Note the different staining patterns with the
368 ISH (strongly positive cells containing replicating stages stained as deep purple,
369 arrowheads) and the CW (bright blue clusters of mature spores, arrows) (double stain
370 with CW and ISH, photographed under simultaneous visible and UV light). G: Detail of
371 an intestinal epithelium containing –different developmental stages of *E. nucleophila*.
372 Mature spores are mostly unstained (arrows). H: Toluidine blue-stained plastic section
373 showing the typical hypercellularity and altered nuclei often associated with *E.*
374 *nucleophila* infection. I: Detail of ISH-staining pattern in a similar infection to that
375 shown in H. Note the ISH signal with variable intensity in different cells, proportional to
376 the parasite activity and concentrating within the cell nuclei. Scale bars: 20 µm (A & B);
377 10 µm (C); 5 µm (D); 50 µm (Figs. E, G & I); 25 µm (F); 10 µm (H).

378

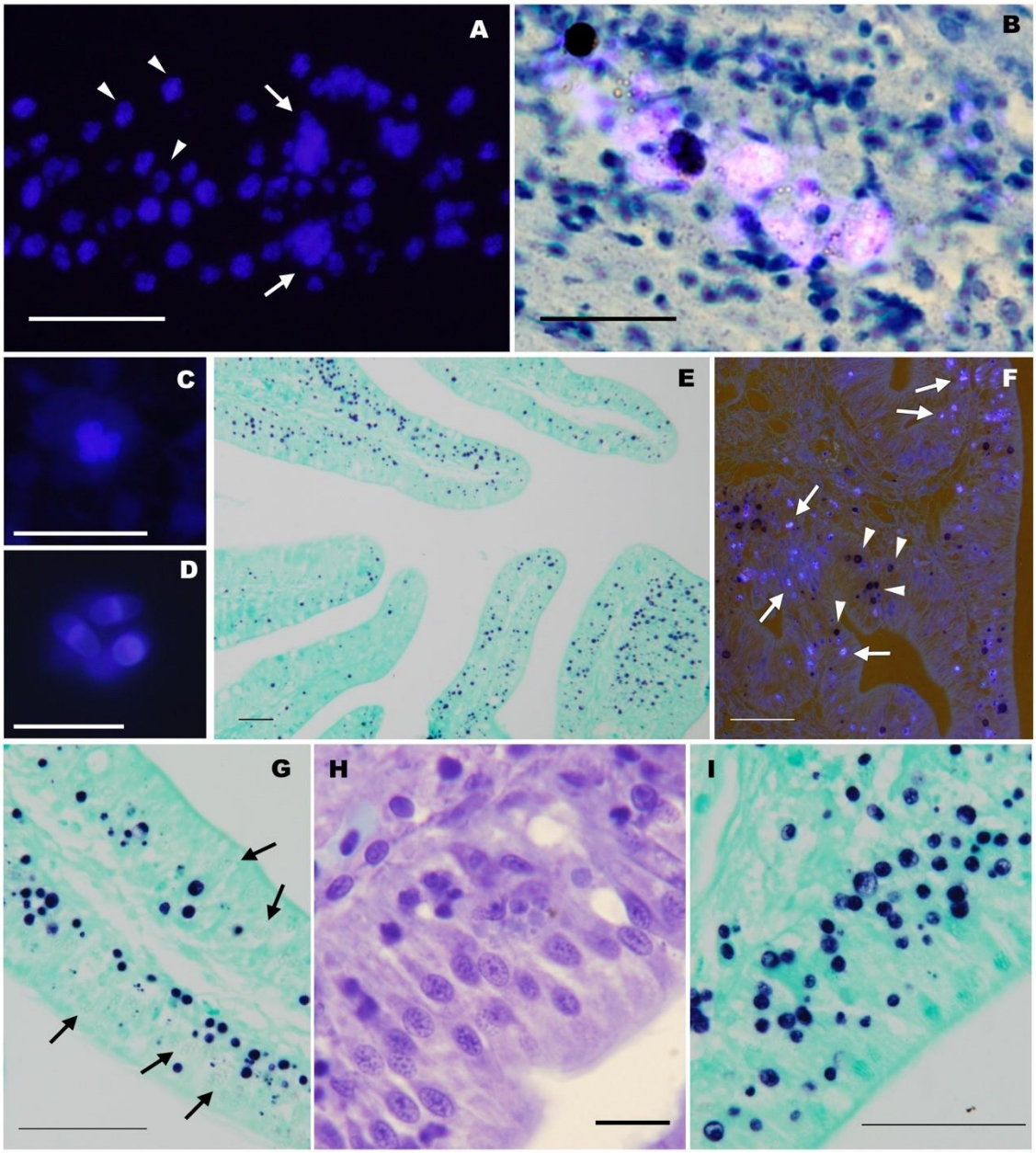

381