

Romiplostim as early treatment of immune thrombocytopenia with severe immunodeficiency

Francesca Palandri,¹ Nicola Polverelli,¹
Francesca Lifrieri,² Lucia Catani,¹
Maria Benedetta Giannini,³
Michele Baccarani,¹ Nicola Vianelli¹

¹Department of Hematology and Oncology L. e A. Seràgnoli, St. Orsola-Malpighi Hospital, University of Bologna;
²Nefrology Unit, Pierantoni Hospital, Forlì; ³Istituto Oncologico Romagnolo per la cura dei tumori, Meldola, Forlì, Italy

Abstract

Immunosuppressive agents are the standard therapeutic approach for immune thrombocytopenia (ITP). Their prolonged use may increase the risk of infectious complications, particularly when the patient is already at higher infectious risk. In this setting, the use of drugs with a mechanism of action alternative to immunosuppression, like thrombopoietin receptor agonists (TRAs), may find particular indication. We report the unique case of a patient with severe immunodeficiency and ITP, who experienced a serious infectious complication while on steroids treatment, and who was successfully treated with Romiplostim second-line. The present experience supports the effectiveness and safety of TRAs as early treatment of ITP patients with drug-induced immunodeficiency or with active infections.

Introduction

Immune thrombocytopenia (ITP) is characterized by an immune-mediated reduction of platelet count ($<100 \times 10^9/L$) in absence of other obvious causative factors.¹ Platelet destruction is mainly due to the formation of auto-antibodies against platelet surface antigens and to rapid elimination of antibody-coated platelets by macrophages and dendritic cells in the spleen. Additionally, auto-antibodies and activated T-lymphocytes seem to directly impair megakaryocytes in the bone marrow, causing a suboptimal platelet production. Standard front-line therapy for ITP are steroids (prednisone or dexamethasone), achieving initial responses in about 80% of the cases.² However, response is sustained only in 10-30% of the cases, and most patients require further treatment. Splenectomy is an established second-line therapy for ITP, achieving a durable

response in about 60% of patients; however, it might be unfeasible in some patients, and is often delayed in other patients due to the risks related to the surgical procedure.³ Medical approaches for unresponsive/refractory ITP include conventional immunosuppressive agents and rituximab,¹ a CD20 receptor antibody that impairs B-cell response and antibody formation.⁴ All these approaches are jeopardized by the risks of infectious complications consequent to immunosuppression. This is particularly relevant when the patient already carries comorbidities whose treatments increase the infectious risk, such as chronic immunosuppressive therapies. In this setting, the use of drugs with a mechanism of action alternative to immunosuppression may find particular indication. In 2008, agents that directly stimulate the thrombopoietin (TPO) receptor, increasing platelet production, were approved for treatment of chronic ITP.⁵⁻⁶ TPO receptor agonists (TRAs), such as romiplostim and eltrombopag may be particularly efficacious for ITP patients with immunodeficiency. Ineffective platelet production may be a more prominent cause of thrombocytopenia in ITP with drug-induced immunodeficiency, since thrombocytopenia develops during the course of immunosuppressive treatments usually active in ITP. TRAs may provide more effective correction of this abnormality, and may also be safer than standard therapies. Indeed, TPO-mimetics can achieve rapid and sustained responses, without increasing the danger of serious infectious complications. To support the principle that TPO-mimetic agents are effective and safe long-term treatment for immunocompromised ITP patients, we report the case of a man who has been successfully treated for 12 months.

Case Report

A 47-year-old man was referred to our department in May 2010 because of isolated severe thrombocytopenia (platelet count: $8 \times 10^9/L$) with positivity of antiplatelet antibodies test, in absence of clinically significant hemorrhagic syndrome. His personal data were notable for a liver transplant which was performed in 1997, due to hepatitis B virus and hepatitis C-related cirrhosis. For that reason, the patient was treated with Ciclosporin A, Mycophenolate and low-dose prednisone. Additionally, the patient was on dialysis since February 2010, following bilateral nephrectomy occurred for detection of clear cell renal carcinoma. A bone marrow biopsy was suggestive with ITP, showing an activated megakaryocytopoiesis and normal reticulatin distribution in absence of a myelodysplastic/lymphoproliferative disorder. According to standard clinical practice, the patient was treated front-

Correspondence: Francesca Palandri, Department of Hematology and Oncology L. & A. Seràgnoli, Via Massarenti 9, 40138, Bologna, Italy.
Tel. +39.051.6363680 - Fax: +39.051.6364037.
E-mail: francesca.palandri@libero.it

Key words: immune thrombocytopenia, romiplostim, TPO receptor agonist, immunodeficiency.

Acknowledgment: the research was supported by the University of Bologna (Funds for selected topics), by the EuropeanLeukemiaNet and by BolognALL.

Received for publication: 11 January 2012.
Accepted for publication: 1 March 2012.

This work is licensed under a Creative Commons Attribution NonCommercial 3.0 License (CC BY-NC 3.0).

©Copyright F. Palandri et al., 2012
Licensee PAGEPress, Italy
Hematology Reports 2012; 4:e10
doi:10.4081/hr.2012.e10

line with prednisone 1 mg/kg/day, obtaining only a transient response of thrombocytopenia (Figure 1). After 3 weeks of consecutive treatment, the patient developed a septic shock, with cardio-respiratory failure, due to a *Listeria monocytogenes*-induced meningoencephalitis. Leukocyte count and immunoglobulin levels were normal. To face the infectious problem, steroids and immunosuppressive agents were rapidly discontinued. Consequently, platelet count returned below $10 \times 10^9/L$ and the patient experienced bleeding from the gastrointestinal tract, which required transfusions and intravenous immune globulin (1 g/kg/d for 2 days). When the patient recovered from the infectious complication, Romiplostim treatment was initiated with weekly administrations, as per standard protocol. Doses were escalated from 1 to 2 g/kg after 2 weeks of treatment because of no response. A rapid and steady increase in platelet count over $50 \times 10^9/L$ followed dose escalation. He is currently maintained on 2 g/kg of romiplostim weekly. Throughout the observation time, the patient has felt well, with no infectious complications or relapse of thrombocytopenia. No major side effects have been observed, including thrombotic events and worsening of comorbidities.

Discussion and Conclusions

The front-line therapy of ITP patients with immunodeficiency is particularly challenging, as these patients are more vulnerable to the toxicity induced by immunosuppressive agents.

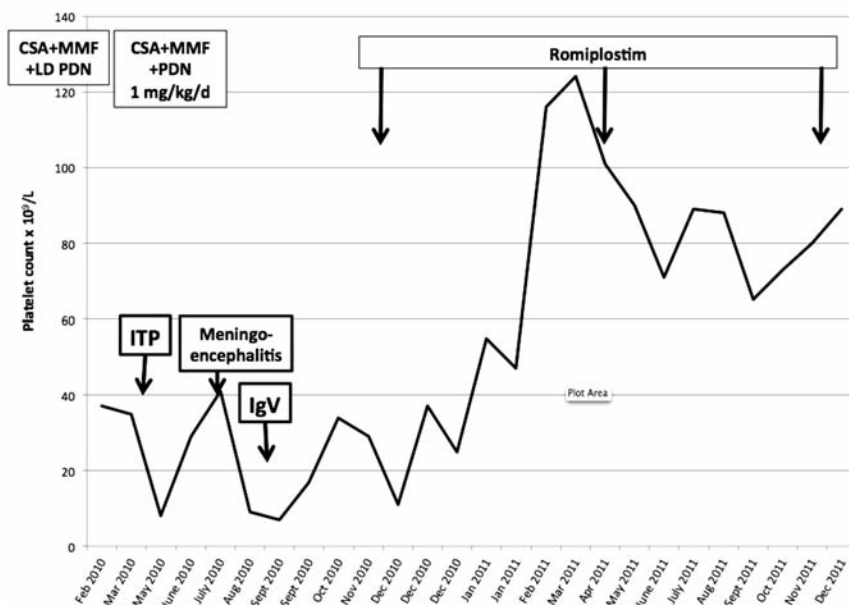


Figure 1. Platelet counts before immune thrombocytopenia (ITP) onset to 18-month follow-up. The patient was already on immunosuppressant treatment with Cislosporin A, Mycophenolate and low-dose prednisone, because of a previous liver transplant. Front-line steroid treatment for ITP reached only a transient response on platelet count but contributed to the development of a severe infectious complication (meningoencephalitis). After the first 3 weeks of romiplostim the platelet count rapidly increased above $50 \times 10^9/L$. Over the following months, the platelet count remained stable at around $70 \times 10^9/L$.

Among available therapeutic options, only TPO receptor agonists act by stimulating platelet production and does not alter the normal immune function. In published clinical trials,⁷⁻⁹ the rate and the rapidity of response to romiplostim in chronic ITP patients were higher than those observed with other second-line therapies, including rituximab and conventional immunosuppressive drugs. Furthermore, romiplostim was associated with a favorable toxicity profile, and a better quality of life.⁸ The present experience supports the effectiveness

and safety of TPO receptor agonists as treatment of ITP patients with drug-induced immunodeficiency or with active infections, and encourage their early administration in this setting.

References

1. Provan D, Stasi R, Newland AC, et al. International consensus report on the

investigation and management of primary immune thrombocytopenia. *Blood* 2010; 115:168-86.

2. Zaja F, Bacarani M, Mazza P, et al. Dexamethasone plus rituximab yields higher sustained response rates than dexamethasone monotherapy in adults with primary immune thrombocytopenia. *Blood* 2010;115:2755-62.
3. Kojouri K, Vesely SK, Terrell DR, George JN. Splenectomy for adult patients with idiopathic thrombocytopenic purpura: a systematic review to assess long term platelet count responses, prediction of response, and surgical complications. *Blood* 2004;104:2623-34.
4. Alasfoor K, Alrasheed M, Alsayegh F, Mousa SA. Rituximab in the treatment of idiopathic thrombocytopenic purpura (ITP). *Ann Hematol* 2009;88:239-43.
5. Kuter DJ, Bussel JB, Lyons RM, et al. Efficacy of romiplostim in patients with chronic immune thrombocytopenic purpura: a double-blind randomised controlled trial. *Lancet* 2008;37:95-403.
6. Bussel JB, Cheng G, Saleh MN, et al. Eltrombopag for the treatment of chronic idiopathic thrombocytopenic purpura. *N Engl J Med* 2007;357:2237-47.
7. Kuter DJ, Rummel M, Boccia R, et al. Romiplostim or standard of care in patients with immune thrombocytopenia. *N Engl J Med* 2009;363:1889-99.
8. Gernsheimer TB, George JN, Aledort LM, et al. Evaluation of bleeding and thrombotic events during long-term use of romiplostim in patients with chronic immune thrombocytopenia (ITP). *J Thromb Haemost* 2010;8:1372-82.
9. Khellaf M, Michel M, Quittet P, et al. Romiplostim safety and efficacy for immune thrombocytopenia in clinical practice: 2-year results of 72 adults in a romiplostim compassionate-use program. *Blood* 2011;118:4338-45.