

Combining CEUS and CT/MRI LI-RADS Major Imaging Features: Diagnostic Accuracy for Classification of Indeterminate Liver Observations in Patients at Risk for HCC

Journal Name: Abdominal Radiology Journal

Tania Siu Xiao, MD¹; Cristina Mariuxi Kuon Yeng Escalante, MD¹; Aylin Tahmasebi, MD¹; Yuko Kono, MD, PhD, FAIUM, FAASLD²; Fabio Piscaglia, MD, PhD^{3,4}; Stephanie R. Wilson, MD, FRCPC⁵; Alexandra Medellin-Kowalewski, MD, FRCPC⁵; Shuchi K. Rodgers, MD^{1,6}; Virginia Planz, MD⁷; Aya Kamaya, MD⁸; David T. Fetzer, MD⁹; Annalisa Berzigotti, MD, PhD¹⁰; Iuliana-Pompilia Radu, MD¹⁰; Paul S. Sidhu, BSc, MBBS, MRCP, FRCR, DTM&H, FCIRSE, FAIUM¹¹; Corinne E. Wessner, MS, MBA, RDMS, RVT¹; Kristen Bradigan, RN, BSN¹; John R. Eisenbrey, PhD¹; Flemming Forsberg, PhD, FAIUM, FAIMBE¹; Andrej Lyshchik, MD, PhD¹; CEUS LI-RADS Trial Group.

¹ Thomas Jefferson University Hospital, Philadelphia PA, United States

² University of California, San Diego, San Diego CA, United States

³ Division of Internal Medicine, Hepatobiliary and Immunoallergic Diseases, IRCCS Azienda Ospedaliero-Universitaria di Bologna, Italy

⁴ Department of Medical and Surgical Sciences, University of Bologna, Italy

⁵ University of Calgary, Calgary, Canada

⁶ Einstein Medical Center, Philadelphia PA, United States

⁷ Vanderbilt University, Nashville TN, United States

⁸ Stanford University, Stanford CA, United States

⁹ UT Southwestern Medical Center, Dallas, TX, United States

¹⁰ Department of Visceral Surgery and Medicine, Bern University Hospital, University of Bern, Bern, Switzerland

¹¹ Department of Imaging Sciences, School of Biomedical Engineering and Imaging Sciences, Faculty of Life Sciences and Medicine, King's College London. Department of Radiology, King's College Hospital, London, UK

Corresponding Author:

Andrej Lyshchik

Associate Professor of Radiology

andrej.lyshchik@jefferson.edu

SUPPLEMENTAL TABLES AND FIGURES

Online Resource 1 Combination groups of multimodality imaging with LI-RADS imaging major features

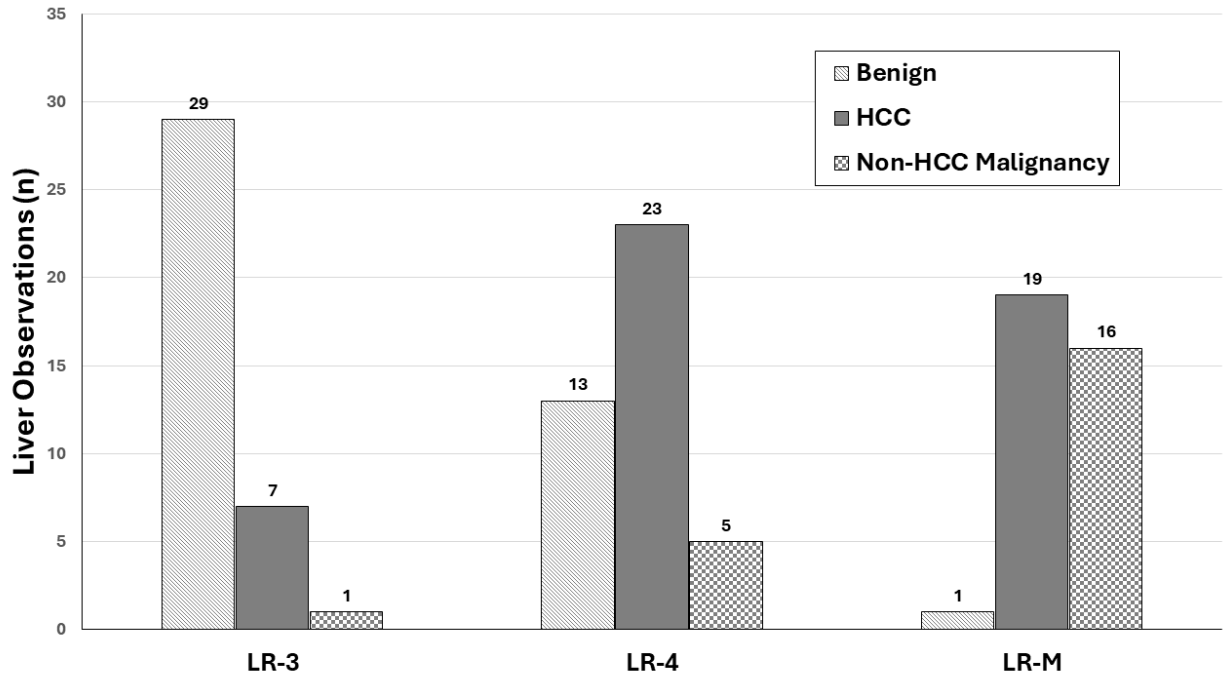
Groups	Multimodality Combinations of LI-RADS Major Features
#1	CEUS APHE + CT/MRI APHE
#2	CEUS APHE + CT/MRI WO
#3	CEUS WO + CT/MRI APHE
#4	CEUS WO + CT/MRI WO
#5	CT/MRI APHE + CEUS late and mild WO
#6	CT/MRI WO + CEUS late and mild WO
#7	CEUS APHE + CT/MRI (capsule enhancement)
#8	CEUS APHE + CT/MRI (threshold growth)
#9	CEUS late and mild WO + CT/MRI (capsule enhancement)
#10	CEUS late and mild WO + CT/MRI (threshold growth)

APHE = arterial-phase hyper-enhancement, CEUS = contrast-enhanced ultrasound, CT = computed tomography, LI-RADS = Liver Imaging Reporting and Data System, MRI = magnetic resonance imaging, WO = washout (regardless of timing or degree)

Online Resource 2 Variables used for the stepwise logistical regression analysis

VARIABLES	DESCRIPTION
Dependent	
<i>Pathology (Subgroup 1)</i>	Benign or all malignancy (HCC and non-HCC malignancy)
<i>Pathology (Subgroup 2)</i>	HCC or everything else (benign and non-HCC malignancy)
Independent	
<i>CEUS APHE</i>	Hypo-enhancement, iso-enhancement, rim-enhancement, or hyperenhancement
<i>CEUS WO (Presence)</i>	Absent or present
<i>CEUS WO (Degree)</i>	Mild or marked
<i>CEUS WO (Time)</i>	Early or late
<i>CEUS WO (Time + Degree)</i>	Early, late + marked, or late + mild
<i>CT/MRI APHE</i>	Hypo-enhancement, iso-enhancement, rim-enhancement, hyperenhancement, or peripheral discontinuous enhancement
<i>CT/MRI WO</i>	Absent or present
<i>CT/MRI capsule enhancement</i>	Absent or present
<i>CT/MRI threshold growth</i>	Absent or present
<i>CEUS LI-RADS categories</i>	LR-3, LR-4, LR-M, or LR-TIV
<i>CT/MRI LI-RADS categories</i>	LR-3, LR-4, or LR-M
<i>Age</i>	Original value
<i>BMI</i>	Original value

APHE = arterial-phase hyper-enhancement, BMI = body mass index, CEUS = contrast-enhanced ultrasound, CT = computed tomography, HCC = hepatocellular carcinoma, LI-RADS = Liver Imaging Reporting and Data System, MRI = magnetic resonance imaging, WO = washout



Online Resource 3 Final diagnosis of initial CT/MRI indeterminate liver observations

HCC = hepatocellular carcinoma

Online Resource 4 Initial CEUS and CT/MRI LI-RADS classification of liver observations with the final diagnosis

Final Diagnosis		Initial CEUS LI-RADS	Initial CT/MRI LI-RADS	Total cases (n)
Benign				
<i>Follow-up CT/MRI</i>	LR-3	28	27	35
	LR-4	6	8	
	LR-M	1	0	
<i>Biopsy</i>	LR-3	0	0	5
	LR-4	5	4	
	LR-M	0	1	
<i>Explant Histology</i>	LR-3	3	2	3
	LR-4	0	1	
	LR-M	0	0	
HCC				
<i>Follow-up CT/MRI</i>	LR-3	6	3	17
	LR-4	10	11	
	LR-M	1	3	
<i>Biopsy</i>	LR-3	5	3	23
	LR-4	11	6	
	LR-M	6	14	
	LR-TIV	1	0	
<i>Explant Histology</i>	LR-3	5	1	9
	LR-4	2	6	
	LR-M	2	2	
Other malignancy				
<i>Follow-up CT/MRI</i>	LR-3	0	0	1
	LR-4	0	0	
	LR-M	1	1	
<i>Biopsy</i>	LR-3	0	0	20
	LR-4	2	5	
	LR-M	18	15	
<i>Explant Histology</i>	LR-3	1	1	1
	LR-4	0	0	
	LR-M	0	0	

CEUS = contrast-enhanced ultrasound, CT = computed tomography, HCC = hepatocellular carcinoma, LI-RADS = Liver Imaging Reporting and Data System, MRI = magnetic resonance imaging

Online Resource 5 Distribution of CEUS and CT/MRI LI-RADS major features for all indeterminate liver nodules

CEUS* LI-RADS Major Features		CT/MRI LI-RADS Major Features	
CEUS LR-3	n	CT/MRI LR-3	n
Total Nodules	48	Total Nodules	37
APHE		APHE	
• Hyperenhancement	1	• Hyperenhancement	16
• Isoenhancement	32	• Isoenhancement	13
• Hypoenhancement	15	• Hypoenhancement	7
• Rim-enhancement	0	• Rim-enhancement	0
		• No Enhancement	1
WO		WO	
• Present	3	• Present	8
• Absent	45	• Absent	29
WO Timing		Capsule Enhancement	
• Early	0	• Present	0
• Late	3	• Absent	37
WO Degree		Threshold Growth	
• Mild	3	• Present	0
• Marked	0	• Absent	37
CEUS LR-4	n	CT/MRI LR-4	n
Total Nodules	36	Total Nodules	41
APHE		APHE	
• Hyperenhancement	26	• Hyperenhancement	27
• Isoenhancement	5	• Isoenhancement	11
• Hypoenhancement	5	• Hypoenhancement	2
• Rim-enhancement	0	• Rim-enhancement	0
		• Peripheral Discontinuous Enhancement	1
WO		WO	
• Present	9	• Present	13
• Absent	27	• Absent	28
Wo Timing		Capsule Enhancement	
• Early	0	• Present	6
• Late	9	• Absent	35
Wo Degree		Threshold Growth	
• Mild	9	• Present	5

• Marked	0	• Absent	36
CEUS LR-M	n	CT/MRI LR-M	n
Total Nodules	29	Total Nodules	36
APHE		APHE	
• Hyperenhancement	12	• Hyperenhancement	9
• Isoenhancement	2	• Isoenhancement	3
• Hypoenhancement	2	• Hypoenhancement	0
• Rim-Enhancement	13	• Rim-enhancement	24
WO		WO	
• Present	28	• Present	10
• Absent	1	• Absent	26
WO Timing		Capsule Enhancement	
• Early	13	• Present	3
• Late	15	• Absent	33
WO Degree		Threshold Growth	
• Mild	12	• Present	10
• Marked	16	• Absent	26

Note. *CEUS LI-RADS classified one nodule as LR-TIV (isoenhancement, WO present, late WO, and mild WO). For this case, CT/MRI LI-RADS classified it as LR-3 (Hypoenhancement, WO absent, no capsule enhancement, and no threshold growth).

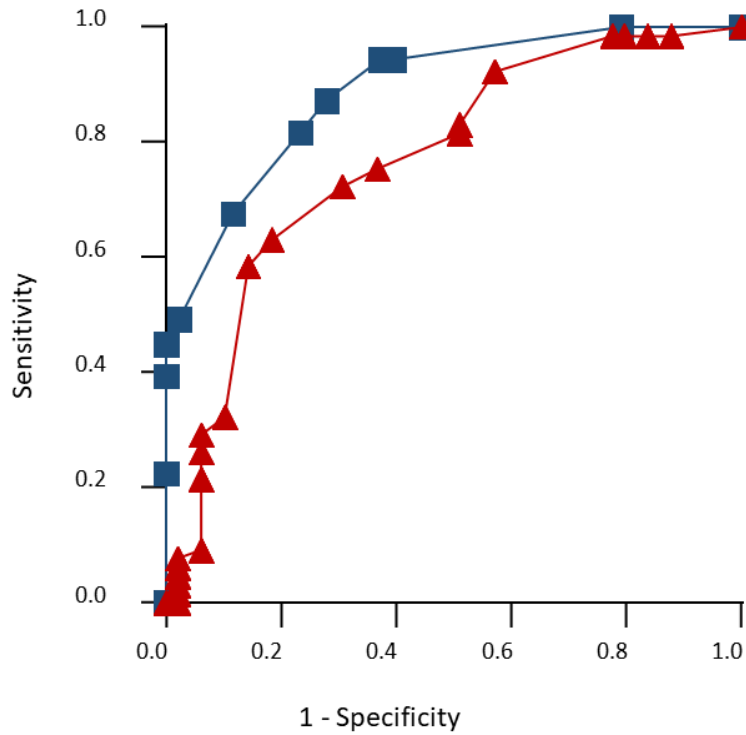
APHE = arterial-phase hyper-enhancement, CEUS = contrast-enhanced ultrasound, CT = computed tomography, LI-RADS = Liver Imaging Reporting and Data System, MRI = magnetic resonance imaging, WO = washout

Online Resource 6 Results of stepwise logistical regression analysis

CATEGORIES	P-value	ROC
All CT/MRI observations		
<i>Benign vs All Malignant</i>		
o CEUS APHE	0.005**	0.8914
o CT/MRI LI-RADS	<0.001***	0.8914
<i>HCC vs Everything Else</i>		
o CEUS APHE	0.0025**	0.7699
o CEUS LI-RADS	0.0031**	0.7699
o CT/MRI LI-RADS	0.0025**	0.7699
CT/MRI LR-3		
<i>Benign vs All Malignant</i>		
o CEUS APHE	0.0082**	0.7845
<i>HCC vs Everything Else</i>		
o CEUS APHE	0.0057**	0.8095
CT/MRI LR-4		
<i>Benign vs All Malignant</i>		
o CEUS APHE	0.2875 (ns)	0.5989
<i>HCC vs Everything Else</i>		
o Age	0.0288*	0.6739
CT/MRI LR-M		
<i>Benign vs All Malignant</i>		
o CT/MRI APHE	0.7598 (ns)	0.5857
<i>HCC vs Everything Else</i>		
o CEUS LI-RADS	0.0149*	0.7167
CT/MRI LR-3 + LR-4		
<i>Benign vs All Malignant</i>		
o CEUS APHE	0.0144*	0.8016
o CT/MRI LI-RADS	0.0004***	0.8016
<i>HCC vs Everything Else</i>		
o Age	0.0367*	0.7899
o CEUS APHE	0.0113*	0.7899
o CT/MRI LI-RADS	0.0025**	0.7899

Note. —ns (nonsignificant) $P > 0.05$, * $P \leq 0.05$, ** $P \leq 0.01$, *** $P \leq 0.001$

APHE = arterial-phase hyper-enhancement, BMI = body mass index, CEUS = contrast-enhanced ultrasound, CT = computed tomography, CI = confidence interval, HCC = hepatocellular carcinoma, LI-RADS = Liver Imaging Reporting and Data System, MRI = magnetic resonance imaging, ROC = Receiver operating characteristic

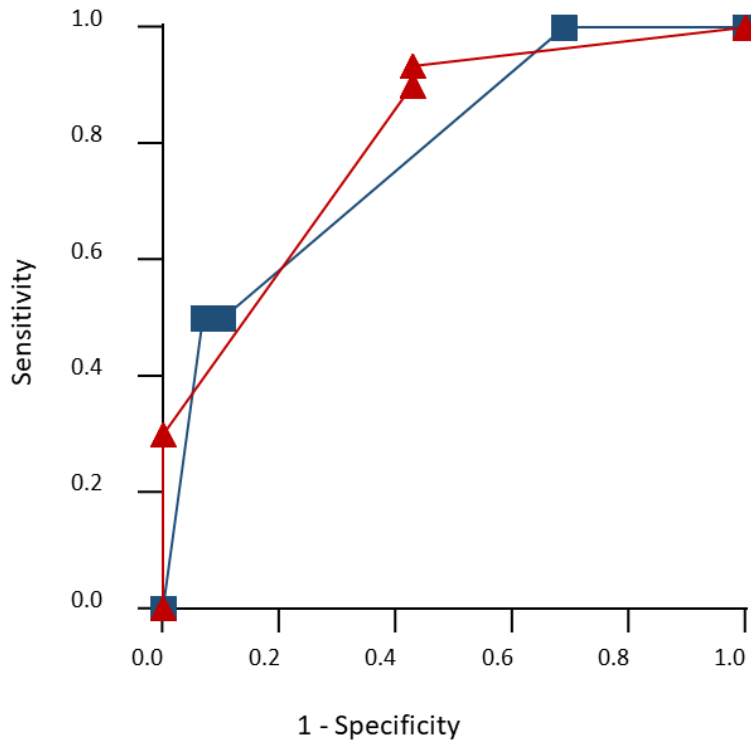


Area under ROC curve All Observations

- 0.8914 - Benign vs All Malignancy
- ▲ 0.7699 - HCC vs Everything Else (Benign + Non-HCC Malignancy)

Online Resource 7 Area under ROC curve for all observations

HCC = Hepatocellular carcinoma, ROC = Receiver operating characteristic



Area under ROC curve LR-3

- 0.7845 - Benign vs All Malignancy
- ▲ 0.8095 - HCC vs Everything Else (Benign + Non-HCC Malignancy)

Online Resource 8 Area under ROC curve for LR-3 observations

HCC = Hepatocellular carcinoma, ROC = Receiver operating characteristic