



Outcomes and complications of conversion THA after internal fixation of proximal femur fractures: a systematic review

Alberto Di Martino^{1,2} · Claudio D'Agostino^{1,2} · Riccardo Poluzzi^{1,2} · Matteo Brunello^{1,2} · Giuseppe Geraci² · Francesco Traina^{1,3} · Cesare Faldini^{1,2}

Received: 21 September 2024 / Accepted: 31 August 2025
© The Author(s) 2025

Abstract

Purpose The goal of this systematic review is to analyse clinical results and complications of conversion total hip arthroplasty (cTHA) after failure of internal fixation (IFix), distinguishing according to the initial fixation method: intramedullary nail, plate/screw systems, and cannulated screws.

Methods PubMed, EMBASE, and Cochrane database were firstly accessed in April 2025, and lastly checked on July 2025, to identify studies addressing patients who underwent to cTHA after sustaining proximal femoral fractures with subsequent IFix. The PRISMA guidelines were followed, and the quality of studies was assessed. Data were extracted from the identified articles and summarised.

Results Twelve retrospective studies on 1,260 patients analyzed complications of conversion to total hip arthroplasty (cTHA) after internal fixation of the femur. After fixation with an intramedullary nail, cTHA showed a 6.01% dislocation rate, 3.14% periprosthetic fractures, 2.59% aseptic loosening, and 3.41% periprosthetic infections, with a 3.82% reoperation rate. Fixation with a plate/screw system resulted in fewer complications but a higher incidence of periprosthetic fractures (11.57%). A notably higher dislocation rate of 10.04% was observed following fixation with cannulated screws.

Conclusion This review confirms that cTHA after IFix of proximal femoral fractures is associated to an elevated rate of perioperative complications, with a higher incidence when cTHA is performed after intramedullary nail fixation; a higher incidence of intraoperative periprosthetic fractures is observed on those patients treated by plate/screws system at first surgery. Unexpectedly, a higher rate of implant dislocations is recorded in those patients undergoing cTHAs after IFix by cannulated screws.

Keywords Conversion THA · Revision · Internal fixation · CTHA · Total hip arthroplasty · Complication

Introduction

Proximal femoral fractures are a common and severe injury affecting both the elderly and the adult population, with 1.6 million cases occurring annually worldwide; this

incidence is predicted to increase, with an occurrence of 6.3 million in 2050 [1].

In most cases, treatment is aimed at fracture reduction and bone stock preservation, preferring Internal Fixation (IFix) to total hip arthroplasty (THA) [2]. Currently, a variety of devices are available for the treatment of proximal femur fractures. It is widely agreed that Pauwels Type I intracapsular fractures should be addressed using multiple cannulated screws. However, sliding hip screws and side plate design devices (such as the Femoral Neck System, FNS), as well as hemiarthroplasty, are effective treatment options, particularly for Pauwels Type II and III fracture patterns [3]. On the other hand, extracapsular fractures are best treated with an intramedullary device (short or long cephalo-medullary nail, CMN) or other sliding screw and side plate design devices (e.g., dynamic hip screw, DHS; proximal femur

✉ Alberto Di Martino
albertocorrado.dimartino@ior.it

¹ Department of Biomedical and Neuromotor Sciences (DIBINEM), University of Bologna, Bologna, Italy

² 1st Orthopedic and Traumatology Department, IRCCS Rizzoli Orthopedic Institute, Bologna, Italy

³ Department of Orthopedics and Traumatology and Hip and Knee Arthroplasty and Revisions, IRCCS Rizzoli Orthopedic Institute, Bologna, Italy

locking compression plates, PF-LCP; dynamic compression plate, DCP; etc.) [3, 4].

Numerous studies compared intramedullary with extramedullary devices; however, inconsistent results were reported; so far, no study demonstrated a clinical superiority of any of these devices in terms of fracture healing [5–8].

IFix procedures at the proximal femur are not exempt from complications, ranging from avascular necrosis (AVN) of the femoral head, malunion or nonunion, and mechanical fixation failure which may ultimately lead to the development of secondary osteoarthritis [3, 4].

Despite the availability of multiple treatment choices for femoral neck fractures, the options for subsequent revision procedures are limited, particularly when dealing with complex proximal femoral anatomical deformities resulting from a failed fracture fixation, bone deficiencies, and in patients with inadequate muscle balance [9]. In those cases, an effective salvage treatment entails the extraction of the implanted device followed by implant of a THA: this surgery is commonly referred to as conversion THA (cTHA) [10–14].

This surgery requires an extended surgical exposure, the management of a weak and osteoporotic bone, and removal of retained hardware before cTHA performance; not last, surgeons and anesthesiologists are required to manage the fragile nature typical of the elderly population [15, 16]. These elements collectively exacerbate the risks associated with cTHA surgery following a previous IFix. Consequently, cTHA has been reasonably compared to revision THAs in terms of blood loss, dislocation rate, duration of hospitalization, and overall costs for the National Health System [17].

While our systematic review is not the first on this topic, the purpose is to update and refine previous findings considering emerging data reporting on cTHA after IFix failure for proximal femoral fractures, focusing on clinical results and complications; results will be reported separately according to the initial method of fixation: intramedullary nail, plate/screw systems and cannulated screws (Fig. 1).

Materials and methods

Eligibility criteria

The PICOS model (Population, Intervention, Comparison, Outcomes, Study design) was used for the present study. The authors included studies that considered patients who underwent IFix for proximal femoral fracture (Population), undergoing a cTHA (Intervention), with or without a comparison group of primary THA controls (Comparison), that reported differences on blood loss, procedure time, average follow-up and Harris Hip Score (HHS) at twelve months, and complications such as hip dislocations, intra- and post-operative fractures, aseptic loosening and periprosthetic joint infection that required or not a revision surgery (Outcomes); Randomized Controlled Trials (RCTs), retrospective or prospective observational studies (Study design) that met the abovementioned PICOS were included; reviews, case reports and poor case series were excluded.

No limits regarding the year of publication were applied. Only articles in English language were considered.

Search strategy

A systematic review of the available English literature on three large databases (Scopus, Embase and PubMed) was performed in April 2025 and lastly checked on July 2025.

Medical subject headings (MeSH) terms used were “femur fracture,” “nail,” “screw,” “DHS,” “FNS,” “plate” and “conversion,” “THA” and “cTHA”. The following string was used: (femur fracture) AND (nail OR screw OR DHS OR FNS OR PLATE) AND (conversion OR THA OR CTHA).

Additional articles were found through a cross-reference search of eligible studies. Two authors (CD and RP) independently screened all potentially relevant titles and abstracts, and any disagreement was solved by the senior authors (ADM and CF). The Preferred Reporting Items for

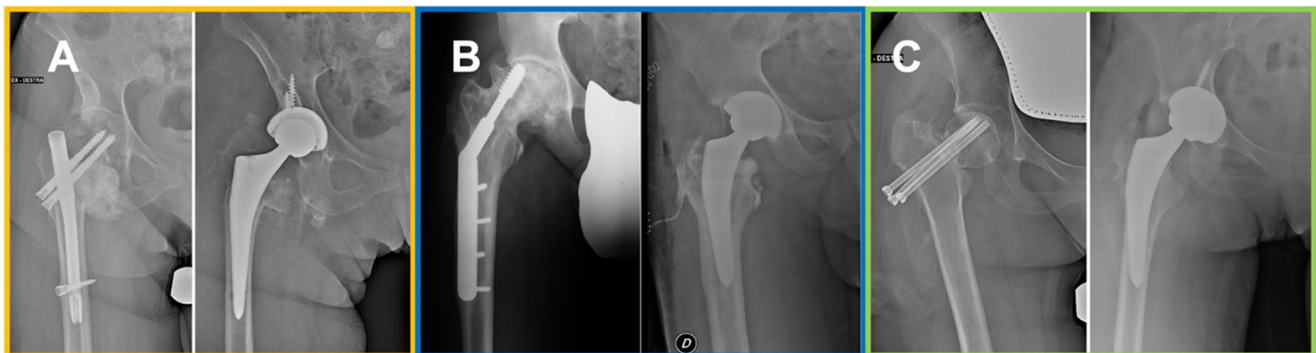

Fig. 1 cTHAs performed after intramedullary nail (A-orange), plate/screw system (B-blue) and cannulated screws (C-green) removal

Systematic reviews and Meta-Analyses recommendations were followed during this review [18](Fig. 2).

Two authors (GG and FT) independently evaluated the methodological quality of the included studies using the NIH tool [18]. If any disagreement arose, it was resolved by a discussion with a third senior author (ADM). Reference data, populations and outcomes were extracted from the articles into pre-specified tables using a standardized data extraction procedure by two of the authors (RP and MB). They extracted information on studies' general characteristics (including design and primary outcomes), number of patients (population), interventions (cTHA after nail, screws and/or plate and screws), comparator (none), and the summary of main outcomes.

Statistical analysis

Descriptive statistics were used to summarize the data, presented as median and mean with standard deviation (SD) for continuous variables and as frequency with percentage (%) for categorical variables. Descriptive statistics were reported when data to pool were evaluated insufficient, or when substantial clinical heterogeneity was observed in

terms of population characteristics, intervention types, or outcome assessment methods.

Results

Twelve studies reporting on a total of 1,260 patients were included; these were all retrospective case series in which instrumentation removal and cTHA were performed during the same surgery; the populations presented in the selected studies were mostly concordant in age, ASA score, and BMI; 64.8% (817 cases) were females and 443 were males. The average age at cTHA was 70.58 years ($\pm 5,31$ years), while the average follow-up time was 48.57 months (± 4.3 months). The overall quality of the included studies was judged as "good" (Supplementary Table 1).

Conversion-THAs after intramedullary nailing

We pooled data from 7 studies [1, 9, 19–23], resulting in a cohort of 733 cTHAs. The average BMI was 26.3 Kg/m² (± 3.5 Kg/m²), the median ASA score was 2 (range 1–3), the average intraoperative blood loss was 858.6 mL, and

Fig. 2 Search strategy according to the preferred reporting items for systematic reviews and meta-analyses (PRISMA) statement

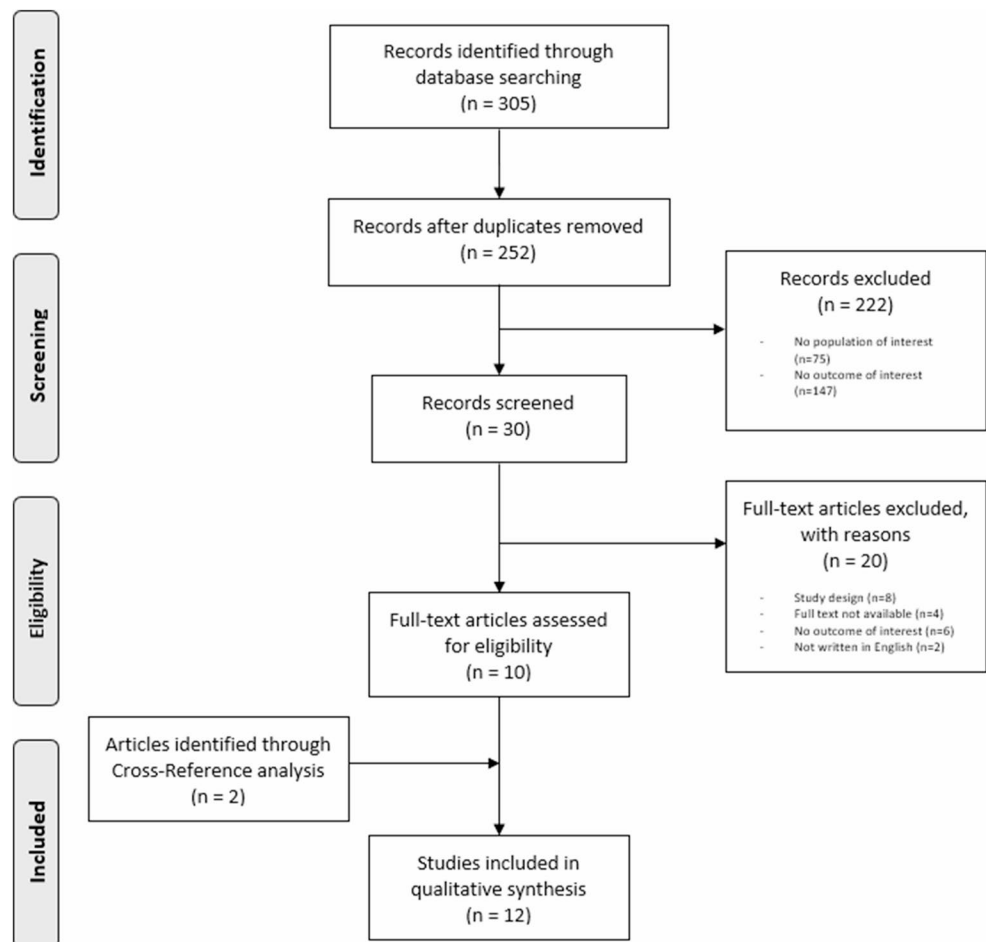


Table 1 Groups characteristics at cTHA surgery

Groups characteristics at cTHA surgery	Intramedullary nail	Plate and screws	Canulated screws
Pt. n°	733	268	259
BMI (kg/m ²)	26.4 (range 23.2–29.5) ^{19–21}	25.5 (range 23.2–28.9) ^{19,21,24,26}	26 (range 26–26.1) ^{26,28}
ASA Score	2 (range 1–3) ^{19,21,23}	2 (range 2–3) ^{19,21,23,24,26}	2 (range 1–2) ^{23,26,27}
Mean Blood Loss (ml)	858.6 ¹⁹	911.65±395 ^{19,23–25}	516.7 ²⁵
Mean Procedure Time (min)	116 ^{19,23}	122 ^{19,23–26}	97 ^{23,26}

Table 2 Groups characteristics at cTHA surgery

Clinical Outcome of cTHA after	Authors	Average follow-up (months)	HHS at 12months
Intramedullary Nail	Selim et al. 2025	48	87
	Jin et al. 2021	N/A	85.4
	Godoy et al. 2021	63.6	86
	Yu et al. 2020	65.15	85.62
	Smith et al. 2019	N/A	N/A
	Zeng et al. 2017	47.92	82.54
	Pui et al. 2013	35	78.6
	Tot.	51.93±12.54	84.19 (78.6–87)
Plate and Screws	Selim et al. 2025	48	86
	Jin et al. 2021	N/A	85.4
	Morice et al. 2018	42	78.7
	Zeng et al. 2017	48.1	81.9
	Pui et al. 2013	37	83.6
	Winemaker 2006	N/A	73.9
	Zhang et al. 2004	N/A	79.9
	Tot.	43.78±5.34	81.34 (73.9–86)
Canulated Screws	Selim et al. 2025	48	87
	Hernandez et al. 2017	24	85
	McKinley et al. 2010	78	N/A
	Winemaker et al. 2006	N/A	82.6
	Tot.	50±27.06	84.87 (82.6–87)

the average surgical time was 116 min (Table 1). The average Harris Hip Score (HHS) at 12 months was 84.19±3.12 (Table 2). Regarding surgical complications, implant dislocations occurred in 44/733 cTHAs (6.01%), 23 patients had an intra- or post-operative periprosthetic fracture (3.14%), 19 presented aseptic loosening (2.59%) and 25 developed a periprosthetic joint infection (3.51%). A reoperation was necessary in 28 cTHAs (3.82%) (Table 3).

Conversion-THAs after plate and screws

With data extrapolated from seven studies [19, 21–26] a cohort of 268 cTHAs were performed after removal of plate/screw system; in this group were included the different systems based on sliding hip screw and side plate design (i.e., DHS, FNS, etc.). The mean BMI was 25.5 Kg/m² (±2.5 Kg/m²), the median ASA score was 2 (range 2–3), the average blood loss was 911.65mL (±395.88mL) and the average surgical time was 122 min (Table 1). Average HHS at 12 months was 81.34±4.24 (Table 2). As regards surgical complications, implant dislocation occurred in 7 patients (2.61%), intra-operative periprosthetic fracture occurred in 12 cTHAs (4.48%), 19 patients (7.09%) experienced a post-operative periprosthetic fracture, 2 patients (0.75%) developed aseptic loosening and 3 patients (1.12%) developed a periprosthetic joint infection. Revision surgery was required in 5 cases (1.87%) (Table 4).

Conversion-THAs after cannulated screws

We pooled data from three studies [23, 26–28] with a cohort of 259 cTHA implants. The average BMI was 26.0±0.1 Kg/m², median ASA score was 2 (1–2), the average intra-operative blood loss was 516.7mL, and the average procedure time was 97 min (Table 1). Average HHS at 12 months was 84.87±2.20 (Table 2). Hip dislocation occurred in 26 patients (10.04%), intra-operative periprosthetic fracture occurred during 9 procedures (3.47%), and 2 patients (0.77%) had post-operative periprosthetic fracture. Nine patients (3.47%) had aseptic loosening and 10 (3.86%) developed a periprosthetic joint infection. A revision surgery was necessary in 18 cases (6.95%) (Table 5).

As a secondary outcome, complications were pooled based on the surgical approach used during cTHA. In most of the included studies, the approach was either unspecified, or not related to the single patient; therefore, maintaining the division into three groups according to the instrumentation used, data on post-operative complications from six studies [1, 19, 21, 23, 24, 27] on cTHAs performed by posterolateral (PL) approach were considered. From these 6 studies, 135 cTHAs after intramedullary nailing were performed with the PL approach [1, 19, 21, 23]; implant dislocation occurred in 6 cases (4.4%), intra- or post-operative periprosthetic fracture in 3 (2.2%), and 2 (1.5%) patients developed a periprosthetic joint infection. Reoperation was necessary in 3 of these 135 patients (2.2%).

From a cohort of 146 cTHAs performed after plate and screws removal by PL approach [19, 21, 23, 27], hip dislocation occurred in 6 patients (6.1%), periprosthetic fracture occurred intraoperatively during 20 cTHAs (13.7%),

Table 3 Clinical outcomes

Complications of cTHA after Intramedullary Nail						
Authors	Hip dislocations	Periprosthetic fracture [Intra-Op]	Aseptic loosening	Periprosthetic joint infection	Revision	Tot. (%)
Selim et al. 2025	2	1 (3)	0	0	1	7
Jin et al. 2021	1	0	0	0	1	2
Godoy et al. 2021	2	0	0	0	0	2
Yu et al. 2020	6	13	18	0	14	51
Smith et al. 2019	30	N/A	N/A	22	12	64
Zeng et al. 2017	1	3	0	2	0	6
Pui et al. 2013	2	3	1	1	N/A	7
Pt. 733 (100%)	44(6.01%)	23 (3.14%) [3 (0.41%)]	19(2.59%)	25(3.41%)	28(3.82%)	139 (18.96%)

Table 4 Complications of cTHA after plate and screws

Complications of cTHA after Plate and Screws						
Authors	Hip dislocations	Periprosthetic fracture [Intra-Op]	Aseptic loosening	Periprosthetic joint infection	Revision	Tot. (%)
Selim et al. 2025	0	0 [2]	0	0	0	2
Jin et al. 2021	0	0	0	0	0	0
Morice et al. 2018	1	3	0	0	3	7
Zeng et al. 2017	3	11	1	2	N/A	17
Pui et al. 2013	0	4	0	1	0	5
Winemaker et al. 2006	N/A	1 [3]	1	N/A	2	7
Zhang et al. 2004	3	0 [7]	0	0	0	10
Pt. 268 (100%)	7 (2.61%)	31 (11.57%) [12 (4.48%)]	2 (0.75%)	3 (1.12%)	5 (1.87%)	48 (17.91%)

Table 5 Complications of cTHA after cannulated screws

Complications of cTHA after Cannulated Screws						
Authors	Hip dislocations	Periprosthetic fracture [Intra-Op]	Aseptic loosening	Periprosthetic joint infection	Revision	Tot. (%)
Selim et al. 2025	3	0	0	0	1	4
Hernandez et al. 2017	2	0 [2]	1	1	4	10
McKinley et al. 2010	21	2 [3]	8	8	12	54
Winemaker et al. 2006	0	0 [4]	0	1	1	6
Pt. 259 (100%)	26 (10.04%)	11 (4.25%) [9 (3.47%)]	9 (3.47%)	10(3.86%)	18(6.95%)	74 (28.57%)

Table 6 Surgical complications of cTHA in PL approach

Surgical complications of cTHA in Posterolateral approach						
	Pt. n°	Hip dislocation	Periprosthetic fracture	Aseptic loosening	Periprosthetic joint infection	Revision
Intramedullary Nail	135	6 (4.4%)	3 (2.2%)	0 (0%)	2 (1.5%)	3 (2.2%)
Plate and Screws	146	6 (4.1%)	20 (13.7%)	1 (0.7%)	2 (1.4%)	0 (0%)
Cannulated Screws	183	5 (2.7%)	7 (3.8%)	8 (3.4%)	8 (3.4%)	13 (7.1%)

1 patient developed aseptic loosening and 2 (1.14%) had a periprosthetic joint infection. Only two studies [23, 24] evaluated cTHAs after cannulated screws removal by PL approach. In a population of 183 cTHAs, hip dislocation occurred in 5 patients (2.7%), 7 (3.8%) periprosthetic fractures occurred, 8 patients (3.4%) presented aseptic loosening and 8 (3.4%) developed a periprosthetic joint infection. Revision surgery was required in 13 cases (7.1%) (Table 6).

Discussion

This review focuses on a very topical issue. With the increase in the average age of the general population, the number of fractures at the proximal femur is steadily increasing as well as life expectancy after IFix for these fractures. This elderly population usually presents a condition of frailty, characterized by a state of loss of physical reserve and decreased ability to withstand physiological

and homeostatic stressors [29], with clinical and functional decline. Frailty places older patients at increased likelihood of biological and mechanical complications of IFix surgery, requiring revision surgery. The effectiveness of cTHA as a salvage procedure for the failure of IFix of proximal femur fractures has already been reported [2, 30]. However, this is a challenging procedure associated with longer surgical times, increased intraoperative bleeding, and higher complication rates compared to primary THAs [2, 30, 31].

Aim of this study was to systematically review current literature and compare clinical outcomes, complication rates, and procedural difficulties among patients initially treated with different open reduction and IFix strategies.

Our study was not exempt of limitations. Firstly, the recovery of data from the selected studies which were all retrospective and reporting on small populations. Another limitation was the need to compare data that lacked uniformity, as there were instances where it was not feasible to differentiate between data associated with different patterns of fracture, cemented and uncemented THA implants, different approaches, or the primary fixation systems.

Regarding clinical and functional outcomes assessed through the HHS, these were consistent across the reviewed studies and were not influenced by the previous fixation devices [19, 21–23, 26]. Conversely, the length of surgery and intraoperative bleeding averaged higher values in cTHA when compared to primary THA, Winemaker et al. [26] describe an average operating time of 76.7 min and an average bleeding of 406.5 mL in primary THA. Similarly, Brunello et al. [32] described an average surgery time of 78.8 min in primary THA performed by direct anterior access and a mean 74 min for the posterolateral approach. Instead, our study reported an average operating time of 100.53 min and an average blood loss of 762.3 mL. These differences were primarily attributed to the removal of instrumentation during cTHA.

As highlighted in the study by Selim et al. [23], conversion procedures following CMN were associated with the longest operative times, with the authors reporting a substantial 45-minute increase in duration compared to cases converted after cannulated screw fixation. Moreover, our study showed an even greater prolongation of operative time in cases requiring the removal of plate and screw constructs, further emphasizing the technical complexity and surgical challenges associated with hardware extraction during cTHA.

The analysis of cTHA after CMN failure reveals complications such as postoperative dislocation and periprosthetic infection, with a notable incidence of dislocation reaching 8.1% within two years in the report by Smith et al. [1]. The use of intramedullary devices like CMN is associated to higher soft tissue damage, in particular at the gluteus medius muscle tendon, possibly leading to an increased

risk of dislocation [33]. Achieving proper femoral anteversion is emphasized to minimize complications' rate and to enhance patient's satisfaction after CMN failure [9, 34, 35].

Less frequent complications in these patients include aseptic mobilization and periprosthetic fractures. Yu et al. [20] noticed a higher rate of aseptic loosening in patients treated with uncemented rather than cemented THA. The choice between cemented and uncemented implants for this procedure remains unclear due to the lack of comparative studies [36–39]. However, uncemented revision stem fixation could be beneficial for patients if performed by experienced surgeons, particularly in younger and non-osteoporotic patients [36–39], while cemented cTHA should be reserved for older individuals with compromised bone stock [23].

The relatively higher incidence of infections observed in the conversion group can be attributed to several factors, including the presence of hardware, the requirement for extensive surgical exposure and prolonged surgical time, but definitely it reflects the increased comorbidities usually associated to this patients' population; however, in suspected patients it is appropriate to investigate and exclude infections as the underlying cause of fixation failure of CMN devices before cTHA performance [1, 40].

In the plate/screw group, periprosthetic fractures and postoperative dislocations were the most significant complications. The association between periprosthetic fractures and previous IFix by DHS has already been reported by several studies [21, 25]. The biomechanical impact of stress shielding by the side plate of DHS implants leads to lower mechanical strength at the lateral cortex [41]. These events are less frequently encountered when intramedullary nail implants are used.

Unexpectedly, in patients undergoing cTHA after cannulated screw fixation, the most frequent complication was hip dislocation (12.57%) followed by periprosthetic joint infection (PJI, 5.46%). McKinley et al. [27] reported a high dislocation rate of 19.6% and a PJI rate of 7.5%, attributing these outcomes to the particular frailty of the treated patients and the limited expertise of the surgical team. These outcomes are in contrast with other data collected in the current review [15, 26]. Conversely, Hernandez et al. [28], reported a low dislocation incidence (3%), attributing it to the use of large diameter heads. Hernandez and colleagues studied cTHA after cannulated screw IFix for femoral neck fractures, reporting a low periprosthetic fracture rate, crediting careful surgical strategies, especially leaving screws in place until hip dislocation.

We could not address the question if some complications could be more frequent when a peculiar surgical approach is performed, because only data from studies on PL approach were available, being it the most used approach when CMN or plate implants are on site at cTHA; on the other side, PL approach has an intrinsic risk of THA implant dislocation,

particularly in patients with conditions of frailty and osteosarcopenia [2, 28]. It could be interesting to evaluate the role of other approaches including the direct anterior approach and direct lateral approach for cTHA in terms of dislocation rate, seen the lack of comparative studies presenting specific data for cTHAs [42].

Conclusion

This review confirms that cTHA after IFix of proximal femur fractures is associated to an elevated rate of complications. Our subgroup analysis identified a higher number of complications in cTHAs performed after intramedullary nail fixation, except for a higher incidence of intraoperative periprosthetic fractures in the plate/screw group and a higher rate of hip dislocations in patients undergoing cTHA after cannulated screws.

Patients should be informed that salvage cTHA after failure of IFix is a procedure at risk of early complications, higher compared to primary THAs; moreover, despite an improvement of HHS after surgery, hip function may be poorer compared to primary replacements.

These findings are of critical importance because of the increased rate of cTHA expected in the next future; these data may recalibrate patients' expectations and improve doctor-patient relationship, eventually decreasing the rate of litigations after cTHA surgery.

Supplementary Information The online version contains supplementary material available at <https://doi.org/10.1007/s00068-025-02977-6>.

Author contributions AD contributed to the conceptualization and project administration. Literature review, data collection and analysis were performed by CD and RP. MB assessed the quality and contributed to data extraction. GG contributed to the methodology. FT and CF contributed to the supervision and the validation. The first draft of the manuscript was written by CD and RP. All the authors contributed to the review and editing of the manuscript. All authors proofread and approved the final manuscript.

Funding Open access funding provided by Alma Mater Studiorum - Università di Bologna within the CRUI-CARE Agreement. The authors declare that no funds, grants or other support were received during the preparation of this manuscript. The authors have no financial or non-financial interests to disclose.

Data availability No datasets were generated or analysed during the current study.

Declarations

Ethical approval Not applicable.

Competing interests The authors declare no competing interests.

Open Access This article is licensed under a Creative Commons Attribution 4.0 International License, which permits use, sharing, adaptation, distribution and reproduction in any medium or format, as long as you give appropriate credit to the original author(s) and the source, provide a link to the Creative Commons licence, and indicate if changes were made. The images or other third party material in this article are included in the article's Creative Commons licence, unless indicated otherwise in a credit line to the material. If material is not included in the article's Creative Commons licence and your intended use is not permitted by statutory regulation or exceeds the permitted use, you will need to obtain permission directly from the copyright holder. To view a copy of this licence, visit <http://creativecommons.org/licenses/by/4.0/>.

References

- Smith A, Denehy K, Ong KL, et al. Total hip arthroplasty following failed intertrochanteric hip fracture fixation treated with a cephalomedullary nail. *Bone Jt J*. 2019;101-B:91–6. <https://doi.org/10.1302/0301-620X.101B6.BJJ-2018-1375.R1>.
- Mortazavi SMJ, Greenky R, Bican M O, et al. Total hip arthroplasty after prior surgical treatment of hip fracture is it always challenging? *J Arthroplasty*. 2012;27:31–6. <https://doi.org/10.1016/j.arth.2011.05.014>.
- AO Principles of Fracture management Third Edition. -Richard E Buckley Christopher G Moran Theerachai Apivatthakakul.
- Giannini S, Faldini C. *Manuale Di ortopedia e traumatologia*. Minerva Medica; 2008.
- Baumgaertner MR, Curtin SL, Lindskog DM. Intramedullary versus extramedullary fixation for the treatment of intertrochanteric hip fractures. *Clin Orthop*. 1998;348:87–94.
- Parker MJ, Handoll HH. Gamma and other cephalocondylic intramedullary nails versus extramedullary implants for extracapsular hip fractures in adults. *Cochrane Database Syst Rev* CD000093. 2010. <https://doi.org/10.1002/14651858.CD000093.pub5>.
- Utrilla AL, Reig JS, Muñoz FM, Tufanisco CB. Trochanteric gamma nail and compression hip screw for trochanteric fractures: a randomized, prospective, comparative study in 210 elderly patients with a new design of the gamma nail. *J Orthop Trauma*. 2005;19:229–33. <https://doi.org/10.1097/01.bot.0000151819.95075.ad>.
- Barton TM, Gleeson R, Topliss C, et al. A comparison of the long gamma nail with the sliding hip screw for the treatment of AO/OTA 31-A2 fractures of the proximal part of the femur: a prospective randomized trial. *J Bone Joint Surg Am*. 2010;92:792–8. <https://doi.org/10.2106/JBJS.I.00508>.
- Godoy-Monzon D, Diaz Dileria F, Piccaluga F, et al. Conversion total hip arthroplasty with a proximally modular, distal fixation reconstruction prosthesis following cephalomedullary nail failure. *HIP International*. 2020;30:26–33. <https://doi.org/10.1177/1120700020937952>.
- Afghanyar Y, Coutandin M, Schneider M, et al. Conversion of failed internal fixation in proximal femur fractures using calcar-guided short-stem total hip arthroplasty. *J Orthop Traumatol*. 2022;23:34. <https://doi.org/10.1186/s10195-022-00655-6>.
- Albright JP, Weinstein SL. Treatment for fixation complications: femoral neck fractures. *Arch Surg Chic Ill* 1960. 1975;110:30–6. <https://doi.org/10.1001/archsurg.1975.01360070030006>.
- Stoffelen D, Haentjens P, Reynders P, et al. Hip arthroplasty for failed internal fixation of intertrochanteric and subtrochanteric fractures in the elderly patient. *Acta Orthop Belg*. 1994;60(Suppl 1):135–9.
- Tabsh I, Waddell JP, Morton J. Total hip arthroplasty for complications of proximal femoral fractures. *J Orthop Trauma*.

- 1997;11:166–9. <https://doi.org/10.1097/00005131-199704000-00005>.
14. Haidukewych GJ, Berry DJ. Hip arthroplasty for salvage of failed treatment of intertrochanteric hip fractures. *J Bone Joint Surg Am.* 2003;85:899–904. <https://doi.org/10.2106/00004623-200305000-00019>.
 15. Nilsson LT, Strömqvist B, Thorngren KG. Secondary arthroplasty for complications of femoral neck fracture. *J Bone Joint Surg Br.* 1989;71:777–81. <https://doi.org/10.1302/0301-620X.71B5.2584246>.
 16. Franzén H, Nilsson LT, Strömqvist B, et al. Secondary total hip replacement after fractures of the femoral neck. *J Bone Joint Surg Br.* 1990;72:784–7. <https://doi.org/10.1302/0301-620X.72B5.2211756>.
 17. Moon NH, Shin WC, Kim JS, et al. Cementless total hip arthroplasty following failed internal fixation for femoral neck and intertrochanteric fractures: a comparative study with 3–13 years' follow-up of 96 consecutive patients. *Injury.* 2019;50:713–9. <https://doi.org/10.1016/j.injury.2019.01.018>.
 18. Booth A, Clarke M, Gheri D, et al. An international registry of systematic-review protocols. *Lancet.* 2011;377:108–9. [https://doi.org/10.1016/S0140-6736\(10\)60903-8](https://doi.org/10.1016/S0140-6736(10)60903-8).
 19. Jin S-Y, Jin J-Y, Kim M-G, et al. Cementless total hip arthroplasty for failed treatment of subtrochanteric fracture. *BMC Musculoskelet Disord.* 2021;22:384. <https://doi.org/10.1186/s12891-021-04268-8>.
 20. Yu W, Han X, Chen W, et al. Conversion from a failed proximal femoral nail anti-rotation to a cemented or uncemented total hip arthroplasty device: a retrospective review of 198 hips with previous intertrochanteric femur fractures. *BMC Musculoskelet Disord.* 2020;21:791. <https://doi.org/10.1186/s12891-020-03806-0>.
 21. Zeng X, Zhan K, Zhang L, et al. Conversion to total hip arthroplasty after failed proximal femoral nail antirrotations or dynamic hip screw fixations for stable intertrochanteric femur fractures: a retrospective study with a minimum follow-up of 3 years. *BMC Musculoskelet Disord.* 2017;18:38. <https://doi.org/10.1186/s12891-017-1415-6>.
 22. Pui CM, Bostrom MP, Westrich GH, et al. Increased complication rate following conversion total hip arthroplasty after cephalomedullary fixation for intertrochanteric hip fractures: a multi-center study. *J Arthroplasty.* 2013;28:45–7. <https://doi.org/10.1016/j.arth.2013.04.048>.
 23. Selim A, Dass D, Govilkar S, et al. Outcomes of conversion total hip arthroplasty following previous hip fracture surgery. *Bone Jt Open.* 2025;6:195–205. <https://doi.org/10.1302/2633-1462.62.BJ O-2024-0188.R1>.
 24. Morice A, Ducellier F, Bizot P, Orthopaedics and Traumatology Society of Western France (SOO). Total hip arthroplasty after failed fixation of a proximal femur fracture: analysis of 59 cases of intra- and extra-capsular fractures. *Orthopaedics & Traumatology: Surgery & Research.* 2018;104:681–6. <https://doi.org/10.1016/j.otsr.2018.04.015>.
 25. Zhang B, Chiu K-Y, Wang M. Hip arthroplasty for failed internal fixation of intertrochanteric fractures. *J Arthroplasty.* 2004;19:329–33. <https://doi.org/10.1016/j.arth.2003.10.010>.
 26. Winemaker M, Gamble P, Petruccioli D, et al. Short-term outcomes of total hip arthroplasty after complications of open reduction internal fixation for hip fracture. *J Arthroplasty.* 2006;21:682–8. <https://doi.org/10.1016/j.arth.2005.08.013>.
 27. McKinley JC, Robinson CM. Treatment of displaced intracapsular hip fractures with total hip arthroplasty: comparison of primary arthroplasty with early salvage arthroplasty after failed internal fixation. *J Bone Joint Surg Am.* 2002;84:2010–5. <https://doi.org/10.2106/00004623-200211000-00016>.
 28. Hernandez NM, Chalmers BP, Perry KI, et al. Total hip arthroplasty after in situ fixation of minimally displaced femoral neck fractures in elderly patients. *J Arthroplasty.* 2018;33:144–8. <https://doi.org/10.1016/j.arth.2017.07.035>.
 29. Clegg A, Young J, Iliffe S, et al. Frailty in elderly people. *Lancet.* 2013;381:752–62. [https://doi.org/10.1016/S0140-6736\(12\)62167-9](https://doi.org/10.1016/S0140-6736(12)62167-9).
 30. Archibeck MJ, Carothers JT, Tripuraneni KR, White RE. Total hip arthroplasty after failed internal fixation of proximal femoral fractures. *J Arthroplasty.* 2013;28:168–71. <https://doi.org/10.1016/j.arth.2012.04.003>.
 31. Mahmoud SSS, Pearse EO, Smith TO, Hing CB. Outcomes of total hip arthroplasty, as a salvage procedure, following failed internal fixation of intracapsular fractures of the femoral neck: a systematic review and meta-analysis. *Bone Jt J.* 2016;98-B:452–60. <https://doi.org/10.1302/0301-620X.98B4.36922>.
 32. Brunello M, Di Martino A, Ruta F, et al. Which patient benefit most from minimally invasive direct anterior approach total hip arthroplasty in terms of perioperative blood loss? A retrospective comparative study from a cohort of patients with primary degenerative hips. *Musculoskelet Surg.* 2023;107:431–7. <https://doi.org/10.1007/s12306-023-00792-z>.
 33. McConnell T, Tornetta P, Benson E, Manuel J. Gluteus medius tendon injury during reaming for gamma nail insertion. *Clin Orthop.* 2003. <https://doi.org/10.1097/00003086-200302000-00028>.
 34. Lachiewicz PF, Soileau E, Ellis J. Modular revision for recurrent dislocation of primary or revision total hip arthroplasty. *J Arthroplasty.* 2004;19:424–9. <https://doi.org/10.1016/j.arth.2003.12.077>.
 35. Kwong LM, Miller AJ, Lubinus P. A modular distal fixation option for proximal bone loss in revision total hip arthroplasty: a 2- to 6-year follow-up study. *J Arthroplasty.* 2003;18:94–7. <https://doi.org/10.1054/arth.2003.50083>.
 36. Tyson Y, Hillman C, Majenburg N, et al. Uncemented or cemented stems in first-time revision total hip replacement? An observational study of 867 patients including assessment of femoral bone defect size. *Acta Orthop.* 2021;92:143–50. <https://doi.org/10.1080/17453674.2020.1846956>.
 37. Okike K, Chan PH, Prentice HA, et al. Association between uncemented vs cemented hemiarthroplasty and revision surgery among patients with hip fracture. *JAMA.* 2020;323:1077–84. <https://doi.org/10.1001/jama.2020.1067>.
 38. Davis CM, Berry DJ, Harmsen WS. Cemented revision of failed uncemented femoral components of total hip arthroplasty. *J Bone Joint Surg Am.* 2003;85:1264–9. <https://doi.org/10.2106/00004623-200307000-00012>.
 39. Huang T, Zhang S, Liu X, et al. Mid-term outcomes of cemented or uncemented total hip arthroplasty for failed proximal femoral nail antirotation following intertrochanteric femur fractures: a retrospective observational study. *Geriatr Orthop Surg Rehabil.* 2022;13:21514593221132400. <https://doi.org/10.1177/21514593221132400>.
 40. Tetsunaga T, Fujiwara K, Endo H, et al. Total hip arthroplasty after failed treatment of proximal femur fracture. *Arch Orthop Trauma Surg.* 2017;137:417–24. <https://doi.org/10.1007/s00402-017-2631-0>.
 41. Chen DW, Lin C-L, Hu C-C, et al. Biomechanical consideration of total hip arthroplasty following failed fixation of femoral intertrochanteric fractures - a finite element analysis. *Med Eng Phys.* 2013;35(5):569–75. <https://doi.org/10.1016/j.medengphy.2012.06.023>.
 42. Gondusky JS, Lee JH. The anterior approach for conversion hip arthroplasty. *Arthroplasty Today.* 2019;5:477–81. <https://doi.org/10.1016/j.artd.2019.04.011>.