



Avoiding errors and complications related to immediate implant placement in the esthetic area with a mucogingival approach

Martina Stefanini¹  | Alexandra Rendón¹ | Alessandro Zucchelli² |
Matteo Sangiorgi¹  | Giovanni Zucchelli^{1,3}

¹Department of Biomedical and Neuromotor Sciences, Periodontology Unit, Bologna University, Bologna, Italy

²Dentistry Department, Vita Salute "San Raffaele" University, Milan, Italy

³Department of Periodontics and Oral Medicine, School of Dentistry, University of Michigan, Ann Arbor, Michigan, USA

Correspondence

Matteo Sangiorgi, University of Bologna Department of Biomedical and Neuromotor Sciences, Via San Vitale n. 59, Bologna, Emilia-Romagna, IT 40125, Italy.

Email: matteo.sangiorgi@yahoo.it

1 | INTRODUCTION

Immediate implant placement is often considered the treatment of choice for tooth replacement in esthetic areas owing to advantages such as reduced treatment time, reduced number of surgical procedures, low morbidity, and the possibility of an immediate provisional prosthesis being delivered on the day of extraction—all of which contribute to increased patient satisfaction. In addition, survival rates for this therapy are comparable to those of early and delayed implant placement modalities.¹⁻⁴

Nevertheless, immediate implant placement is not able to mitigate the buccal hard and soft tissue remodeling following tooth extraction,⁵⁻⁷ and thus has also been associated with several critical drawbacks related to the inadequate assessment/management of the soft and hard peri-implant tissues and their subsequent remodeling, ultimately resulting in the occurrence of peri-implant soft tissue defects,⁸⁻¹¹ which can lead to an impaired esthetic outcome in time.

Traditionally, immediate implant placement in the esthetic area has been indicated as a flapless procedure. After a tooth is extracted, blood supply from the periodontal ligament disappears, so vascularity to the site comes solely from soft tissue and bone. If flaps are reflected, the scarcely vascularized cortical bone loses its supraperiosteal blood supply, prompting some amount of bone resorption during the initial healing phase.^{12,13} Flapless techniques are considered minimally invasive because, in a way, they preserve vascularity at the surgical site by not exposing the bone or

performing incisions on the soft tissue.¹⁴ Therefore, it has been suggested that this approach causes less trauma to the peri-implant tissues, ultimately preserving the anatomy of the postextraction site and neighboring teeth. However, this implicitly requires for the future implant site to have an "ideal" baseline anatomy that complies with basic tenets such as intact and thick (at least 1 mm) buccal bone wall and a thick gingival phenotype. In this regard, the literature shows that only 5%-10% of single-tooth extraction cases could fulfill these criteria.¹⁵

Furthermore, flapless postextraction implant placement has been linked with a series of esthetic and functional complications because of the impaired visibility that can hinder adequate assessment of implant depth and buccolingual position in relation to the anatomical position of the bone crest (leading to wrong implant position/angulation), underestimation of the quality/quantity of the buccal and interproximal soft tissues (resulting in the occurrence of mucosal recession), chance of unnoticed fenestration or dehiscence related to incorrect bur angulation, or a combination of the these,^{1,13,16,17} especially when performing freehand implant placement.

In implant therapy, whether to elevate the flap is still a subject of debate and controversy. The effect that raising a flap has on the remodeling of the cortical bone has been profoundly explored in the literature.¹⁸⁻²¹ However, in the context of implant placement, no statistically significant difference has been found regarding crestal bone loss between flapped and flapless procedures,^{14,22-24} and several researchers concluded that flap design should be chosen

Martina Stefanini and Alexandra Rendón contributed equally to this study.

[Correction added on August 10, 2023, after first online publication: The affiliation for the author Giovanni Zucchelli has been updated.]

This is an open access article under the terms of the [Creative Commons Attribution-NonCommercial-NoDerivs](https://creativecommons.org/licenses/by-nc-nd/4.0/) License, which permits use and distribution in any medium, provided the original work is properly cited, the use is non-commercial and no modifications or adaptations are made.

© 2023 The Authors. Periodontology 2000 published by John Wiley & Sons Ltd.

according to the need for access/visibility and experience level of the surgeon.²⁵

Nowadays, computer-guided implant placement allows planned and predictable implant positioning²⁶ even in flapless approaches that result in impaired visual access during surgery. Nevertheless, alterations in the bone and gingival morphology—such as altered passive eruption or gingival recession—affecting the failing tooth or the teeth adjacent to the extraction site could also lead to incorrect planning and positioning of the postextraction implant. Additionally, cases with large mucogingival deformities or buccal bone defects on the tooth being replaced require flap mobilization in order to achieve complete coverage of the soft and/or hard tissues being grafted.

With the goal of avoiding possible errors and complications at immediate implant sites, in this article we describe the advantages of raising a buccal flap in order to deal with the very diverse scenarios that can be encountered both at the failing tooth and at the adjacent dentition during post-extractive implant placement: defects of the buccal bone wall, inadequate quantity/ quality of the buccal and interproximal soft tissues, gingival recession, or even altered passive eruption. The purpose of this paper is to present a mucogingival approach²⁷ for fully guided immediate implant placement and provisionalization with buccal flap elevation in the esthetic area as an alternative to the flapless approach to overcome some of the limitations for immediate tooth replacement in cases that lack the pristine conditions once considered essential.

2 | THE MUCOGINGIVAL APPROACH TO IMMEDIATE IMPLANT PLACEMENT

Beginning with a thorough analysis of the hard and soft tissue conditions at the area being treated, with computer-guided implant planning as a prerequisite, this approach encompasses the following series of steps:

- Flap elevation.
- Intraoperative tooth extraction.
- Fully guided implant placement.
- Bone augmentation.
- Soft tissue augmentation.
- Immediate provisionalization and flap closure.
- Postsurgical care and subsequent prosthetic phases.

This is a standardized approach; however, particularities and modifications for every single step will be described in detail.

3 | THE FLAP

The basic principles for the elevation of the buccal flap for immediate implant placement derive from the techniques developed in periodontal plastic surgery for multiple gingival recession coverage; that is, the coronally advanced flap. This is a well-documented and validated technique utilized in esthetic mucogingival surgery^{28,29} and more recently also to treat soft tissue dehiscences at implant sites.^{30–34}

The proposed technique is a redesign of the multiple coronally advanced envelope flap with a frontal approach, originally reported in the literature as an access flap for single implant insertion in areas of esthetic relevance.^{27,35} The implementation of guided implant placement systems is crucial, since this allows the sole elevation of an envelope-type buccal flap, sparing disruption to the crestal, interproximal, and palatal tissues.

The design of this flap starts with the identification of its center of rotation, which in these cases will be represented by the failing tooth/future implant site. A series of oblique incisions directed towards the center of rotation should be placed interproximally, including at least one tooth mesial and distal to the implant site. Said incisions start from the gingival margin of the adjacent tooth and end at a distance from the vertex of the papilla that should equal the desired amount of coronal advancement of the marginal tissues.

The flap is raised by performing a split-full-split thickness approach. Split-thickness flap elevation starts from the interproximal incisions, placing the scalpel parallel to the long axis of the tooth in order to produce a connective surface; this creates the surgical papillae of the flap, while leaving the anatomical papillae in situ. Full-thickness flap elevation is then performed on the buccal aspect of the teeth included in the surgical area, starting at the sulcus and reaching 3 mm apical to the bone crest. Coronal flap advancement is obtained by sharp dissection consisting in two types of split-thickness incisions: The first is “deep,” parallel to the bone surface, and the second one is “superficial,” parallel to the inner aspect of the flap—freeing the flap from the periosteum and from muscle insertions (Figures 1-3).

The flap design described is indicated for cases in which only the failing tooth is affected by gingival recession, both the failing tooth and one or more of the adjacent teeth are affected by gingival recession, or in situations requiring bone augmentation at the extraction site. In the latter situation, since defects on the buccal bone plate can be over- or underestimated with preoperative radiographic evaluations, flap elevation can allow their effective assessment and treatment.

However, in the presence of altered passive eruption, paramarginal incisions should be performed solely on the teeth adjacent to the future implant site,³⁶ and they should be placed about 1 mm more coronal than normally done for the treatment of altered passive eruption. Split-thickness incisions at the level of the papillae and full-thickness elevation of the buccal keratinized tissues at the future implant site are done as formerly described. In this scenario, flap release from the deep and superficial muscle insertions is site specific—only at the level of the failing tooth and of the two adjacent teeth—to allow coronal advancement in the future implant site. As previously mentioned, the palatal flap and interproximal tissues are never reflected (Figures 4-6).

4 | INTRAOPERATIVE TOOTH EXTRACTION

It has been reported that when a full-thickness flap is raised during tooth extraction, an additional 0.7 mm of tissue remodeling has to be expected.³⁷ Nevertheless, a study by Binderman et al³⁸

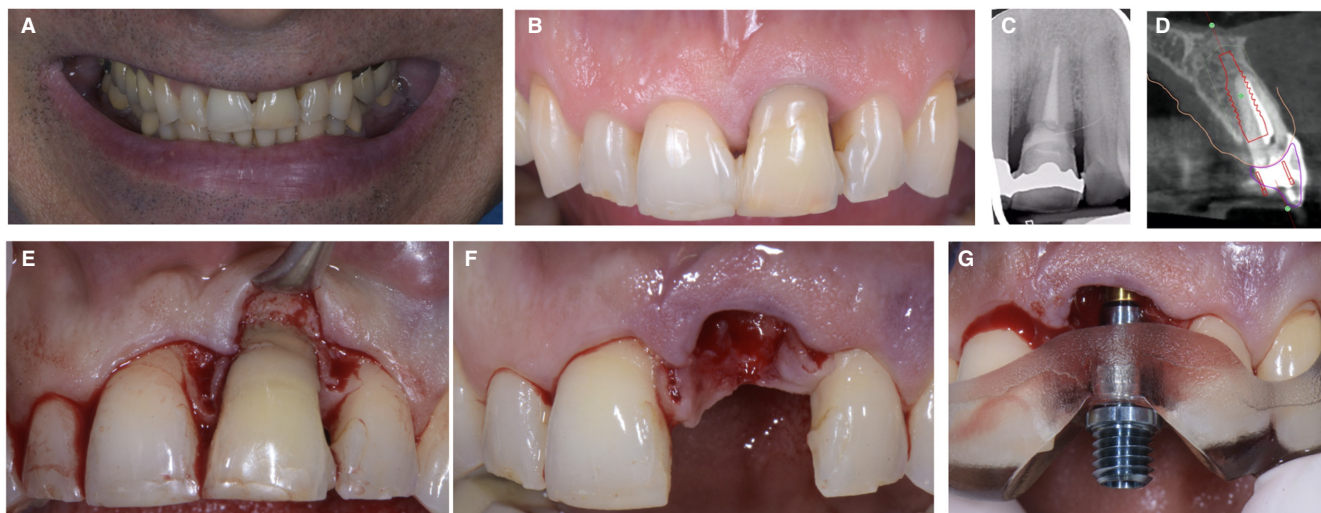


FIGURE 1 Case 1. A,B, Baseline situation showing gingival recession and open gingival embrasures around failing tooth 21. C, Periapical radiograph shows advanced subgingival tooth decay. D, Digital planning with prosthetically-guided implant position. E,F, Elevation of a split-full-split thickness flap and intraoperative tooth extraction preserves the integrity of the buccal, interproximal and palatal tissues. G, Fully guided implant placement

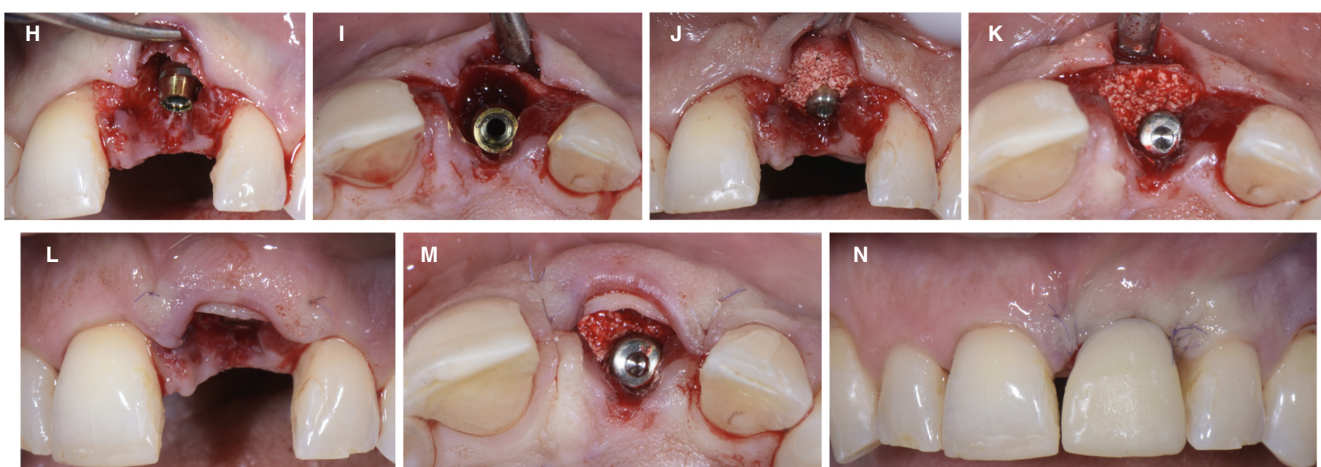


FIGURE 2 Case 1. H,I, Ideal apico-coronal, bucco-lingual, and mesio-distal implant position. J,K, Filling of the bone-implant gap with a mixture of biomaterial and autologous bone within the limits of the surrounding bone contours. L, CTG sutured to the internal aspect of the buccal flap in a paramarginal position. M, Flap closure is started with simple interrupted sutures on the peri-implant papillae before placement of the provisional crown. N, Flap closure is completed and improved with a sling suture suspended around the provisional crown.

comparing two approaches for the elevation of a mucoperiosteal flap reported that an incision in the marginal gingiva for flap elevation induced marked bone remodeling, but no significant crestal bone loss was observed when performing blunt dissection for the elevation of the full-thickness flap. Their findings suggested that the injury and breakdown of the marginal connective tissue was responsible for triggering bone loss after flap elevation. In other words, the intrasulcular use of a surgical blade should be avoided to minimize the damage or thinning of the facial marginal tissues of the flap, which could result in additional bone loss at the extraction site.

Following this rationale, flap elevation in the mucogingival approach to immediate implant placement is performed full thickness in

the central portion by inserting the periosteum elevator directly into the sulcus. Furthermore, surgical access facilitates tooth extraction and helps minimize the trauma on the surrounding soft tissues. By raising a flap, injury to the buccal soft tissues during placement of the extraction forceps can be avoided. The improved visibility allows atraumatic extraction of the tooth (or root fragment), which is essential for preserving the integrity of the anatomical papillae and of the buccal bone plate.

When dealing with cases involving altered passive eruption, once the failing tooth has been extracted, the corrective osteoplasty can be performed initially with a mini bone scraper to collect some autologous bone chips that can be used later on at the implant site (see Section 6). Afterwards, osteoplasty and ostectomy can be

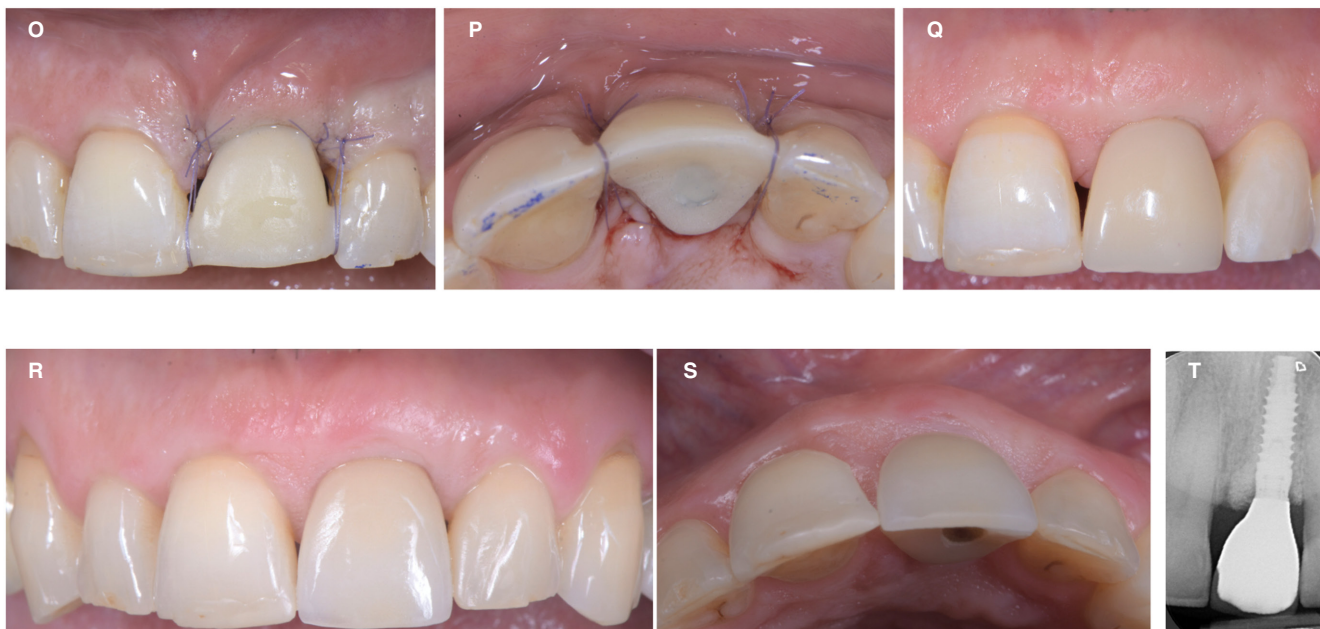


FIGURE 3 Case 1. O,P, Intimate flap adaptation creates a seal around the provisional crown, occlusal contacts and interferences are removed. Q, Situation at 4 months post-op, final stages of soft tissue conditioning with the provisional crown. R,S,T Follow-up after 5 years shows complete papillae fill interproximally and natural, esthetic buccal contour; the periapical radiograph shows stability of the crestal bone level.

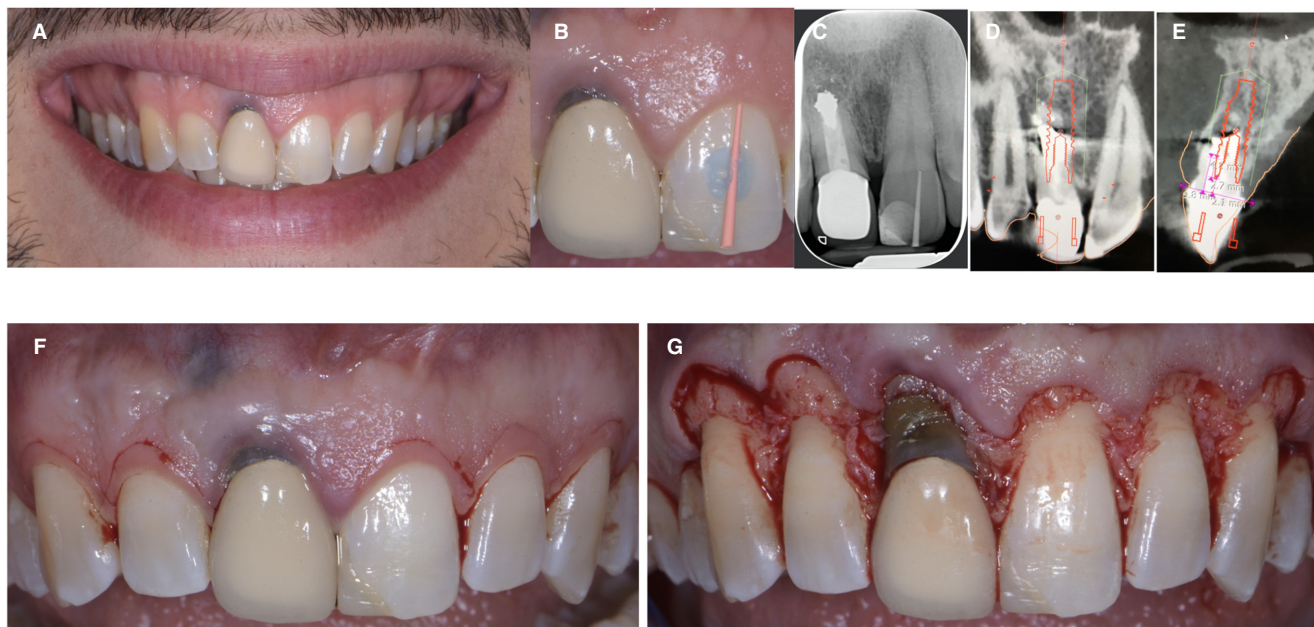


FIGURE 4 Case 2. A, Baseline situation showing dark root discoloration and misalignment of the gingival margin around failing tooth 11. B,C, Diagnostic test and radiograph confirms presence of altered passive eruption in the frontal aesthetic area. D,E, Digital implant planning foreseeing the ideal apico-coronal position of the future gingival margin. F, G, Flap design following the principles of crown-lengthening surgery without placing paramarginal incisions on the future implant site. Flap elevation is done partial thickness in the papilla area and full thickness at the other teeth in the surgical area, before tooth extraction

completed with rotating instruments and chisels as required, until restoring a physiologic bony architecture and repositioning the buccal bone crest of each affected tooth at a distance of 2-3mm from the cemento-enamel junction.³⁶

5 | FULLY GUIDED IMPLANT PLACEMENT

Errors in buccolingual implant position and angulation are a common finding in cases of immediate implant placement, mainly due to the

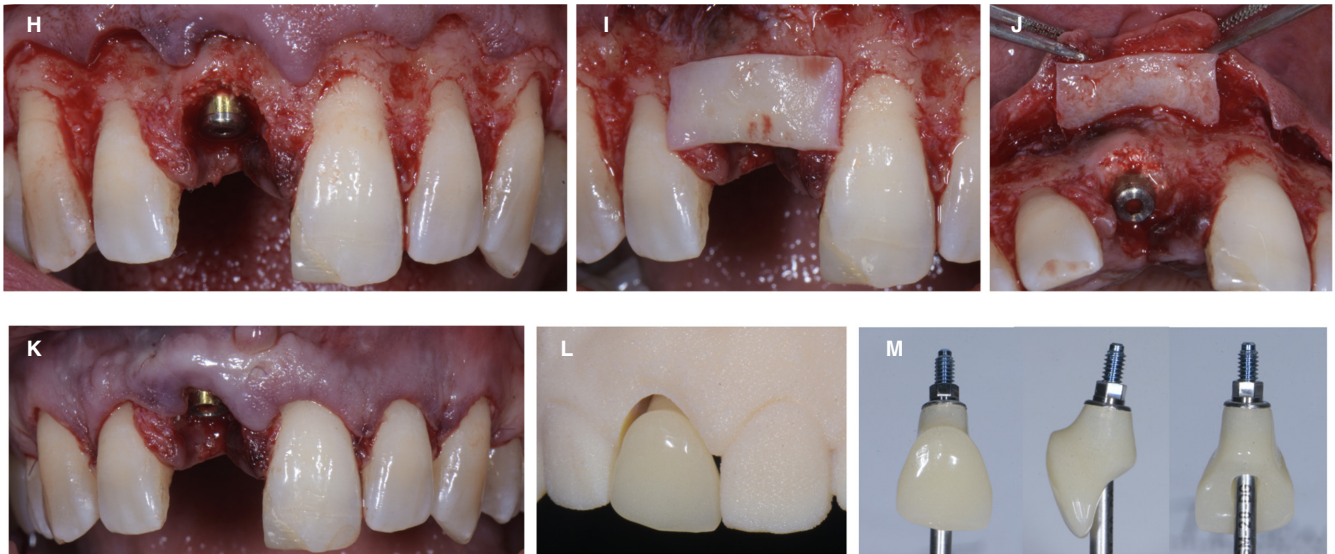


FIGURE 5 Case 2. H, Restoration of the ideal bone contours after osteotomy and osteoplasty at the teeth affected by altered passive eruption followed by fully-guided implant placement and gap fill with bone graft. I, Dimensions of the CTG should encompass the base of the peri-implant papillae mesio-distally and its height should extend from the desired position of the gingival margin to 2-3mm apically to the position of the buccal bone crest. J, Fixation of the CTG to the internal aspect of the flap. K, Flap closure is done with simple interrupted sutures in the peripheral area of the flap before placement of the provisional crown. L, M, Ideal characteristics of the provisional restoration include undercontouring in all aspects of the transgingival portion of the crown.

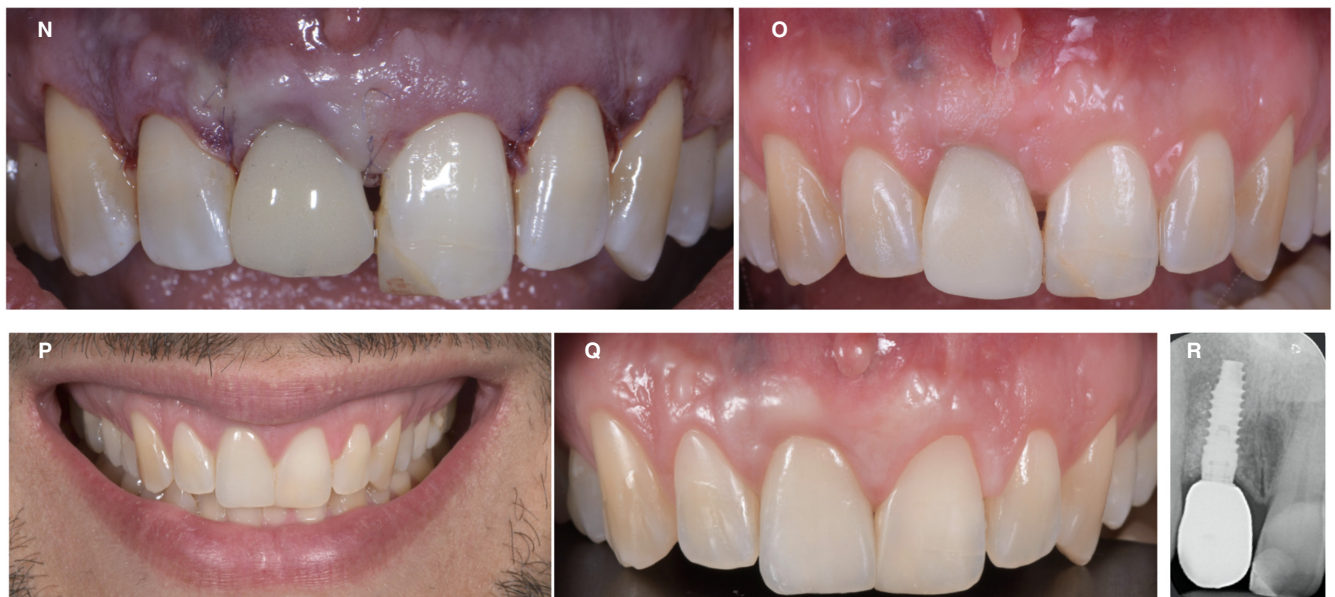

FIGURE 6 Case 2. N, The flap is coronally advanced around the implant and fixed with simple interrupted sutures and a final sling suture around the provisional. O, Healing after 2 months. P,Q,R, Follow-up after 5 years showing improved aesthetics at the treated area and stability of the peri-implant bone radiographically.

anatomy of the postextraction socket and the need for primary implant stability, which can highly influence free-hand implant installation. Static computer-aided implant placement consists in the use of high-precision restrictive surgical guides generated on the basis of preoperative digital planning.³⁹⁻⁴¹ Fully guided implant placement is when the aforementioned guides are used for both implant site preparation and implant installation. According to a couple of studies,^{26,42} superior accuracy and significantly lower three-dimensional

deviations between the planned and actual implant position can be achieved with fully guided protocols compared with partially guided and freehand placement (0.22 ± 0.07 mm, 0.69 ± 0.15 mm, and 0.80 ± 0.35 mm offset at the crest, respectively; mean differences in angular deviation of 4.41° and of 2.11° for free hand and partially guided placement, respectively, versus fully guided implants). Use of digital planning software for guided implant surgery is also crucial in cases with limited mesiodistal space in order to respect the minimum

1.5 mm required tooth-to-implant distance,^{43,44} which is critical for maintenance of esthetics and peri-implant health in the interproximal area as well as for avoiding any damage to adjacent roots. Additionally, primary implant stability—a prerequisite for immediate implant placement and provisionalization—can be ensured by planning implant placement in a position that engages the palatal wall and the bone 4–5 mm beyond the apex of the extraction socket.⁴⁵

During planning, the apicocoronal implant position is chosen according to the position of the gingival margin of the reference tooth. It follows that positioning errors, such as a very shallow implant placement, can result from undiagnosed altered passive eruption on the teeth adjacent to the implant site. Therefore, during digital implant planning in such cases it is necessary to predetermine the amount of crown lengthening to be done on the adjacent teeth and use these measurements to place the rough portion of the implant at a distance of 3.5–4 mm from the ideal position of the mucosal margin of the future implant-supported crown.⁴⁶

The mucogingival approach to immediate implant placement foresees that fully guided implant placement is done only after complete elevation of the buccal flap and subsequent correction of the altered passive eruption, when required.

6 | BONE AUGMENTATION

Bone thickness of 1.8–2 mm on the buccal aspect of dental implants has been suggested to ensure predictable long-term stability of the hard and soft tissues.^{44,47} However, according to several studies,^{48–50} the reported buccal bone thickness in the maxillary anterior region—as measured by computed tomography in healthy

patients—is frequently less than 1 mm in as many as 74% of cases. In addition, as a consequence of postextraction alveolar remodeling, the mean changes in horizontal bone dimensions at immediate implant sites in the maxillary esthetic zone amount to nearly 0.7 mm.⁵¹ In contrast, the use of bone-substitute materials during immediate implant placement has been advocated to reduce horizontal buccal bone resorption,⁵² therefore, careful presurgical assessment should include planning of a buccal bone graft.

When implementing the mucogingival approach to immediate implant placement there are two possible scenarios: intact buccal bone wall, or presence of buccal dehiscence in the postextraction socket. In the first scenario, the gap between the buccal bone plate and the implant surface is an area that requires bone grafting because the implant is positioned more palatal with respect to the original root position.⁴³ Internal socket grafting will favor bone formation and reduce the risk of advanced remodeling of the buccal contour.⁵³ The gap should be filled with bone graft material, preferably combined with autologous bone harvested from adjacent intraoral areas with a bone scraper. In the presence of buccal bone dehiscence, the defect can be treated with a mixture of bone-substitute material and autologous bone chips covered and stabilized with a resorbable barrier membrane.⁵⁴ Thanks to the split-thickness flap elevation, the membrane can be secured in place by suturing it to the periosteum remaining laterally to the extraction site.

In both of the aforementioned scenarios, excessive amounts of bone graft should be avoided, taking care to place the bone graft at a level where buccal bone reconstruction is predictable: Vertical augmentation should end at the level of the implant's rough surface, and horizontal augmentation should follow the convex contour of the buccal bone (Figures 7–9).

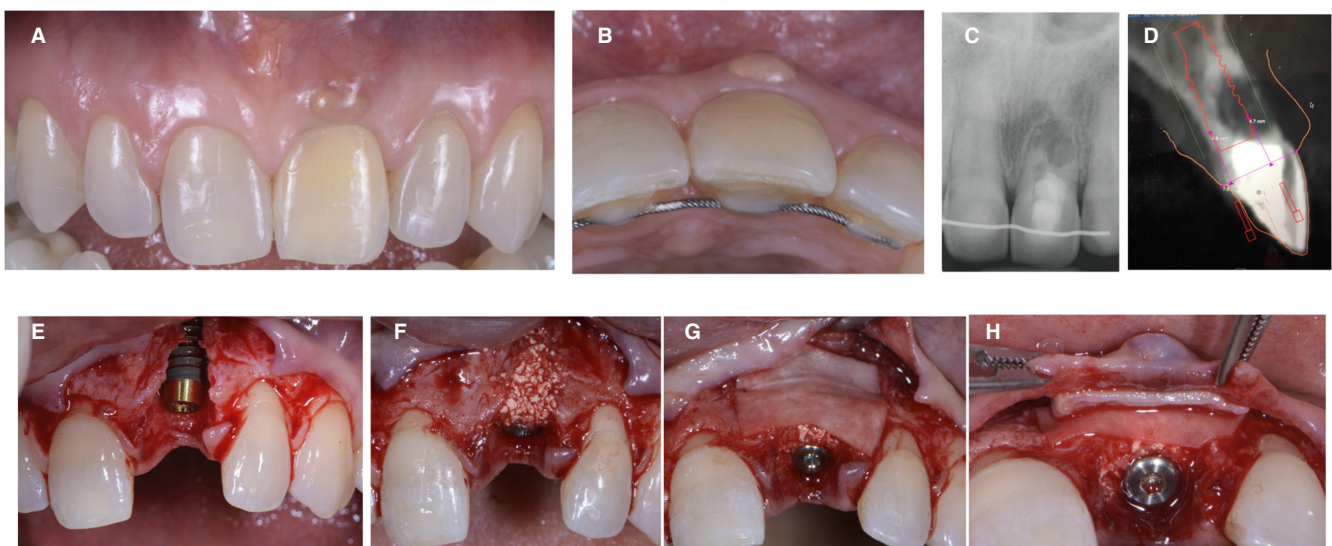


FIGURE 7 Case 3. A,B,C, Baseline situation shows presence of a chronic inflammatory lesion on tooth 21 associated with resorption of the buccal bone plate. D, Digital planning shows availability of bone palatally and apically to ensure primary stability. E, A split-full-split thickness envelope flap was raised with oblique interproximal incisions directed towards the center of rotation; guided implant placement was successful regardless of the considerable buccal bone dehiscence defect. F,G,H, A mixture of biomaterial and autologous bone was placed within the buccal bone contour of the adjacent teeth. The resorbable membrane was fixed with simple interrupted sutures anchored to the periosteum laterally and a CTG was sutured to the internal aspect of the flap.

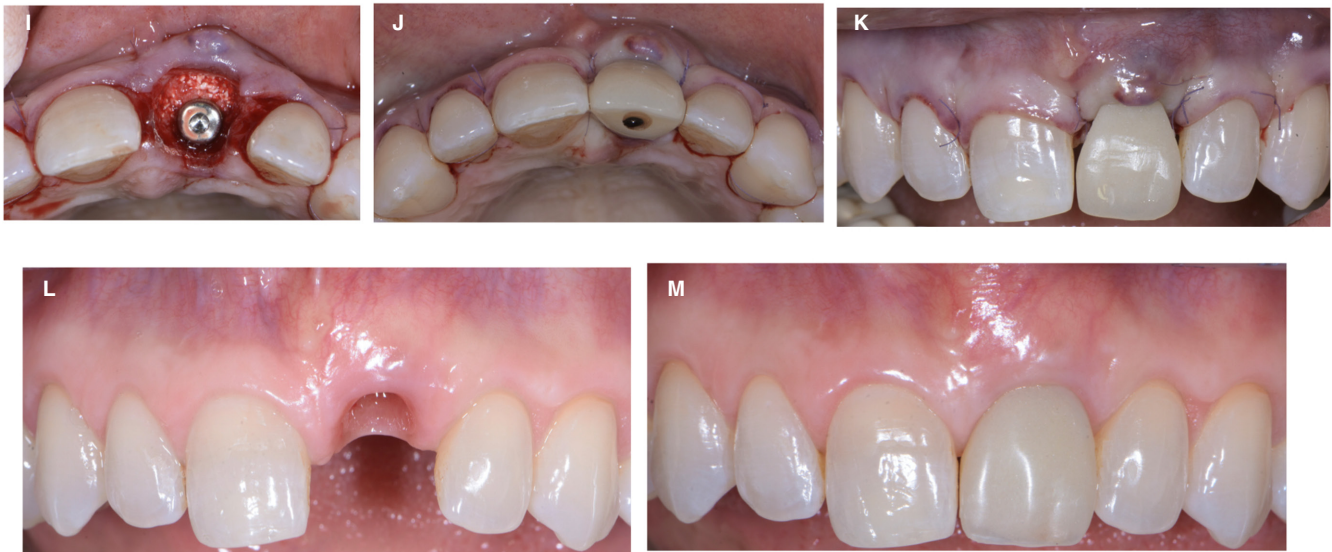


FIGURE 8 Case 3. I, Closure of the coronally advanced flap begins with sling sutures around the peripheral areas of the flap before placement of the provisional crown. J,K, After crown placement, simple interrupted sutures are placed at the peri-implant papillae and a final sling suture improved adaptation and ensures marginal stability. L, Undercontouring of the provisional restoration allowed growth and maturation of the buccal and interproximal soft tissues. M, Situation after 6 months, at the end of the soft tissue conditioning phase with the provisional.

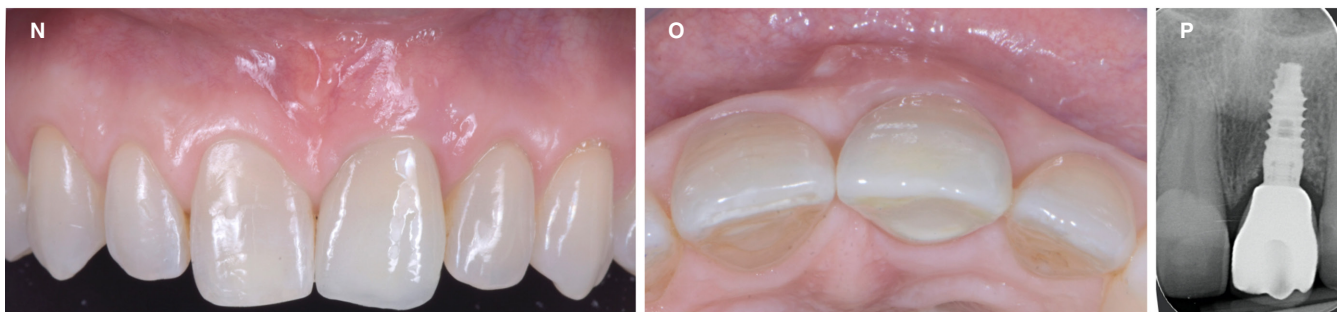


FIGURE 9 Case 3. N, O,P, Follow-up after 5 years showing improved aesthetics at the treated area, restoration of the buccal contour and stability of the peri-implant bone radiographically.

Bone graft particles that impinge on the area belonging to the supracrestal soft tissues must be removed before placing the connective tissue graft, since excessive amounts of bone graft at the supracrestal level will not integrate and risk becoming encapsulated in scar tissue.

7 | SOFT TISSUE AUGMENTATION

Several advantages seem to be related to the adjunctive use of connective tissue grafts simultaneously with immediate implant placement in cases of high esthetic priority.^{55–57} It has been reported that a connective tissue graft is able to promote greater stability of peri-implant bone levels,^{58,59} improve mucosal thickness and peri-implant conditions around the implant-supported crown, and prevent risk of future esthetic and functional complications, such as mucositis and midfacial recession.^{60,61}

Mucosal thickness plays a major role in esthetic outcomes and peri-implant health.⁵⁹ Implant sites with soft tissue grafts have demonstrated more facial dimensional gain and significantly better color match of the peri-implant mucosa than implant sites without soft tissue grafts have.⁶² Compared with thin soft tissues, thicker tissues can provide greater stability of the mucosal margin: According to a recent meta-analysis,⁵⁷ soft tissue augmentation with a connective tissue graft following immediate implant placement in esthetic areas results in significantly less recession (mean difference 0.38 mm, $P=0.005$) and a significantly thicker mid-buccal mucosa (mean difference 0.87 mm, $P<0.001$) when compared with no grafting after 1 year. Furthermore, concomitant soft and hard tissue augmentations have reported less marginal soft tissue recession when compared with hard tissue augmentation alone.⁶¹

Increased mucosal thickness (greater than 2 mm) may also promote greater stability of interproximal marginal bone levels⁶³ and minimize peri-implant bone loss overall.^{63–67} When the effect of

phenotype modification on changes in marginal bone loss was assessed in a recent meta-analysis, treatment with connective tissue graft resulted in significantly less marginal bone loss than control sites with no soft tissue augmentation did.⁵⁸

Furthermore, the buccal soft-tissue thickness needed to mask the implant-prosthetic components (at least 2 mm),⁶⁸ and to reduce the risk for development of peri-implant soft tissue dehiscence, is rarely present in immediate postextractive implant cases. Therefore, buccal soft-tissue augmentation techniques performed simultaneously with postextractive, immediately provisionalized implants is strongly suggested.

After implant placement and peri-implant bone augmentation, the anatomical interproximal papillae included in the surgical area need to be carefully de-epithelialized to promote first intention wound healing with the overlying flap. The mucogingival approach to immediate implant placement technique foresees the placement of a de-epithelialized connective tissue graft harvested from the posterior palate.^{69,70} The graft should be sutured to the internal aspect of the buccal flap at the implant site, where it will serve both to stabilize the area of bone augmentation and also to increase soft tissue thickness buccally at the level of the future peri-implant transmucosal path. The vertical dimensions of the connective tissue graft should cover from 1 mm coronal to the level of the soft tissue margin of the reference tooth and up to 2-3 mm of bone apical to the buccal bone crest at the implant site; mesiodistal graft dimensions should extend to the base of the surgical papillae of the flap. Graft thickness should be at least 1 mm in order to guarantee a minimum thickness of 2 mm of the entire buccal soft tissues (ie, flap plus graft).

The connective tissue graft is secured to the internal aspect of the buccal flap with two horizontal internal mattress sutures placed mesially and distally. The graft should be sutured in a paramarginal position, 1 mm apical to the scalloped margin of the buccal flap to prevent graft exposure and to avoid interference with primary closure in the area of the papillae.

8 | IMMEDIATE PROVISIONALIZATION AND FLAP CLOSURE

One crucial aspect for the stability and maturation of the peri-implant soft tissues is the implant-supported crown.^{71,72} The ideal characteristics of the emergence profiles of these restorations have been described in the literature as the critical and subcritical contours,⁷³ and more recently as the esthetic biological contour concept.⁷⁴ The latter article subdivides the subgingival contour of the implant restoration into three zones: an esthetic zone (E), corresponding to the 1 mm subgingival area immediately apical to the free gingival margin; a bounded zone (B), immediately apical to the esthetic zone and measuring approximately 1-2 mm; and a crestal zone (C), 1-1.5 mm area located immediately coronal to the implant platform. Although the crestal and esthetic zones have an established conformation—straight and convex, respectively—the anatomy of the middle area

defined as zone B will depend on the position of the implant and the thickness of the soft tissues. In this regard, special consideration has to be given when translating this information to provisional crowns placed on postextractive implants. Not only should overcontouring be avoided in all aspects of the restoration, but a concave subcritical contour is mandatory during the initial healing phase to accommodate the augmented buccal soft tissues. The prosthetic emergence profile at the interproximal area should also be deliberately undercontoured to allow space for papillae growth and maturation without unwanted mechanical compression. Immediate provisionalization without occlusal loading is advised.

Digitally guided implant planning allows the fabrication of a very precise-fitting provisional crown. In this way, the clinician does not have to deal with a shell that has to be extensively relined and can predictably foresee the use of a screw-retained restoration.

During flap closure, the first sutures that have to be placed are the ones that stabilize the peripheral area of the flap; the central area (ie, implant site) is sutured last, after the provisional crown has been placed. Following the principles of mucogingival techniques,²⁸ sling sutures suspended around the cingula of the teeth in the treated area are performed to stabilize the coronally advanced flap while allowing its precise adaptation at the buccal aspect and ensuring intimate contact between every single surgical papilla and the interdental connective tissue surface. Coronal displacement of the flap compensates for the tendency for its apical shrinkage and allows simultaneous treatment of gingival recession defects present at the implant site or on adjacent teeth.

Conversely, in cases also being treated for altered passive eruption, flap closure consists of simple interrupted sutures that stabilize the vertices of the surgical papillae at the base of the corresponding anatomical de-epithelialized papillae, allowing apical repositioning of the flap at the level of the teeth that need to be elongated.

At the implant site, simple interrupted sutures are first performed on the peri-implant papillae, followed by a sling suture anchored to the palatal cingulum of the provisional crown. Regardless of the treatment being performed at the adjacent teeth, coronal flap advancement must always take place around the implant. This is done to compensate for future primary and/or secondary flap shrinkage, but especially to obtain an excessive increase in height of the buccal and interproximal soft tissues, which can then be conditioned in posterior phases to achieve optimal esthetics.

9 | POSTSURGICAL CARE AND SUBSEQUENT PROSTHETIC PHASES

During the first 2 weeks, mechanical cleaning is abandoned at the surgical site. During this period, chemical plaque control should be performed three times a day with a chlorhexidine digluconate (0.12%) mouthwash. Sutures are removed after 14 days and use of a soft toothbrush at the treated area can be reinstated afterwards. Follow-up visits are recommended after 1, 3, and 6 months with clinical examination and local hygiene of the treated area.

Modifications on the provisional screw-retained crown, including occlusal loading, should take place only after 3-4 months from implant insertion. This will ensure the stability and time needed for osteointegration to occur and for the supracrestal soft tissues to mature and grow, both buccally and interproximally. At this point, soft tissue conditioning can be started by making small increments to the provisional crown until achieving the desired scallop of the mucosal margin and fill of the interproximal embrasure. In this way, the final crown should ideally be placed 6-8 months after implant placement.

10 | CONCLUDING REMARKS

When contemplating the possibility of performing immediate implant placement in the esthetic area, thorough examination of the case at hand should lead the clinician to establish the need for additional therapy both at the site of the failing tooth and in the surrounding dentition based on the quantity and morphology of the soft and hard tissues.

Predetermination of the ideal implant position can be transferred to a digital project, and fully guided implant placement is advised in order to avoid deviations from the desired apicocoronal, mesiodistal, and buccolingual position. However, the presence of altered passive eruption or gingival recession in the treated area should always be acknowledged during the treatment-planning stage.

If the case does not meet the criteria for flapless immediate implant placement, raising a buccal flap could still make it possible to place an immediate implant. The more apical position of the gingival margin on the tooth to be extracted is no longer a contraindication for the postextractive implant with immediate provisionalization because the initial unfavorable position of the marginal soft tissues can be compensated by the coronal advancement of the access flap.

Elevation of a buccal flap allows the comprehensive treatment of both the implant site—such as reconstruction of the buccal hard and soft tissues—and the neighboring dentition—in cases with concomitant presence of gingival recession or altered passive eruption. The mucogingival approach to the immediate implant placement technique ensures adequate three-dimensional implant placement, makes it possible to perform bone augmentation with complete visibility of the area being treated, allows soft tissue augmentation with proper fixation of the connective tissue graft, and foresees the placement of an immediate provisional that can stabilize the peri-implant tissues throughout the healing period.

ACKNOWLEDGMENTS

Thanks to Professor Carlo Monaco and Dr Pietro Bellone for having performed the restorative and prosthetic parts.

ORCID

Martina Stefanini  <https://orcid.org/0000-0002-9154-637X>

Matteo Sangiorgi  <https://orcid.org/0000-0003-3778-4243>

REFERENCES

1. Araújo MG, Sukekava F, Wennström JL, Lindhe J. Ridge alterations following implant placement in fresh extraction sockets: an experimental study in the dog. *J Clin Periodontol*. 2005;32:645-652.
2. Araújo MG, Wennström JL, Lindhe J. Modeling of the buccal and lingual bone walls of fresh extraction sites following implant installation. *Clin Oral Implants Res*. 2006;17:606-614.
3. Bakkali S, Rizo-Gorrita M, Romero-Ruiz M-M, Gutiérrez-Pérez JL, Torres-Lagares D, Serrera-Figallo MÁ. Efficacy of different surgical techniques for peri-implant tissue preservation in immediate implant placement: a systematic review and meta-analysis. *Clin Oral Investig*. 2021;25:1655-1675.
4. Baldini N, Zucchelli G, De Sanctis M. A novel surgical technique for soft tissue management in aesthetic areas of the mouth at implant placement. *J Parodontol & d' Implantol Orale*. 2010;29(4).
5. Becker W, Wikesjö UME, Sennerby L, et al. Histologic evaluation of implants following flapless and flapped surgery: a study in canines. *J Periodontol*. 2006;77:1717-1722.
6. Binderman I, Adut M, Zohar R, Bahar H, Faibish D, Yaffe A. Alveolar bone resorption following coronal versus apical approach in a mucoperiosteal flap surgery procedure in the rat mandible. *J Periodontol*. 2001;72:1348-1353.
7. Blanco J, Nuñez V, Aracil L, Muñoz F, Ramos I. Ridge alterations following immediate implant placement in the dog: flap versus flapless surgery. *J Clin Periodontol*. 2008;35:640-648.
8. Buser D, Chappuis V, Belser UC, Chen S. Implant placement post extraction in esthetic single tooth sites: when immediate, when early, when late? *Periodontol* 2000. 2000;2017(73):84-102.
9. Buser D, Martin W, Belser UC. Optimizing esthetics for implant restorations in the anterior maxilla: anatomic and surgical considerations. *Int J Oral Maxillofac Implants*. 2004;19(Suppl):43-61.
10. Campelo LD, Camara JRD. Flapless implant surgery: a 10-year clinical retrospective analysis. *Int J Oral Maxillofac Implants*. 2002;17:271-276.
11. Caneva M, Salata LA, De Souza SS, Bressan E, Botticelli D, Lang NP. Hard tissue formation adjacent to implants of various size and configuration immediately placed into extraction sockets: an experimental study in dogs: implant configuration and osseointegration. *Clin Oral Implants Res*. 2010;21(9):885-890.
12. Chen S, Buser D. Esthetic outcomes following immediate and early implant placement in the anterior maxilla—a systematic review. *Int J Oral Maxillofac Implants*. 2014;29:186-215.
13. Chen ST, Buser D. Clinical and esthetic outcomes of implants placed in postextraction sites. *Int J Oral Maxillofac Implants*. 2009;24:186-217.
14. Chen ST, Darby IB, Reynolds EC, Clement JG. Immediate implant placement postextraction without flap elevation. *J Periodontol*. 2009;80:163-172.
15. Cosyn J, Hooghe N, De Bruyn H. A systematic review on the frequency of advanced recession following single immediate implant treatment. *J Clin Periodontol*. 2012;39:582-589.
16. Del Fabbro M, Ceresoli V, Taschieri S, Ceci C, Testori T. Immediate loading of postextraction implants in the esthetic area: systematic review of the literature: immediate implant placement and restoration. *Clin Implant Dent Relat Res*. 2015;17:52-70.
17. D'haese J, Ackhurst J, Wismeijer D, De Bruyn H, Tahmaseb A. Current state of the art of computer-guided implant surgery. *Periodontol* 2000. 2017;73(1):121-133.
18. Donos N, Asche NV, Akbar AN, et al. Impact of timing of dental implant placement and loading: summary and consensus statements of group 1—the 6th EAO consensus conference 2021. *Clin Oral Implants Res*. 2021;32:85-92.
19. Evans CDJ, Chen ST. Esthetic outcomes of immediate implant placements. *Clin Oral Implants Res*. 2008;19(1):73-80.
20. Fickl S, Kebschull M, Schupbach P, Zuhr O, Schlagenhauf U, Hürzeler MB. Bone loss after full-thickness and partial-thickness

- flap elevation: bone loss after flap elevation. *J Clin Periodontol.* 2011;38:157-162.
21. Fickl S, Therese Kröger A, Dietrich T, Kepschull M. Influence of soft tissue augmentation procedures around dental implants on marginal bone level changes—a systematic review. *Clin Oral Implants Res.* 2021;32:108-137.
 22. Fickl S, Zuhr O, Wachtel H, Bolz W, Huerzeler M. Tissue alterations after tooth extraction with and without surgical trauma: a volumetric study in the beagle dog. *J Clin Periodontol.* 2008;35:356-363.
 23. Gao X, Qin S, Cai H, Wan Q. Comparison of general and aesthetic effects between flapless and flap techniques in dental implantation: a meta-analysis of randomized controlled trials. *Int J Implant Dent.* 2021;7:100.
 24. Giannobile WV, Jung RE, Schwarz F. The groups of the 2nd osteology foundation consensus meeting. Evidence-based knowledge on the aesthetics and maintenance of peri-implant soft tissues: osteology foundation consensus report part 1—effects of soft tissue augmentation procedures on the maintenance of peri-implant soft tissue health. *Clin Oral Implants Res.* 2018;29:7-10.
 25. Gomez-Meda R, Esquivel J, Blatz MB. The esthetic biological contour concept for implant restoration emergence profile design. *J EsthetRestor Dent.* 2021;33:173-184.
 26. Grunder U, Gracis S, Capelli M. Influence of the 3-D bone-to-implant relationship on esthetics. *Int J Periodontics Restorative Dent.* 2005;25:113-119.
 27. Guentsch A, Sukhtankar L, An H, Luepke PG. Precision and trueness of implant placement with and without static surgical guides: an in vitro study. *J Prosthet Dent.* 2021;126:398-404.
 28. Heimes D, Schiegnitz E, Kuchen R, Kämmerer PW, Al-Nawas B. Buccal bone thickness in anterior and posterior teeth—a systematic review. *Dent Health.* 2021;9:1663.
 29. Hosseini M, Worsaae N, Gotfredsen K. Tissue changes at implant sites in the anterior maxilla with and without connective tissue grafting: a five-year prospective study. *Clin Oral Implants Res.* 2020;31:18-28.
 30. Jemt T, Lekholm U. Measurements of buccal tissue volumes at single-implant restorations after local bone grafting in maxillas: a 3-year clinical prospective study case series. *Clin Implant Dent Relat Res.* 2003;5:63-70.
 31. Jemt T, Lekholm U. Single implants and buccal bone grafts in the anterior maxilla: measurements of buccal crestal contours in a 6-year prospective clinical study. *Clin Implant Dent Relat Res.* 2005;7:127-135.
 32. Jung RE, Sailer I, Hämmerle CHF, Attin T, Schmidlin P. In vitro color changes of soft tissues caused by restorative materials. *Int J Periodontics Restorative Dent.* 2007;27:251-257.
 33. Jung RE, Schneider D, Ganeles J, et al. Computer technology applications in surgical implant dentistry: a systematic review. *Int J Oral Maxillofac Implants.* 2009;24:92-109.
 34. Kan JYK, Rungcharassaeng K, Deflorian M, Weinstein T, Wang H-L, Testori T. Immediate implant placement and provisionalization of maxillary anterior single implants. *Periodontol 2000.* 2018;77(1):197-212.
 35. Kan JYK, Rungcharassaeng K, Lozada JL, Zimmerman G. Facial gingival tissue stability following immediate placement and provisionalization of maxillary anterior single implants: a 2- to 8-year follow-up. *Int J Oral Maxillofac Implants.* 2011;26:179-187.
 36. Khzam N, Arora H, Kim P, Fisher A, Mattheos N, Ivanovski S. Systematic review of soft tissue alterations and esthetic outcomes following immediate implant placement and restoration of single implants in the anterior maxilla. *J Periodontol.* 2015;86:1321-1330.
 37. Kobayashi T, Nakano T, Ono S, Matsumura A, Yamada S, Yatani H. Quantitative evaluation of connective tissue grafts on peri-implant tissue morphology in the esthetic zone: a 1-year prospective clinical study. *Clin Implant Dent Relat Res.* 2020;22:311-318.
 38. Lin G-H, Chan H-L, Bashutski JD, Oh T-J, Wang H-L. The effect of flapless surgery on implant survival and marginal bone level: a systematic review and meta-analysis. *J Periodontol.* 2014;85:e91-e103.
 39. Linkevicius T, Apse P, Grybauskas S, Puisys A. The influence of soft tissue thickness on crestal bone changes around implants: a 1-year prospective controlled clinical trial. *Int J Oral Maxillofac Implants.* 2009;24:712-719.
 40. Linkevicius T, Puisys A, Steigmann M, Vindasiute E, Linkeviciene L. Influence of vertical soft tissue thickness on crestal bone changes around implants with platform switching: a comparative clinical study: platform switching does not reduce bone loss. *Clin Implant Dent Relat Res.* 2015;17:1228-1236.
 41. Mao Z, Lee C, He SM, Zhang S, Bao J, Xie ZG. Buccal bone dimensional changes at immediate implant sites in the maxillary esthetic zone within a 4-12-month follow-up period: a systematic review and meta-analysis. *Clin Implant Dent Relat Res.* 2021;23:883-903.
 42. Mazzotti C, Stefanini M, Felice P, Bentivogli V, Mounssif I, Zucchelli G. Soft-tissue dehiscence coverage at peri-implant sites. *Periodontol 2000.* 2018;77(1):256-272.
 43. Mele M, Felice P, Sharma P, Mazzotti C, Bellone P, Zucchelli G. Esthetic treatment of altered passive eruption. *Periodontol 2000.* 2018;77(1):65-83.
 44. Puisys A, Linkevicius T. The influence of mucosal tissue thickening on crestal bone stability around bone-level implants. A prospective controlled clinical trial. *Clin Oral Implants Res.* 2015;26:123-129.
 45. Raghoobar GM, Korfage A, Meijer HJA, Gareb B, Vissink A, Delli K. Linear and profilometric changes of the mucosa following soft tissue augmentation in the zone of aesthetic priority: a systematic review and meta-analysis. *Clin Oral Implants Res.* 2021;32:138-156.
 46. Ramfjord SF, Costich ER. Healing after exposure of periosteum on the alveolar process. *J Periodontol.* 1968;39:199-207.
 47. Revilla-León M, Sadeghpour M, Özcan M. An update on applications of 3D printing technologies used for processing polymers used in implant dentistry. *Odontology.* 2020;108:331-338.
 48. Rojo-Sanchis J, Soto-Peñaloza D, Peñarrocha-Oltra D, Peñarrocha-Diago M, Viña-Almunia J. Facial alveolar bone thickness and modifying factors of anterior maxillary teeth: a systematic review and meta-analysis of cone-beam computed tomography studies. *BMC Oral Health.* 2021;21:143.
 49. Sanz M, Lindhe J, Alcaraz J, Sanz-Sanchez I, Cecchinato D. The effect of placing a bone replacement graft in the gap at immediately placed implants: a randomized clinical trial. *Clin Oral Implants Res.* 2017;28:902-910.
 50. Schropp L, Wenzel A. Timing of single implant placement and long-term observation of marginal bone levels. *Eur J Oral Implantol.* 2016;9:S107-S122.
 51. Seyssens L, Eghbali A, Cosyn J. A 10-year prospective study on single immediate implants. *J Clin Periodontol.* 2020;47:1248-1258.
 52. Spinato S, Bernardello F, Lombardi T, et al. Influence of apico-coronal positioning of tissue-level implants on marginal bone stability during supracrestal tissue height establishment: a multi-center prospective study. *Clin Implant Dent Relat Res.* 2022;24:611-620.
 53. Spray JR, Black CG, Morris HF, Ochi S. The influence of bone thickness on facial marginal bone response: stage 1 placement through stage 2 uncovering. *Ann Periodontol.* 2000;5:119-128.
 54. Staffileno H. Significant differences and advantages between the full thickness and split thickness flaps. *J Periodontol.* 1974;45:421-425.
 55. Stefanini M, Sangiorgi M, Bianchelli D, et al. A novel muco-gingival approach for immediate implant placement to obtain soft- and hard-tissue augmentation. *J Clin Med.* 2022;11:4985.

56. Su H, Gonzalez-Martin O, Weisgold A, Lee E. Considerations of implant abutment and crown contour: critical contour and subcritical contour. *Int J Periodontics Restorative Dent*. 2010;30:335-343.
57. Suárez-López del Amo F, Lin G-H, Monje A, Galindo-Moreno P, Wang H-L. Influence of soft tissue thickness on peri-implant marginal bone loss: a systematic review and meta-analysis. *J Periodontol*. 2016;87:690-699.
58. Tattan M, Chambrone L, González-Martín O, Avila-Ortiz G. Static computer-aided, partially guided, and free-handed implant placement: a systematic review and meta-analysis of randomized controlled trials. *Clin Oral Implants Res*. 2020;31:889-916.
59. Tavelli L, Barootchi S, Avila-Ortiz G, Urban IA, Giannobile WV, Wang H. Peri-implant soft tissue phenotype modification and its impact on peri-implant health: a systematic review and network meta-analysis. *J Periodontol*. 2021;92:21-44.
60. Thoma DS, Bienz SP, Figuero E, Jung RE, Sanz-Martín I. Efficacy of lateral bone augmentation performed simultaneously with dental implant placement: a systematic review and meta-analysis. *J Clin Periodontol*. 2019;46:257-276.
61. Thoma DS, Cosyn J, Fickl S, et al. Soft tissue management at implants: summary and consensus statements of group 2. The 6th EAO consensus conference 2021. *Clin Oral Implants Res*. 2021;32:174-180.
62. Thoma DS, Naenni N, Figuero E, et al. Effects of soft tissue augmentation procedures on peri-implant health or disease: a systematic review and meta-analysis. *Clin Oral Implants Res*. 2018;29:32-49.
63. Tsigarida A, Toscano J, Brito Bezerra B, et al. Buccal bone thickness of maxillary anterior teeth: a systematic review and meta-analysis. *J Clin Periodontol*. 2020;47:1326-1343.
64. Vignoletti F, Discepoli N, Müller A, Sanctis M, Muñoz F, Sanz M. Bone modelling at fresh extraction sockets: immediate implant placement versus spontaneous healing. An experimental study in the beagle dog. *J Clin Periodontol*. 2012;39:91-97.
65. Wood DL, Hoag PM, Donnenfeld OW, Rosenfeld LD. Alveolar crest reduction following full and partial thickness flaps. *J Periodontol*. 1972;43:141-144.
66. Zaki J, Yusuf N, El-Khadem A, Scholten RJPM, Jenniskens K. Efficacy of bone-substitute materials use in immediate dental implant placement: a systematic review and meta-analysis. *Clin Implant Dent Relat Res*. 2021;23:506-519.
67. Zucchelli G, De Sanctis M. Treatment of multiple recession-type defects in patients with esthetic demands. *J Periodontol*. 2000;71:1506-1514.
68. Zucchelli G, Felice P, Mazzotti C, et al. 5-year outcomes after coverage of soft tissue dehiscence around single implants: a prospective cohort study. *Eur J Oral Implantol*. 2018;11:215-224.
69. Zucchelli G, Mazzotti C, Mounssif I, Marzadori M, Stefanini M. Esthetic treatment of Peri-implant soft tissue defects: a case report of a modified surgical-prosthetic approach. *Int J Periodontics Restorative Dent*. 2013;33:327-335.
70. Zucchelli G, Mazzotti C, Mounssif I, Mele M, Stefanini M, Montebugnoli L. A novel surgical-prosthetic approach for soft tissue dehiscence coverage around single implant. *Clin Oral Implants Res*. 2013;24(9):957-962.
71. Zucchelli G, Mele M, Mazzotti C, Marzadori M, Montebugnoli L, De Sanctis M. Coronally advanced flap with and without vertical releasing incisions for the treatment of multiple gingival recessions: a comparative controlled randomized clinical trial. *J Periodontol*. 2009;80:1083-1094.
72. Zucchelli G, Mele M, Stefanini M, et al. Patient morbidity and root coverage outcome after subepithelial connective tissue and de-epithelialized grafts: a comparative randomized-controlled clinical trial: patient morbidity and root coverage outcome after grafts. *J Clin Periodontol*. 2010;37(8):728-738.
73. Zucchelli G, Tavelli L, McGuire MK, et al. Autogenous soft tissue grafting for periodontal and peri-implant plastic surgical reconstruction. *J Periodontol*. 2020;91:9-16.
74. Zucchelli G, Tavelli L, Stefanini M, Barootchi S, Wang H-L. The coronally advanced flap technique revisited: treatment of peri-implant soft tissue dehiscences. *Int J Oral Implantol (Berl)*. 2021;14:351-365.

How to cite this article: Stefanini M, Rendón A, Zucchelli A, Sangiorgi M, Zucchelli G. Avoiding errors and complications related to immediate implant placement in the esthetic area with a mucogingival approach. *Periodontol 2000*. 2023;92:362-372. doi:[10.1111/prd.12491](https://doi.org/10.1111/prd.12491)