

HEAD AND NECK

# Prevention of fistulas after salvage laryngectomy using temporoparietal fascia free flap

## *L'utilizzo del lembo libero di fascia temporoparietale per la prevenzione delle fistole dopo laringectomia di salvataggio*

Raul Pellini<sup>1</sup>, Jacopo Zocchi<sup>1</sup>, Barbara Pichi<sup>1</sup>, Valentina Manciocco<sup>1</sup>, Paolo Marchesi<sup>1</sup>, Isabella Sperduti<sup>1</sup>, Giuseppe Mercante<sup>2</sup>, Gabriele Molteni<sup>3</sup>, Oreste Iocca<sup>2</sup>, Pasquale Di Maio<sup>2</sup>, Armando De Virgilio<sup>2</sup>, Antonello Vidiri<sup>4</sup>, Giuseppe Sanguineti<sup>5</sup>, Giuseppe Spriano<sup>2</sup>

<sup>1</sup> IRCCS "Regina Elena" National Cancer Center, Rome, Italy; <sup>2</sup> Otorhinolaryngology Unit, Humanitas University, IRCCS Humanitas Clinical and Research Center, Rozzano (MI), Italy; <sup>3</sup> Department of Otolaryngology, University Hospital of Verona. University of Verona; <sup>4</sup> IRCCS "Regina Elena" National Cancer Center Department of Radiology; <sup>5</sup> IRCCS "Regina Elena" National Cancer Center Department of Radiotherapy

### SUMMARY

We conducted a retrospective review to assess the role of the temporoparietalis fascia flap (TPFF), comparing rates of postoperative pharyngocutaneous fistula (PCF) and functional outcomes with those of pectoralis major myocutaneous flap (PMMF) and primary closure of the pharynx, in a population of patients treated with salvage total laryngectomy (STL). Patients were divided in three groups depending on the pharynx reconstruction technique after primary closure: no vascularised tissue augmentation (group 1), PMMF patch (group 2), or TPFF patch (group 3). The main outcomes analysed were overall fistula rate, fistula requiring reoperation and speech and swallowing function at 6 months. Factors influencing the incidence of fistulas were also evaluated. 39 patients respected inclusion criteria: 14, 11 and 14 patients in the three groups, respectively. Nine patients of 39 (23.1%) experienced a PCF. No statistically significant differences were noted between the three groups, except for a longer surgical operation time and a trend for better functional results in group 3. None of the factors analysed significantly influenced the overall rate of fistula. TPFF patch thus represents a reliable alternative to PMMF in preventing PCF in the setting of STL, with minor donor-site morbidity and good functional outcomes.

**KEY WORDS:** laryngectomy, flaps, surgery, fistulas

### RIASSUNTO

È stata condotta una revisione retrospettiva per valutare il ruolo del lembo di fascia temporoparietale (TPFF), confrontando i tassi di fistola faringocutanea postoperatoria (PCF) e gli esiti funzionali con quelli del lembo miofasciale di gran pettorale (PMMF) e la chiusura primaria del faringe, in una popolazione di pazienti trattati con laringectomia totale di salvataggio (STL). I pazienti sono stati divisi in tre gruppi a seconda della tecnica di chiusura del faringe dopo sutura diretta dello stesso: nessun rinforzo con tessuto vascolarizzato (gruppo 1), patch con PMMF (gruppo 2) o patch con TPFF (gruppo 3). I principali risultati analizzati sono stati la frequenza complessiva della fistola, la necessità di re-intervento e gli esiti funzionali inerenti linguaggio e deglutizione a 6 mesi. Sono stati anche valutati i possibili fattori predisponenti l'incidenza delle fistole. 39 pazienti hanno rispettato i criteri di inclusione: rispettivamente 14, 11 e 14 pazienti nei tre gruppi. In nove pazienti su 39 (23,1%) il decorso è stato complicato dallo sviluppo di PCF. Non sono stati osservati risultati statisticamente diversi tra i tre gruppi, fatta eccezione per un tempo di intervento chirurgico più lungo e una tendenza a risultati funzionali migliori nel gruppo 3. Nessuno dei fattori analizzati ha influenzato in modo significativo la frequenza complessiva della fistola. L'utilizzo del TPFF rappresenta un'alternativa affidabile al PMMF nella prevenzione della fistola faringocutanea nel contesto delle laringectomie di salvataggio, con morbilità minore nel sito donatore e buoni risultati funzionali.

**PAROLE CHIAVE:** laringectomia, lembi, chirurgia, fistole

Received: July 31, 2019  
Accepted: December 8, 2019

### Correspondence

**Jacopo Zocchi**  
IRCCS "Regina Elena" National Cancer Center,  
Rome, Italy  
E-mail: jaczocchi@gmail.com

### Funding

None.

### Conflict of interest

The Authors declare no conflict of interest.

**How to cite this article:** Pellini R, Zocchi J, Pichi B, et al. Prevention of fistulas after salvage laryngectomy using temporoparietal fascia free flap. Acta Otorhinolaryngol Ital 2020;40:181-189. <https://doi.org/10.14639/0392-100X-N0411>

© Società Italiana di Otorinolaringoiatria e Chirurgia Cervico-Facciale



OPEN ACCESS

This is an open access article distributed in accordance with the CC-BY-NC-ND (Creative Commons Attribution-Non-Commercial-NoDerivatives 4.0 International) license. The article can be used by giving appropriate credit and mentioning the license, but only for non-commercial purposes and only in the original version. For further information: <https://creativecommons.org/licenses/by-nc-nd/4.0/deed.en>

## Introduction

The advent of chemoradiotherapy (CRT) protocols has shifted the treatment paradigm of advanced laryngeal cancer from primary surgery to organ preservation options, based on the combination of CRT and salvage surgery<sup>1,2</sup>. The literature evidence, starting from the pioneering works by Veteran's Affairs Cooperative Laryngeal Cancer Study Group and Radiation Therapy Oncology Group (RTOG) 291-11 trials<sup>3,4</sup> has shown that radiotherapy (RT) and CRT are associated with comparable control rates as primary surgery with the additional value of a functional organ preservation rate ranging from 60 to 100%<sup>1,5,6</sup>.

Although partial laryngectomy can be used in selected laryngeal relapses<sup>7</sup>, most patients with persistent/recurrent disease or dysfunctional larynx undergo salvage total laryngectomy (STL)<sup>8</sup>, which is performed in approximately 31-36% of cases following RT and in 16-28% of patients treated with CRT<sup>3,9</sup>. Despite being commonly used, the procedure is characterised by a high risk of post-operative complications, including the common and fearsome pharyngocutaneous fistula (PCF), reported in approximately 30% of cases<sup>7</sup>. Interestingly, several factors have been described to be independently associated with the occurrence of PCF, including chronic obstructive pulmonary disease, low hemoglobin level (< 12.5 g/dL) prior to surgery, need for blood transfusion, advanced primary tumour, supraglottic subsite, hypopharyngeal tumour site, positive surgical margins and the addition of neck dissection<sup>10,11</sup>. Previous RT or CRT are also associated with healing complications and fistula formation: hypoxia resulting from microvascular damage induced by radiation impairs wound healing<sup>12</sup> and chemotherapy exacerbates this effect, producing endarteritis and fibrosis<sup>13</sup>. Notably, the occurrence of complications seems to be higher if STL is performed within the first year after CRT<sup>14</sup>.

Some studies have suggested that the use of well-vascularised, non-irradiated tissue may reverse the negative effects of CRT and prevent the occurrence of PCF. In fact, the flap reconstruction technique has been associated with reduced risk of fistula formation and better tendency to spontaneous healing compared with primary closure following STL<sup>7,14,15</sup>. Moreover, a recent systematic review by Paleri et al. concluded that better functional outcomes are achieved with the introduction of vascularised tissue from outside the irradiated field<sup>6</sup>. This is particularly important considering that the main goals of reconstruction should not be limited to reduce wound complications, but also to maximise post-operative function, mainly swallowing and phonation<sup>16</sup>.

Today, no clear indication exists regarding the type of pharynx reconstruction (primary closure, pedicled flap, or free

flap) should be adopted in various patients<sup>17</sup>, and the different techniques available are chosen on a case-by-case basis, depending on patient's comorbidities, donor site morbidity, availability of technical experts for microvascular anastomosis<sup>14</sup> and the preferences of the surgeon and institution. Pectoralis major myofascial flap (PMMF), first described in 1979<sup>18</sup>, has been the most widely used flap reconstruction technique for several years, but nowadays is being replaced by more popular options, such as the on-lay or patch flap<sup>16</sup>. Tissue transfer, with a variety of donor sites available, is also commonly used in pharyngeal reconstruction after STL<sup>19,20</sup>.

Temporoparietal fascial flap (TPFF) has been suggested as a valuable alternative to the one more commonly used (PMMF) in STL<sup>21</sup>. However, this evidence is reported only by a single study on a limited number of patients and the advantages, limits and functional outcomes of this technique compared with other flaps are still poorly characterised in the current literature. As we recently adopted this alternative technique in our surgical strategy for STL, we aimed to assess the feasibility of TPFF, comparing rates of postoperative PCF and functional outcomes with those of PMMF and primary closure of the pharynx after STL.

## Patients and methods

### *Patients and study characteristics*

In this retrospective study, we collected data on a consecutive series of patients who underwent total laryngectomy for persistent or recurrent laryngeal squamous cell carcinoma (SCC) after RT/CRT with curative intent at IRCCS "Regina Elena" National Cancer Institute, between July 2010 and January 2018. The study was approved by the Institutional Ethic Committee (RS1167/18). No other inclusion criteria were applied, while exclusion criteria were primary laryngectomy (no previous RT/CRT), any kind of partial or circumferential resection of the hypopharynx and use of any other flap than PMMF or TPFF.

Patients were divided into three groups according to pharynx closure; namely primary closure without vascularised tissue augmentation (group 1), primary closure and PMMF patch (group 2) and primary closure and TPFF patch (group 3).

After the surgical reconstruction, a nasogastric tube (NGT) was used in all patients until oral diet intake was restored. Broad spectrum antibiotic therapy was also administered to all patients postoperatively. We did not proceed directly with tracheoesophageal puncture (TEP) in any case, but all patients were followed by a professional teacher of oesophageal voice technique.

### *Surgical technique of TPDF flap harvesting*

TPDF is based on the superficial temporal artery (STA) and vein. The vascular pedicle is usually checked and marked preoperatively using a portable colour flow Doppler. Digital palpation to feel superficial vascular pulsation can help for a continuous check during incision and dissection. The STA usually runs through the retromandibular parotid gland, crosses the posterior root of the zygomatic bone, taking a more superficial course into the fascia at the level of the zygomatic arch<sup>22</sup>, with a mean distance from the tragus of 16 mm<sup>23</sup>. One or two veins usually accompany the STA<sup>22</sup>. A variety of surgical incisions have been described<sup>24</sup>; we prefer the Y-shaped incision, which allows better exposition of the surgical field when harvesting the flap. The incision begins at a pretragal level and ends at the level of the temporal line. It is possible to find the vascular pedicle anteriorly to the surgical skin incision<sup>25</sup>. The dissection proceeds in the subdermal subfollicular plane, superficially to the musculoaponeurotic system. Both incision and dissection are performed rigorously with a cold scalpel technique in order to avoid damage to the vascular pedicle and hair follicles through the electric scalpel. The frontal branch of facial nerve, coursing just under the temporoparietal fascia, is recognised after it crosses the superficial surface of the zygomatic arch<sup>23,24</sup> and spared. Consequently, once the frontal branch of the facial nerve is identified, the anterior incision of the fascia can be made immediately posteriorly to its course. Posterior incision is usually performed posteriorly to the vein, thus avoiding damage to the vascular network, while the superior one is conducted at the level of the temporal line. The deep landmark plane for the surgeon is the temporalis fascia. The detachment of the flap from the deep temporal fascia is started from superior to inferior and conducted through the avascular areolar tissue that separates the two fascial layers. The definitive dimension of the flap is approximately 12 × 10 cm, with a thickness of 2-4 mm (Fig. 1).

Once tracheostomy is harvested and primary closure of the pharynx is completed via a continuous Connel suture, similar to the PMMF technique, the free flap is applied directly over the pharyngeal closure with an on-lay technique, wrapping the pharyngeal mucosa and fixing it to the base of the tongue superiorly, to the prevertebral fascia laterally and to the tracheo-oesophageal septum inferiorly. Anastomosis is usually performed with superior thyroid artery and internal jugular vein with a Prolene 9/0 suture (Ethicon Sàrl, Neuchâtel, Switzerland).

### *Parameters evaluated*

For each patient, sex, age, smoking habit, medical history, postoperative outcomes and postoperative complica-

tions were recorded. Patients were followed for at least 12 months after surgery. Clinical evolution and postoperative complications included total hospital stay; starting soft food oral intake without complications; need for surgical revision; and incidence of PCF and incidence of minor and major complications, such as wound dehiscence, minor and major haemorrhage, haematoma, flap necrosis and donor site morbidity. Patients developing PCF were not considered for time to oral intake recovery analysis.

Presence of comorbidities (vascular and heart diseases, pulmonary diseases or diabetes), pre-treatment clinical staging, dose of radiation received (Gy), the interval from RT/CRT, technique of reconstruction, surgical procedure time, concurrent mono- or bilateral neck dissection, vascular anastomosis time (when free flap was adopted) and pathology report (cancer site, TNM stage group) were registered and analysed as possible risk factors for PCF formation.

Postoperative functional results were also assessed by evaluating swallowing and voice outcomes. Swallowing outcomes at 6 months were routinely evaluated in all patients. The analysis was then elaborated using a 3-point scale in which patients were categorised as: 1) taking nothing by mouth; 2) oral intake with a liquid/soft diet; and 3) oral intake without limitation. Voice outcomes were evaluated through understandability of speech analysis at 6 months using a 5-point scale adopted by the Microvascular Committee of the American Academy of Otolaryngology-Head and Neck Surgery<sup>15</sup>, in which patients were categorised as: 1) never understandable; 2) difficult to understand; 3) usually understandable but may need face-to-face contact; 4) understandable most of the time but may need repetition; and 5) always understandable.

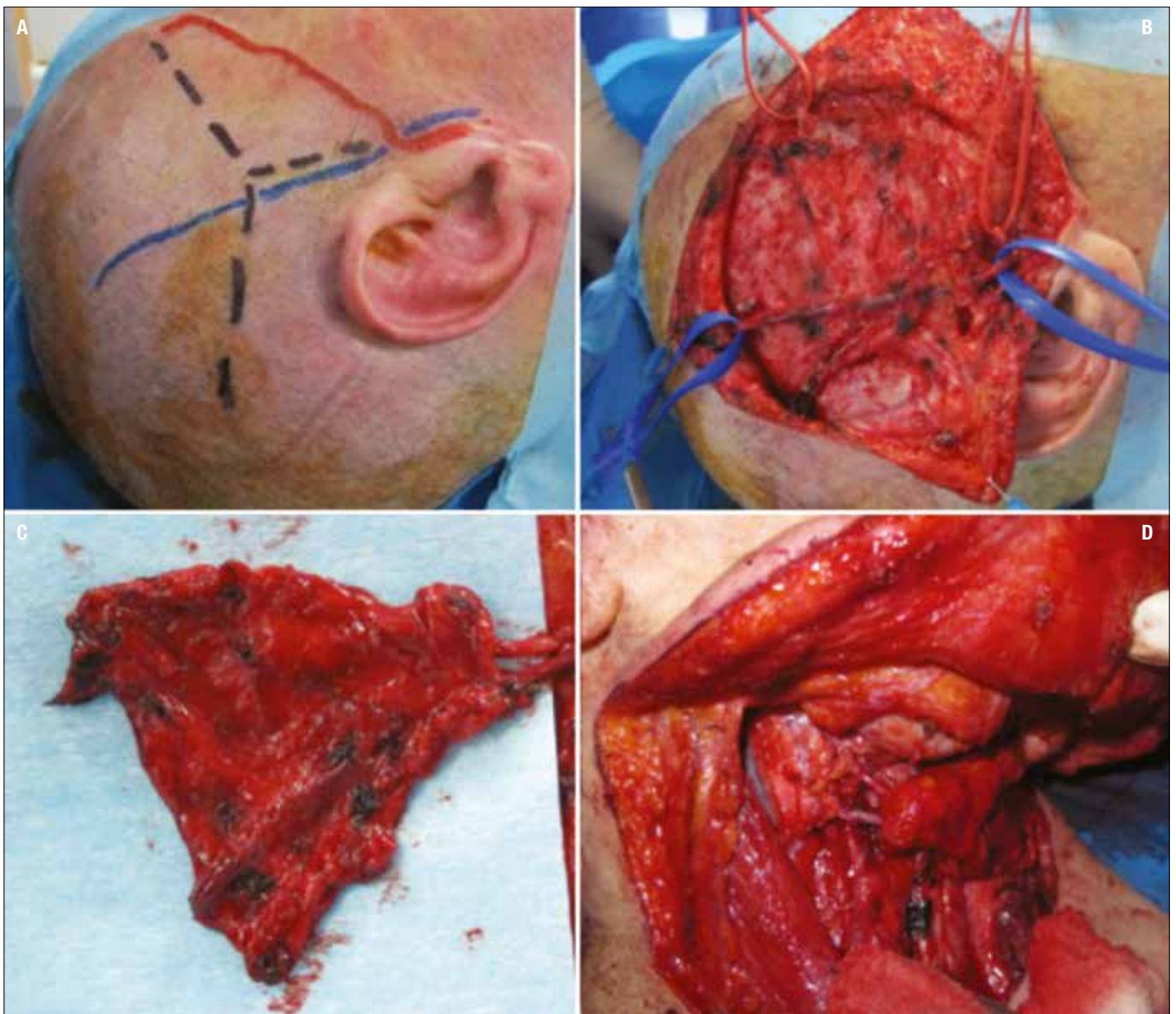
### *Statistical analysis*

Descriptive statistics were used to describe patient characteristics. The association between variables was tested by Pearson Chi-Square test or Fisher's Exact test. The comparison between groups was performed by Mann-Whitney U test or Kruskal-Wallis nonparametric test, when appropriate. A p-value < 0.05 was considered as statistically significant. The SPSS (21.0) statistical programs was used for all analyses.

## **Results**

### *Relapse characteristics*

A total of 39 patients were included in the study, 32 males and seven females with a median age of 67 years (range: 49-86). In total, 28 of 39 patients had at least one co-pathology in past medical history: seven had chronic obstructive



**Figure 1.** TPFF harvesting. **A:** Drawing of superficial course of the STA, collateral vein and Y-shaped cutaneous incision; **B:** identification and isolation of pedicles through subfollicular, supra-superficial musculoaponeurotic system plane dissection; **C:** definitive harvesting of the flap with a usual dimension of 12x10 cm; **D:** microanastomosis with superior thyroid artery and internal jugular vein and on-lay application of the flap over the pharyngeal closure.

pulmonary disease, 20 had vascular or heart disease, and seven had diabetes. A total of 12 patients had more than one disease. Pre-radiotherapeutic treatment clinical T staging was: 6 T1 (3 T1a, 3 T1b), 17 T2, 14 T3 and 2 T4a. Median radiation dose received was 70 Gy (66-70) on T. Pathological staging showed eight cases with an early-stage relapse (rpT1–T2) and 30 patients had an advanced rpT3–T4 lesion, while one patient necessitated total laryngectomy for dysfunctional larynx following chondroradionecrosis. In total, 14 patients received pharyngeal reconstruction through a primary closure (group 1), 11 were treated with

PMMF (group 2) and 14 with TPFF (group 3). The three surgical groups were homogeneous from epidemiological and clinical points of view (age, sex, time from primary treatment to salvage surgery). Overall, 14 patients had previous CRT, while 25 had only RT. Median interval from previous RT/CRT to salvage surgery was 10 months (range: 3-276), with no significant differences among groups. A total of 16 and 22 patients had monolateral and bilateral neck dissection, respectively; only one patient was not subjected to this procedure.

Major features of the three groups are summarised in Table I.

*Post-surgical complications and PCF*

The main clinical outcomes in the three surgical groups are summarised in Table I.

Six patients (15.3%) necessitated surgical revision: three patients in group 1 underwent either PMMF (n = 2) or direct suture (n = 1); two patients in group 2 were treated with a sternocleidomastoid muscle flap (n = 1) or direct suture (n = 1), and one patient in group 3 was revised through a PMMF. Time to wound closure was 45, 28 and 14 days, respectively, in the 3 groups. Only three patients (one for each group) obtained closure through a medical treatment only; the remaining patients underwent surgical revision. Overall, three patients experienced minor complications

(immediate postoperative bleeding) and three patients (two in group 1 and one in group 2) were discharged with a NGT. No major or minor intra- or post-operative complications were noted in the TPF group; in particular, none of the patients in this group experienced alopecia, facial nerve deficit (frontalis branch), or other donor site complications (dehiscence, keloid), nor necessitated flap revision.

Nine of 39 patients (23.1%) experienced a PCF in the post-operative period, 4 (28.6%), 3 (27.3%) and 2 (14.3%) patients, respectively, in the three groups (p = 0.62). None of the potential risk factors considered (age, sex, comorbidity, CRT, radiation dose; mono- or bi-lateral neck dissection) influenced the incidence of PCF. The time interval between

**Table I.** Comparison of baseline characteristics and clinical outcomes between the three surgical groups (primary closure, PMMF, TPF).

	Total	PC; group 1	PMMF; group 2	TPF; group 3	P-value
<b>Patients (n)</b>	39	14	11	14	-
<b>Age, median (range); years</b>	67 (49-86)	68 (51-86)	61 (49-72)	69.5 (61-80)	<b>0.03</b>
<b>Smoking status, n (%)</b>					
Yes	27 (69.2)	11 (78.6)	6 (54.5)	10 (71.4)	0.42
No	12 (30.8)	3 (21.4)	5 (45.5)	4 (28.6)	
<b>Comorbidity, n (%)</b>					
Yes	26 (66.7)	10 (71.4)	6 (54.5)	10 (71.4)	0.60
No	13 (33.3)	4 (28.6)	5 (45.5)	4 (28.6)	
<b>Primary cancer site, n (%)</b>					
Glottic	16 (41.0)	8 (57.1)	1 (9.1)	7 (50.0)	0.15
Glottic-hypoglottic	10 (25.6)	3 (21.4)	3 (27.3)	4 (28.6)	
Glottic-supraglottic	1 (2.6)	0	1 (9.1)	0	
Supraglottic	12 (30.8)	3 (21.4)	6 (54.5)	3 (21.4)	
<b>TNM stage*, n (%)</b>					
T1	2 (5.1)	2 (14.3)	0	0	<b>0.004</b>
T2	6 (15.4)	1 (7.1)	0	5 (35.7)	
T3	12 (30.8)	6 (42.9)	1 (9.1)	5 (35.7)	
T4	18 (46.2)	5 (35.7)	10 (90.9)	3 (21.4)	
<b>Primary to salvage treatment (months), median (range)</b>	10 (3-276)	12.5 (4-276)	11 (3-108)	14 (85-108)	0.95
<b>Neck dissection, n (%)</b>					
None	2 (5.1)	1 (7.1)	0	1 (7.1)	0.16
Monolateral	21 (53.8)	11 (78.6)	6 (54.5)	5 (35.7)	
Bilateral	16 (41.0)	2 (14.3)	5 (45.5)	8 (57.1)	
<b>Surgical time (minutes)</b>	240 (100-440)	187.5 (100-270)	240 (210-300)	309 (200-440)	<b>&lt; 0.0001</b>
<b>Time to oral feeding (days)</b>	20.5 (13-42)	20.5 (16-24)	20 (13-42)	20.5 (13-23)	0.98
<b>Hospitalisation (days)</b>	24 (15-129)	24.5 (18-90)	23 (15-129)	24 (17-39)	0.85
<b>PCF</b>	8 (22.8)	4 (28.6)	3 (27.3)	2 (14.3)	0.62
<b>Nutritional score</b>					
1	2 (5.1)	1 (7.1)	1 (9.1)	0	0.66
2	9 (23.1)	3 (21.4)	3 (27.3)	3 (21.4)	
3	28 (71.8)	10 (71.4)	7 (63.6)	11 (78.6)	
<b>Speech score</b>					
1	3 (7.7)	3 (21.4)	0	0	<b>0.03</b>
2	7 (17.9)	4 (28.6)	3 (27.3)	0	
3	15 (38.5)	4 (28.6)	4 (36.4)	7 (50.0)	
4	14 (35.9)	3 (21.4)	2 (18.2)	6 (42.9)	
5	3 (7.7)	0	2 (18.2)	1 (7.1)	

Values are median (range) or numbers (%). \* One patient in TPF group underwent total laryngectomy for dysfunctional larynx. Bold values represent p-values that are statistically significant.

primary treatment (RT/CRT) and salvage surgery was the only element that was close to being an independent factor for PCF in the entire population ( $p = 0.13$ ), although it did not reach statistical significance (Tab. II).

No statistically significant differences were noted between groups in terms of hospitalisation time ( $p = 0.85$ ) and time to oral feeding ( $p = 0.98$ ), while surgical time varied significantly between the three techniques ( $p < 0.0001$ ) (Tab. II) Postoperative outcomes: swallowing and phonation.

At 6 months from surgery, swallowing outcomes were similar in the three groups ( $p = 0.66$ ) with all patients but two having re-established “per os” feeding and reported “nutritional mode” scores of 2 or 3. Two patients (one in group 1 and one in group 2) remained dependent on a NGT (score 1); both patients were considered frail subjects who did not begin rehabilitation therapy and precociously died due to disease relapse. Two patients in the PMMF group required an esophageal dilatation procedure to resolve solid consistence dysphagia.

Considering speech intelligibility, 35.7% of patients in group 1, 18.1% in group 2 and 42.8% in group 3 reached a score of 4 (understandable most of the time but may need repetition) or 5 (always understandable). Statistical analysis showed a significant difference between the three groups, favoring TPF (p = 0.03). The majority of patients (43.5%), however, were classified as score 3 (usually understandable but may need face-to-face contact).

## Discussion

Our study focused on the use of TPF as a possible alternative to PMMF or other free flaps in reconstructive surgery after STL in patients with recurrent laryngeal cancer.

PMMF is historically the most widely used flap for head and neck reconstruction, with a reported flap necrosis rate of only 2.3%, which makes it possibly the most reliable reconstructive method, even in the setting of STL. Notably, a systematic review by Guimarães reported a decreased incidence of PCF of approximately 22% in 742 patients treated with PMMF<sup>17</sup> compared with primary closure alone. This technique presents several advantages, including easy harvesting and constant and predictable pedicle, robust vascularisation, reduced operative time, abundance of tissue, allows a unique surgical field and does not require a separate reconstructive team or microvascular experience. The richer and more robust vascularisation compared with the peripheral edges of a free flap may also increase the ability to seal off the pharyngotomy<sup>17</sup>. Furthermore, the deep fascia surrounding the pectoralis muscle is rich in hyaluronan, which may have an important role in the earliest stages of wound healing<sup>26</sup>. On the other hand, harvesting a PMMF

**Table II.** Main clinical factors associated with the incidence of PCF.

Patient characteristics	Pharyngocutaneous fistula		P-value
	Yes	No	
<b>Comorbidity</b>			
Yes	5 (17.9)	23 (82.1)	0.24
No	4 (36.4)	7 (63.6)	
<b>Sex</b>			
Male	8 (25)	24 (75)	0.99
Female	1 (14.3)	6 (85.7)	
<b>Neck dissection</b>			
Monolateral	3 (18.8)	13 (81.3)	0.99
Bilateral	5 (22.7)	17 (77.3)	
<b>Prev. treatment</b>			
RT	7 (28)	18 (72)	0.44
RCT	2 (14.3)	12 (85.7)	
<b>RT dose (Gy)</b>	70 (66-70)	70 (60-70)	0.81
<b>Time from RT (months)</b>	6 (3-37)	12 (3-276)	0.13
<b>Age (years)</b>	67 (51-86)	65 (49-86)	0.44

Values are median (range) or numbers (%).

exposes the patients to some implicit and constant consequences, partly due to its bulkiness, and partly to donor site morbidity<sup>27</sup>.

Considering the disadvantages associated with PMMF, in the last years we decided to shift to a free flap procedure, consisting in the use of the temporoparietal fascia (TPF). This fascial layer represents a continuation of the superficial musculoaponeurotic system, is 2-3 mm in thickness and can comprise an area of 17 × 14 cm. This flap is characterised by predictable vascularisation, furnished by the STA and collateral veins; it also receives branches from the deep temporal artery, branch of internal maxillary artery<sup>28</sup>, thus offering rich vascularity, which makes it ideal when a highly vascularised tissue is required in the surgical bed. Moreover, the TPF is characterised by good pliability, and reduced volume and encumbrance, making it a good candidate for reconstruction after STL. The use of TPF as a flap has been reported in a variety of reconstructive settings<sup>29</sup>; however, only a very limited number of case reports have described the use of TPF after STL<sup>29,30</sup>. The largest experience is that reported by Higgins et al., who registered only one failure and two minor complications in 12 patients treated with TPF<sup>21</sup>.

### *Surgical outcomes and PCF occurrence*

In our retrospective study, we reported no major differences in terms of intra- or postoperative surgical complications in patients treated with TPF compared with primary closure or PMMF. Regarding PCF formation, which is the most fearsome complication after STL, we did not find any significant difference between the three groups, even if a

somewhat minor incidence was noted in the TPFf group, where only two patients (14%) developed a PCF (Tab. II). Vascularisation provided by the TPFf can explain the low rate of PCF observed in our series; although, contrary to PMMF, the presence of experts in microsurgical procedures is needed for microvascular anastomosis. Of note, the relative lack of useable vessels for microvascular anastomosis reported in patients previously treated with CRT<sup>31</sup> did not constitute a real contraindication to free flap use in our experience, nor did it lead to a higher incidence of flap failures compared with patients who are not irradiated.

Moreover, none of the patients in the TPFf group experienced donor site morbidity, such as alopecia or frontal branch weakness. Donor site morbidity can be strongly reduced by respecting some critical surgical steps such as the use of cold surgical instruments and bipolar electrocautery, which must be limited to control haemostasis in case of minor bleeding. The damage to frontal branch of facialis nerve can also be avoided by limiting the flap dissection posteriorly to the Pitanguy line which connects a point 0.5 cm below the tragus and 1.5 cm lateral to the superior brow. In order to obtain a much longer length of the vascular pedicle, it is possible to continue the dissection of the temporal vessels downwards along the tragal region. Even with this expedient, the length of TPFf pedicle is quite short, but in the setting of STL this does not represent a real limit.

Our analysis showed a significant difference in operating time between the three groups, with a mean surgical time of 309 minutes for TPFf, compared with 187.5 minutes for primary closure and 240 minutes for PMMF. This difference is consequent to the obvious extension of surgery when a microvascular flap is harvested, but can also be explained by the different incidence of lateral neck dissection in the three groups. In our experience, TPFf harvesting does not allow two surgical teams to work together, contrary to what described by Higgins et al.<sup>21</sup> In spite of this, median extra time compared with PMMF harvesting was only 69 minutes, including a median of 30 minutes spent for vascular anastomoses. This is an acceptable and justified extension of surgical time if accompanied by beneficial effects such as reduction in hospital stay, need for second surgical procedure, or postoperative complications. It could thus be speculated that, even from an economical point of view, the use of the TPFf does not add any expenses compared to the major pectoralis myofascial flap.

In our opinion, TPFf may be associated with minor morbidity even in a hypothetical comparison with other free flaps. Radial forearm free flap (RFFF) has similar tissue qualities with a longer pedicle, although if a skin paddle is harvested the forearm donor site generally requires skin grafting, which can be complicated by tendon exposure

or forearm stiffness<sup>24</sup>. This aspect can be overcome if the RFFF is harvested as a fascial-only flap as described by Fung et al.<sup>19</sup>. Anterolateral thigh flap (ALT) has meaningless donor site morbidity, with the only lasting sequelae represented by a vertically oriented scar along the thigh and thigh numbness<sup>24</sup>. However, we believe that the characteristic thickness of adipose tissue limits its use in STL, as already shown by a randomised study comparing RFFF with ALT<sup>31</sup>. Notably, the results of RFFF and ALT strongly depend on body habitus of the patient, while TPFf has the advantage of being independent of the patient's anatomy. Finally, it should be noted that no flap has shown a significant advantage about PCF formation in the literature. This is consistent with the rationale that any non-irradiated vascularised tissue may be beneficial in aiding wound healing. Therefore, the choice of flap should consider other factors such as performance status, donor site morbidity, functional outcomes and the availability of technical expertise for microvascular anastomosis.

#### *Functional and aesthetic outcomes*

No studies exist on functional responses after TPFf. The recent multicentre study by the Microvascular Committee of the American Academy of Otolaryngology-Head & Neck Surgery<sup>15</sup> clearly showed that vascularised tissue augmentation with muscle leads to worse speech and swallowing function compared to primary closure or vascularised tissue augmentation without muscle. Another study on alternative free flaps concluded that fasciocutaneous free flap guarantees better swallowing functional outcomes and similar rates of postoperative complications compared with PMMF<sup>27</sup>.

Our study showed similar swallowing outcomes between the three groups. Except for two frail patients who never re-established oral intake alimentation, all patients ate by mouth at the 6-month follow-up and only two patients in the PMMF group underwent a procedure of oesophageal dilatation for dysphagia with food with a solid consistency, while none of the patients in the TPFf group required this operation. Empirically, muscle fibrosis and atrophy consequent to denervation and scarring process, can lead to pharyngeal constriction and consequent dysphagia when PMMF is used, while this effect can be insignificant for a thin fascial layer such as that provided by the TPFf.

We report less remarkable outcomes regarding speech intelligibility at 6 months, with few patients reaching a satisfying "speech score" (score 4 or 5) and most patients were classified as group 1 or 3. This can be in part explained by the less reproducible results achieved through oesophageal voice training even with long logopedic rehabilitation. Fung et al. found no difference in voice-related quality of

life between patients treated with primary total laryngectomy and STL with a fascial free flap; this suggests that an additional fascial layer over the pharyngeal closure does not impede the vibratory (pharyngoesophageal) segment<sup>20</sup>. These results are attributed to the pliability and thinness of the flaps applied. Considering that TPF is the thinnest flap described in the human body<sup>29</sup>, characterised by a tissue composition that is associated with good pliability and easy draping without architectural distortion, we could assume that comparable functional results would be achieved. Finally, concerning motility and aesthetical outcomes, TPF can be considered as a less invasive procedure compared with PMMF as long as the correct technique is applied. In fact, PMMF pedicle encumbrance determines unaesthetic bulging in supraclavicular region and in the neck, with possible distortion and stenosis of tracheostomy, making skin closure demanding when the muscle is excessively bulky. Moukarbel et al. also clearly showed a detectable limitation in shoulder and neck function, unavoidably associated with chest deformity, subsequent to PMMF harvesting<sup>32</sup>.

### Limitations

We acknowledge some limitations of our study, including the retrospective nature of the analysis, the limited number of patients and lack of more thorough functional analysis. Despite the modest size of the population, it is important to underline that this is the largest experience reported to date on patients with advanced laryngeal cancer treated with TPF, since this aspect has been only marginally described in literature. Moreover, the retrospective approach is intrinsically linked to the type of study and surgical procedure performed.

### Conclusions

The reinforcement of pharyngeal suture with non-irradiated well vascularised tissue seems to slightly reduce the rate of PCF after STL. The use of TPF as an overlay technique, although increasing the surgical time compared with PMMF, seems to be at least equally efficacious in reducing PCF compared with other techniques. We conclude that TPF is a reliable alternative flap in case of STL, which should also be considered for its minor donor site morbidity and better functional outcomes in selected patients.

### Acknowledgements

Editorial assistance was provided by Ambra Corti, Luca Giacomelli, PhD, and Aashni Shah; this assistance was supported by internal funds.

### References

- Hendriksma M, Heijnen BJ, Sjögren EV. Oncologic and functional outcomes of patients treated with transoral CO2 laser microsurgery or radiotherapy for T2 glottic carcinoma: a systematic review of the literature. *Curr Opin Otolaryngol Head Neck Surg* 2018;26:84-93. <https://doi.org/10.1097/MOO.0000000000000438>
- Iocca O, Farcomeni A, Di Rocco A, et al. Locally advanced squamous cell carcinoma of the head and neck: A systematic review and Bayesian network meta-analysis of the currently available treatment options. *Oral Oncol* 2018;80:40-51. <https://doi.org/10.1016/j.oraloncology.2018.03.001>
- The Department of Veterans Affairs Laryngeal Cancer Study Group. Induction chemotherapy plus radiation compared with surgery plus radiation in patients with advanced laryngeal cancer. *N Engl J Med* 1991;324:1685-90. <https://doi.org/10.1056/NEJM199106133242402>
- Forastiere AA, Goepfert H, Maor M, et al. Concurrent chemotherapy and radiotherapy for organ preservation in advanced laryngeal cancer. *N Engl J Med* 2003;349:2091-8. <https://doi.org/10.1056/NEJMoa031317>
- Sheahan P. Management of advanced laryngeal cancer. *Rambam Maimonides Med J* 2014;5:e0015. <https://doi.org/10.5041/RMMJ.10149>
- Paleri V, Drinnan M, van den Brekel, et al. Vascularized tissue to reduce fistula following salvage total laryngectomy: a systematic review. *Laryngoscope* 2014;124:1848-53. <https://doi.org/10.1002/lary.24619>
- Pellini R, Pichi B, Ruscito P, et al. Supracricoid partial laryngectomies after radiation failure: a multi-institutional series. *Head Neck* 2008;30:372-9. <https://doi.org/10.1002/hed.20709>
- Spriano G, Mercante G, Manciocco V, et al. A new lateral cervical approach for salvage total laryngo-pharyngectomy. *Acta Otorhinolaryngol Ital* 2019;39:61-4. <https://doi.org/10.14639/0392-100X-1753>
- Weber RS, Berkey BA, Forastiere A, et al. Outcome of salvage total laryngectomy following organ preservation therapy: the Radiation Therapy Oncology Group trial 91-11. *Arch Otolaryngol Head Neck Surg* 2003;129:44-9. <https://doi.org/10.1001/archotol.129.1.44>
- Dedivitis RA, Aires FT, Cernea CR, et al. Pharyngocutaneous fistula after total laryngectomy: systematic review of risk factors. *Head Neck* 2015;37:1691-7. <https://doi.org/10.1002/hed.23804>
- Aires FT, Dedivitis RA, Kulcsar MAV, et al. Neutrophil-to-lymphocyte ratio as a prognostic factor for pharyngocutaneous fistula after total laryngectomy. *Acta Otorhinolaryngol Ital* 2018;38:31-7. <https://doi.org/10.14639/0392-100X-1572>
- Pellini R, Mercante G, Marchese C. et al. Predictive factors for post-operative wound complications after neck dissection. *Acta Otorhinolaryngol Ital* 2013;33:16-22.
- Gao Q, Zhou G, Lin SJ, et al. How chemotherapy and radiotherapy damage the tissue: Comparative biology lessons from feather and hair models. *Exp Dermatol* 2019;28:413-8. <https://doi.org/10.1111/exd.13846>
- Sayles M, Grant DG. Preventing pharyngo-cutaneous fistula in total laryngectomy: a systematic review and meta-analysis. *Laryngoscope* 2014;124:1150-63. <https://doi.org/10.1002/lary.24448>
- Microvascular Committee of the American Academy of Otolaryngology-Head & Neck Surgery. Salvage laryngectomy and laryngopharyngectomy: Multicenter review of outcomes associated with a reconstructive approach. *Head Neck* 2019;41:16-29. <https://doi.org/10.1002/hed.25192>
- Yeh DH, Sahovaler A, Fung K. Reconstruction after salvage laryngectomy. *Oral Oncol* 2017;75:22-7. <https://doi.org/10.1016/j.oraloncology.2017.10.009>



- <sup>17</sup> Guimarães AV, Aires FT, Dedivitis RA, et al. Efficacy of pectoralis major muscle flap for pharyngocutaneous fistula prevention in salvage total laryngectomy: A systematic review. *Head Neck* 2016;38 (Suppl 1):E2317-21. <https://doi.org/10.1002/hed.24248>
- <sup>18</sup> Ariyan S. The pectoralis major myocutaneous flap. A versatile flap for reconstruction in the head and neck. *Plast Reconstr Surg* 1979;63:73-81. <https://doi.org/10.1097/00006534-197901000-00012>
- <sup>19</sup> Fung K, Teknos TN, Vandenberg CD, et al. Prevention of wound complications following salvage laryngectomy using free vascularized tissue. *Head Neck* 2007;29:425-30. <https://doi.org/10.1002/hed.20492>
- <sup>20</sup> Patel UA, Keni SP. Pectoralis myofascial flap during salvage laryngectomy prevents pharyngocutaneous fistula. *Otolaryngol Head Neck Surg* 2009;141:190-5. <https://doi.org/10.1016/j.otohns.2009.03.024>
- <sup>21</sup> Higgins KM, Ashford B, Erovcic BM, et al. Temporoparietal fascia free flap for pharyngeal coverage after salvage total laryngectomy. *Laryngoscope* 2012;122:523-7. <https://doi.org/10.1002/lary.22477>
- <sup>22</sup> Moore KL, Dalley AF. *Clinically Oriented Anatomy*. Fifth edition. Baltimore: Lippincott Williams and Wilkins; 2006. pp. 788-798.
- <sup>23</sup> Casoli V, Dauphin N, Taki C, et al. Anatomy and blood supply of the subgaleal flap. *Clin Anat* 2004;17:392-399. <https://doi.org/10.1002/ca.10243>
- <sup>24</sup> Olson KL, Manolidis S. The pedicled superficial fascial flap: a new method for reconstruction in otologic surgery. *Otolaryngol Head Neck Surg* 2002;126:538-47. <https://doi.org/10.1067/mhn.2002.125114>
- <sup>25</sup> Urken ML, Cheney ML, Sullivan MJ, et al. Atlas of regional and free flaps in head and neck reconstruction. New York: Raven Press; 1994. p. 379.
- <sup>26</sup> Pellini R, Pichi B, Marchesi P, et al. External monitor for buried free flaps in head and neck reconstructions. *Acta Otorhinolaryngol Ital* 2006;26:1-6.
- <sup>27</sup> Nguyen S, Thuot F. Functional outcomes of fasciocutaneous free flap and pectoralis major flap for salvage total laryngectomy. *Head Neck* 2017;39:1797-805. <https://doi.org/10.1002/hed.24837>
- <sup>28</sup> Acland R, Abul-Hasan H, Ulfe E. Superficial and deep temporal fascia flap: an anatomic approach. Videotape presentation at the Annual Meeting of the American Society of Plastic and Reconstructive Surgeons. Las Vegas, Nevada, October 12, 1983.
- <sup>29</sup> Collar RM, Zopf D, Brown D, et al. The versatility of the temporoparietal fascia flap in head and neck reconstruction. *J Plast Reconstr Aesthet Surg* 2012;65:141-8. <https://doi.org/10.1016/j.bjps.2011.05.003>
- <sup>30</sup> Fabrizio T, Donati V, Nava M. Repair of the pharyngocutaneous fistula with a fasciocutaneous island flap pedicled on the superficial temporalis artery. *Plast Reconstr Surg* 2000;106:1573-6. <https://doi.org/10.1097/00006534-200012000-00020>
- <sup>31</sup> Morrissey AT, O'Connell DA, Garg S, et al. Radial forearm versus anterolateral thigh free flaps for laryngopharyngectomy defects: prospective, randomized trial. *J Otolaryngol Head Neck Surg* 2010;39:448-53.
- <sup>32</sup> Moukarbel RV, Fung K, Franklin JH, et al. Neck and shoulder disability following reconstruction with the pectoralis major pedicled flap. *Laryngoscope* 2010;120:1129-34. <https://doi.org/10.1002/lary.20900>