

Urgent endovascular maneuvers to rescue a failing transplant kidney with a T-stent approach

Astrid Sofia Cavenaghi, MD,^a Antonio Cappiello, MD,^a Rodolfo Pini, MD, PhD, FEBVS,^{a,b} Gianluca Faggioli, MD, PhD,^{a,b} Gaetano La Manna, MD, PhD,^{b,c} and Mauro Gargiulo, MD, PhD,^{a,b} Bologna, Italy

ABSTRACT

Renal artery thrombosis (RAT) is a major cause of renal transplant loss and, for this reason, should be treated promptly. We present a case of a 48-year-old man with external iliac thrombosis associated with thrombosis of a transplant renal artery that led to worsening of renal function. Multiple mechanisms have been identified in the literature as risk factors for RAT. In our patient, a combination of anastomotic stenosis, hypercoagulability, and diabetic nephropathy had resulted in RAT, and an unconventional endovascular revascularization technique with a T-stent approach was needed to guarantee patency of the treated vessels. No 30-day perioperative complications occurred, and the postoperative follow-up examination showed patency of the treated vessels; thus, transplant loss was avoided. (*J Vasc Surg Cases Innov Tech* 2023;9:1-5.)

Keywords: Drug-eluting stent; Endovascular recanalization; Iliac artery stenting; Iliac artery thrombosis; Kidney injury; Renal artery stenting; Renal artery thrombosis; Renal transplantation; Thromboaspiration

Renal transplantation is the most effective of the renal replacement therapies, with significant advantages compared with dialysis.^{1,2} After the introduction of effective immunosuppression, the causes of graft loss were brought to the forefront.³ At present, two of the main causes of transplant loss are high-grade stenosis of the renal artery and thrombosis.^{4,5} Renal artery stenosis can afflict $\leq 20\%$ of transplanted kidneys. In contrast, renal artery thrombosis (RAT) is a rare event, affecting 0.5% to 3.5%. It can cause a sudden reduction in urine output and, if left untreated or not promptly treated, can lead to hemodialysis, which will result in a life expectancy reduction. Graft loss will lead to the additional necessity of a new kidney transplant for patients who have already undergone abdominal surgery, with a higher surgical risk.⁶ Thrombosis of a transplant renal artery is listed as one of the immediate vascular complications and is a

major cause of graft loss in the early post-transplant period.^{7,8} Thus, to minimize the morbidity and mortality due to graft failure, appropriate and timely treatment is crucial. Several methods are available to treat RAT, including surgical thrombectomy with correction of the stenosis, thrombus aspiration, and percutaneous balloon angioplasty (either plain or stent assisted).

We present a case of symptomatic RAT associated with asymptomatic ipsilateral external iliac thrombosis treated with thrombus aspiration and stenting. The patient provided written informed consent for the report of his case details and imaging studies, including data processing for scientific aims.

CASE REPORT

Patient presentation. A 48-year-old male patient with hypertension, metabolic syndrome, type 2 diabetes mellitus requiring insulin therapy complicated by chronic kidney failure, and liver cirrhosis complicated by hepatocellular carcinoma underwent hepatorenal transplantation. He was discharged after 28 days with a serum creatinine of 1.04 mg/d and an estimated glomerular filtration rate (eGFR) of 85 mL/min. A postoperative duplex ultrasound scan showed an average renal artery index resistance of 0.65 and symmetric and uniform renal perfusion.

At 2 months after the transplant, the patient developed urosepsis, which was treated with intravenous antibiotic therapy. He was discharged with a serum creatinine of 1.4 mg/dL and an eGFR of 63 mL/min. The right iliac axis had a regular caliber with no stenosis before or after the renal transplant anastomosis, as shown on the pre- and post-transplant computed tomography angiography (CTA) scan.

He presented to our vascular surgery unit 4 months after transplantation because of a sudden deterioration of renal function detected via his follow-up blood test. The patient had a serum

From the Vascular Surgery University of Bologna DIMEC^a; the Vascular Surgery Unit, IRCCS, University Hospital Policlinico S.Orsola^b; and the Nephrology, Dialysis and Renal Transplant Unit, IRCCS-Azienda Ospedaliero-Universitaria di Bologna, Alma Mater Studiorum University of Bologna.^c

Author conflict of interest: none.

Correspondence: Antonio Cappiello, MD, Department of Experimental, Diagnostic and Specialty Medicine, Vascular II Surgery Unit, IRCCS University Hospital, Policlinico Sant'Orsola-Malpighi, Bologna, Italy (e-mail: antonio.cappiello2@studio.unibo.it).

The editors and reviewers of this article have no relevant financial relationships to disclose per the Journal policy that requires reviewers to decline review of any manuscript for which they may have a conflict of interest.

2468-4287

© 2023 The Authors. Published by Elsevier Inc. on behalf of Society for Vascular Surgery. This is an open access article under the CC BY-NC-ND license (<http://creativecommons.org/licenses/by-nc-nd/4.0/>).

<https://doi.org/10.1016/j.jvscit.2023.101168>

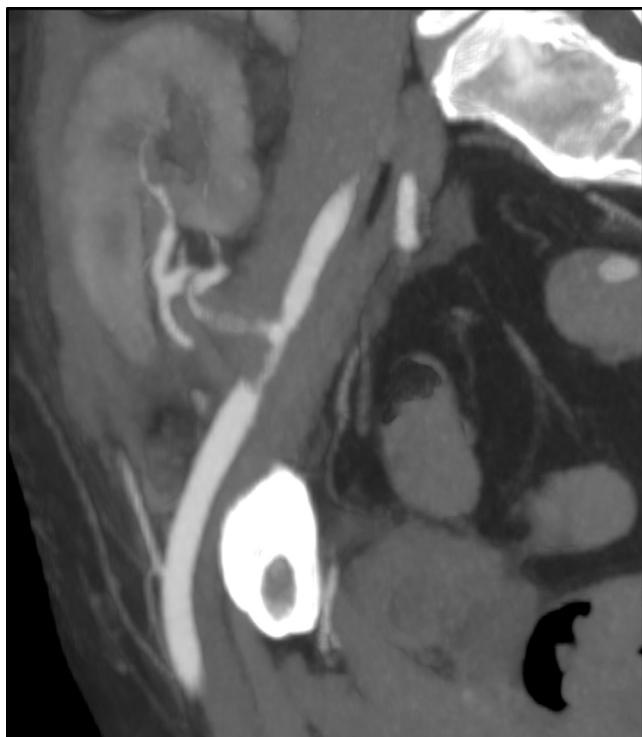

Fig 1. Preoperative computed tomography angiogram showing partial thrombosis of the right external iliac artery and transplant renal artery.

creatinine of 3.6 mg/dL, eGFR of 19 mL/min, and preserved diuresis (chronic kidney disease stage 4), without the necessity for dialysis. Hemodialysis was performed only before and after the use of iodine contrast medium to prevent a worsening of his renal function.

The absence of right lower limb pulses and severe claudication were detected at the physical examination 4 days before the blood tests. An ultrasound study highlighted partial thrombosis of both the right external iliac artery and the transplanted renal artery. Moreover, the peak systolic velocity (PSV) had decreased from 120 cm/s before the stenosis to 30 cm/s in the distal part of the transplanted renal artery, with a monophasic waveform. The average PSV was 40 cm/s, with a monophasic waveform in the right lower extremity axis. The average PSV was 120 cm/s, with a triphasic waveform in the left lower extremity axis. A CTA scan (Fig 1) confirmed the presence of thrombosis occluding 70% of the right external iliac artery and 80% of the transplanted renal artery, with a longitudinal extent of 23 mm. The patient was treated with endovascular thromboaspiration of both the right external iliac artery and the transplanted renal artery, with stenting of both vessels.

Surgical technique. Because of his worsening renal function, the patient was treated urgently. The surgical procedure

was performed with the patient under general anesthesia with surgical exposure of the right common femoral artery. Access was obtained by retrograde puncture of the common femoral artery, using a 10F introducer (Cordis, Santa Clara, CA). The preoperative angiogram confirmed partial thrombosis of both the right external iliac artery and the transplanted right renal artery (Fig 2, A). With an Indigo System CAT8 (Penumbra, Alameda, CA), thromboaspirations in the right external iliac artery and transplanted renal artery were performed (Fig 2, B). Selective angiography in the kidney showed the presence of thrombus also in the segmental renal arteries, and an Indigo System CAT6 (Penumbra) was used to perform thromboaspiration (Fig 2, C).

The intraoperative angiogram showed complete recanalization of the treated vessels but also highlighted the presence of external iliac artery and proximal renal artery stenosis. To achieve a good angiographic result and avoid stenting of the transplant renal artery, we performed transplant renal artery angioplasty with a drug-eluting balloon (4 × 40 mm; Lutonix, Maple Grove, MN).

Because of the persistence of the stenosis (Figs 2, D, and 3, A), an uncovered self-expandable Zilver stent (9 × 60 mm; Cook Medical Inc, Bloomington, IN) was positioned in the external iliac artery at the turn of the anastomosis with the renal artery (Fig 3, B). We chose this stent because it is an open cell stent, which allows for passage of guidewires and endovascular materials. We chose the 9-mm diameter for the right oversizing. Postdilation with a semi-compliant Armada balloon (7 × 40 mm; Boston Scientific, Marlborough, MA, USA) was performed to guarantee optimal stent expansion. The diameter was chosen to avoid overdilation of the stent in a 7.5-mm diameter artery.

For cannulation of the renal artery, a Vansche-3 catheter (Cook Medical Inc) and a Command ES 0.014-in. guidewire (Abbott Laboratories, Chicago, IL) were used to pass through the cells of the external iliac artery stent. Predilation of the renal artery was performed with a semi-compliant Armada balloon (3 × 40 mm; Boston Scientific). Next, we proceeded with the stenting using an uncovered, self-expandable, drug-eluting stent (Onyx, 5 × 18 mm; Medtronic, Minneapolis, MN; Fig 3, C). We chose this stent because of its conformability, flexibility, and adaptability in curves and to prevent anastomotic restenosis.

The final angiogram showed the success of the procedure, patency of both the external iliac artery and the transplanted renal artery, and the absence of residual stenosis or thrombosis (Fig 3, D). The postoperative course was free of complications, and the patient was moved after 2 days to the nephrology department with a prescription for double antiplatelet therapy for ≥6 months and single antiplatelet therapy as lifetime therapy.

At 1 month after discharge, an ultrasound scan showed a PSV of 150 cm/s with a biphasic waveform and low-resistance pattern in the renal stent, a PSV of 140 cm/s with a triphasic

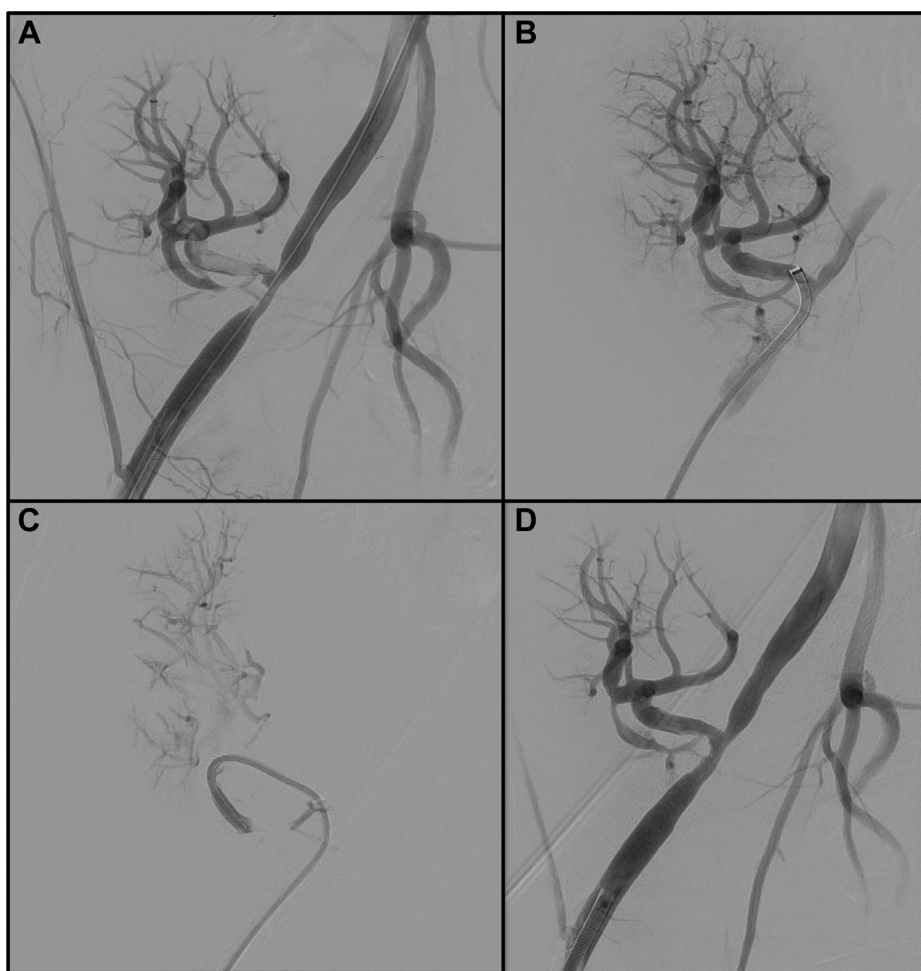


Fig 2. Endovascular thromboaspiration procedure. **A,** Preoperative angiogram. **B,** Angiogram showing thromboaspiration of the main trunk of the transplant renal artery. **C,** Angiogram showing thromboaspiration of a distal branch of the transplant renal artery. **D,** Completion angiogram after thromboaspiration.

waveform in the iliac stent, and a PSV of 120 cm/s with a triphasic waveform in the external iliac artery before and after the stent. CTA highlighted the patency of the treated vessels without residual stenosis (Fig 4). The patient was discharged after 2 months with a serum creatinine of 1.17 mg/dL and an eGFR of 73 mL/min, with all peripheral pulses present and claudication absent.

DISCUSSION

Treatment of RAT has been described mostly in case reports and case series, and the most common surgical interventions are the endovascular approach and thrombectomy. Reanastomosis is an option in rare cases such as early post-transplant thrombosis. The restenosis rate was reported by Douis et al⁹ in 2008. However, multiple case series and reviews have described the effectiveness of percutaneous transluminal angioplasty

stenting, especially if a drug-eluting stent were used.⁴ The present case represents a rare event of transplant RAT combined with external iliac artery thrombosis.

We used an unconventional endovascular recanalization technique that required passage of the material through the cells of an uncovered iliac stent to position a drug-eluting stent in the transplant renal artery. To increase the possibility of passing through the stent's cells, we used an open cell stent, a catheter with an angulated tip design, and a 0.014-in. guidewire to create a bifurcated stent.

This technique is rarely used in vascular surgery and was previously described by Manunga¹⁰ and Manunga and Oderich¹¹ for patients with chronic mesenteric ischemia with unusual anatomy. A similar technique, called the T-stent approach, is used in endovascular myocardial revascularization.¹²

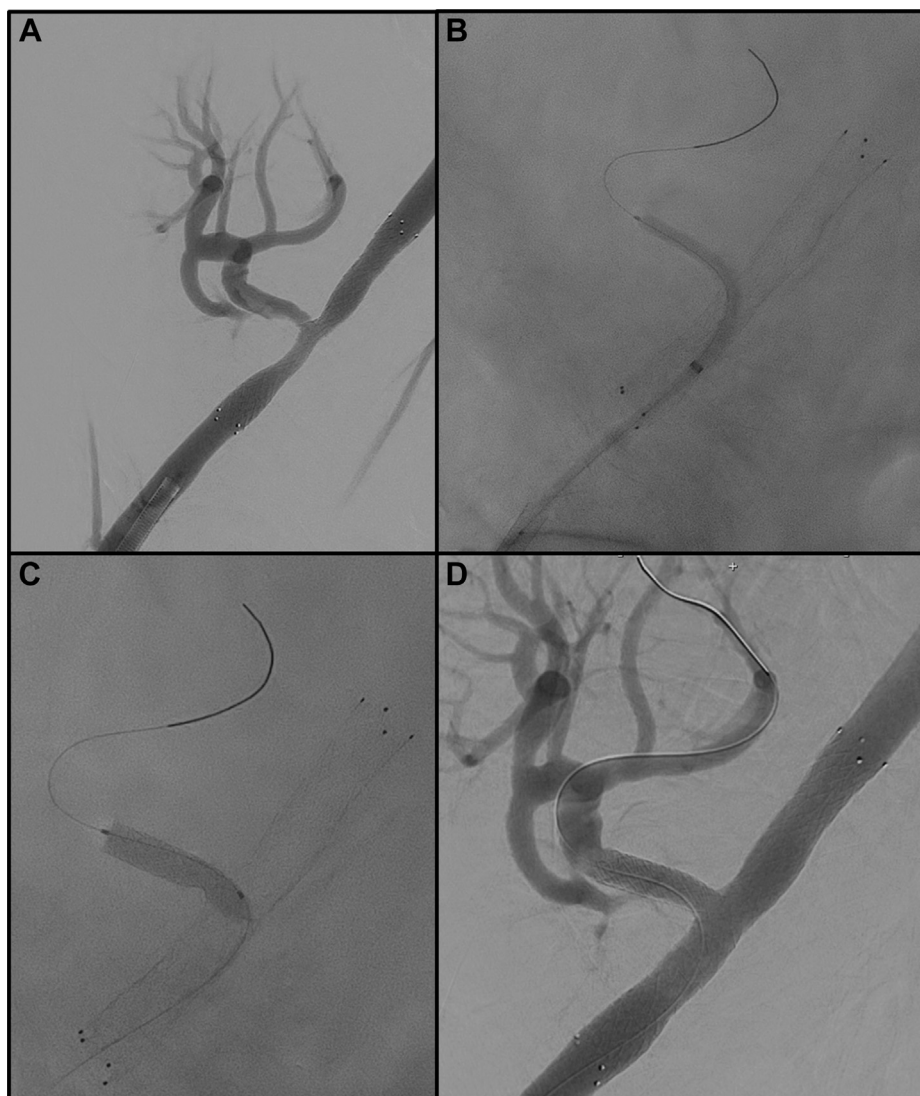

Fig 3. Stenting procedure. **A**, Angiogram showing right external iliac artery stenting. **B**, Angiogram showing predilation of transplant renal artery. **C**, Angiogram showing transplant renal artery stenting. **D**, Postoperative angiogram.

Vascular complications after renal transplantation are the most critical complications with a very high risk of graft loss. Of these, RAT is the most significant, although rare, with a reported incidence of $\leq 4\%$, and can lead to sudden graft loss.^{6,13,14} As Bakir et al¹⁵ highlighted in their study, there are five independent risk factors for RAT, including the use of the donor's right kidney, a history of venous thrombosis in the recipient, problems with the surgical technique, diabetic nephropathy, and the perioperative hemodynamic status of the recipient.¹⁵ In our clinical case, specifically, this mid-term complication of RAT can be ascribed

to a combination of diabetic nephropathy, hypercoagulability due to previous urosepsis,¹⁶ and anastomotic stenosis.

Because of the patient's frailty, previous abdominal surgery, and the presence of an abdominal scar, we opted for an endovascular approach for stenting of both the right external iliac artery and the transplant renal artery to guarantee the long-term patency of the arteries. Moreover, to avoid reintervention through scar tissue, in our clinical practice, we prefer an endovascular approach when the thrombosis has occurred ≥ 3 months after the kidney transplant date.

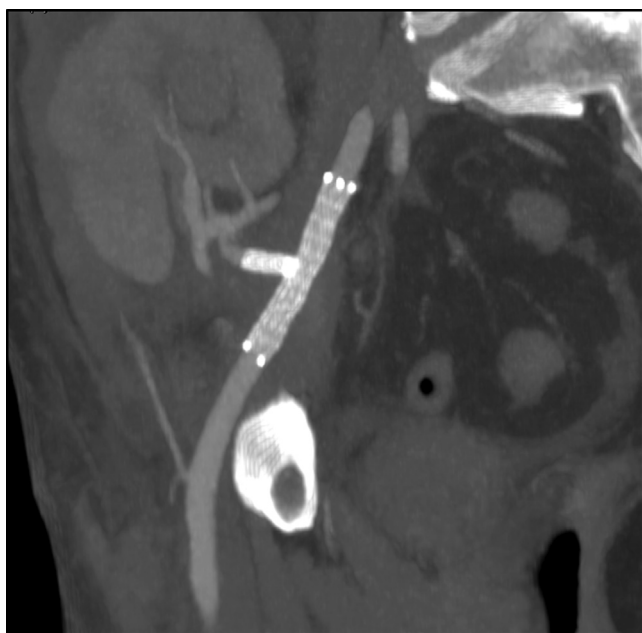


Fig 4. Postoperative computed tomography angiogram showing complete resolution of the thrombosis of the right external iliac artery and transplant renal artery.

CONCLUSIONS

Transplant RAT is a rare complication of renal transplantation, needing timely revascularization to avoid graft loss. If the endovascular approach is preferred, it should restore complete patency of the vessel, without residual stenosis, which could trigger a new thrombotic event.

REFERENCES

1. Schnuelle P, Lorenz D, Trede M, Van Der Woude FJ. Impact of renal cadaveric transplantation on survival in end-stage renal failure: evidence for reduced mortality risk compared with hemodialysis during long-term follow-up. *J Am Soc Nephrol* 1998;9:2135-41.

2. Wong C, Howard K, Chapman JR, Chadban S, Cross N, Tong A, et al. Comparative survival and economic benefits of deceased donor kidney transplantation and dialysis in people with varying ages and co-morbidities. *PLoS One* 2012;7:e29591.
3. Hariharan S, Johnson CP, Bresnahan BA, Taranto SE, McIntosh MJ, Stablein D. Improved graft survival after renal transplantation in the United States, 1988 to 1996. *N Engl J Med* 2000;342:605-12.
4. Pini A, Faggioli G, Pini R, Mauro R, Gallitto E, Mascoli C, et al. Assessment and management of transplant renal artery stenosis. A literature review. *Ann Vasc Surg* 2022;82:13-29.
5. Singh G, Jolly N. Peripheral vascular disease involving transplant renal artery. *J Invasive Cardiol* 2021;33:E798-804.
6. Srivastava A, Kumar J, Sharma S, Abhishek, Ansari MS, Kapoor R. Vascular complication in live related renal transplant: an experience of 1945 cases. *Indian J Urol* 2013;29:42-7.
7. Fernández-Nájera JE, Beltrán S, Aparicio M, Molina P, Gavela E, Avila A, et al. Transplant renal artery stenosis: association with acute vascular rejection. *Transpl Proc* 2006;38:2404-5.
8. Tavakkoli M, Zafarghandi RM, Taghavi R, Ghoreifi A, Zafarghandi MM. Immediate vascular complications after kidney transplant: experience from 2100 recipients. *Exp Clin Transpl* 2017;15:504-8.
9. Douis H, Shabir S, Lipkin G, Riley P. Drug-eluting stent insertion in the treatment of in-stent renal artery restenosis in three renal transplant recipients. *J Vasc Interv Radiol* 2008;19:1757-60.
10. Manunga J. Bifurcated stent technique: a Viable option for treatment of patients with unusual anatomy presenting with combined chronic mesenteric ischemia and diffuse ischemic gastric ulcers. *Vasc Endovascular Surg* 2018;52:66-9.
11. Manunga JM, Oderich GS. Orbital atherectomy as an adjunct to debulk difficult calcified lesions prior to mesenteric artery stenting. *J Endovasc Ther* 2012;19:489-94.
12. Hildick-Smith D, Behan MW, Lassen JF, Chieffo A, Lefèvre T, Stankovic G, et al. The EBC TWO study (European bifurcation Coronary TWO): a randomized comparison of provisional T-stenting versus a systematic 2 stent culotte strategy in large caliber true bifurcations. *Circ Cardiovasc Interv* 2016;9:e003643.
13. Ponticelli C, Moia M, Montagnino G. Renal allograft thrombosis. *Nephrol Dial Transpl* 2009;24:1388-93.
14. Zilinska Z, Chrastina M, Trebaticky B, Breza Jr, Slobodnik L, Breza J, et al. Vascular complications after renal transplantation. *Bratisl Lek Listy* 2010;111:586-9.
15. Bakir N, Sluiter WJ, Ploeg RJ, van Son WJ, Tegzess AM. Primary renal graft thrombosis. *Nephrol Dial Transpl* 1996;11:140-7.
16. Guliciuc M, Maier AC, Maier IM, Kraft A, Cucuruzac RR, Marinescu M, et al. The urosepsis-a literature review. *Medicina (Kaunas)* 2021;57:872.

Submitted Nov 24, 2022; accepted Mar 2, 2023.