Technical pitfalls and proposed modifications of instructions for use for endovascular aortic aneurysm repair using the Gore Excluder conformable device in angulated and short landing zones

Andrea Vacirca, MD, PhD,[a,b] Titia A. L. Sulzer, BSc,[a,c] Thomas Mesnard, MD,[a] Aidin Baghbani-Oskouei, MD,[a] Laura Ocasio, MD,[a] Thanila A. Macedo, MD,[a] Hence J. M. Verhagen, MD, PhD,[c] Robert Rhee, MD,[d] *and* Gustavo S. Oderich, MD,[a] *Houston, TX; Bologna, Italy; Rotterdam, The Netherlands; and Brooklyn, NY*

ABSTRACT

We describe a case of an abdominal aortic aneurysm (AAA) and angulated proximal neck treated with a Gore Excluder conformable endoprosthesis and show relevant technical pitfalls in the deployment of the graft main body. An 82-year-old man presented with a 71-mm asymptomatic AAA with an angulated infrarenal proximal neck (75°) and was referred to our unit. The patient was treated with a 26-mm Gore Excluder conformable device, which was deployed slightly above the renal arteries after precatheterization of the lowest renal artery. The graft was then repositioned with support of the introducer sheath and a stiff guide wire. The proximal sealing zone was ballooned before the endograft delivery system was retrieved to avoid distal migration. Technical success was achieved. The patient was discharged with no complications. No type Ia endoleak was present on the 6-month computed tomography scan. Endovascular treatment of an AAA with a severe angulated proximal neck can be effective with a conformable stent graft if technical measures are used during deployment of the main body to optimize the seal. (J Vasc Surg Cases Innov Tech 2023;9:101339.)

Keywords: Abdominal aortic aneurysm; Angulated proximal neck; Endovascular aortic repair

Endovascular aneurysm repair (EVAR) is the treatment of choice for infrarenal abdominal aortic aneurysms (AAAs) in patients with suitable anatomy due to the low perioperative morbidity and mortality compared with open surgical repair.[1] Nevertheless, a severely angulated proximal neck (>60°-90°) still represents a serious challenge for stent graft apposition and deployment, increasing the risks of type Ia endoleaks and secondary interventions.[2-6]

The Gore Excluder Conformable stent graft (WL Gore & Associates) has been designed with proximal active control for optimization of stent graft apposition and repositioning in tortuous and angulated segments.[7-9] The ability to bend and/or reposition the stent graft can extend the indications to patients with severely angulated proximal necks.[10-13] However, the initial investigators' experience with the proposed instructions for use (IFU) revealed significant challenges due to risk of malposition and dislodgement of the stent graft in angulated segments. The aim of this case report is to illustrate a step-by-step modification of the proposed IFU for Gore Excluder Conformable stent graft deployment in a patient with a severely angulated proximal neck. The patient provided written informed consent for the report his case details and imaging studies.

CASE REPORT

An 82-year-old male patient presented with an enlarging 7.1-cm asymptomatic AAA. His medical history included hypertension, glaucoma, and urinary retention due to benign prostatic hypertrophy. Preoperative computed tomography angiography confirmed a 7.1-cm infrarenal aortic aneurysm (Fig 1) with 20-mm and 15-mm proximal sealing zone diameter and length, respectively, and 50° suprarenal and 75° infrarenal neck angulation. No evidence of thrombus was found, with minimal calcification present. Both common iliac arteries were tortuous but had adequate length and diameter sealing zones.

From the Department of Cardiothoracic and Vascular Surgery, Advanced Aortic Research Program, The University of Texas Health Science Center at Houston, McGovern Medical School, Houston[a]; the Vascular Surgery, Department of Medical and Surgical Sciences, University of Bologna, Bologna[b]; the Department of Vascular Surgery, Erasmus Medical Center, Rotterdam[c]; and the Division of Vascular and Endovascular Surgery, Maimonides Medical Center, Brooklyn.[d]

A.V. and T.A.L.S. share first authorship.

Additional material for this article may be found online at https://www.jvscit.org.

Correspondence: Gustavo S. Oderich, MD, Department of Cardiothoracic and Vascular Surgery, Advanced Aortic Research Program, The University of Texas Health Science Center at Houston, McGovern Medical School, 6400 Fannin St, Ste 2850, Memorial Hermann Medical Plaza, Houston, TX 77030 (e-mail: gustavo.oderich@uth.tmc.edu).

The editors and reviewers of this article have no relevant financial relationships to disclose per the Journal policy that requires reviewers to decline review of any manuscript for which they may have a conflict of interest.

2468-4287

© 2023 Published by Elsevier Inc. on behalf of Society for Vascular Surgery. This is an open access article under the CC BY-NC-ND license (http://creativecommons.org/licenses/by-nc-nd/4.0/).

https://doi.org/10.1016/j.jvscit.2023.101339

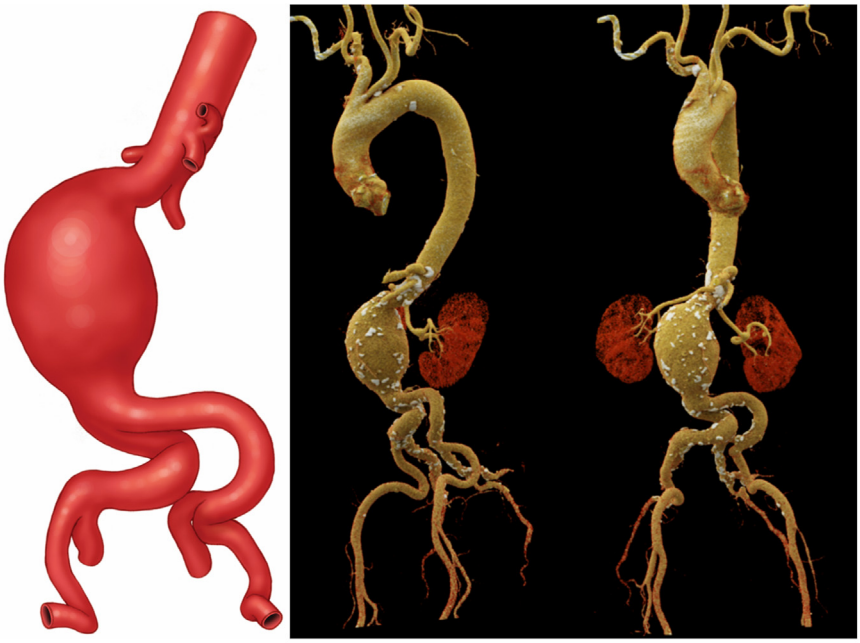

Fig 1. Illustration and three-dimensional model based on preoperative computed tomography angiography.

Despite the infrarenal neck angulation exceeding 60° in the approved IFU, we recommended EVAR using a Gore Excluder Conformable device with an off-label indication.

Surgical technique. The procedure was performed in a hybrid room using the Allia IGS system (GE Healthcare), and the patient underwent general endotracheal anesthesia (Supplementary Video 1, online only). Bilateral percutaneous transfemoral access with a preclosure technique was established. Cook Lunderquist extra stiff 0.035-in. guide wires (Cook Medical Inc) were positioned in the thoracic aorta in modification of the original Terumo Advantage wires (Terumo Interventional Systems) used in the initial experience. Bilateral 16F DrySeal sheaths (WL Gore & Associates) were advanced to the infrarenal aorta. To enhance precision during deployment of the stent graft, the lowest renal artery was selectively catheterized via the right femoral access using a left internal mammary artery guide catheter. The proximal neck anatomy and origin of the renal arteries were referenced using onlay fusion. A 26-mm Gore Excluder Conformable bifurcated aortic stent graft was oriented extracorporeally, introduced via the left transfemoral approach, and advanced to a position slightly above the renal arteries. The ipsilateral sheath was retracted just distal to the contralateral gate in modification of the original IFU. The first deployment of the proximal main body was performed slightly above the lowest renal artery. The device was therefore constrained using the repositioning system, the Lunderquist guidewire was partially retrieved, and the endograft was bended to adapt to the angulated anatomy. Subsequently, the graft was cautiously pulled downward a few millimeters and reexpanded once the level of the lowest renal artery was confirmed by puff angiography. The proximal device mechanism was fully deployed. The contralateral gate was successfully catheterized via the right transfemoral approach. The main body was completely deployed after further withdrawal of the ipsilateral sheath. However, the endograft delivery system was retrieved in modification of the proposed IFU, after inflation of a molding balloon over the Lunderquist wire, to dilate the proximal sealing zone. The repair was extended to both common iliac arteries using iliac extension limbs. A molding balloon was used to dilate again the proximal and distal landing zones and attachment sites. Completion cone beam computed tomography angiography of the aorta and iliac arteries revealed widely patent bilateral renal arteries, main body, iliac limbs, and iliac arteries without evidence of endoleaks. Both femoral artery punctures were closed using the preclosure technique.

The patient was discharged home on postoperative day 2 with no complications. Follow-up computed tomography angiography (Fig 2) at 6 months showed a patent stent graft with a stable sac diameter, a type Ib endoleak from inadequate apposition of the right iliac stent graft limb, and a type II endoleak. The patient underwent successful revision with extension of the right iliac limb and perigraft embolization of the lumbosacral arteries. No residual endoleak was present on the intraoperative duplex and contrast-enhanced ultrasound scans.

DISCUSSION

This case shows several modifications of the proposed IFU for accurate deployment of the Gore Excluder conformable stent graft in patients with a severely angulated proximal neck. The approved IFU for the Gore Excluder conformable stent graft recommends using the graft in patients with a proximal infrarenal neck of ≤60° and ≥15 mm in length; therefore, this case

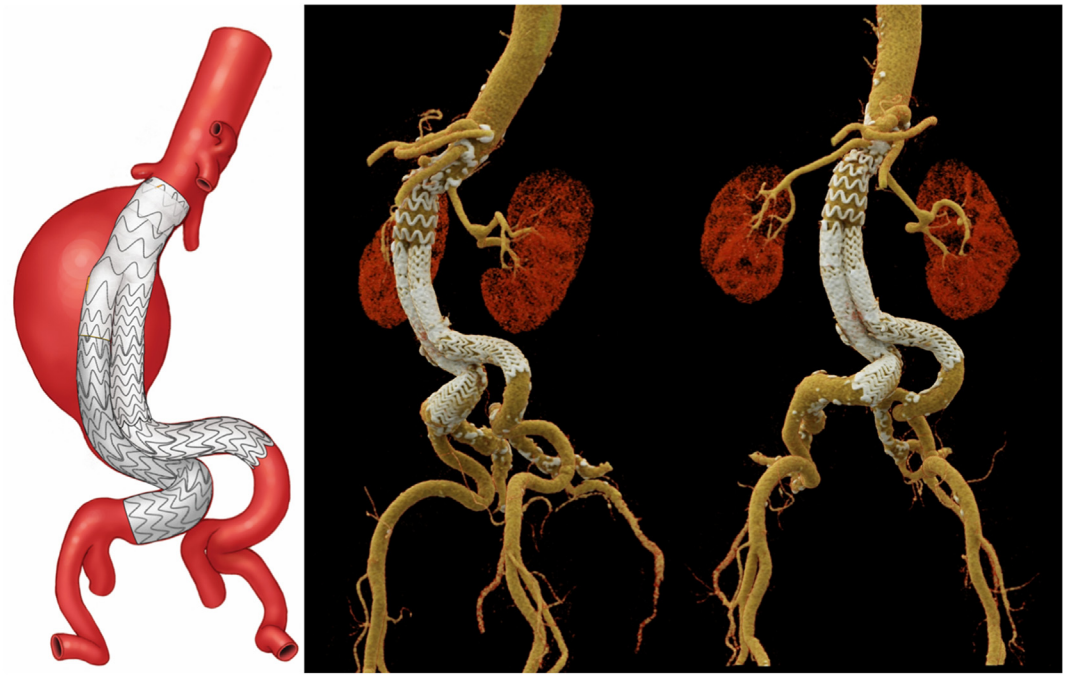

Fig 2. Illustration and three-dimensional model based on postoperative computed tomography angiography after endovascular aortic repair (EVAR) using Gore Excluder conformable endograft.

represents an off-label indication. Although several series have shown favorable short-term outcomes using the device in angulated proximal necks (>60°), we have experienced challenges in our initial experience due to the lack of a support system using the proposed IFU technique, which can lead to inaccurate deployment.[10-13] Based on the proposed IFU and initial experience, it is recommended to use the Terumo Advantage wire due to the more flexible tip and to retract the ipsilateral sheath distal to the edge of the stent graft limb. However, the lack of stent graft support with excessive tortuosity and angulation can predispose to distal dislodgement and suboptimal deployment.

Bonvini et al[12] reported on five patients with severe proximal neck angulation and recommended starting the deployment of the graft above the level of renal arteries. Other investigators have also used precatheterization of the lowest renal artery, akin to advanced fenestrated stent graft techniques, for precise deployment in patients with short landing zones.[12] These maneuvers were also applied in our case to improve the accuracy of the deployment. In addition, the approved-device IFU recommend that the main body and its integrated ipsilateral leg should be fully unsheathed before starting the deployment. We have modified the technique to keep the sheath at a higher level just distal to the contralateral gate to provide support. In addition, our preference for the Lunderquist guidewire over the floppier Terumo Advantage 0.035-in. guidewire (Terumo Interventional Systems) is also to provide support and overcome the tendency of the device to migrate distally during deployment in the presence of tortuosity and angulation. We recommend the sequence of first deployment, adjustment of parallax, bending the graft, and, finally, moving the constrained graft downward, if needed. Finally, ballooning of the proximal neck before removal of the delivery system is also recommended to engage the active fixation and prevent distal movement (Supplementary Video 2, online only).

The technique we describe reflects adjustments to the proposed IFU for the Gore Excluder conformable deployment steps based on our increasing experience with tortuous and angulated anatomy. However, caution in patient selection is critical to balance the indication against alternative options such as open repair, fenestrated grafts, and EndoSuture aneurysm repair (Medtronic). Finally, longer follow-up is needed to assess the durability of infrarenal repair in patients with excessive neck angulation.

CONCLUSIONS

The use of a conformable infrarenal stent graft is feasible in selected patients with angulated infrarenal sealing zones. Modification of the proposed IFU is needed to optimize deployment and seal due to the risk of distal movement. These useful modifications are not recommended for routine cases but offer potential advantages for patients with short and angulated necks: precatheterization of the lowest renal artery, deployment above the intended target, repositioning and

bending over support of the introducer sheath and a stiff guide wire, and ballooning before retrieval of the delivery system.

DISCLOSURES

G.S.O. has received consulting fees and grants from Cook Medical Inc, W.L. Gore & Associates, Centerline Biomedical, and GE Healthcare (all paid to Mayo Clinic and The University of Texas Health Science Center at Houston with no personal income). H.J.M.V. is a consultant for Medtronic, W.L. Gore & Associates, Artivion, Terumo Aortic, and Philips. A.V., T.A.L.S., T.M., A.B.-O., L.O., T.A.M., and R.R. have no conflicts of interest.

REFERENCES

1. Lederle FA, Kyriakides TC, Stroupe KT, et al. Open versus endovascular repair of abdominal aortic aneurysm. N Engl J Med 2019;380:2126-35.
2. Chaikof EL, Fillinger MF, Matsumura JS, et al. Identifying and grading factors that modify the outcome of endovascular aortic aneurysm repair. J Vasc Surg 2002;35:1061-6.
3. Hobo R, Kievit J, Leurs LJ, Buth J, Collaborators E. Influence of severe infrarenal aortic neck angulation on complications at the proximal neck following endovascular AAA repair: a EUROSTAR study. J Endovasc Ther 2007;14:1-11.
4. Hoshina K, Akai T, Takayama T, et al. Outcomes and morphologic changes after endovascular repair for abdominal aortic aneurysms with a severely angulated neck- a device-specific analysis. Circ J 2013;77:1996-2002.
5. Oliveira NFG, Goncalves FB, Hoeks SE, et al. Long-term outcomes of standard endovascular aneurysm repair in patients with severe neck angulation. J Vasc Surg 2018;68:1725-35.
6. Mathlouthi A, Locham S, Dakour-Aridi H, Black JH, Malas MB. Impact of suprarenal neck angulation on endovascular aneurysm repair outcomes. J Vasc Surg 2020;71:1900-6.
7. Rhee R, Peterson B, Moore E, Lepore M, Oderich G. Initial human experience with the GORE EXCLUDER conformable AAA Endoprosthesis. J Vasc Surg Cases Innov Tech 2019;5:319-22.
8. Rhee R, Oderich G, Han S, et al. One-year results of the GORE EXCLUDER Conformable AAA Endoprosthesis system in the United States regulatory trial. J Vasc Surg 2022;76:951-9.e2.
9. Finotello A, Schuurmann R, Di Gregorio S, et al. Initial clinical experience with a new conformable abdominal aortic endograft: aortic neck coverage and curvature analysis in challenging aortic necks. J Endovasc Ther 2021;28:407-14.
10. Zuidema R, Bastianon M, Mena Vera JM, et al. Single-center results of the Gore Excluder Conformable Endoprosthesis with active control system in endovascular aneurysm repair. J Cardiovasc Surg 2023;64:150-8.
11. Lee SH, Melvin R, Kerr S, Barakova L, Wilson A, Renwick B. Novel conformable stent-graft repair of abdominal aortic aneurysms with hostile neck anatomy: a single-centre experience. Vascular 2022:17085381221124990.
12. Bonvini S, Tasselli S, Raunig I, Wassermann V, Piazza M, Antonello M. Endovascular aortic repair with the Gore Excluder Conformable endograft in severe neck angulation: preliminary experience and technical aspects. Vascular 2021;29:183-9.
13. Mascoli C, Faggioli G, Goretti M, et al. Endovascular treatment of abdominal aortic aneurysm with severe angulation of infrarenal aortic neck by Gore conformable endograft. J Endovasc Ther 2022:15266028221083461.

Submitted Jul 26, 2023; accepted Sep 18, 2023.