

Proton therapy: A therapeutic opportunity for aggressive pediatric meningioma

Barbara Rombi^{1,7} | Alessandro Ruggi² | Iacopo Sardi³ | Mino Zucchelli⁴ |
Mirko Scagnet⁵ | Francesco Toni⁶ | Silvia Cammelli⁷ | Giulia Giulietti² |
Viscardo Paolo Fabbri⁸ | Francesca Gianni⁹ | Maurizio Amichetti¹ |
Torunn Ingrid Yock¹⁰ | Alessio Giuseppe Morganti⁷ | Andrea Pession² |
Fraia Melchionda²

¹ Proton Therapy Center, Santa Chiara Hospital, Trento, Italy

² Department of Pediatrics, University of Bologna, Bologna, Italy

³ Pediatric Neuro-Oncology Unit, Meyer Children's Hospital, Florence, Italy

⁴ Pediatric Neurosurgery, Institute of Neurological Science, IRCCS Bellaria Hospital, Bologna, Italy

⁵ Department of Neurosurgery, Meyer Children's Hospital, Florence, Italy

⁶ Pediatric Neuroradiology of Institute of Neurological Science, IRCCS Bellaria Hospital, Bologna, Italy

⁷ Radiation Oncology Center, Department of Experimental, Diagnostic and Specialty Medicine, DIMES, University of Bologna, Bologna, Italy

⁸ Department of Biomedical and Neuromotor Sciences, Pathology Department, University of Bologna, IRCCS Bellaria Hospital, Bologna, Italy

⁹ Department of Radiological, Oncological and Anatomic-Pathological Sciences, Sapienza University of Rome, Rome, Italy

¹⁰ Pediatric Radiation Oncology Department, Massachusetts General Hospital, Boston, Massachusetts, USA

Correspondence

Barbara Rombi, Proton Therapy Center, Santa Chiara Hospital, via Al Desert, 14, Trento 38122, Italy.
Email:

Abstract

Meningiomas are an extremely rare histology among pediatric brain tumors, and there is a shortage of literature on their management. Proton therapy is currently used safely and effectively for many types of both pediatric and adult cancer, and its main advantage is the sparing of healthy tissues from radiation, which could translate in the reduction of late side effects. We review the literature on radiotherapy and proton therapy for pediatric meningiomas and report clinical outcomes for two aggressive pediatric meningiomas we treated with protons. Proton therapy might be a safe and effective therapeutic option for this rare subgroup of tumors.

KEYWORDS

pediatric brain tumors, pediatric meningioma, proton therapy, radiotherapy

Abbreviations: CNS, central nervous system; CTV, clinical target volume; GTR, gross total resection; NF2, type 2 neurofibromatosis; OAR, organ at risk; PT, proton therapy; QoL, Quality of life; RBE, relative biological effectiveness; RFS, relapse-free survival; RT, radiotherapy.

This is an open access article under the terms of the [Creative Commons Attribution-NonCommercial](https://creativecommons.org/licenses/by-nc/4.0/) License, which permits use, distribution and reproduction in any medium, provided the original work is properly cited and is not used for commercial purposes.

© 2021 The Authors. *Pediatric Blood & Cancer* published by Wiley Periodicals LLC

1 | INTRODUCTION

While in the adult meningiomas account for 30% of all primary brain tumors and are the most common benign primary neoplasm of the brain,¹ in the pediatric population they are considerably rarer, making up roughly 2% of all pediatric central nervous system (CNS) tumors.^{2,3} The majority of meningiomas are benign, but atypical (WHO grade II) or malignant meningioma (WHO grade III) can be observed in approximately 4%–30% and 1%–3% of cases, respectively.^{4–7} These nonbenign meningiomas are associated with less favorable clinical outcome and an increased local aggressiveness, with early recurrence or tumor progression: therefore, a prompt postoperative radiotherapy may be of benefit.^{8,9}

The clinical presentation of meningiomas depends on the age of the patient and on tumor location, with symptoms and signs ranging from those related to elevated intracranial pressure to focal neurological deficits and seizures.¹⁰

The most important risk factors for the development of a meningioma in the pediatric population are genetic cancer-predisposing syndromes, such as type 2 neurofibromatosis (NF2) and Gorlin syndrome, and past cranial irradiation. Clear cell meningiomas are often associated with *SMARCE1* mutation.¹¹

Imaging studies usually show a clearly defined, contrast-enhanced lesion with surrounding brain edema, sometimes with calcification.² Cystic lesions are more common in children and sometimes (13%–30%) pediatric meningiomas lack a dural attachment.^{12–14}

Meningiomas are classified according to the WHO grading system and the most recent revision was published in 2016.⁴ Even if the majority of pediatric meningiomas are WHO grade I, there is a higher incidence of grade II and grade III tumors compared to adults¹⁰; furthermore, some variants such as clear cell meningioma (WHO grade II, 0.2% of all meningiomas¹⁴) are more common in children.² WHO grade correlates with recurrence-free survival but does not correlate clearly with overall survival.^{2,3,10}

Proton therapy (PT) is a precise and highly conformal radiation modality, representing an important therapeutic step in the multidisciplinary management of pediatric patients affected by CNS tumors. In fact, children have a high risk of developing severe long-term complications after radiotherapy, leading to psychosocial problems and reduced quality of life (QoL).^{15,16} PT has been shown to offer significant advantages compared to conventional photon-based radiotherapy in terms of both reduction of radiation-related long-term side-effects and incidence of secondary malignancies.^{17,18} The relatively good prognosis of meningiomas stresses the need of organs at risk (OARs) sparing to preserve neurocognitive function. Furthermore, some small retrospective studies^{19,20} reported improved outcome with higher than standard radiotherapy (RT) doses in WHO grade II–III tumors. A nonrandomized clinical trial found a 70% 3-year progression-free survival in WHO grade II meningioma patients undergoing a complete resection (Simpson I–III) plus high-dose (60 Gy) radiotherapy.²¹ Based on this background,

we present here two cases of pediatric meningiomas treated with PT.

2 | RESULTS

Two pediatric patients with meningioma located intracranially in two different sites were treated with proton irradiation (pencil-beam scanning technique) in 2018.

2.1 | Case descriptions

2.1.1 | Case one

A 1-month-old male infant developed right eye ptosis and was closely monitored. At 4 months of age, a fixed mydriasis was also noted, with partial deficit of the third cranial nerve and *heterochromia iridis*. His birth history was only notable for oligohydramnios. However, family history was positive for neurosensorial hypoacusis on the maternal side and for retinoblastoma on the paternal side. Brain magnetic resonance imaging (MRI) revealed an expansive lesion (diameters: 12 × 14 × 16 mm) adjacent to the third right cranial nerve and in the interpeduncular and ambiens cistern; no secondary lesions were observed. A surgical biopsy of the lesion was performed, and histology showed an invasive clear-cell meningioma (WHO grade II) with a Ki67 proliferative index of 7%. Tumor cells were positive for EMA and vimentin, negative for GFAP, Olig2, and SYN. The protein INI1 was expressed. The diagnosis was confirmed by the Italian central pathology reference center for pediatric CNS tumors. Given the rarity of the disease and family history of hypoacusis, the child was investigated for mutations of the NF2 gene, as well as for germ-line mutations of *SMARCE1*: however, both tests were negative. Surgery was deemed not feasible and, after multidisciplinary consultation, a close clinical and radiological follow up was planned to detect early signs of progressive disease.

At approximately 12 months of age, a follow-up MRI (see Figure 1A–D) showed signs of progression: the mass grew to 14 × 18 × 23 mm, expanding into the ambiens cistern with signs of infiltration of the homolateral cerebral peduncle. A slight contrast enhancement along the border of the contralateral cerebral peduncle was also observed, as well as a significant increase of the perilesional edema, with marked involvement of the midbrain.

Since the tumor was unresectable, the patient was referred to a proton facility where he received active-scanning fractionated PT using three beam arrangements. He received a total dose of 54 Gy relative biological effectiveness (RBE) in 30 fractions, 1.8 Gy daily, to the clinical target volume (CTV), which included both gross tumor volume and 3 mm isotropic margins for high risk of microscopic dissemination in daily anesthesia (Figure S1). PT was well tolerated, and no supportive therapies were necessary; neither hematological nor other toxicities

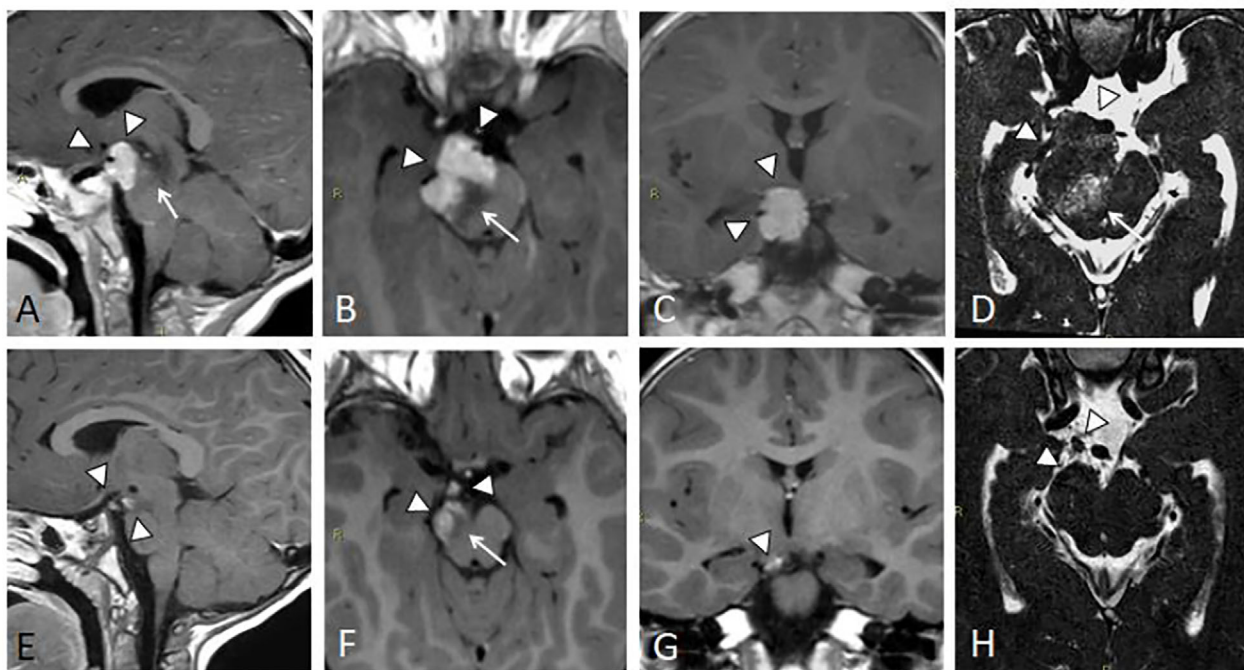


FIGURE 1 MRI of an infant with invasive clear-cell meningioma of the brainstem. Post-surgical/preprotontherapy MRI: (A–C) sagittal, axial, and coronal 3D T1-weighted multiplanar reconstructions (MPR); (D) axial 3D T2 DRIVE. Meningioma arising from the right third cranial nerve, infiltrating adjacent ventral portion of the mesencephalon (arrowheads); perilesional vasogenic edema is evident (arrow). (E–G) Postprotontherapy MRI, 39 months after treatment: sagittal, axial, and coronal 3D T1-weighted MPR; (H) axial 3D T2 DRIVE. Noticeable volume reduction of the treated meningioma (arrowhead) along with perilesional edema (arrow)

(i.e., neurological symptoms) were observed, except for alopecia and a mild skin reaction (grade 1, CTCAE v.4) of the treated region.

Two months after PT, the parents complained about a significant loss of muscle strength on the left side. A first MRI was performed, showing slightly increased perilesional edema, with no other modifications of the known lesion; two months later, a second MRI showed an increase of the edema and the appearance of small cavernomas adjacent to the irradiated area. The tumor, however, appeared smaller and with more contrast inhomogeneity. Dexamethasone was initiated and after 1 month of therapy, a control MRI showed a significant reduction of the edema. Therefore, steroid therapy was gradually reduced and finally discontinued. Clinically, the hyposthenia improved, with only a slight residual weakness in grasping with the left hand. Regular MRI scans (one every 3 months) showed a steady reduction in size of the meningioma (Figure 1E–H). At 39 months of follow-up after PT, no other toxicities were observed. The child undergoes regular physical therapy for residual minimal impairment of the left hand; the right eye ptosis, observed since diagnosis, has remained unchanged. During follow-up, the child's cognitive development was regularly evaluated using age-adjusted neuropsychological scales and no significant deviations from the normal range were found.

2.1.2 | Case two

A 7-year-old male child experienced repeated episodes of severe headache with falls, tremors, and loss of urine. An MRI showed a frontal

lobe mass (50 × 70 × 50 mm) with signs of intralesional hemorrhage (Figure 2A–C). The patient underwent surgery, with a frontal paramedian approach. Pathological examination showed a proliferation of meningothelial cells with prominent nucleoli, invading the adjacent brain parenchyma. Mitoses were present (>4 X HPF) as well as areas of necrosis. The Ki67 proliferative index was 18% in the most positive areas. Based on these features, the tumor was identified as an atypical meningioma (WHO grade II).

A ventriculo-peritoneal shunt was implanted due to postoperative obstructive hydrocephalus. Postoperative MRI showed residual tumor (47 × 45 × 45 mm) in the anterior part of the corpus callosum. Therefore, a second resection was performed with the goal of achieving complete tumor removal. The postoperative contrast-enhancement MRI scan showed a 7 mm diameter nodule, confirmed by a Gallium-68 DOTATOC PET-CT (Figure 2D–F).

Considering these findings, PT was delivered 45 days after re-resection to the CTV plus 3 mm of margins (total dose: 59.4 Gy RBE in 33 fractions, 1.8 Gy RBE/fraction, daily) (Figure S2). PT was well tolerated, and no toxicities (i.e., neurological symptoms) were observed except for partial alopecia of the treated region. The CTV was defined as the tumor bed area seen on postoperative MRI, planning CT/MRI, and additional PET-imaging with ⁶⁸Ga-Dotatoc, plus a 5 mm margin. CTV also included the biological target volume, that is, areas with increased focal uptake as seen in the DOTATOC PET-CT.

An MRI performed after PT showed only mild contrast enhancement in the frontal meninges of the surgical cavity (Figure 2G–I). Subsequently, the child started follow-up with both clinical

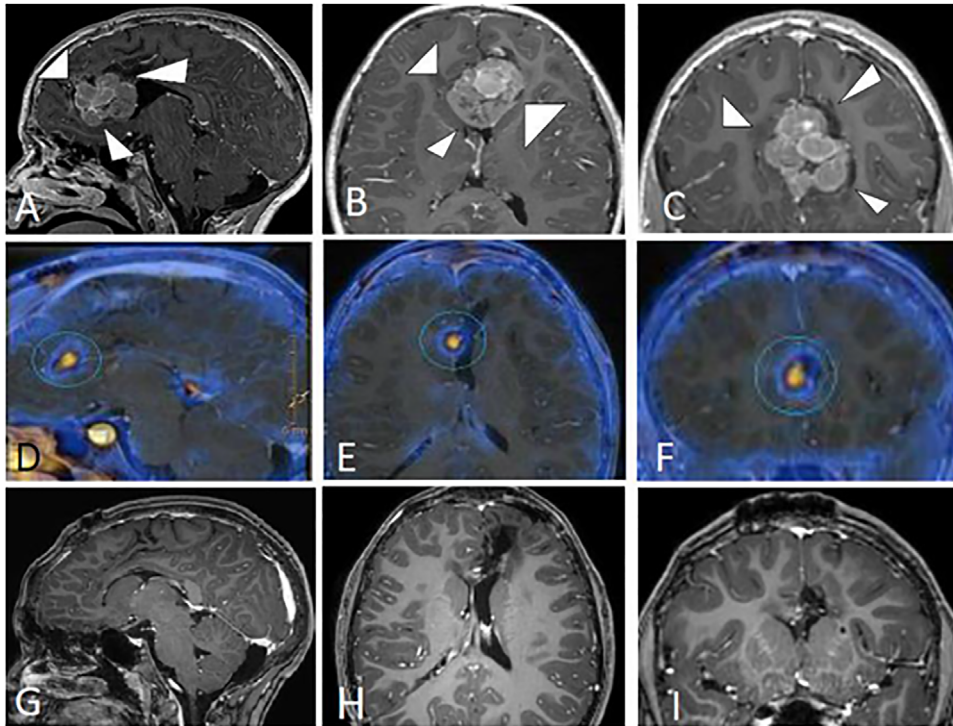


FIGURE 2 MRI of a child with frontal lobe atypical meningioma. Presurgical MRI: (A–C) sagittal, axial, and coronal 3D T1-weighted multiplanar reconstructions (MPR). Meningioma arising from the frontal lobe with signs of intraslesional hemorrhage (arrowheads); postsurgical/preprotontherapy MRI/PET: (D–F) sagittal, axial, and coronal Gallium-68 DOTATOC PET fused with 3D T1-weighted postoperative MRI; noticeable small hypercaptating nodule in the frontal tumor bed (ring). Postprotontherapy MRI 30 months after treatment: (G–I): sagittal, axial, and coronal 3D T1-weighted. No evidence of residual tumor

examinations and surveillance MRIs. At 33 months of follow-up after PT, the last MRI showed an unchanged postsurgical malacic area with hemosiderin residues of the left parasagittal frontal lobe. The contrast enhancement of the frontal meninges was also unchanged. Clinically, he did not develop any late toxicity. As with the first patient, a series of regular cognitive evaluations were performed, and at the latest follow-up visit the child was both cognitively and physically normal.

3 | DISCUSSION

We reported on two pediatric meningiomas treated with PT. After an observation period of approximately 3 years, the disease was controlled, and PT was relatively well tolerated.

Infantile meningiomas, like the first case we reported, are exceedingly rare²: genetic cancer-predisposing syndromes, such as NF2 and Gorlin syndrome, are sometimes associated with these tumors and we screened both our patients for them, but neither was found positive. Until now, the number of reported clear cell meningiomas in children is extremely limited, making its management challenging, with no clear treatment options and scarce data on prognosis.^{14,22–25} Management of pediatric meningiomas is often extrapolated from knowledge of the adult counterparts.^{2,3} As for many other CNS tumors in children and adolescents, gross-total resection (GTR) should be attempted

whenever possible: a large meta-analysis showed that patients who had an initial GTR had better relapse-free survival (RFS) and overall survival than those with only subtotal resections.¹⁰ In the event of an incomplete resection, the possibility of a second surgery should be evaluated. It should be noted, however, that aggressive surgery is associated with higher perioperative mortality and long-term neurological morbidity. Therefore, a careful risk–benefit analysis should be done for each patient.¹⁰ The same meta-analysis by Kotecha et al. reported a relatively high mortality rate of 12.7% after 5–7 years of follow-up,¹⁰ with a Dutch study showing similar results (16.1% mortality, mean follow-up: 4.8 years).²⁶ Children with NF2 tend to have worse RFS and overall survival (especially over longer periods of time).¹⁰ Patients under 3 years of age may have worse overall survival, with the already cited meta-analysis finding a borderline significant correlation.¹⁰ However, since these two studies only included children who underwent surgery, they may be biased toward more aggressive tumors. In fact, other studies show no difference in mortality between children/adolescents and young adults and warn against overtreatment due to a perceived aggressive nature of pediatric meningiomas.³

The evidence for the use of radiotherapy in pediatric meningiomas is limited and current recommendations are based on adult retrospective series.^{2,27} Children, especially infants, are more vulnerable to the effects of radiotherapy and of developing late sequelae.²⁸ The *St. Jude Lifetime Cohort Study* (SJLIFE) showed a higher incidence of

severe chronic disease in children with brain tumors who received a higher radiation dose.²⁹ Thus, the decision to use radiation therapy for pediatric meningioma should be carefully evaluated: the Children's Cancer and Leukemia Group (CCLG) suggests consideration of radiotherapy for grade I–II meningiomas after multiple relapses that cannot be operated or after evidence of clinically relevant progression after incomplete resection, and in all grade III meningiomas at time of diagnosis, regardless of surgical outcome.³⁰ Gamma knife and conventional radiotherapy are also used as adjuvant therapies for pediatric meningiomas that cannot be completely resected due to their location.³¹ A retrospective analysis by Dudley et al. showed that a higher percentage of children/adolescents and young adults with meningioma are treated with radiotherapy compared to adults,³ even if its role and impact on prognosis are not clear. Upfront radiotherapy is associated with worse RFS but does not appear to have a significant effect on overall survival; it should be noted that in the meta-analysis by Kotecha et al. the number of patients who underwent upfront radiotherapy was small and the dose, type, and rationale behind the decision to irradiate were unknown.¹⁰

During the treatment planning process, the definition of the target volume remains challenging even when using MRI and CT imaging combined: Kessel et al. showed that the addition of PET imaging for target volume definition led to a significantly enhanced local control after high-precision RT. Thus, PET improves the detection of tumor cells and helps distinguish between healthy tissue and meningioma tissue.³²

The use of PT in adult meningioma patients showed promising results,^{33,34} the main limitation being its availability. The physical properties of protons allow to better spare healthy brain tissue and neighboring organs, significantly reducing the dose received by OARs: this should lead to a lower incidence of adverse effects, justifying the higher cost of protons compared to traditional, photon-based radiation therapy.^{35,36} A recent review by Adeberg et al. found that PT for adult meningiomas achieves high rates of local control and limited toxicity, with positive implications for QoL.³⁷ In our patients, limited toxicity (both acute and late) has been reported: in patient 1, the post PT perilesional edema resolved completely after standard steroid therapy, with minimal residual hyposthenia of the left hand, while the small cavernomas remained asymptomatic. The development of cavernomas following CNS radiotherapy is well documented with photons^{38–40} and authors believe that asymptomatic lesions should only be monitored regularly.³⁸ Patient 2 had no significant acute or late toxicities related to PT and remains in good physical and cognitive conditions at the last follow-up evaluation.

The present study has several limitations: disease rarity makes prospective and comparative studies exceedingly difficult, thus only retrospective data were used. However, the results presented, while representing only a starting point for future clinical studies on the subject, indicate a favorable role of protons in treating these rare and challenging tumors thanks to their well-documented dosimetric advantage, which leads to lower toxicity rates while still achieving good clinical results.

4 | CONCLUSIONS

Pediatric meningiomas are rare and differ from their adult counterpart in many regards. When feasible, gross total resection remains the treatment of choice also in the pediatric setting. In the event of subtotal resection, a re-resection is recommended if achievable. After careful pathological review and multidisciplinary discussion, adjuvant RT should be carefully considered particularly for high-grade tumors. Given the marked radiosensitivity of brain parenchyma in children, PT should be considered in these patients to reduce the risk of toxicity and to improve their quality of life. Based on data showing improved local control in meningiomas treated with RT and planned using also PET, the latter should be used for target definition in highly conformed treatment modalities such as PT.

ACKNOWLEDGMENT

We sincerely thank Milly Buwenge, PhD, for editorial assistance in preparing the manuscript.

CONFLICT OF INTEREST

The authors declare that there is no conflict of interest.

REFERENCES

- Combs SE, Adeberg S, Dittmar J-O, et al. Skull base meningiomas: long-term results and patient self-reported outcome in 507 patients treated with fractionated stereotactic radiotherapy (FSRT) or intensity modulated radiotherapy (IMRT). *Radiother Oncol J Eur Soc Ther Radiol Oncol*. 2013;106(2):186–191.
- Kotecha RS, Junckerstorff RC, Lee S, Cole CH, Gottardo NG. Pediatric meningioma: current approaches and future direction. *J Neurooncol*. 2011;104(1):1–10.
- Dudley RWR, Torok MR, Randall S, et al. Pediatric versus adult meningioma: comparison of epidemiology, treatments, and outcomes using the Surveillance, Epidemiology, and End Results database. *J Neurooncol*. 2018;137(3):621–629.
- Louis DN, Perry A, Reifenberger G, et al. The 2016 World Health Organization classification of tumors of the central nervous system: a summary. *Acta Neuropathol*. 2016;131(6):803–820.
- Holleczek B, Zampella D, Urbschat S, et al. Incidence, mortality and outcome of meningiomas: a population-based study from Germany. *Cancer Epidemiol*. 2019;62. <https://doi.org/10.1016/j.canep.2019.07.001>.
- Backer-Grøndahl T, Moen BH, Torp SH. The histopathological spectrum of human meningiomas. *Int J Clin Exp Pathol*. 2012;5(3):231–242.
- Kshetry VR, Ostrom QT, Kruchko C, Al-Mefty O, Barnett GH, Barnholtz-Sloan JS. Descriptive epidemiology of World Health Organization grades II and III intracranial meningiomas in the United States. *Neuro Oncol*. 2015;17(8):1166–1173.
- Murray FR, Snider JW, Bolsi A, et al. Long-term clinical outcomes of pencil beam scanning proton therapy for benign and non-benign intracranial meningiomas. *Int J Radiat Oncol Biol Phys*. 2017;99(5):1190–1198.
- Adeberg S, Hartmann C, Welzel T, et al. Long-term outcome after radiotherapy in patients with atypical and malignant meningiomas—clinical results in 85 patients treated in a single institution leading to optimized guidelines for early radiation therapy. *Int J Radiat Oncol Biol Phys*. 2012;83(3):859–864.

10. Kotecha RS, Pascoe EM, Rushing EJ, et al. Meningiomas in children and adolescents: a meta-analysis of individual patient data. *Lancet Oncol*. 2011;12(13):1229-1239.
11. Smith MJ, O'sullivan J, Bhaskar SS, et al. Loss-of-function mutations in SMARCE1 cause an inherited disorder of multiple spinal meningiomas. *Nat Genet*. 2013;45(3):295-298.
12. Ferrante L, Acqui M, Artico M, Mastronardi L, Fortuna A. Paediatric intracranial meningiomas. *Br J Neurosurg*. 1989;3(2):189-196.
13. Symons P, Tobias V, Pereira J, Vonau M. Brain-invasive meningioma in a 16-month-old boy. *Pathology*. 2001;33(2):252-256.
14. Li H, Zhao M, Jiao Y, et al. Pediatric intracranial clear cell meningioma: a clinicopathological study of seven cases and literature review. *Child's Nerv Syst ChNS Off J Int Soc Pediatr Neurosurg*. 2017;33(2):239-248.
15. Armstrong GT, Stovall M, Robison LL. Long-term effects of radiation exposure among adult survivors of childhood cancer: results from the childhood cancer survivor study. *Radiat Res*. 2010;174(6 B):840-850.
16. Armstrong GT, Reddick WE, Petersen RC, et al. Evaluation of memory impairment in aging adult survivors of childhood acute lymphoblastic leukemia treated with cranial radiotherapy. *J Natl Cancer Inst*. 2013;105(12):899-907.
17. Sethi RV, Shih HA, Yeap BY, et al. Second nonocular tumors among survivors of retinoblastoma treated with contemporary photon and proton radiotherapy. *Cancer*. 2014;120(1):126-133.
18. Chung CS, Yock TI, Nelson K, Xu Y, Keating NL, Tarbell NJ. Incidence of second malignancies among patients treated with proton versus photon radiation. *Int J Radiat Oncol*. 2013;87(1):46-52.
19. Milosevic MF, Frost PJ, Laperriere NJ, Wong CS, Simpson WJ. Radiotherapy for atypical or malignant intracranial meningioma. *Int J Radiat Oncol Biol Phys*. 1996;34(4):817-822.
20. Goldsmith BJ, Wara WM, Wilson CB, Larson DA. Postoperative irradiation for subtotally resected meningiomas. A retrospective analysis of 140 patients treated from 1967 to 1990. *J Neurosurg*. 1994;80(2):195-201.
21. Weber DC, Ares C, Villa S, et al. Adjuvant postoperative high-dose radiotherapy for atypical and malignant meningioma: a phase-II parallel non-randomized and observation study (EORTC 22042-26042). *Radiother Oncol*. 2018;128(2):260-265.
22. Kumar R, Das K, Jaiswal A, et al. Clear cell meningioma in a child: a case report and review of literature. *Asian J Neurosurg*. 2015;10(1):53.
23. Ahn ES, Chin LS, Gyure KA, Hudes RS, Ragheb J, Dipatri AJ. Long-term control after resection and gamma knife surgery of an intracranial clear cell meningioma. Case report. *J Neurosurg*. 2005;102:303-306.
24. Li Z, Zhang Yi, Wang E, et al. Intracranial clear cell meningioma in two children with blood relations: two case reports and literature review. *Child's Nerv Syst*. 2012;28(12):2143-2151.
25. Juratli TA, Geiger KD, Weigel P, et al. A five year-old child with clear cell petro-clival meningioma: case report with clinical and histopathological long-term follow-up. *Child's Nerv Syst*. 2015;31(11):2193-2198.
26. Thuijs NB, Uitdehaag BMJ, Van Ouwkerk WJR, Van Der Valk P, Vandertop WP, Peerdeman SM. Pediatric meningiomas in The Netherlands 1974-2010: a descriptive epidemiological case study. *Child's Nerv Syst*. 2012;28(7):1009-1015.
27. Gao X, Zhang R, Mao Y, Wang Y. Childhood and juvenile meningiomas. *Child's Nerv Syst ChNS Off J Int Soc Pediatr Neurosurg*. 2009;25(12):1571-1580.
28. D. PAMP, D. DGPM. *Principles and Practice of Pediatric Oncology*. 7th ed. Philadelphia, PA: Lippincott Williams & Wilkins; 2015.
29. Bhakta N, Liu Qi, Ness KK, et al. The cumulative burden of surviving childhood cancer: an initial report from the St Jude Lifetime Cohort Study (SJLIFE). *Lancet*. 2017;390(10112):2569-2582.
30. Traunecker H, Mallucci C, Grundy R, Pizer B, Saran F. Children's Cancer and Leukaemia Group (CCLG): guidelines for the management of intracranial meningioma in children and young people. *Br J Neurosurg*. 2008;22(1):13-25.
31. Liu H, Luo W, Li J, Yang J, Xu Y. Pediatric infratentorial meningiomas: a series of 19 cases and review of the literature. *Child's Nerv Syst ChNS Off J Int Soc Pediatr Neurosurg*. 2017;33(5):777-786.
32. Kessel KA, Weber W, Yakushev I, et al. Integration of PET-imaging into radiotherapy treatment planning for low-grade meningiomas improves outcome. *Eur J Nucl Med Mol Imaging*. 2020;47(6):1391-1399.
33. Hanft S, Canoll P, Bruce JN. A review of malignant meningiomas: diagnosis, characteristics, and treatment. *J Neurooncol*. 2010;99(3):433-443.
34. Modha A, Gutin PH. Diagnosis and treatment of atypical and anaplastic meningiomas: a review. *Neurosurgery*. 2005;57(3):538-549.
35. Baliga S, Yock TI. Proton beam therapy in pediatric oncology. *Curr Opin Pediatr*. 2019;31(1):28-34.
36. Rombi B, Vennarini S, Vinante L, Ravanelli D, Amichetti M. Proton radiotherapy for pediatric tumors: review of first clinical results. *Ital J Pediatr*. 2014;40(1). <https://doi.org/10.1186/s13052-014-0074-6>.
37. Adeberg S, Harrabi SB, Verma V, et al. Treatment of meningioma and glioma with protons and carbon ions. *Radiat Oncol*. 2017;12(1):193.
38. Di Giannatale A, Morana G, Rossi A, et al. Natural history of cavernous malformations in children with brain tumors treated with radiotherapy and chemotherapy. *J Neurooncol*. 2014;117(2):311-320.
39. Passos J, Nzwalo H, Valente M, et al. Microbleeds and cavernomas after radiotherapy for paediatric primary brain tumours. *J Neurol Sci*. 2017;372:413-416.
40. Liu Y, Preston R, Thomas SM, Brackenridge A, Carroll PV. Cerebral cavernoma: an emerging long-term consequence of external beam radiation in childhood. *Clin Endocrinol (Oxf)*. 2010;73(5):555-560.

SUPPORTING INFORMATION

Additional supporting information may be found online in the Supporting Information section at the end of the article.

How to cite this article: Rombi B, Ruggi A, Sardi I, et al. Proton therapy: A therapeutic opportunity for aggressive pediatric meningioma. *Pediatr Blood Cancer*. 2021;e28919. <https://doi.org/10.1002/pbc.28919>