




ELSEVIER

Contents lists available at [ScienceDirect](https://www.sciencedirect.com)

Oral and Maxillofacial Surgery Cases

journal homepage: www.oralandmaxillofacialsurgerycases.com

Minimally invasive rehabilitation of a severely atrophic and fully edentulous maxilla using 4-mm-ultrashort implants: A case report with 1-year follow-up

Pietro Felice^{a,*}, Maryia Karaban^a, Roberto Pistilli^b, Pierantonio Bellini^c, Lorenzo Bonifazi^a, Carlo Barausse^a

^a Unit of Oral Surgery, Department of Biomedical and Neuromotor Sciences, University of Bologna, Italy

^b Oral and Maxillofacial Unit, San Camillo Hospital, Rome, Italy

^c Unit of Dentistry and Oral-Maxillo-Facial Surgery, University of Modena and Reggio Emilia, Italy

ARTICLE INFO

Keywords:

Fully edentulism
Atrophic maxilla
Minimal invasiveness
Short implant

ABSTRACT

This case report describes an alternative minimally invasive treatment option using 4-mm-long ultrashort implants placed to rehabilitate a severely atrophic edentulous maxilla. The patient, coming from a full removable denture, asked for an implant prosthesis avoiding reconstructive surgeries and expensive procedures. Considering that the mean available bone was about 4.8 mm in height on Cone Beam Computed Tomography (CBCT) scans, 6 implants were placed where bone volumes were sufficient to receive 4-mm-ultrashort implants. Six months after implant placement an implant-supported bar-retained overdenture prosthesis was delivered. The healing process was uneventful and 1 year after loading the result appears clinically and radiographically stable and the patient is fully satisfied. The described approach, despite some prosthetic compromises, within all the limitations of this case report, might be applied in selected cases, reducing rehabilitative times, possible complications and costs. However, longer follow-ups on large number of patients coming from Randomised Controlled clinical Trials (RCTs) are necessary before making more reliable recommendations.

1. Introduction

The rehabilitation of patients with fully edentulous maxillae can be a common clinical situation [1]. For a long time, the usual solution to treat these cases has been a traditional removable full denture prosthesis. However, this method of treatment has a large number of limits, which currently makes it unacceptable by many patients.

Nowadays, with an increase in average life expectancy, clinicians often have to deal with completely edentulous patients with functional and aesthetic needs asking for implant rehabilitations [2].

In cases of available bone volumes, it is possible to rehabilitate the upper jaw using various implants solutions. However, there are also clinical conditions with posterior bone atrophies, in these cases, it is possible to exploit the front patient's bone tilting implants in different ways, also with immediate loading protocols [3,4]. Another option could be to place standard implants in the anterior

* Corresponding author. Unit of Oral Surgery, Department of Biomedical and Neuromotor Sciences, University of Bologna, Via San Vitale 59, 40125, Bologna (BO), Italy.

E-mail address: pietro.felice@unibo.it (P. Felice).

<https://doi.org/10.1016/j.omsc.2020.100176>

Received 17 June 2020; Accepted 13 July 2020

Available online 14 July 2020

2214-5419/© 2020 The Authors. Published by Elsevier Inc. This is an open access article under the CC BY-NC-ND license

(<http://creativecommons.org/licenses/by-nc-nd/4.0/>).

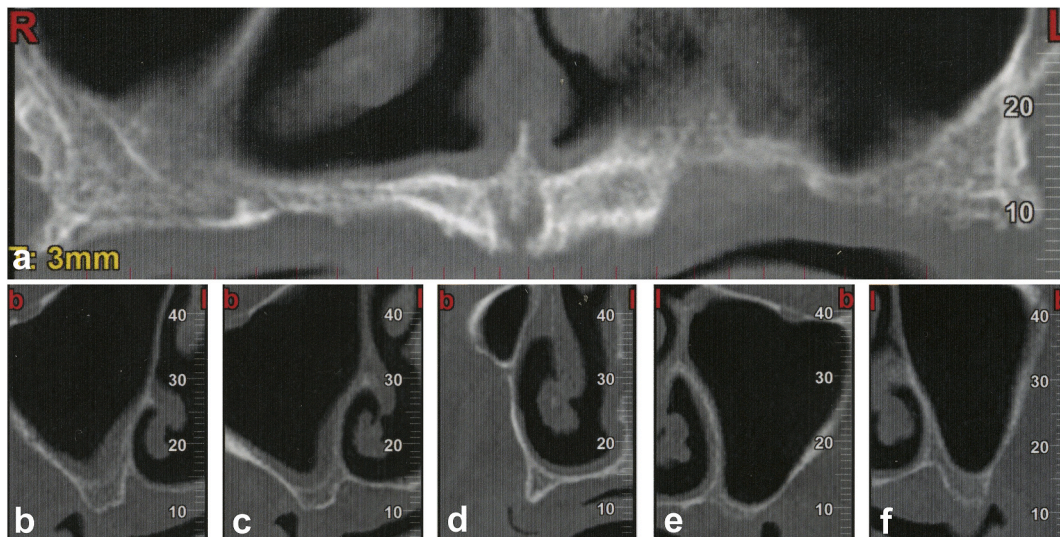


Fig. 1. (a–f): Baseline Cone Beam Computed Tomography (CBCT) scans showing a fully edentulous maxilla with different degrees of extreme bone atrophy.

non-atrophic bone performing posterior bone augmentation surgeries [5–7].

Also, there are cases of extreme atrophy where there is no posterior or anterior available bone to receive any standard implants; in these situations, surgeons can apply different approaches. Various reconstructive techniques can be used to augment bone for long implant placement, the most known are Guided Bone Regeneration (GBR) with titanium meshes [8], onlay bone grafts [9,10] and sinus lifting surgeries [5]. However, these procedures are associated with postoperative complications, long rehabilitative times and tend to be expensive.

Zygomatic [11,12] and pterygoid [13] implants placement can be an alternative to bone augmentation surgery in patients with a severely atrophic maxilla. Nevertheless, these kinds of rehabilitative treatments are often associated with hospitalization, general anesthesia, and require particular surgical skills.

So another option for the rehabilitation of severely atrophic upper jaws might be to place short implants. Encouraging short-term results on implants with a minimum length of 5 mm were reported in the literature [14].

However, according to the authors' present knowledge, there are no studies on extreme maxillary atrophies allowing the placement of only 4-mm-long implants. This case report describes a preliminary case of an extremely atrophic and fully edentulous upper jaw rehabilitated with 4-mm-supershort implants with results at 1 year after prosthetic loading.

2. Materials and methods

A 71-year-old female in good general health was referred, complaining about functional masticatory insufficiency at her upper jaw, asking for implant rehabilitation.

Clinical and radiographic baseline data (Orthopantomography, OPG) revealed a fully edentulous maxilla. Cone Beam Computed Tomography (CBCT) scans showed a mean residual bone height of about 4.8 mm with different levels of vertical and horizontal bone atrophy (Fig. 1). At the time of the first examination, the patient wore a fully removable upper denture, which according to the anamnesis was delivered several years ago. Over time, the patient was no longer satisfied with the removable solution and asked for a cheap implant rehabilitation avoiding any reconstructive surgery.

Trying to meet patient's needs, a minimally invasive approach was proposed using implants with a length of 4 mm for subsequent implant-retained prosthetic rehabilitation. The patient underwent professional oral hygiene 2 weeks before surgery and gave informed consent for all the procedures. Two grams of amoxicillin were administered 1 hour prior to implant placement and the patient rinsed for 1 minute with 0.2% chlorhexidine solution just before surgery. The surgical procedure was performed under local anesthesia (4% articaine, 1:100,000 adrenaline). A crestal incision was made along the entire maxilla with distal releasing incisions and full-thickness flaps were elevated.

Six 4 × 4 mm transmucosal ultrashort implants (Twinkon 4, Global D, Brignais, France) were then placed where sufficient bone volumes were available. In case of less than 4 mm of residual bone, supershort implants were placed palatally and when needed a crestal sinus lifting approach, placing just collagen sponges to protect the sinus membrane, was performed [15]. However, posteriorly, at least 2 mm of vertical residual bone were needed in order to stabilize the implants, so there were parts of the left maxilla not useable at all. At the end, all the implants had good primary stability.

Flaps were then closed with resorbable sutures and a post-surgical OPG was taken to verify the correct implant position (Fig. 2). The patient was then prescribed 1 g of amoxicillin with clavulanic acid twice a day for 6 days, 600 mg of ibuprofen to be taken with meals

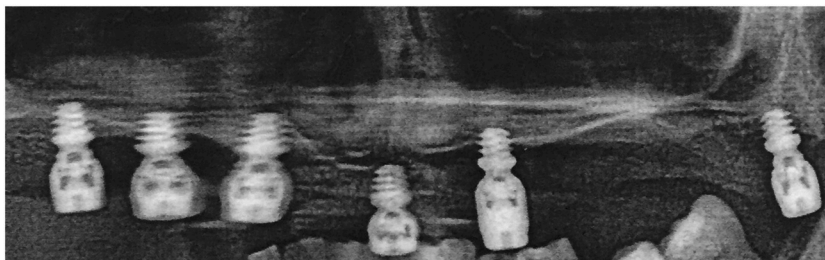

Fig. 2. Post-operative Orthopantomography (OPG) showing the six 4-mm-supershort implants in place.

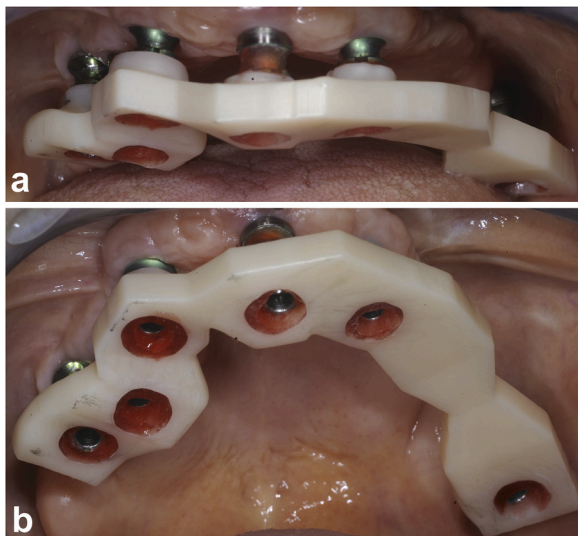


Fig. 3. (a,b): Prosthetic phases 6 months after supershort implant placement: intraoral bar check.

twice a day for two days and oral betamethasone (4 mg the first day, 3, 2, 1 mg the followings). The patient was instructed to place 1% of chlorhexidine gel on the wound twice a day for 2 weeks and to avoid brushing and trauma on the surgical site; a soft diet was also advised.

3. Results

Sutures were removed after 14 days and the patient was clinically examined every week for the first month and monthly during the first 6 months, with an uneventful postoperative course. The patient was instructed not to wear the removable prosthesis during masticatory function for 1 month after surgery and the denture was rebased with a soft conditioner once a week for the first month and then once a month up to 6 months. A radiographic check was made 6 months after implant placement with no complications detected.

Six months after implants placement, a definitive bar-retained overdenture (OVD) prosthesis was delivered (Figs. 3 and 4) and the patient was enrolled in a professional oral hygiene program with recalls every 3 months.

One year after prosthetic loading, the implants showed no clinical or radiographic issues (Fig. 5). Peri-implant marginal bone levels appear to be stable and the patient is fully satisfied.

4. Discussion

In the described case the patient had worn a full removable upper prosthesis for several years. Fixed solutions proposed in the past were too expensive and the patient had refused the at-that-time proposed reconstructive surgeries because they were too invasive and long. However, over time the patient was no longer satisfied with the removable denture asking for a minimally invasive and cheap implant solution. In these cases where the level of atrophy is extreme, not allowing the placement of any conventional-length implant, patients' needs and expectations should be firstly assessed with particular attention.

If aesthetic and functional needs are relevant, then it could be necessary to reconstruct the bone. As an alternative, it is possible to exploit patient's native bone and there are three main options: zygomatic, pterygoid or tilted implants. Although the use of pterygoid implants has been successfully described, this procedure has not been widely used because of the severity of possible complications

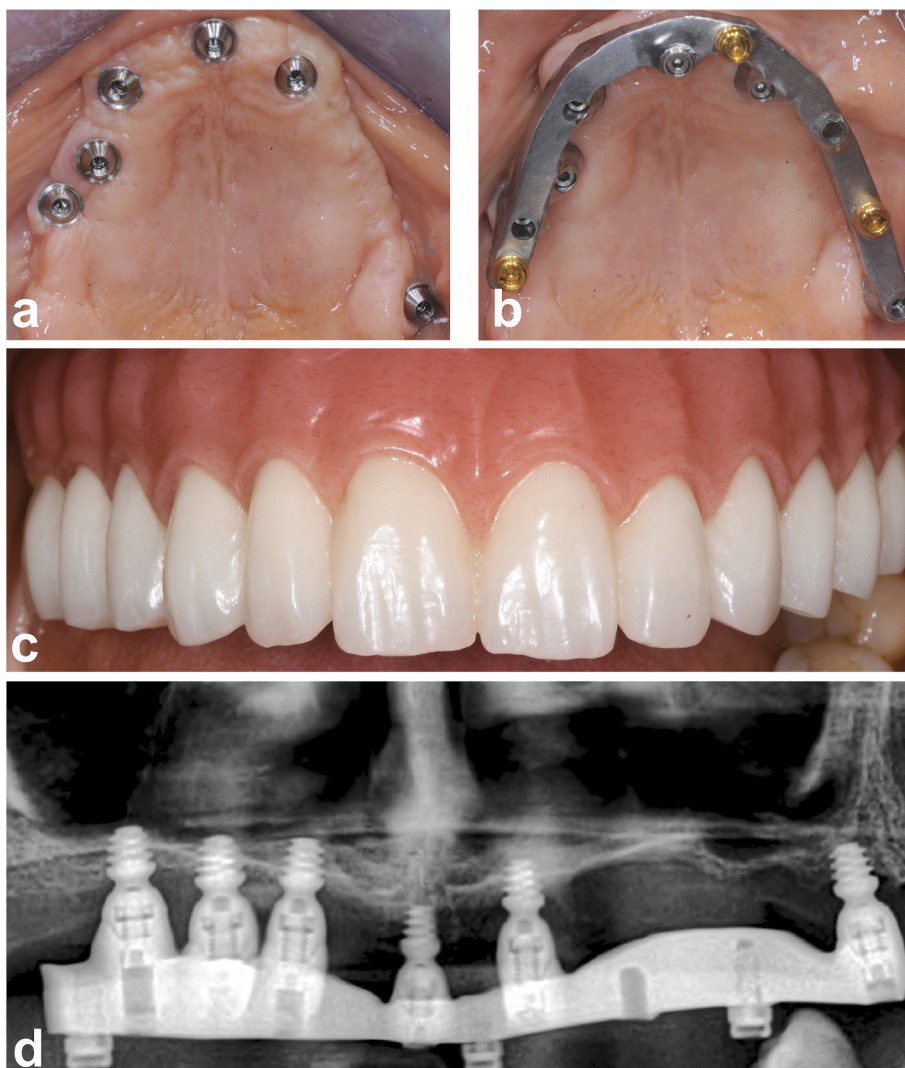


Fig. 4. (a–d): Delivery of the bar-retained overdenture (OVD) prosthesis: (a) tissues appearance, (b) milled bar in place, (c) clinical and (d) radiographic (OPG) OVD prosthetic views.

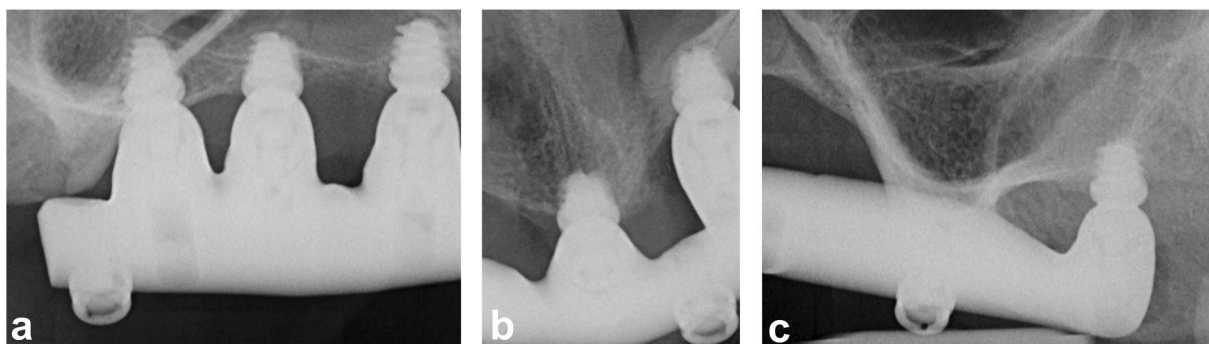


Fig. 5. (a–c): Intraoral periapical x-rays taken 1 year after loading with stable peri-implant marginal bone levels.

[13]. Also tilted implants could be a viable treatment modality for the immediate rehabilitation of the edentulous maxilla, but it was not suitable for the described clinical situation because there was not enough residual bone allowing long implants placement, even if tilted.

The patient of this current case report asked for the least invasive and expensive implant approach refusing grafts or invasive and costly procedures such as zygomatic implants [11,12], which were probably the best possible alternative to short implants according to the author's experience.

Therefore, given the severe degree of atrophy, it was decided to place 4 mm ultrashort implants, sharing all the possible risks with the patient and being aware of all the limits of this procedure.

Our choice was made on the basis of encouraging results coming from the literature [16–18]. For instance, an RCT compared up to 5 mm short implants to longer implants in augmented bone in atrophic maxillae, without showing statistically significant difference in implant failure but significantly fewer complications in the short implants group (no complications vs 3) [14]. Regarding 4 mm ultrashort implants good results were reported in the literature, but in partially edentulous atrophic and posterior jaws and again with a follow-up of only 1 year after loading. In this RCT, 4.0 mm long implants achieved similar results than longer implants placed in augmented jaws but were affected by fewer complications (9 versus 4) [19].

However, despite the possible advantages, the use of ultrashort implants can involve a series of prosthetic compromises that should be taken into consideration: implants are placed where there is sufficient available bone and, therefore, it is necessary at the end to compensate lacking bone volumes and implant disparallelism with the prosthesis. Regarding prosthetic options, a Toronto Bridge may have led to severe hygienic problems, so, in agreement with the patient, the choice of the prosthetic type was in favour of a bar-retained overdenture [20].

5. Conclusions

One year after loading, 4 mm ultrashort implants with a diameter of 4 mm could represent a good alternative to rehabilitate this specific edentulous atrophic maxilla. This approach could reduce operative times, possible complications, postsurgical morbidity and costs. Moreover, 4-mm-ultrashort implants tend to be more acceptable for the patient, compared to conventional rehabilitation, which includes more invasive surgical procedures. However, both the clinician and the patient should consider all the possible compromises of this procedure, which are mainly prosthetics. Additionally, this case will continue to be observed over time to report any changes in the results. Aware of the limitations of a case report, further RCTs with longer follow-ups and larger samples are needed to confirm the authors' results.

Consent statement

Patient gave written informed consent for all the procedures. Patient's figures were completely anonymized so a formal consent to show images was not elaborated.

Declaration of competing interest

Prof. Pietro Felice receives research grants from Global D. There are no other conflicts of interest to report.

Acknowledgments

The authors would like to thank Dr Cristiana Breccia and Dr Cesare Berti for the prosthetic phases.

References

- [1] Agliardi EL, Pozzi A, Stappert CF, Benzi R, Romeo D, Gherlone E. Immediate fixed rehabilitation of the edentulous maxilla: a prospective clinical and radiological study after 3 years of loading. *Clin Implant Dent Relat Res* 2014;16:292–302.
- [2] Esposito M, Felice P, Barausse C, Pistilli R, Grandi G, Simion M. Immediately loaded machined versus rough surface dental implants in edentulous jaws: one-year postloading results of a pilot randomised controlled trial. *Eur J Oral Implant* 2015;8:387–96.
- [3] Menini M, Signori A, Tealdo T, Bevilacqua M, Pera F, Ravera G, Pera P. Tilted implants in the immediate loading rehabilitation of the maxilla: a systematic review. *J Dent Res* 2012;91:821–7.
- [4] Maló P, de Araújo Nobre M, Lopes A, Ferro A, Nunes M. The All-on-4 concept for full-arch rehabilitation of the edentulous maxillae: a longitudinal study with 5–13 years of follow-up. *Clin Implant Dent Relat Res* 2019;21:538–49.
- [5] Esposito M, Felice P, Worthington HV. Interventions for replacing missing teeth: augmentation procedures of the maxillary sinus. *Cochrane Database Syst Rev* 2014;5:1–70.
- [6] Chiapasco M, Casentini P, Zaniboni M. Bone augmentation procedures in implant dentistry. *Int J Oral Maxillofac Implants* 2009;24:237–59.
- [7] Urban IA, Jovanovic SA, Lozada JL. Vertical ridge augmentation using guided bone regeneration (GBR) in three clinical scenarios prior to implant placement: a retrospective study of 35 patients 12 to 72 months after loading. *Int J Oral Maxillofac Implants* 2009;24:502–10.
- [8] Lozada J, Proussaefs P. Clinical radiographic, and histologic evaluation of maxillary bone reconstruction by using a titanium mesh and autogenous iliac graft: a case report. *J Oral Implantol* 2002;28:9–14.
- [9] Pistilli R, Felice P, Piatelli M, Nisii A, Barausse C, Esposito M. Blocks of autogenous bone versus xenografts for the rehabilitation of atrophic jaws with dental implants: preliminary data from a pilot randomised controlled trial. *Eur J Oral Implant* 2014;7:153–71.
- [10] Dellavia C, Giammattei M, Carmagnola D, Musto F, Canciani E, Chiapasco M. Iliac crest fresh-frozen allografts versus autografts in oral pre-prosthetic bone reconstructive surgery: histologic and histomorphometric study. *Implant Dent* 2016;25:731–8.
- [11] Davó R, Felice P, Pistilli R, Barausse C, Marti-Pages C, Ferrer-Fuertes A, Ippolito DR, Esposito M. Immediately loaded zygomatic implants vs conventional dental implants in augmented atrophic maxillae: 1-year post-loading results from a multicentre randomised controlled trial. *Eur J Oral Implant* 2018;11:145–61.

- [12] Esposito M, Barausse C, Balercia A, Pistilli R, Ippolito DR, Felice P. Conventional drills vs piezoelectric surgery preparation for placement of four immediately loaded zygomatic oncology implants in edentulous maxillae: results from 1-year split-mouth randomised controlled trial. *Eur J Oral Implant* 2017;10:147–58.
- [13] Araujo RZ, Santiago Júnior JF, Cardoso CL, Benites Condezo AF, Moreira Júnior R, Curi MM. Clinical outcomes of pterygoid implants: systematic review and meta-analysis. *J Cranio-Maxillo-Fac Surg* 2019;47:651–60.
- [14] Esposito M, Barausse C, Pistilli R, Sammartino G, Grandi G, Felice P. Short implants versus bone augmentation for placing longer implants in atrophic maxillae: one-year post-loading results of a pilot randomised controlled trial. *Eur J Oral Implant* 2015;8:257–68.
- [15] Esposito M, Cannizzaro G, Barausse C, Cosci F, Soardi E, Felice P. Cosci versus Summers technique for crestal sinus lift: 3-year results from a randomised controlled trial. *Eur J Oral Implant* 2014;7:129–37.
- [16] Felice P, Barausse C, Pistilli V, Piattelli M, Ippolito DR, Esposito M. Posterior atrophic jaws rehabilitated with prostheses supported by 6 mm long × 4 mm wide implants or by longer implants in augmented bone. 3-year post-loading results from a randomised controlled trial. *Eur J Oral Implant* 2018;11:175–87.
- [17] Esposito M, Barausse C, Pistilli R, Checchi V, Diazzi M, Gatto MR, Felice P. Posterior jaws rehabilitated with partial prostheses supported by 4.0 × 4.0 mm or by longer implants: four-month post-loading data from a randomised controlled trial. *Eur J Oral Implant* 2015;8:221–30.
- [18] Checchi V, Felice P, Zucchelli G, Barausse C, Piattelli M, Pistilli R, Grandi G, Esposito M. Wide diameter immediate post-extractive implants vs delayed placement of normal-diameter implants in preserved sockets in the molar region: 1-year post-loading outcome of a randomised controlled trial. *Eur J Oral Implant* 2017;10:263–78.
- [19] Bolle C, Felice P, Barausse C, Pistilli V, Trullenque-Eriksson A, Esposito M. 4 mm long vs longer implants in augmented bone in posterior atrophic jaws: 1-year post-loading results from a multicentre randomised controlled trial. *Eur J Oral Implant* 2018;11:31–47.
- [20] Boven GC, Meijer HJA, Vissink A, Raghoobar GM. Maxillary implant overdentures retained by use of bars or locator attachments: 1-year findings from a randomized controlled trial. *J Prosthodont Res* 2020;64:26–33.