ALMA MATER STUDIORUM
UNIVERSITÀ DI BOLOGNA

ARCHIVIO ISTITUZIONALE
DELLA RICERCA

Alma Mater Studiorum Università di Bologna
Archivio istituzionale della ricerca

Three dimensional bone mineral density changes in the femur over 1 year in primary total hip arthroplasty patients

This is the submitted version (pre peer-review, preprint) of the following publication:

Published Version:
Gislason M.K., Lupidio F., Jonsson H., Cristofolini L., Esposito L., Bifulco P., et al. (2020). Three dimensional bone mineral density changes in the femur over 1 year in primary total hip arthroplasty patients. CLINICAL BIOMECHANICS, 78, 1-6 [10.1016/j.clinbiomech.2020.105092].

Availability:
This version is available at: https://hdl.handle.net/11585/808666 since: 2021-02-27

Published:
DOI: http://doi.org/10.1016/j.clinbiomech.2020.105092

Terms of use:

Some rights reserved. The terms and conditions for the reuse of this version of the manuscript are specified in the publishing policy. For all terms of use and more information see the publisher's website.

This item was downloaded from IRIS Università di Bologna (https://cris.unibo.it/).
When citing, please refer to the published version.

(Article begins on next page)

12 October 2024

This is the pre-peer-review manuscript (PRE-print) of:

Clin Biomech (Bristol, Avon). 2020 Aug;78:105092.

Three dimensional bone mineral density changes in the femur over 1 year in primary total hip arthroplasty patients

Magnus Kjartan Gislason [1], Francesca Lupidio [2], Halldór Jónsson Jr [3], Luca Cristofolini [4], Luca Esposito [5], Paolo Bifulco [6], Massimiliano Fraldi [5], Paolo Gargiulo [7]

PMID: 32590143 DOI: 10.1016/j.clinbiomech.2020.105092

The final published version is available online at: https://doi.org/10.1016/j.clinbiomech.2020.105092

Rights / License:

The terms and conditions for the reuse of this version of the manuscript are specified in the publishing policy. For all terms of use and more information see the publisher's website.

Three dimensional bone mineral density changes in the femur over 1 year in primary total hip arthroplasty patients

Magnus Gislason, Francesca Lupidio, Halldór Jónsson Jr, Luca Cristofolini, Luca Esposito, Paolo Bifulco, Massimiliano Fraldi, Paolo Gargiulo

Introduction

Aseptic loosening causing micromotion of the prosthesis is one of the primary reason for total hip revision. Inserting a metal stem into the femoral canal brings on changes in the mechanical loading behaviour of the bone tissue which will adapt accordingly. As hypothesized by the Wolff's law [Barak 2011], bone remodels itself in response to the load it is exposed to and the stresses will be primarily absorbed by the stiffer material, namely the metal implant and loading on the surrounding bone tissue will decrease. The remodelling procedure of the bone depends on implant size, geometry, mechanical properties and fixation type, that is whether the implant is cemented into the femoral canal using a PMMA cement or the implant is press fitted into the femoral canal and the fixation is achieved between the interference fit between the bone and prosthesis [Tavakkoli]. Huiskes [1993] proposed a simple formula that would predict the overall fraction of bone loss.

$$m_r = \frac{\mu}{1+\mu}$$

where μ is a function of the ratio between the stem and bone rigidities as well as stimulation levels, defined as

$$\mu = c\,(1-s)\frac{E_s}{\rho_a^3}$$

where E_s is the stem modulus in MPa, ρ_a is the apparent density of the femur, s represents the stimulation levels as predicted by the principle of the mean effective strain by Frost [1987] and c is a constant.

When deciding upon fixation method, the surgeon bases the decision generally on the age, gender of the patients as well as professional experience. Both fixation methods have advantages and disadvantages associated to them. The risk of the interference fit is that there is a possibility of a periprosthetic fracture during the surgery in the case of un-cemented implant [Spring et al, 2018, Esposito et al., 2018], whereas the risk of the cemented method is that should a revision surgery be required, it can become a challenge to extract the prosthesis and the cement without compromising the existing bone stock [Roussota et al 2018]. Another risk factor for the cemented method can be that proximal loosening of the implant due to cement fracture can cause a cantilever effect on the distal aspect of the prosthesis, creating dangerously high levels of bending stresses [Bolland et al].

In accordance to Wolff's las, it has been noted that post-operatively, there is a distinct degradation of the bone mineral density (BMD), in particular around the proximal aspect of the femur [Venesmaa et al, 2012]. The connection between the mechanical properties of bone and BMD has been demonstrated both in terms of stiffness [Keller] and strength [Lee]. Analysing the distribution of the BMD can therefore give important information about the structural integrity of the bone. Loss of BMD will make the bone weaker and more susceptible to fractures, but can also compromise the mechanical stability of an implanted prosthesis leading to revision surgery. Little is known about the long term remodelling behaviour of the implanted femur and how the bone adapts to the new loading regime as it

will be depend on many different factors such as bone strength prior to surgery, activity levels, etc. Measurements on BMD values on spinal cord injury patients (SCI) have shown that bone loss in the lower limb, due to mechanical disuse reach a steady state with time [Frotzler et al 2008] and that bone loss pattern between individuals vary. There is therefore a distinct difference the BMD distribution between SCI patients in early stages (< 4 years post injury) of the disease and the established SCI patients (≥4 years post injury) which can be seen in the increased volume of lower density bone [Coupaud et al 2017]. By carrying out analysis of the bone density, it is possible to identify patients at risk of fracture. Similarly, it can be argued that by analysing the bone gain and loss in the THA patients, it is possible to extract those subjects that are showing unusually high values of bone loss and therefore be able to adapt physiotherapy or exercise regime accordingly. The primary aim of total hip arthroplasty is to alleviate pain and restore the patient's movement. Post operatively it is expected that the daily activity of the patient increases thus creating an improved distribution of joint reaction forces acting on the hip. Measurements have shown that the forces acting on the hip joint post-operatively resemble the forces predicted using a musculoskeletal model based on able-bodied subjects [Wesseling et al 2018, Heller et al 2001].
Computational models have been created to try to predict 2 year bone remodelling behaviour [Levadnyi et al, 2017], where it was demonstrated how different designs of implants dictate different bone remodelling profiles within the femur [Fraldi et al., 2010]. The results showed that theoretically hip resurfacing would have a bone remodelling profile that most resembles the one seen in the healthy femur. However, clinical data suggest that hip resurfacing has higher revision rates than total hip arthroplasty after 10 years [Jacobs et al 2018]. Other computational studies have looked at the influence of the short stemmed implants on the bone remodelling (Lerch et al, 2019), where decrease in bone mineral density was predicted at the proximal femur but also areas where bone had gained density [Iupariello et al 2019]. Computational studies can become difficult to validate in vivo, but by carrying out a CT analysis on the stem and the surrounding bone tissue over a period of time [van den Wyngaert et al 2018] where quantification of tissue density and morphological changes of the bone can be carried out with a high degree of automaticity [Esposito et al., 2015]. A few radiological studies have been carried out to monitor the bone quality post-operatively in THA subjects, but mostly using visual inspection to assess the state of the bone [Sanli et al, 2016]. In 1997 Neander et al [1997], carried out CT analysis of BMD at the middle and distal part of the femur of THA patients and compared with a control group to evaluate bone loss in those regions. Measurements on BMD in total knee replacement patients has been carried out, quantifying the BMD changes in the distal femur but using the conventional DXA scans to quantify BMD values [Kim et al, 2014, Beaupre et al 2015, Thomas et al 2019]. Little has been researched in terms of bone quality on THA patients post-operatively where the bone loss has been quantified both in terms of density values and the three dimensional location of resorption.

In the presented study, a cohort of 50 subjects undergoing primary total hip arthroplasty was examined over a period of 1 year and how the bone mineral changes affected the bone mineral density distribution in the femur, looking at both males and females as well as a cemented and uncemented fixation methods. The work aims to identify the regions in which the highest level of bone remodelling takes place, both by analysing the femur in 3D as well as looking at the BMD changes from distal to proximal. The methodology presented in the study is unique when looking at BMD changes in total joint replacement patients as it compares bone quality

in 3D whereas other studies have only looked at two dimensional distribution. This methodology provides basis for more in-depth analysis as a part of a routine check up on patients.

Methods

Fifty subjects were recruited for the study undergoing primary THA, both undergoing uncemented and cemented operation, where only one type of femoral stem was used for each group. For the uncemented group, a CLS Spotorno stem made from a titanium alloy was used and for the uncemented group and the MS 30 stem made from stainless steel was used for the cemented group.

The distribution between the cohorts can be seen in Table 1.

Table 1: Distribution within the groups

	Females		**Males**	
	Number	Age [years]	Number	Age [years]
Uncemented	10	57.6	20	51.9
Cemeted	17	66.7	3	66.3

Spiral CT scans were taken of the patients‘ femurs, ranging from the anterior superior iliac spine to the diaphysis of the femoral shaft, at 24 hours post- operatively and 1 year post-operatively. The tube voltage was 120 KVp. The in-plane resolution was 0.6mm x 0.6mm and the slice thickness was 1mm.

The scans were calibrated using a quasar phantom to facilitate the linear conversion of the Hounsfield units (HU) to bone mineral density (BMD) values in g/cm^3. The linear relationship can be described as [Gargiulo et al]

$$BMD = 9.02 * 10^{-4} * HU + 0.0419$$

The scans were imported into Mimics (Materialize) in order to carry out the bone segmentation. As the CT scans were carried out post-operatively, the metal from the implant caused image artefacts [Barrett] therefore causing a high degree of noise around the implant.

By applying image reduction, it is possible to improve the quality of the image so that the information stored in the pixels in the surrounding tissues is not lost [Wellenberg].

An algorithm was used to reduce the artefacts and reconstruct the images [Boas]. Figure 1 shows the a CT slice before and after the image artefact reduction

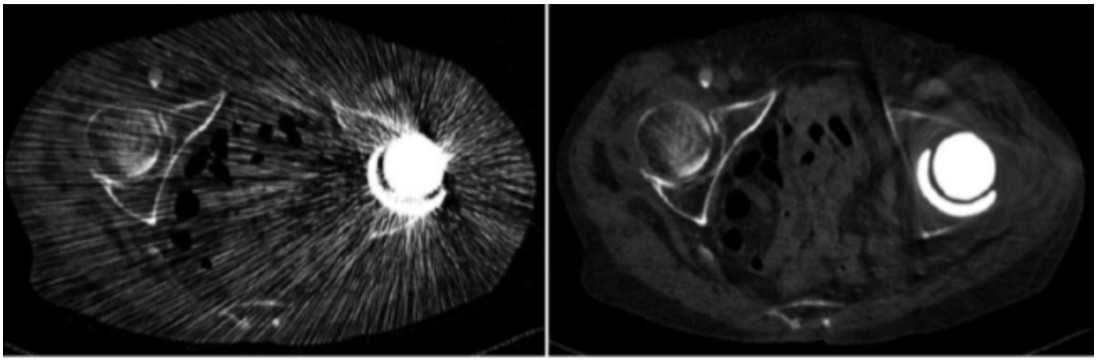

Figure 1: Image artefact reduction

The two sets of scans were re-aligned by identifying anatomical landmarks on the femur and the by using the distal end of the stem to superimpose the scans onto each other. Reslicing was then carried out in order to have the slices identical between the 24h post-op scan and the 1 year post-op scan. The reslicing was carried out by identifying the following anatomical landsmarks

- Distal end of the stem
- Distal end of the attachment site of Gluteus Minimus
- Superior aspect of the Greater Trochanter
- Lesser Trochanter
- Ischial Tuberosity
- Protuberance of pectineal line

Using these anatomical landmarks on the CT scans it was possible to align and superimpose the two scans onto each other with the slices in the same positions. By doing that it was possible to compare different regions within the two femur models in identical frame of referece.

After the alignment, boolean operations were carried out on the two femur models using subtraction. The gain and loss were calucated using the following criteria.

$$Gain = \begin{cases} GV_{1y} - GV_{24h} & , GV_{1y} > GV_{24h} \\ 0 & , GV_{1y} \leq GV_{24h} \end{cases}$$

$$Loss = \begin{cases} GV_{24h} - GV_{1y} & , GV_{24h} > GV_{1y} \\ 0 & , GV_{24h} \leq GV_{1y} \end{cases}$$

Where the difference in BMD values between individual voxels is then compared and categorized into gain and loss. BMD changes <0.01 g/cm^3 are not considered to have changed over the period of 1 year.

Figure 2 shows the overall workflow for the analysis

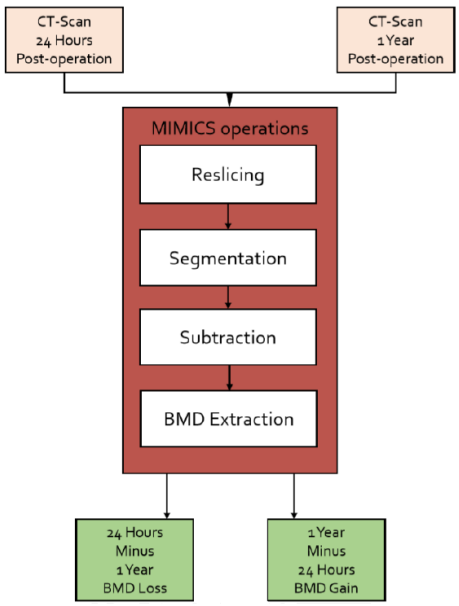

Figure 2: Study workflow

Each bone was normalized into 100 slices from proximal to distal and the total bone gain and bone loss calculated in each slice. The bone gain and loss for each slice is the summation of all the pixels containing gain or loss as described from the equations above. The bone gain and loss was finally mapped along the inferior-superior axis of the femur in 2D as well as represented in 3D.

The analysis was carried out on both the operarated leg and on the healthy leg.

Results

The bone gain and loss was represented as the average over a slice of 1mm along the length of the femur, ranging from 1cm below the distal end of the stem to the proximal aspect of the greater trochanter. All the distances were normalized from 0% at the distal end to 100% at the proximal end. The average results between the subjects in the cemented group and the uncemented group, males and females can be seen in Figure 3.

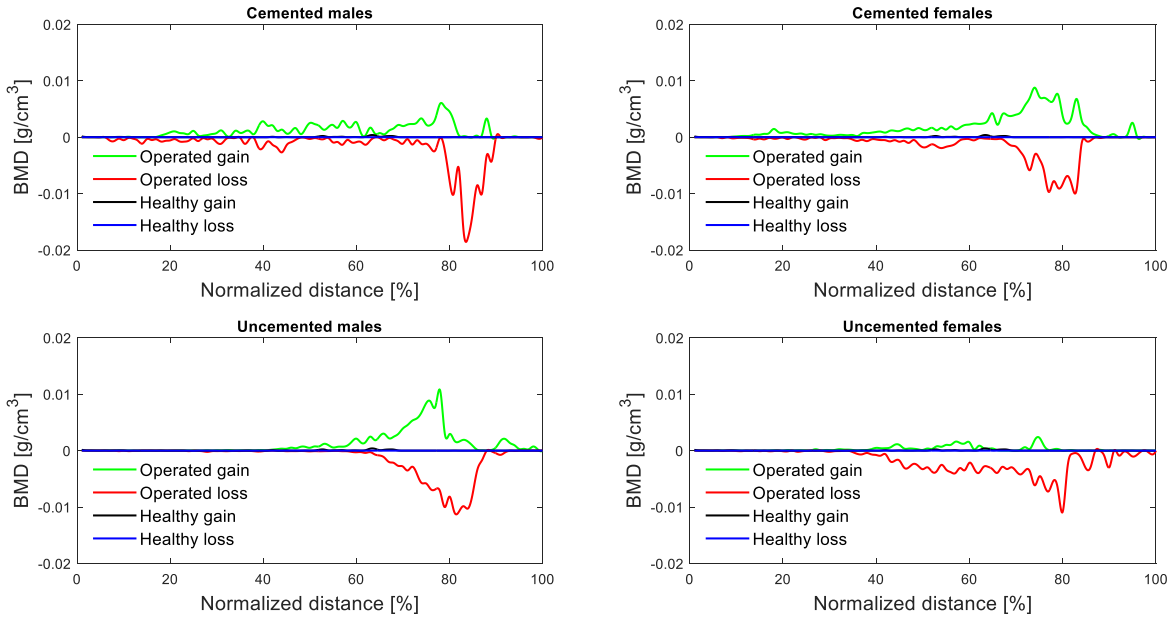

Figure 3. Results for the bone gain and loss for the cemented and the uncemented group between males and females for both the operated leg and the healthy leg

From Figure 3, it can be seen how the bone remodelling varies between fixation methods and gender. The results for the healthy leg demonstrate that there is little or no changes in the overall BMD values for each slice, indicating that the remodelling process is more uniform over time and that no drastic localised changes are occurring. From the figure it can also be seen how the groups respond differently to the remodelling of the femur, where as expected the largest degree of bone gain and loss occurs at the proximal aspect.

There was a high degree of variability between subjects on an individual level. Figure 4 shows the difference between subjects within each group.

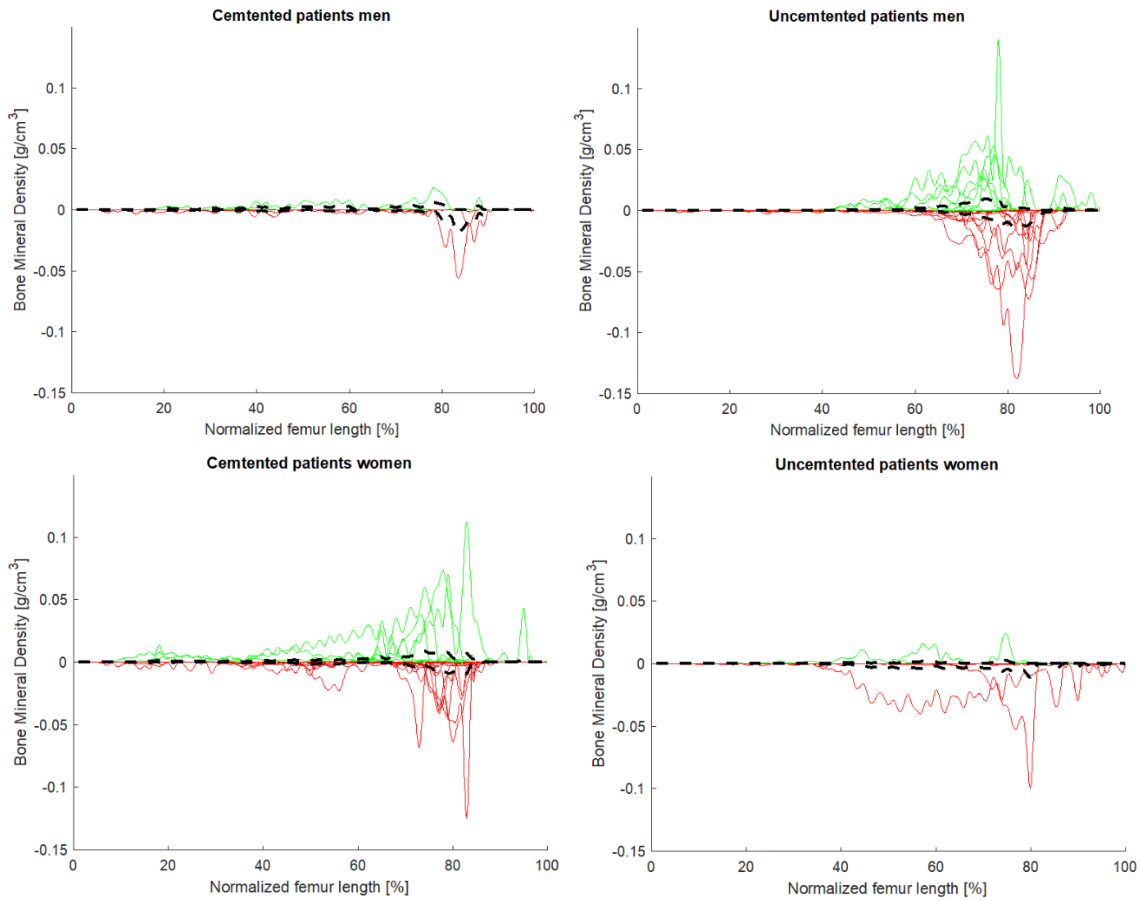

Figure 4. Differences in the bone gain and loss profiles between genders and fixation methods

The net gain and loss was calculated for each group. The overall gain and loss was calculated by numerically integrating the gain curve from 0% (distal) to 100% (proximal) for each subject. The average values were then calculated for each group (gender and fixation method). The values can be seen in Table 1.

Table 1: Gain and loss between males and females for both cemented and uncemented fixation.

	Cemented [g/cm^3*10^{-3}]			Uncemented [g/cm^3*10^{-3}]		
	Gain	Loss	Net gain(+) / loss (-)]	Gain	Loss	Net gain (+) /loss (-)
Males operated leg	108.05	149.32	-41.27	133.87	158.28	-24.42
Males healthy leg	0.30	0.92	-0.62	8.47	2.87	+5.60
Females operated leg	166.76	122.61	+44.16	24.78	171.42	-146.64
Females healthy leg	10.49	13.12	-2.64	3.55	4.17	-0.62

For all 4 groups it can be seen that bone loss occurs on the operated leg, primarily around the proximal aspect of the femur. For the healthy leg, minor changes can be seen in terms of bone

gain and bone loss as the biomechanics of the non-operated femur represent a more natural remodelling process than in the operated femur.

Additionally, three dimensional representation of the BMD changes was created, the results for three separate subjects can be seen in Figure 5, where the green colour represents the increase in BMD and the red colour, the decrease in BMD. The subjects are as follows:

- Subject 1: Male aged 50, uncemented
- Subject 2: Male aged 42, uncemented
- Subject 3: Female aged 60, uncemented.

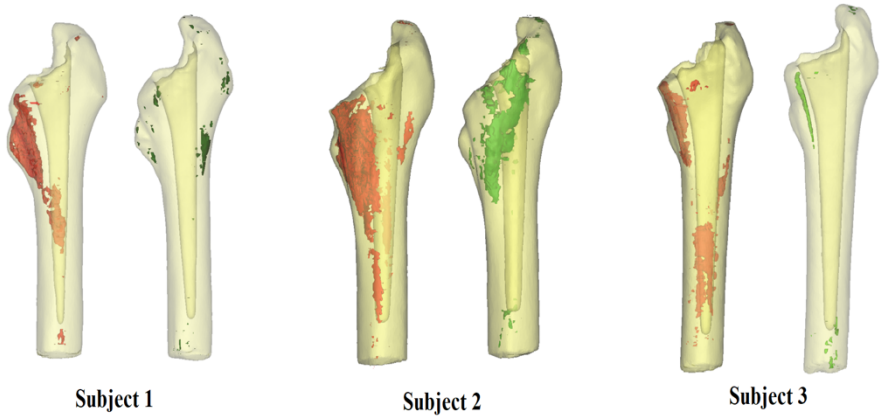

Figure 5: Three dimensional representation of the bone gain and loss calculations for 3 selected patients, showing varying degree of bone remodelling between individuals.

From Figure 5, it can be seen how the density patterns occur differently between patients. No relationship was found between bone gain and loss depending on age. Figure 6 shows the net bone gain and loss between the four groups as a function of age. The net bone gain and loss was calculated as the difference between the overall bone gain values for the whole femur and the loss values. A positive value represented gain and a negative value loss.

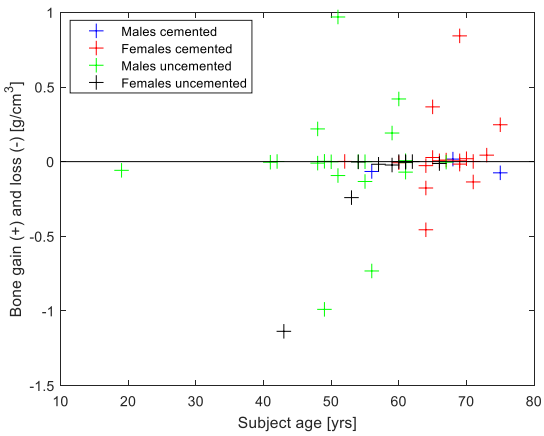

Figure 6: Net bone gain and loss as a function of age.

Most of the uncemented subjects were younger than the cemented patients, but from Figure 6, it can be seen that bone loss is not directly connected to age.

Discussion

Understanding the behaviour of bone remodelling between cemented and uncemented fixation methods is an important clinical knowledge when determining implantation methods for patients. From the results it can be seen how different fixation mechanisms and individual differences between the patients dictate the bone loss mechanism. From the results it can be seen that no correlation exists between overall bone quality and age, although the uncemented subjects in the study tended to be younger than the ones in the cemented group. This lack of correlation between bone quality and age, gender and fixation methods, emphasises the point that there is a need for a subject specific analysis of the three dimensional BMD changes in the post operative clincial assessment of patients. Many studies base the BMD mapping on single DXA scans which fail to obtain as detailed spatial resolution with regards to the bone remodelling processes as the method presented in this study. Although the results from this study show that the are around the lesser trochanter is generally subjected to bone loss, there are other areas both on the medial and lateral aspect of the femur that demonstrate similar behaviour that only can be quantified using three dimensional analysis.

From the results it can be seen how the primary bone loss occurs around the proximal region of the femur, which is in agreement with findings from other studies [Taylor et al, Tapaninen et al], that have reported on BMD decrease in the calcar area using DXA and presenting their findings as a two dimensional density [g/cm^2]. Steens et al [2015] presented a 1 and 5 year follow up on patients receiving implants with short stems using DXA and reported 0.7% decrease in the density in the proximal medial aspect of the femur. That study also reported regions on the proximal lateral aspect of the femur increasing in BMD values which is in agreement with the results found on several subjects in this study. The clinical reasoning behind using DXA instead of CT for BMD analysis is mainly the radiation dose. The same methodology can be followed focussing on smaller regions of interests thus lowering the radiation dosage. Additionally this analysis can then be expanded onto mucsles as has been demonstrated by Edmunds et al [2018].

Using CT registration of multiple scans of the femur of the same subject, coupled with metal artefact reduction, can give an important information about what is happening within the bone on a voxel level. The methodology described would then allow for clinical assessment of each subject to give details on each patient against a cohort of subjects of similar age with the same implant type using the same surgical technique. The workflow described in this paper has the potential to be made more automatic segmentation methods and bony landmark registrations using computer vision methods described by Baek et al [2013] and Belal [2019]. Neural networks can additionally be used to analyse BMD in both healthy and osteoporotic subject using DICOM images in order to classify subjects into categories as has been demonstrated by Mohamed et al [2019]. With less degree of manual labour when it comes to analysing the BMD content of the femur, it will be possible to assess greater number of patients creating a large database containing three dimensional BMD changes in invididuals undergoing THA to

assess mechanical strength of the bone, but additionally this could be used to identify the subjects are have poor bone quality and are in risk of fracturing if falling. In the future, this database would serve as a decision tool in choosing the most correct implant method for each individual.

The three dimensional approach for asseessing BMD changes in THA patients described in the study is most in-depth analysis carried out on bone quality to date and the methodology presented will serve as a basis for prescribing appropriate rehabilitation strategies which can then help to prolong the time until revision surgery, increasing the quality of life for the patient.

Limitations

From the cohort demographics it can be seen that the number of subjects in each group, reflect the guidlines that surgeons choose younger subjects primarily for uncemented fixation and elderly subjects for a cemented one. The distribution between the 4 groups is not uniform and a distinct lack of subjects in the male cemented group. All subjects in the group had varying activity levels and no standard rehabilitation protocol was followed post-operatively. The results are dependent on the threshold chosen to represent at what density changes. The value 0.01 g/cm^3, was considered low enough to be able to incorporate the BMD changes. Further sensitivity analysis on the effects of the threshold level will be needed to be carried out.

Finally the study only looks at the remodelling process over a period of 1 year which is a comparatively short period of time compared to the overall lifespan of the prosthesis in-vivo.

References

1. Barak MM, Lieberman DE, Hublin JJ. A Wolff in sheep's clothing: Trabecular bone adaptation in response to changes in joint loading orientation. Bone, 2011, vol 49, pp: 1141-1151
2. Tavakkoli AP, Klika V, Bougherara H. Predicting bone remodeling in response to total hip arthroplasty: computational study using mechanobiochemical model. Journal Biomechanical Engineering, 2014, vol 136(5).
3. Huiskes R. Stress Shielding and Bone Resorption in THA: Clincial versus Computer Simulation Studies, Acta Orthopaedica Belgica, 1993, vol 51, pp:118-129
4. Frost HM. Vital hiomechanics. Proposed general concepts for skeletal adaptations to mechanical usage. Calc. Tissue Int., 1987, vol 42, pp:145-156.
5. Spring BD, Etkin CD, Shores PB, Gioe TJ, Lewallen DG, Boziz KJ: Perioperative Periprosthetic Femur Fractures are Strongly Correlated With Fixation Method: an Analysis From the American Joint Replacement Registry.The Journal of Arthroplasty, 2019, vol 34, pp:352-354.
6. Esposito L, Bifulco P, Gargiulo P, Gíslason MK, Cesarelli M, Iuppariello L, Jónsson H, Cutolo A, Fraldi M. Towards a patient-specific estimation of intraoperative femoral fracture risk. Computer Methods in Biomechanics and Biomedical Engineering, 2018
7. Roussota MA, Vlesa GF, Haddadb FS: The role of cemented stems in revision total hip arthroplasty. Seminars in Arthroplasty, 2018, vol 29, pp: 177-182
8. Bolland JRF, Wilson MJ, Howell JR, Hubble MJW, Timperley AJ, Gie GA. An Analysis of Reported Cases of Fracture of the Universal ExeterFemoral Stem Prosthesis. The Journal of Arthoplasty, 2017, vol 32, pp: 1318-1322

9. P. Venesmaa P, Vanninen E, Miettinen H, Kröger H. Periprosthetic bone turnover after primary total hip arthroplasty measured by single-photon emission computed tomography. Scandinavian Journal of Surgery, 2012, vol 101, pp:241–248
10. Keller TS, 1994 Predicting the compressive mechanical behavior of bone. J Biomech, 27(9): 1159-1168.
11. Lee DC, Hoffmann PF, Kopperdahl DL, Keaveny TM. Phantomless calibration of CT scans for measurement of BMD and bone strength—Inter-operator reanalysis precision, Bone, 2017, vol 103, pp:325-333
12. Frotzler A, Berger M, Knecht H, Eser P. Bone steady-state is established at reduced bone strength after spinal cord injury: A longitudinal study using peripheral quantitative computed tomography (pQCT), Bone, 2008, vol 43, pp: 549-555
13. Coupaud S, Gislason MK, Purcell M, Sasagawa K, Tanner KE. Patient-specific bone mineral density distribution in the tibia of individuals with chronic spinal cord injury, derived from multi-slice peripheral Quantitative Computed Tomography (pQCT) — A cross-sectional study. Bone, 2017, vol 97, pp:29-37
14. Wesseling M, Meyer C, Corten C, Desloovere K, Jonkers I. Longitudinal joint loading in patients before and up to one year after unilateral total hip arthroplasty, Gait and Posture, 2018, vol 61, pp: 117-124
15. Heller MO, Bergmann G, Deutetzbacher G, Durselen L, Pohl M, Claes L, Haas N, Duda GN.Musculo-skeletal loading conditions at the hip during walking and stair climbing, Journal of Biomechanics, 2001, vol 34, pp:883–893
16. Levadnyi I, Awrejcewicz J, Gubaua JE, Pereira JT. Numerical evaluation of bone remodelling and adaptation considering different hip prosthesis designs. Clinical Biomechanics, 2017, vol 50, pp:122-129.
17. Fraldi M, Esposito L, Perrella G, Cutolo A, Cowin SC. Topological optimization in hip prosthesis design, 2010, Biomech Model Mechanobiol, vol 9, pp:389–402
18. Jacobs H, McKenna R, Walter WL. Hip resurfacing: What does the Australian National Joint Registry say? Seminars in Arthroplasty, 2017, vol 28, pp:233-238.
19. Lerch M, Windhagen H, Kurtz AE, Budde S, Behrens BA, Bouguecha A, Almohallami A. 'Pre-launch' finite element analysis of a short-stem total hip arthroplasty system consisting of two implant types. Clinical Biomechanics, 2019, vol 61, pp:31-37
20. Iuppariello L, Esposito L, Gargiulo P, Gíslason MK, Jónsson Jr H, Sarno A, Cristofolini L, Bifulco P. A CT-based method to compute femur remodelling after Total Hip Arthroplasty. Journal of Medical Engineering and Physics, 2019, submitted
21. van den Wyngaert T, Paycha F, Strobel K, Kampen WU, Kuwert T, van der Bruggen W, Gnanasegaran G. SPECT/CT in Postoperative Painful Hip Arthroplasty. Seminars in Nuclear Medicine, 2018, vol48(5), pp:425-438
22. Esposito L, Bifulco P, Gargiulo P, Fraldi M. Singularity-free finite element model of bone through automated voxel-based reconstruction. Computer Methods in Biomechanics and Biomedical Engineering, 2015, vol 19(3), pp:1-6
23. Sanli I, Arts JJC, Geurts J. Clinical and Radiologic Outcomes of a Fully Hydroxyapatite-Coated Femoral Revision Stem: Excessive Stress Shielding Incidence and its Consequences. The Journal of Arthroplasty, 2016, Vol 31(1), pp:209-214.
24. Neander G, Sivers Kv, Adolphson P, Dahlborn M, Dalén N. The Journal of Arthroplasty Vol. 14 No. 1 1999 An Evaluation of Bone Loss After Total Hip Arthroplasty for Femoral Head Necrosis After Femoral Neck Fracture A Quantitative CT Study in 16 Patients, The Journal of Arthroplasty, 1999, Vol 14(1), pp: 64-70.

25. Kim KK, Won YY, Heo YM, Lee DH, Yoon JY, Sung WS. Changes in Bone Mineral Density of Both Proximal Femurs after Total Knee Arthroplasty, Clinics in Orthopedic Surgery 2014, vol 6, pp:43-48.
26. Beaupre LA, Rezansoff A, Clark M, Jen H, Lambert RG, Majumdar S. Bone Mineral Density Changes in the Hip and Spine of Men and Women 1-Year After Primary Cemented Total Knee Arthroplasty: Prospective Cohort Study, The Journal of Arthroplasty, 2015, vol 30, pp:2185–2189.
27. Thomas B, Binkley N, Anderson PA. Krueger D. DXA Measured Distal Femur Bone Mineral Density in Patients After Total Knee Arthroplasty: Method Development and Reproducibility. Journal of Clinical Densitometry: Assessment & Management of Musculoskeletal Health, 2019, vol 22(1), pp:67-73.
28. Gargiulo P, Petursson T, Magnusson B, Bifulco P, Cesarelli M, Izzo GM, Magnusdottir G, Halldorsson G, Ludvigsdttir GK, Tribel J, Jonsson H. Assessment of Total Hip Arthroplasty by Means of Computed Tomography 3D Models and Fracture Risk Evaluation. Artificial Organs 2013, vol 37, pp:567-573.
29. Barrett JF, Keat N. Artifacts in CT: Recognition and Avoidance. RadioGraphics, 2004, vol 24, pp:1679-1691.
30. Wellenberg RHH, Hakvoort ET, Slump CH, Boomsma MF, Maas M, Streekstra GJ. Metal artifact reduction techniques in musculoskeletal CT-imaging, European Journal of Radiology, 2018, vol 107, pp: 60-69.
31. Boas FE, Fleischmann D. Evaluation of two iterative techniques for reducing metal artefacts in computed tomography. Radiology. 2011, vol 259(3), pp: 894-902.
32. Taylor WR, Szwedowski TD, Heller MO, Perka C, Matziolis G, Muller M, Janshen K, Duda G. The difference between stretching and splitting muscle trauma during THA seems not to play a dominant role in influencing periprosthetic BMD changes. Clinical Biomechanics, 2012, vol 27(8), pp: 813-818.
33. Tapaninen T, Kroger H, Vensemaa P. Periprosthetic BMD after cemented uncemented total hip arthroplasty: a 10-year follow-up study. Journal of Orthopaedic Science, 2015, vol 25(4), pp:657-662.
34. Steens W, Boettner F, Bader R, Skripitz R, Schneeberger A. Bone mineral density after implantation of a femoral neck hip prosthesis – a prospective 5 year follow-up. BMC Musculoskeletal Disorders, 2015, 16:192
35. Edmunds E, Gíslason MK, Sigurðsson S, Guðnason S, Harris T, Carraro U, Gargiulo P. Advanced quantitative methods in correlating sarcopenic muscle degeneration with lower extremity function biometrics and comorbidities. PloS one, 2018, vol 13(3).
36. Baek SY, Wang JH, Song I, Lee K, Lee J, Koo S. Automated bone landmarks prediction on the femur using an atomical deformation technique. Computer-Aided Design, 2013, vol 45, pp:505-510
37. Belal SL, Sadik M, Kaboteh R, Enquist O, Ulén J, Poulsen MH, Simonsen J, Høilund-Carlsen PF, Edenbrandt L, Trägårdh E. Deep learning for segmentation of 49 selected bones in CT scans: First step in automated PET/CT-based 3D quantification of skeletal metastases. European Journal of Radiology, 2019, vol 113, pp: 89-95.
38. Mohamed EI, Meshref RA, Abdel-Mageed SM, Moustafa MH, Badawi MI, Darwish SH, A Novel Morphological Analysis of DXA-DICOM Images by Artificial Neural Networks for Estimating Bone Mineral Density in Health and Disease, Journal of Clinical Densitometry, 2019, Vol 22(3), pp:382-390.