

Alma Mater Studiorum Università di Bologna
Archivio istituzionale della ricerca

Different Hydraulic Constructs to Optimize the Venous Drainage of DIEP Flaps in Breast Reconstruction:
Decisional Algorithm and Review of the Literature

This is the final peer-reviewed author's accepted manuscript (postprint) of the following publication:

Published Version:

Different Hydraulic Constructs to Optimize the Venous Drainage of DIEP Flaps in Breast Reconstruction:
Decisional Algorithm and Review of the Literature / Pignatti, Marco; Pinto, Valentina; Giorgini, Federico A;
Lozano Miralles, Maria Elisa; D'Arpa, Salvatore; Cipriani, Riccardo; De Santis, Giorgio. - In: JOURNAL OF
RECONSTRUCTIVE MICROSURGERY. - ISSN 0743-684X. - STAMPA. - 37:3(2021), pp. 216-226. [10.1055/s-
0040-1716349]

Availability:

This version is available at: <https://hdl.handle.net/11585/769971> since: 2020-12-30

Published:

DOI: <http://doi.org/10.1055/s-0040-1716349>

Terms of use:

Some rights reserved. The terms and conditions for the reuse of this version of the manuscript are
specified in the publishing policy. For all terms of use and more information see the publisher's website.

This item was downloaded from IRIS Università di Bologna (<https://cris.unibo.it/>).
When citing, please refer to the published version.

(Article begins on next page)

This the post-print version of:

Pignatti M, Pinto V, Giorgini FA, Lozano Miralles ME, D'Arpa S, Cipriani R, De Santis G. Different Hydraulic Constructs to Optimize the Venous Drainage of DIEP Flaps in Breast Reconstruction: Decisional Algorithm and Review of the Literature. J Reconstr Microsurg. 2020 Sep 1

Final version available: <https://doi.org/10.1055/s-0040-1716349>

Rights / License:

The terms and conditions for the reuse of this version of the manuscript are specified in the publishing policy. For all terms of use and more information see the publisher's website.

This item was downloaded from IRIS Università di Bologna (<https://cris.unibo.it/>)

When citing, please refer to the published version.

Different hydraulic constructs to optimize the venous drainage of DIEP flaps in breast reconstruction. Decisional algorithm and review of the literature

Marco Pignatti ^a, Valentina Pinto ^b, Federico A. Giorgini ^{b,d}, Maria Elisa Lozano Miralles ^{b,d}, Salvatore D'Arpa ^c, Riccardo Cipriani ^b, Giorgio De Santis ^d

M. Pignatti, MD, FEBOPRAS

Plastic Surgery, Policlinico di Sant'Orsola - DIMES, University of Bologna, Italy

V. Pinto, MD, PhD

Plastic Surgery, Policlinico di Sant'Orsola - Bologna, Italy

F. A. Giorgini, MD

Plastic Surgery, Policlinico di Sant'Orsola - Bologna, Italy

&

Plastic Surgery, Policlinico di Modena, University of Modena and Reggio Emilia, Italy

M. E. Lozano Miralles, MD

Plastic Surgery, Policlinico di Sant'Orsola - Bologna, Italy

&

Plastic Surgery, Policlinico di Modena, University of Modena and Reggio Emilia, Italy

S. D'Arpa, MD, PhD

Plastic and Reconstructive Surgery, Department of Surgical, Oncological and Oral Sciences (DICHIRONS). University of Palermo, Italy

R. Cipriani, MD

Plastic Surgery, Policlinico di Sant'Orsola - Bologna, Italy

G. De Santis, MD

Plastic Surgery, Policlinico di Modena, University of Modena and Reggio Emilia, Italy

Corresponding author

Marco Pignatti, MD, FEBOPRAS

Plastic Surgery, Policlinico di Sant'Orsola - DIMES, University of Bologna, Italy

Via Massarenti, 9
40138 Bologna, Italy
mrpignatti@gmail.com

Different hydraulic constructs to optimize the venous drainage of DIEP flaps in breast reconstruction. Decisional algorithm and review of the literature

ABSTRACT

Background

Venous congestion is the most common perfusion related complication of DIEP flap.

Several hydraulic constructs can be created for venous super-drainage in case of flap venous engorgement or as a preventive measure.

These can be classified based on the choice of the draining vein of the flap, either a second DIEV or a SIEV, and of the recipient vein, either a vein of the chest or the DIEV.

Methods

We conducted a comprehensive systematic literature review in Medline, Scopus, EMBASE, Cochrane Library, and Google Scholar to find publications that reported on venous congestion in DIEP flap. The keywords used were DIEP Flap, breast reconstruction, venous congestion, supercharging, super-drainage, SIEV and DIEV.

Results

Based on the studies found in the literature, we developed an algorithm to guide the surgeon's decision when choosing the veins for the super-drainage anastomosis.

Conclusion

Several alternatives for venous anastomosis in super-drainage are available. We propose an algorithm to simplify the choice. The use of the ipsilateral SIEV to be connected to a vein of the chest appears to be advantageous. The anatomical position that allows the easiest anastomosis dictates which chest vein to favor.

Keywords: DIEP flap, superdrainage, algorithm, review

INTRODUCTION

Vascular-related complications represent the main risk of failure of autologous breast reconstruction with the Deep Inferior Epigastric artery Perforator (DIEP) flap^{1,2}.

Total flap failure is reported to occur in up to 5 % of cases, while partial failures are diagnosed in approximately 17% of patients³⁻⁵ and include fat necrosis and partial flap necrosis, at times leading to unsatisfactory aesthetic results, and even return to the operating room⁴.

The most common vascular impairment of the flap is venous congestion.

Its clinical manifestations range from subtle signs of superficial veins turgidity, to faster capillary refill or darker discoloration at the flap periphery, to complete change in color of the skin island from pink to purple.

Some causes of venous congestion, such as occlusion of the microsurgical anastomosis, vessel torsion or kinking, or a flap that is oversized for the chosen perforator are reversible. In these cases, the prompt solution of the problem can reverse the clinical signs of congestion.¹

When the causes of venous congestion are not reversible, as in the case of an unfortunate choice of perforator, a pedicle damaged during dissection, or even the unfavorable anatomy of the venous system¹, the use of flap venous supercharging (also called super-drainage) is of great help to solve the problem, as widely reported in the literature.⁶⁻¹⁶

.

When venous super-drainage of the flap is chosen, to treat or to prevent venous congestion, the adjunctive anastomosis can be performed in numerous ways depending on the choice of the vessels to be connected.

Most of the articles in the literature, for anatomical and physiological reasons^{8,17}, favor the use of the superficial inferior epigastric vein (SIEV) of the flap as donor^{1,17,19}.

In this study, we reviewed the pertinent literature and, based on the present knowledge and on our experience, we propose an algorithm to help the surgeon in the choice of the veins to anastomose in different settings.

METHODS

We conducted a comprehensive systematic literature review in June 2019, and again in April 2020, searching major scientific databases (Medline, Scopus, EMBASE, Cochrane Library, and Google Scholar) to find publications that reported on venous congestion in DIEP flap.

To reduce inclusion bias, two of the Authors (VP and FG) performed, separately, the initial article search and selection with pertinent keywords ("Deep inferior epigastric perforator" OR "DIEP" AND "flap" [All Fields] AND venous congestion [All Fields] AND ("additional anastomosis"[Subheading] AND "superficial inferior epigastric vein"[All Fields] OR "SIEV"[All Fields] AND "supercharging" OR "superdrain" OR "super-drainage"). (Figure 1)

Duplicated articles, isolated abstracts, case reports, correspondence and letters were excluded and only full-text articles in English regarding DIEP flaps and venous congestion were considered.

RESULTS

After thorough evaluation of all the articles retrieved on the subject of venous super-drainage, we have come down to 11 studies on various functional factors⁶⁻¹⁶, 18 studies reporting on the results of a single center on hydraulic constructs^{2,5,17-32}, one review of the literature³³, six studies on treatment algorithms^{1,15,34-37}, and one meta-analysis³⁸. (Table 1).

Based on the evidence and the recommendations of these studies^{1,2,5,6,15-37} we developed a practical algorithm to help guiding the surgeon's decision on the choice of the veins for the adjunctive anastomosis (super-drainage) as explained in detail in Figures 1 to 4.

Table 1 shows all the articles that have been studied and contributed to the development of our proposal.

We recommend, when starting the DIEP flap's dissection through the sovrabubic incision, to always preserve and dissect to an adequate length the right and left SIEV. If a super-drainage is performed, the first choice is anastomosing the SIEV, if available, to a chest vein. The choice of what chest vein to use as recipient, should be based on the position in the chest of the two veins to be connected.

1st choice: SIEV to chest vein

If SIEV, due to the flap inseting, is medial, the surgeon can choose to prepare for the extra anastomosis, one of the following. a) an Internal Mammary Vein (IMV), comitant of the main recipient artery (the Internal Mammary Artery-IMA), or , b) a perforator of the IMV (IMVp), or c) in a retrograde fashion, the

caudal stump of the IMV (the cranial stump being used as recipient vein of the primary vein anastomosis), or d) the intercostal vein (ICV). (Figure 2)

If the SIEV is located centrally in the hemithorax, the thoraco-acromial (TAV), intercostal (ICV) or cephalic veins can be chosen. (Figure 3)

If the SIEV is located laterally, the surgeon can prepare a) the lateral thoracic vein (LTV), b) a vein of the subscapular trunk (SSV) such as the thoraco-dorsal (TDV) or circumflexa scapulae (CSV), and finally c) the cephalic vein. (Figure 4)

When possible, the anastomosis is performed and the super-drainage is completed. If the SIEV and the vein of the chest are too far from each other to be anastomosed, a vein graft can be used.

2nd choice: SIEV to DIEV

If the anastomosis is, for any reason, not possible, the SIEV can be connected to the DIEV with an intra-flap anastomosis³⁹.

3rd choice: DIEV to chest vein

If, when deciding to perform a super-drainage, the SIEV is unavailable for anatomical reasons or for a technical problem during dissection, (Figure 1, going back to the top of the flowchart), chances of success drop dramatically. However an attempt to solve the venous congestion can be tried using the second DIEV as flap donor vein for the super-drainage anastomosis, knowing that this measure will be useless to recruit the superficial venous system.

The DIEV can be anastomosed to a vein of the chest, depending, again on its position. The location of the comitant DIEV essentially depends on the vessels chosen for the main anastomosis (it will be medial or central if the IM vessels have been anastomosed, it will be lateral if to have been chosen were the TD vessels).

The veins of the chest that can be used, are the same described above, grouped according to their position in the hemi-chest (medial, central, lateral).

4th choice: alternative methods

In case of frank clinical signs of venous congestion, if the anastomosis between the comitant DIEV and a vein of the chest is not possible, only alternative methods remain (Figure1).

DISCUSSION

Because, when it develops, venous congestion needs to be solved promptly, the operator should have the surgical options ready in mind. These options may be useful also for preventive super-drainage.

Once the causes of the venous congestion have been investigated and the ones due to technical error have been ruled out, using venous super-drainage can solve the problem.

Based on the data of the literature, we have therefore suggested a practical algorithm on how to choose the veins to be anastomosed for super-drainage creating different hydraulic constructs.

This decisional flow-chart may help even the less experienced surgeon to choose how to proceed when needed.

Our review of the literature suggests that using the SIEV as flap vein for super-drainage is the best possible choice^{1,15,34-37,40}

Also, if the etiology of the venous congestion is, at least in part, a lack of communication between the superficial and the deep systems^{41,42}, choosing the SIEV to increase the venous drainage provided by the principal anastomosis (DIEV to IMV or to TDV/CSV) seems reasonable. (Figure 5)

It is preferable to use the SIEV of the same side of the chosen perforator because in the majority of cases the contralateral SIEV is at the borders with perfusion-zone 4 that is routinely discarded. The contralateral SIEV can be used as a vein

graft if required. If the SIEV is unavailable (for anatomical reasons or a technical problem during dissection), the second DIEV can be chosen as donor vein for the super-drainage anastomosis. The latter is considered here for the sake of completeness, although using a 2nd DIEV as donor vein can rarely work. In fact this donor vein does not use alternative draining routes and in particular does not promote the drainage of the superficial system.

Several possibilities are available also when choosing the recipient vein for the superdrainage anastomosis^{1,34,36,40}.

While some authors prefer the intra-flap anastomosis (SIEV to DIEV) as discussed below, others^{5,29-34,40,43} prefer, as recipient vein, instead of the DIEV a vein of the chest, so that the excessive venous output will be drained by an independent route, without the risk of engorging the flap's main pedicle^{31,32,43}.

In the literature, the only prospective, randomized study on the subject⁴⁰, reported a reduced venous congestion, and consequent necrosis of DIEP flaps, when an adjunctive extra-flap anastomosis between the SIEV and the thoraco-acromial vein was performed.

Therefore the use of a chest vein as recipient for the super-drainage appears to be preferable. The choice of the extra-flap recipient vein to use, should take into consideration the reliability of the vein and its ease of dissection, the donor site morbidity, in terms of additional incisions and subsequent scars, and the location³⁴.

In the literature there is not enough evidence to identify the best recipient vein for the secondary venous anastomosis.

From a practical point of view, we prefer the recipient vein to be the one anatomically located in a favorable position for anastomosing. In our algorithm,

therefore, we grouped the different possible recipient veins into the ones reachable on the medial side, on the central area, and on the lateral area of the hemithorax.

If flap venous congestion is present, but performing a second anastomosis is not possible (either with SIEV or DIEV, nor with the use of vein grafts), some alternative methods may be considered as a last resort, being aware that they rarely help in salvaging the flap, but, at the same time, cause discomfort to the patient. Among them are the use of medicinal leeches⁴⁴, SIEV cannulation⁴⁵ or off-label use of drugs such as rTPA⁴⁶, nitroglycerin ointment⁴⁷, sildenafil⁴⁸.

Signs of venous congestion may appear during flap harvesting, when the main deep inferior epigastric vessels have not yet been touched. This problem, if the dissection technique has been precise and uneventful, strongly suggests an intrinsic imbalance between arterial input and venous output that requires an adjunctive draining route through a second venous anastomosis.

If the signs of venous congestion appear after the transfer of the DIEP to the chest and after the microsurgical anastomosis of one artery (most commonly Deep Inferior Epigastric Artery to IMA) and one vein (most commonly DIEV to IMV), the surgeon should start by re-exploring the anastomotic site and evaluating the vessels' patency. If the pedicle is compressed by adjacent tissues or is kinked or twisted, the impairment can be solved by releasing, repositioning or anchoring the pedicle to the surroundings. Conversely, if the anastomosis is not patent it should be resected, the vessels should be irrigated with heparinized solution or thrombolytic agents to wash-out the flap circulation, and the microsurgical suture should be repeated.

In case of flap congestion despite a well-positioned pedicle and patent vessels, venous super-drainage becomes necessary.

Accurate planning based on the vascular anatomy, of the DIEP flap procedure, may help preventing some cases of venous congestion.

In fact, recent studies discuss how to choose the perforators more adequate to prevent venous congestion⁴⁹.

To do so, preoperative Computed Tomographic Angiography and contrast-enhanced magnetic resonance angiography can be used for the analysis of the in-vivo connections between the deep and superficial venous systems^{8,41,42}.

The choice of a perforator with a large accompanying vein⁵⁰, of medial row perforators⁸ and the use of multiple perforators^{8,49}, have all been suggested to reduce the risk of venous congestion.

The diameter of the flap's SIEV has also been studied. While some authors sustain that a large diameter of the SIEV is predictive of superficial venous system dominance and therefore involves a higher risk of venous congestion^{2,21,51}, other authors oppose this theory¹³,

Patients with previous Pfannenstiel scars seem to have a reduced risk of venous congestion⁵², possibly because the surgical incision produces a delay phenomenon, blocking the superficial venous drainage in the lower abdominal soft tissue, while enhancing the deep venous system.

Several authors also recommend the use of the superficial venous system supercharging as a preventive measure^{10,18,25,27,29,34,40,42,49,53}.

Many factors are involved in re-establishing a balance between arterial input and venous output in DIEP free flaps. Therefore a few proposals (among which six

algorithms) to help in the choice of the veins to be used for the anastomosis have been published^{1,15,34-37}. (TABLE 1, TABLE 2)

The options for the donor flap vein are either the SIEV or the DIEV. The options for the recipient veins are either a deep vein of the pedicle of the flap (intra-flap anastomosis), or a vein of the chest (extra-flap anastomosis)

Each algorithm gives priority to different aspects: i.e to the flap inseting, to the reconstruction outcome or to the surgical setting and operative time.

The main difference between our proposal and the previously published algorithms is the choice of donor and recipient veins for the second anastomosis. (TABLE 2)

In particular, some algorithms favor the intra-flap anastomosis between SIEV and DIEV, performed with a number of technical variations^{1,35,37} to optimize surgical time, simplify the procedure by avoiding further dissection in the chest, and possibly perform the adjunctive anastomosis at the abdominal site before dividing the main pedicle and transferring the flap.

The algorithms that favor a connection between the SIEV and a vein of the chest (extra-flap anastomosis) are based on the assumption that a completely alternative drainage route may be more successful, by reducing the risk of overloading of the deep system and of the main anastomosis of the flap (the one between DIEV and IMV or DIEV and TDV-CSV).

The use of the SIEV as donor vein, is supported by the fact that the superficial system is the dominant drainage system of the lower abdomen.^{15,17,18,35}

However, there is no evidence whether it would be better to connect the SIEV to the DIEV (intra-flap anastomosis)^{1,17,35,37} or to a vein of the chest (extra-flap anastomosis)^{15,34,36}.

Adding a second venous anastomosis with the super-drainage has also drawbacks.

Performing an adjunctive anastomosis prolongs the surgical procedure (up to 105 minutes, as reported in the literature)^{25,40}.

Choosing a vein of the chest as recipient adds to the procedure the time of vessel preparation, if not previously dissected (i.e. IMV or TDV).

Moreover the presence of two anastomosed pedicles may limit the freedom of flap inseting⁵⁴.

The present study has some limitations. First, the algorithm proposed is derived from a review of the literature and reflects the limitations of the published studies, none of which has an evidence level of I or II.

Another limitation is due to the fact that the literature data have not been, in this study, evaluated statistically and a clear-cut conclusion is therefore not possible.

CONCLUSIONS

DIEP flap perfusion is a complex subject involving several anatomical, physiological, and surgical variables. When super-drainage of the flap is deemed useful, knowledge of the surgical options is necessary. The use of an algorithm simplifies the matter. We favor the use of the ipsilateral SIEV to be connected to a vein of the chest, the choice of which depends on the anatomical position that allows the easiest anastomosis.

REFERENCES

1. Bartlett EL, Zavlin D, Menn ZK, Spiegel AJ. Algorithmic Approach for Intraoperative Salvage of Venous Congestion in DIEP Flaps. *J Reconstr Microsurg*. 2018 Jul;34(6):404-412.
2. Blondeel PN, Arnstein M, Verstraete K et al. Venous congestion and blood flow in free transverse rectus abdominis myocutaneous and deep inferior epigastric perforator flaps. *Plast Reconstr Surg*. 2000 Nov;106(6):1295-9.
3. Lie KH, Barker AS, Ashton MW. A classification system for partial and complete DIEP flap necrosis based on a review of 17,096 DIEP flaps in 693 articles including analysis of 152 total flap failures. *Plast Reconstr Surg*. 2013 Dec;132(6):1401-8.
4. Peeters WJ, Nanhekhan L, Van Ongeval C, et al. Fat necrosis in deep inferior epigastric perforator flaps: an ultrasound-based review of 202 cases. *Plast Reconstr Surg*. 2009;124:1754-1758.
5. Santanelli F, Longo B, Cagli B, Pugliese P, Sorotos M, Paolini G. Predictive and protective factors for partial necrosis in DIEP flap breast reconstruction: does nulliparity bias flap viability? *Ann Plast Surg* 2015;74: 47-51.

6. Figus A, Mosahebi A, Ramakrishnan V. Microcirculation in DIEP flaps: a study of the haemodynamics using laser Doppler flowmetry and lightguide reflectance spectrophotometry. *J Plast Reconstr Aesthet Surg.* 2006;59(6):604-12.
7. Ayhan S, Oktar SO, Tuncer S, Yucel C, Kandal S, Demirtas Y. Correlation between vessel diameters of superficial and deep inferior epigastric systems: Doppler ultrasound assessment. *J Plast Reconstr Aesthet Surg.* 2009 Sep;62(9):1140-7.
8. Schaverien MV, Ludman CN, Neil-Dwyer J et al. Relationship between venous congestion and intraflap venous anatomy in DIEP flaps using contrast-enhanced magnetic resonance angiography. *Plast Reconstr Surg.* 2010 Aug;126(2):385-92.
9. Rothenberger J, Amr A, Schiefer J, Schaller HE, Rahmanian-Schwarz A. A quantitative analysis of the venous outflow of the deep inferior epigastric flap (DIEP) based on the perforator veins and the efficiency of superficial inferior epigastric vein (SIEV) supercharging. *J Plast Reconstr Aesthet Surg.* 2013 Jan;66(1):67-72.
10. Xin Q, Luan J, Mu H, Mu L. Augmentation of venous drainage in deep inferior epigastric perforator flap breast reconstruction: efficacy and advancement. *J Reconstr Microsurg.* 2012 Jun;28(5):313-8.

11. Figus A, Wade RG, Gorton L, Rubino C, Griffiths MG, Ramakrishnan VV. Venous perforators in DIEAP flaps: an observational anatomical study using duplex ultrasonography. *J Plast Reconstr Aesthet Surg*. 2012 Aug;65(8):1051-9.
12. Minqiang X, Jie L, Dali M, Lanhua M. Hemodynamic effect of different kinds of venous augmentation in a pig transmidline flap model of DIEP flap. *J Reconstr Microsurg*. 2013 Jul;29(6):379-86.
13. Sadik KW, Pasko J, Cohen A, Cacioppo J. Predictive value of SIEV caliber and superficial venous dominance in free DIEP flaps. *J Reconstr Microsurg*. 2013 Jan;29(1):57-61.
14. Gravvanis A, Tsoutsos D, Papanikolaou G, Diab A, Lambropoulou P, Karakitsos D. Refining perforator selection for deep inferior epigastric perforator flap: the impact of the dominant venous perforator. *Microsurgery*. 2014 Mar;34(3):169-76.
15. Vijayasekaran A, Mohan AT, Zhu L, Sharaf B, Saint-Cyr M. Anastomosis of the Superficial Inferior Epigastric Vein to the Internal Mammary Vein to Augment Deep Inferior Artery Perforator Flaps. *Clin Plast Surg*. 2017 Apr;44(2):361-369.
16. Akita S, Yamaji Y, Tokumoto H et al. Intraoperative objective evaluation of venous congestion in deep epigastric artery perforator flap breast reconstruction: A pilot study. *Microsurgery*. 2018 May;38(4):407-412.

17. Sbitany H, Mirzabeigi MN, Kovach SJ, Wu LC, Serletti JM. Strategies for recognizing and managing intraoperative venous congestion in abdominally based autologous breast reconstruction. *Plast Reconstr Surg*. 2012; 129(04):809–815.
18. Enajat M, Rozen WM, Whitaker IS, Smith JM, Acosta R. A single center comparison of one versus two venous anastomoses in 564 consecutive DIEP flaps: investigating the effect on venous congestion and flap survival. *Microsurgery*. 2010; 30(3):185-191.
19. Wechselberger G, Schoeller T, Bauer T, Ninkovic M, Otto A, Ninkovic M. Venous superdrainage in deep inferior epigastric perforator flap breast reconstruction. *Plast Reconstr Surg*. 2001 Jul;108(1):162-6.
20. Tutor EG, Auba C, Benito A, Rábago G, Kreutler W. Easy venous superdrainage in DIEP flap breast reconstruction through the intercostal branch. *J Reconstr Microsurg*. 2002 Oct;18(7):595-8.
21. Tran NV, Buchel EW, Convery PA. Microvascular complications of DIEP flaps. *Plast Reconstr Surg*. 2007; 119(5):1397–1405.
22. Guzzetti T, Thione A. The basilic vein: an alternative drainage of DIEP flap in severe venous congestion. *Microsurgery*. 2008;28(7):555-8.

23. Stasch T, Goon PK, Haywood RM, Sassoon EM. DIEP flap rescue by venesection of the superficial epigastric vein. *Ann Plast Surg*. 2009 Apr;62(4):372-3.
24. Momeni A, Lee GK. A case of intraoperative venous congestion of the entire DIEP-flap--a novel salvage technique and review of the literature. *Microsurgery*. 2010 Sep;30(6):443-6.
25. Al Hindi A, Ozil C, Rem K et al. Intraoperative superficial inferior epigastric vein preservation for venous compromise prevention in breast reconstruction by deep inferior epigastric perforator flap. *Ann Chir Plast Esthet*. 2019 Jun;64(3):245-250.
26. Ochoa O, Pisano S, Chrysopoulou M, Ledoux P, Arishita G, Nastala C. Salvage of intraoperative deep inferior epigastric perforator flap venous congestion with augmentation of venous outflow: flap morbidity and review of the literature. *Plast Reconstr Surg Glob Open*. 2013 Nov 7;1(7):e52.
27. Unukovych D, Gallego CH, Aineskog H, Rodriguez-Lorenzo A, Mani M. Predictors of Reoperations in Deep Inferior Epigastric Perforator Flap Breast Reconstruction. *Plast Reconstr Surg Glob Open*. 2016 Aug 29;4(8):e1016
28. Hillberg NS, van Mulken TJM, Meesters-Caberg MAJ et al. Autologous Breast Reconstruction With a Delay Procedure of the Deep Inferior Epigastric

Artery Perforator Flap Because of Venous Congestion of the Flap on Pedicle: A Case Series. *Ann Plast Surg.* 2019 May;82(5):537-540.

29. Boutros SG. Double venous system drainage in deep inferior epigastric perforator flap breast reconstruction: a single-surgeon experience. *Plast Reconstr Surg.* 2013;131(4): 671-676.

30. Kim EJ, Lee HJ, Mun GH. Muscle-splitting approach to thoracoacromial vein for superdrainage in deep inferior epigastric artery perforator flap breast reconstruction. *Microsurgery.* 2019 Mar;39(3):228-233

31. Chang AI, Fearmonti RM, Chang DW, Butler CE. Cephalic Vein Transposition versus Grafts for Venous Outflow in Free-flap Breast Reconstruction. *Plast Reconstr Surg Glob Open.* 2014; 6;2(5):e141.

32. Kerr-Valentic MA, Gottlieb LJ, Agarwal JP. The retrograde limb of the internal mammary vein: an additional outflow option in DIEP flap breast reconstruction. *Plast Reconstr Surg.* 2009;124(3): 717-721.

33. Kim DY, Lee TJ, Kim EK, Yun J, Eom JS. Intraoperative venous congestion in free transverse rectus abdominis musculocutaneous and deep inferior epigastric artery perforator flaps during breast reconstruction: a systematic review. *Plast Surg (Oakv).* 2015; 23(04):255–259.

34. Eom JS, Sun SH, Lee TJ. Selection of the recipient veins for additional anastomosis of the superficial inferior epigastric vein in breast reconstruction with free transverse rectus abdominis musculocutaneous or deep inferior epigastric artery perforator flaps. *Ann Plast Surg.* 2011; 67(5): 505-509.
35. Ali R, Bernier C, Lin YT et al. Surgical strategies to salvage the venous compromised deep inferior epigastric perforator flap. *Ann Plast Surg.* 2010 Oct;65(4):398-406.
36. La Padula S, Hersant B, Noel W, Niddam J, Hermeziu O, Bouhassira J et al. Use of the retrograde limb of the internal mammary vein to avoid venous congestion un DIEP flap breast reconstruction. Further evidences of a reliable and time-sparing procedure. *Microsurgery.* 2016; 36(6):4476-452.
37. Davis CR, Jones L, Tillett RL, Richards H, Wilson SM. Predicting venous congestion before DIEP breast reconstruction by identifying atypical venous connections on preoperative CTA imaging. *Microsurgery.* 2019 Jan;39(1):24-31.
38. Lee KT, Mun GH. Benefits of super-drainage using SIEV in DIEP flap breast reconstruction: A systematic review and meta-analysis. *Microsurgery.* 2017; 37(1):75-83.
39. Sojitra NM, Vandevooort M, Ghali S, Fabre G. Two new techniques for correcting venous congestion in the free DIEP flap for breast reconstruction: an

analysis of venous augmentation in 581 DIEP flaps. *Plast Reconstr Surg*. 2010 Feb;125(2):72e-74e.

40. Ayestaray B, Yonekura K, Motomura H, Ziade M. A Comparative Study Between Deep Inferior Epigastric Artery Perforator and Thoracoacromial Venous Supercharged Deep Inferior Epigastric Artery Perforator Flaps. *Ann Plast Surg*. 2016; 76(1):78-82.

41. Rozen WM, Pan WR, Le Roux CM, Taylor GI, Ashton MW. The venous anatomy of the anterior abdominal wall: An anatomical and clinical study. *Plast Reconstr Surg*. 2009;124(3): 848–853.

42. Rozen WM, Ashton MW. The venous anatomy of the abdominal wall for Deep Inferior Epigastric Artery (DIEP) flaps in breast reconstruction. *Gland Surg*. 2012 Aug;1(2):92-110.

43. Fansa H. Internal Mammary Artery and Vein Perforator Vessels as Troubleshooter Recipient Vessels. *Plast Reconstr Surg Glob Open*. 2019; 20;7(3):e2148.

44. Conforti ML, Connor NP, Heisey DM, et al. Evaluation of performance characteristics of the medicinal leech (*Hirudo medicinalis*) for the treatment of venous congestion. *Plast Reconstr Surg*. 2002;109:228.

45. Wongtriratanachai P, Martin AM, Chaiyasate K. DIEP flap salvage by cannula venesection of the superficial inferior epigastric vein. *Eur J Plast Surg.* 2016;39:151-154.
46. Tran NV, Bishop AT, Convery PA, Yu AY. Venous congestive flap salvage with subcutaneous rtPA. *Microsurgery.* 2006;26(5):370-2.
47. Gdalevitch P, Van Laeken N, Bahng S, et al. Effects of nitroglycerin ointment on mastectomy flap necrosis in immediate breast reconstruction: a randomized controlled trial. *Plast Reconstr Surg.* 2015;135(6):1530-9.
48. Gao ZM, Lin DM, Wang Y, Li JJ, Chen S1, Gao WY. Role of the NO/cGMP pathway in postoperative vasodilation in perforator flaps. *J Reconstr Microsurg.* 2015;31(2):107-12.
49. Karadsheh MJ, Shafqat MS, Krupp JC, Weiss ES, Patel SA. A Theoretical Model Describing the Dynamics of Venous Flow in the DIEP Flap. *J Reconstr Microsurg.* 2019 Nov;35(9):688-694.
50. Kroll SS. Fat necrosis in free transverse rectus abdominis myocutaneous and deep inferior epigastric perforator flaps. *Plast Reconstr Surg.* 2000 Sep;106(3):576-83.

51. Schaverien M, Saint-Cyr M, Arbique G, Brown SA. Arterial and venous anatomies of the deep inferior epigastric perforator and superficial inferior epigastric artery flaps. *Plast Reconstr Surg*. 2008; 121(6):1909–1919.
52. Kim SY, Lee KT, Mun GH. The Influence of a Pfannenstiel Scar on Venous Anatomy of the Lower Abdominal Wall and Implications for Deep Inferior Epigastric Artery Perforator Flap Breast Reconstruction. *Plast Reconstr Surg*. 2017 Mar;139(3):540-548.
53. Lee KT, Lee JE, Nam SJ, Mun GH. Ischaemic time and fat necrosis in breast reconstruction with a free deep inferior epigastric perforator flap. *J Plast Reconstr Aesthet Surg*. 2013 Feb;66(2):174-81.
54. Razzano S, Marongiu F, Wade R, Figus A. Optimizing DIEP Flap Insetting for Immediate Unilateral Breast Reconstruction: A Prospective Cohort Study of Patient-Reported Aesthetic Outcomes. *Plast Reconstr Surg*. 2019 Feb;143(2):261e-270e.

LEGENDS

Figure 1

Algorithm and schematic representation of veins position in the chest.

If a super-drainage is performed, the first choice is using the SIEV. Its length, patency and flow should be verified. If the SIEV can be used, go to the right of the flow chart.

At the right of the flow chart: 1st choice: SIEV to chest vein

SIEV medial: 2nd Internal Mammary Vein (2nd IMV), retrograde Internal Mammary Vein (Retro IMV), perforator of Internal Mammary Vein (IMVp), InterCostal Vein (ICV). (details in Figure2)

SIEV central: Thoraco-Acromial (TAV), intercostal (ICV) or Cephalic veins can be chosen. (details in Figure 3)

SIEV lateral: Lateral Thoracic Vein (LTV) or a vein of the SubScapular (SS) trunk (Thoracodorsal-TD or Circumflexa Scapulae-CS) or the Cephalic vein. (details in Figure 4)

If needed, a vein graft can be used.

2nd choice: SIEV to DIEV

If the anastomosis is, for any reason, not possible, the SIEV can be connected to the DIEV with an intra-flap anastomosis

3rd choice: DIEV to chest vein

If the SIEV is unavailable, chances of success drop dramatically.

Going back to the top left of the flowchart we represented in a red square the remaining 3rd and 4th options described in the literature as last resorts.
(additional details in the text)

The second DIEV can be chosen as donor vein for the super-drainage anastomosis to a vein of the chest, again on the basis of the location.

4th choice: alternative methods

In case of frank clinical signs of venous congestion, if no super-draining anastomosis is possible, only alternative methods remain

Figure 2

Vein options for the extra anastomosis in the medial chest: 2nd Internal Mammary Vein (2nd IMV), retrograde Internal Mammary Vein (Retro IMV), perforator of Internal Mammary Vein (IMVp), InterCostal Vein (ICV) .

The flap is represented in a horizontal in-setting with a traditional large skin island for clarity. Other flap in-settings and smaller skin islands (de-epithelized flap in skin-sparing mastectomies or a pre-expanded skin envelope) are possible

Figure 3

Vein options for the extra anastomosis in the central chest: Thoraco-Acromial (TA), intercostal (ICV) or Cephalic veins.

Figure 4

Vein options for the extra anastomosis in the lateral chest: Lateral Thoracic Vein (LTV) or a vein of the SubScapular (SS) trunk (Thoracodorsal-TD or Circumflexa Scapulae-CS) or the Cephalic vein

Figure 5

A DIEP flap is transferred to the left chest for breast reconstruction.

One of the possible hydraulic constructs is shown. The main anastomosis is between DIEA and IMA and between DIEV and IMV.

Venous supercharging is drawn between the SIEV and the 2nd IMV

TABLE 1

Studies reporting on venous super-drainage in DIEP flaps for breast reconstruction.

TABLE 2

Previously published decisional algorithms suggesting which veins should be connected when adding a super-drainage anastomosis in DIEP flaps

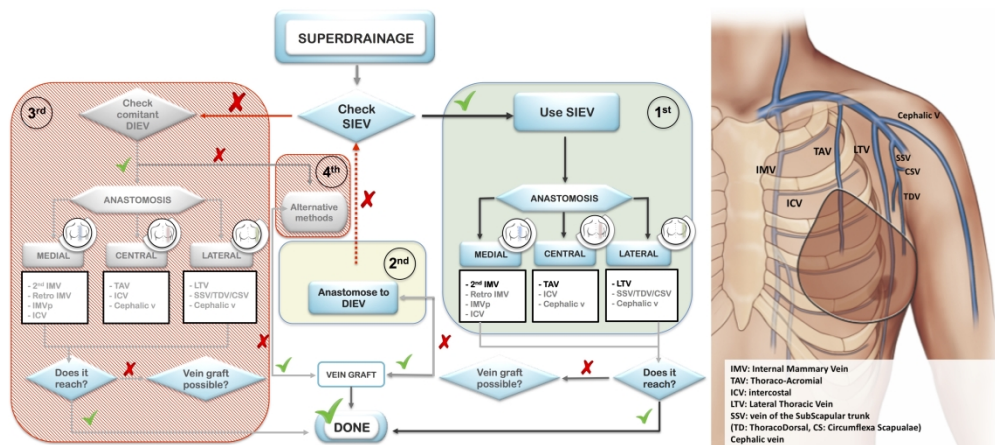


Figure 1

659x290mm (300 x 300 DPI)

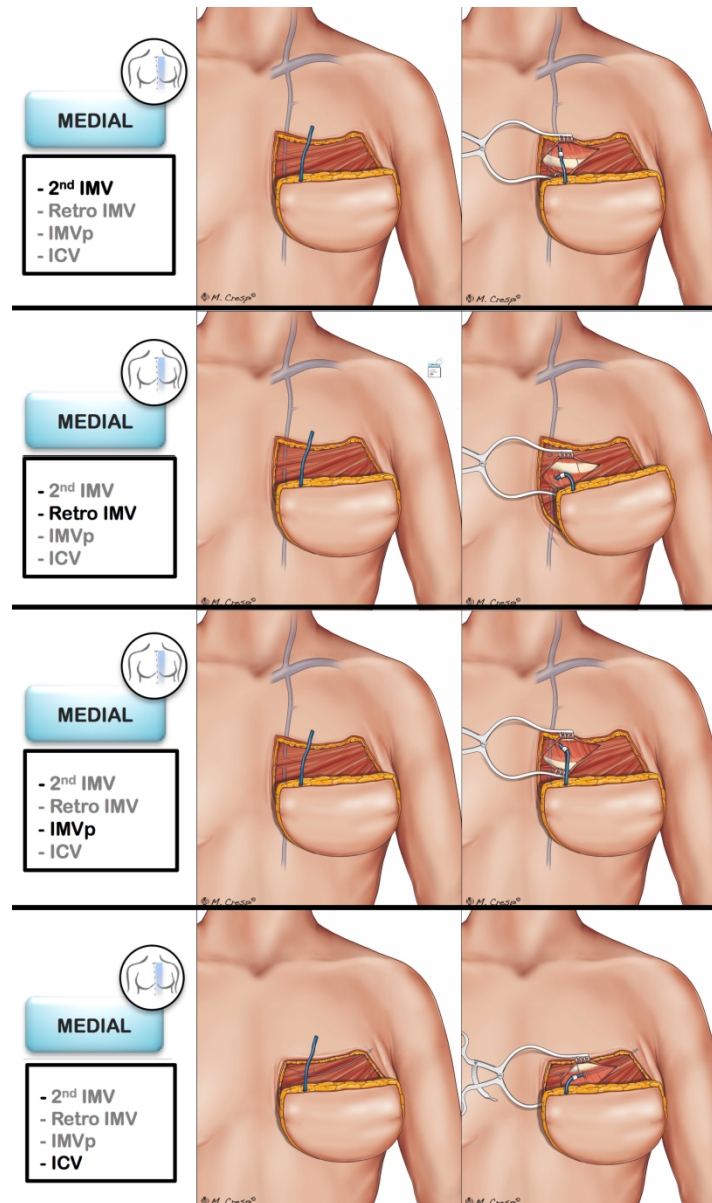


Fig 2

381x640mm (300 x 300 DPI)

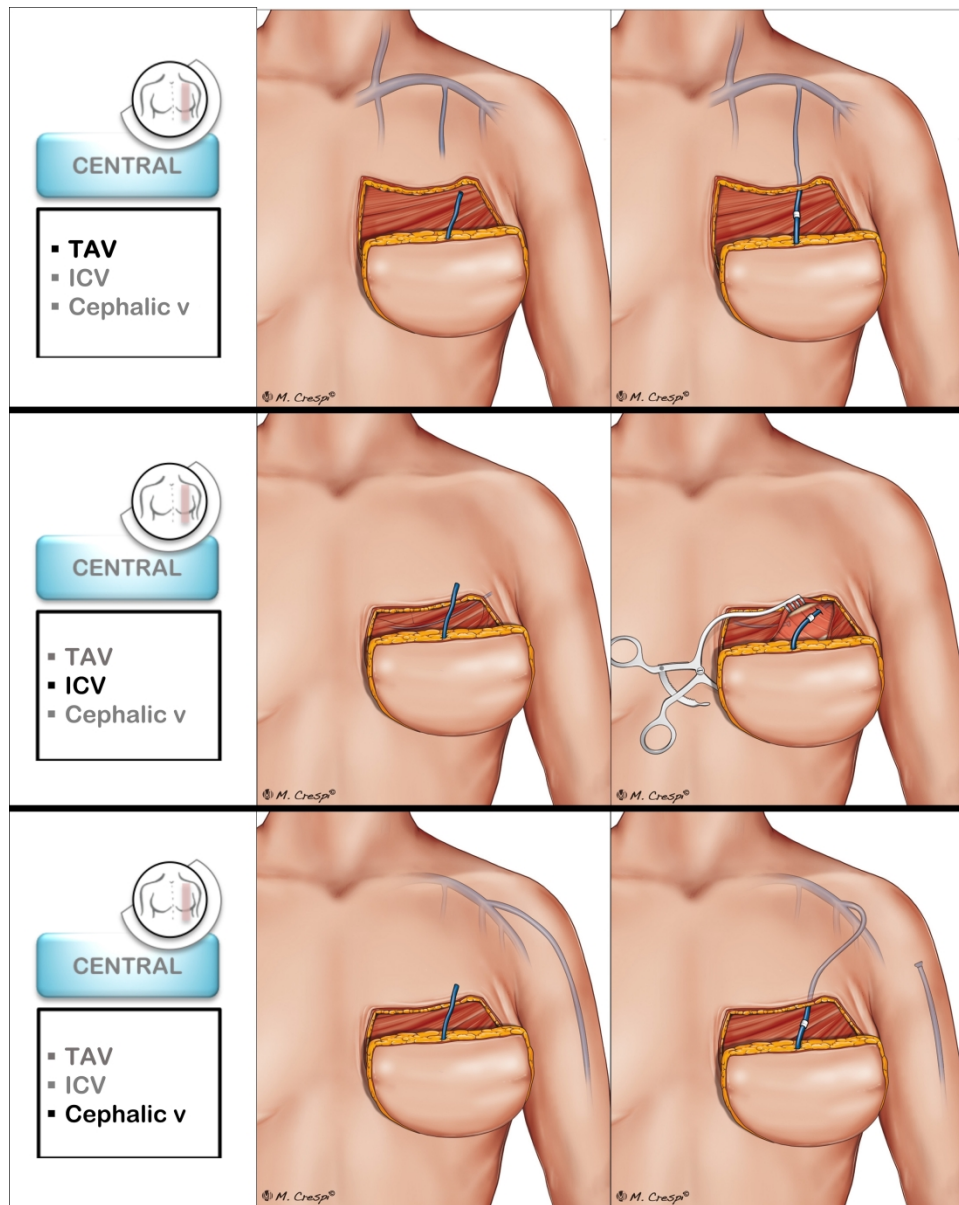


Figure 3

406x510mm (300 x 300 DPI)

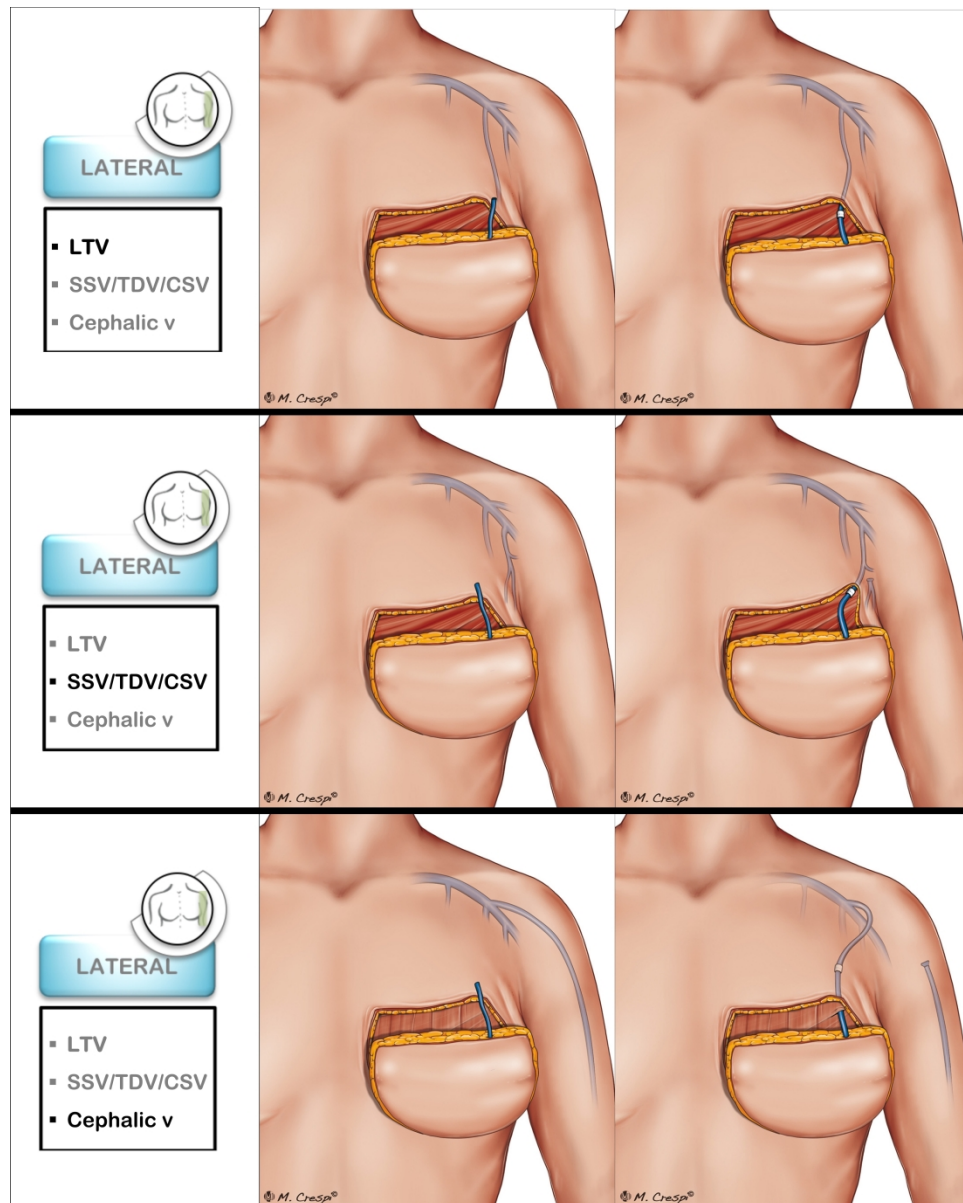


Figure 4

406x506mm (300 x 300 DPI)

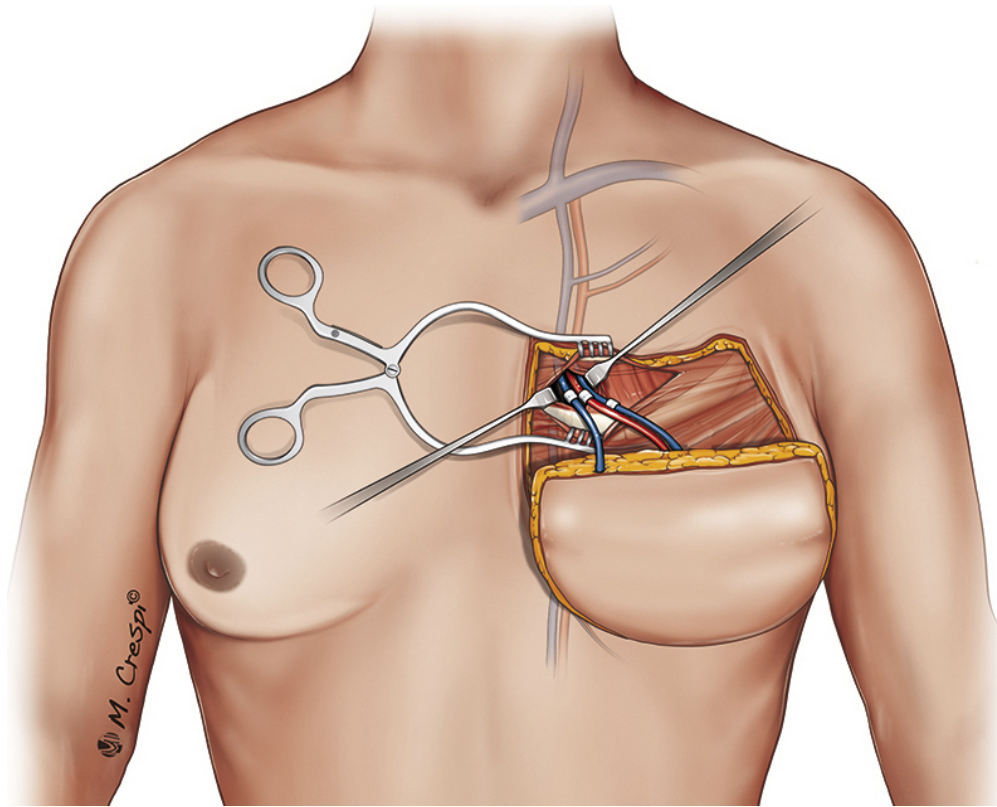


Figure 5

67x53mm (300 x 300 DPI)

	<i>TITLE</i>	<i>FIRST AUTHOR</i>	<i>YEAR</i>
<i>ANATOMICAL PHYSIOLOGICAL RADIOLOGICAL ETIOLOGICAL</i>	▪ A study of the haemodynamics using laser Doppler flowmetry and lightguide reflectance spectrophotometry	Figus	2005
	▪ Correlation between vessel diameters of superficial and deep inferior epigastric systems- Doppler ultrasound assessment	Ayhan	2007
	▪ Relationship between venous congestion and intraflap venous anatomy in DIEP flaps using contrast-enhanced MR angiography	Schaverien	2010
	▪ A quantitative analysis of the venous outflow of the DIEP based on the perforator veins and the efficiency of SIEV supercharging	Rothemberg	2012
	▪ Augmentation of Venous Drainage in Deep Inferior Epigastric Perforator Flap Breast Reconstruction- Efficacy and Advancement	Xin	2012
	▪ Venous perforators in DIEAP flaps- An observational anatomical study using duplex ultrasonography	Figus	2012
	▪ Hemodynamic Effect of Different Kinds of Venous Augmentation in a Pig Transmidline Flap Model of DIEP Flap	Minqiang	2013
	▪ Predictive Value of SIEV Caliber and Superficial Venous Dominance in Free DIEP Flaps	Sadik	2013
	▪ Refining perforator selection for deep inferior epigastric perforator flap: the impact of the dominant venous perforator	Gravvanis	2014
	▪ Anastomosis of the Superficial Inferior Epigastric Vein to the Internal Mammary Vein to Augment DIEAP Flaps	Vijayasekaran	2017
	▪ Intraoperative objective evaluation of venous congestion in deep epigastric artery perforator flap breast reconstruction- A pilot study	Akita	2017
<i>SINGLE TECHNIQUE AND/OR CENTER EXPERIENCE</i>	▪ Venous superdrainage in deep inferior epigastric perforator flap breast reconstruction	Wechselberger	2001
	▪ Easy venous superdrainage in DIEP flap breast reconstruction through the intercostal branch	Tutor	2002
	▪ Microvascular Complications of DIEP Flaps	Tran	2007
	▪ The basilic vein- An alternative drainage of diep flap in severe venous congestion	Guzzetti	2008
	▪ A single center comparison of one versus two venous anastomoses in 564 consecutive diep	Enjat	2009
	▪ DIEP flap rescue by venesection of the superficial epigastric vein	Stasch	2009
	▪ The Retrograde Limb of the Internal Mammary Vein- An Additional Outflow Option in DIEP Flap Breast Reconstruction	Kerr-Valentinic	2009
	▪ Venous congestion and blood flow in free transverse rectus abdominis myocutaneous and deep inferior epigastric perforator flaps	Blondeel	2010
	▪ A case of intraoperative venous congestion of the entire DIEP-flap - A novel salvage technique and review of the literature	Momeni	2010
	▪ Double Venous System Drainage in Deep Inferior Epigastric Perforator Flap Breast Reconstruction- A Single-Surgeon Experience	Boutros	2012
	▪ Strategies for recognizing and managing intraoperative venous congestion in abdominally based autologous breast reconstruction	Sbitany	2012
	▪ Salvage of Intraoperative DIEP Flap Venous Congestion with Augmentation of Venous Outflow- Flap Morbidity and Review of the Literature	Ochoa	2013
	▪ Cephalic vein transposition versus vein grafts for venous outflow in free-flap breast reconstruction	Chang	2014
	▪ Predictive and Protective Factors for Partial Necrosis in DIEP Flap Breast Reconstruction Does Nulliparity Bias Flap Viability?	Santanelli	2015
	▪ Predictors of Reoperations in Deep Inferior Epigastric Perforator Flap Breast Reconstruction	Unukovych	2016
	▪ Intraoperative superficial inferior epigastric vein preservation for venous compromise prevention in breast reconstruction by DIEP flap	Hindi	2018
	▪ Autologous Breast Reconstruction With a Delay Procedure of the DIEAP Flap Because of Venous Congestion of the Flap on Pedicle	Hillberg	2019
	▪ Muscle-splitting approach to thoracoacromial vein for superdrainage in deep inferior epigastric artery perforator flap breast reconstruction	Kim	2019

<i>PROSPECTIVE RANDOMIZED</i>	<ul style="list-style-type: none"> A Comparative Study between DIEAP and Thoracoacromial Venous Supercharged Deep Inferior Epigastric Artery Perforator Flaps 	Ayestaray	2016
<i>ALGORITHM</i>	<ul style="list-style-type: none"> Surgical strategies to salvage the venous compromised deep inferior epigastric perforator flap Selection of the Recipient Veins for Additional Anastomosis of the SIEV in Breast Reconstruction With Free TRAM or DIEAP Flaps The superficial outside-flap shunt (SOS) technique for free deep inferior epigastric perforator flap salvage Use of the retrograde limb of the internal mammary vein to avoid venous congestion in diep flap breast reconstruction: further evidences of a reliable and time-sparing procedure Anastomosis of the Superficial Inferior Epigastric Vein to the Internal Mammary Vein to Augment Deep Inferior Artery Perforator Flaps Algorithmic Approach for Intraoperative Salvage of Venous Congestion in DIEP Flaps 	Ali Eom Davies La Padula Vijayasekaran Bartlett	2010 2011 2014 2016 2017 2018
<i>REVIEW</i>	<ul style="list-style-type: none"> Intraoperative venous congestion in free transverse rectus abdominis musculocutaneous and deep inferior epigastric artery perforator flaps during breast reconstruction- A Systematic review 	Kim	2015
<i>META-ANALYSIS</i>	<ul style="list-style-type: none"> Benefits of superdrainage using siev in diep flap breast reconstruction: a systematic review and meta-analysis 	Lee	2015

SECOND ANASTOMOSIS	ALI 2010	EOM 2011	DAVIES 2014	LA PADULA 2016	VIJAYASEKARAN 2017	BARTLETT 2018	PIGNATTI 2020
INDICATIONS	Congestion	Congestion OR Without a sign of flap congestion	Congestion	Congestion	When technically feasible irrespective of the incidence of venous congestion	Congestion	When technically feasible
FLAP VEIN							
FIRST CHOICE	SIEV	SIEV	SIEV	SIEV	SIEV	SIEV	SIEV
SECOND CHOICE				second DIEV	second DIEV	SCIV	second DIEV
RECIPIENT VEIN							
FIRST CHOICE	DIEV-IMV axis	CHEST VEIN (position, easiness of dissection, inset of the flap, geometry of the additional vein anastomosis)	DIEV	Retrograde IMV	Second IMV	DIEV	CHEST VEIN (position and easiness of dissection)
SECOND CHOICE	Substitute DIEV with SIEV		CHEST VEIN		Retrograde IMV	CHEST VEIN (IMV)	DIEV
DETAILS	Original DIEV-IMV axis as recipient for the SIEV obviates the need for a vein graft and facilitates optimal breast shaping	<ul style="list-style-type: none"> The independent draining route is safer Time for the preparation of another recipient vein can be minimal The prophylactic use of SIEV should be contemplated 	The technique does not require harvest of a further recipient vein or vein graft	<ul style="list-style-type: none"> Independent outflow for superficial and deep systems Dual venous anastomosis could be carried out in routine practice 	<ul style="list-style-type: none"> SIEV because superficial system is dominant. No downsides to routine venous augmentation other than maybe adding 20 minutes to the operative time and the cost of a venous coupler. So the authors ask: "Why not?" 	Additional venous rerouting should be performed prior to pedicle anastomosis: <ul style="list-style-type: none"> no increase in operative time no tethering of the anastomosis, -no, difficulties in flap inset. 	1st choice: SIEV - chest vein because safer 2nd choice: SIEV - DIEV because faster 3rd choice: DIEV - chest vein as last resource 4th choice: alternative methods