



ALMA MATER STUDIORUM
UNIVERSITÀ DI BOLOGNA

ARCHIVIO ISTITUZIONALE
DELLA RICERCA

Alma Mater Studiorum Università di Bologna Archivio istituzionale della ricerca

Evaluation and selection of lower limb lymphedema patients for lymphaticovenular anastomosis: A prospective study

This is the final peer-reviewed author's accepted manuscript (postprint) of the following publication:

Published Version:

Availability:

This version is available at: <https://hdl.handle.net/11585/735664> since: 2020-02-26

Published:

DOI: <http://doi.org/10.1016/j.injury.2020.02.110>

Terms of use:

Some rights reserved. The terms and conditions for the reuse of this version of the manuscript are specified in the publishing policy. For all terms of use and more information see the publisher's website.

This item was downloaded from IRIS Università di Bologna (<https://cris.unibo.it/>).
When citing, please refer to the published version.

(Article begins on next page)

This is the accepted manuscript of:

Kristiansen M, Halle M, Pignatti M, Skogh AD. Evaluation and selection of lower limb lymphedema patients for lymphaticovenular anastomosis: A prospective study. *Injury*. 2020 Dec;51 Suppl 4:S108-S113

Final version available: [10.1016/j.injury.2020.02.110](https://doi.org/10.1016/j.injury.2020.02.110)

Rights / License:

The terms and conditions for the reuse of this version of the manuscript are specified in the publishing policy. For all terms of use and more information see the publisher's website.

This item was downloaded from IRIS Università di Bologna (<https://cris.unibo.it/>)

When citing, please refer to the published version.

Evaluation and selection of lower limb lymphedema patients for lymphaticovenular anastomosis: A prospective study

Martina Kristiansen (MD)¹, Martin Halle (MD, PhD)^{1,2}, Marco Pignatti (MD)³, Ann-Charlott Docherty Skogh (MD, PhD)^{1,2}

¹ Department of Reconstructive Plastic Surgery, Karolinska University Hospital, ²

Department of Molecular Medicine and Surgery, Karolinska Institutet, SE-17177, Stockholm,

Sweden, ³ Plastic Surgery, Policlinico di Sant'Orsola, DIMES, University of Bologna, Italy

The authors have no financial interest to declare in relation to the content of this article and the study is not financially supported. The authors alone are responsible for the content and writing of the paper.

Corresponding author: Ann-Charlott Docherty Skogh, MD, PhD, Department of Surgery,

Breast Cancer Unit, Stockholm South General Hospital, Sjukhusbacken 10, 118 61

Stockholm, Sweden. Email: anna.docherty-skogh@sll.se

The manuscript was presented in part at The 12th National Congress of the Romanian Society for Reconstructive Microsurgery in Cluj Napoca, Romania, 2017.

Abstract

Background: Lymphaticovenular anastomosis (LVA) with supramicrosurgical technique has recently gained popularity as a treatment method for patients with lymphedema. The aim of this study was to prospectively evaluate objective changes in leg volume in patients operated with LVA for lymphedema in the lower extremity, and to find positive predictors for the treatment method to facilitate the location of the venules and lymphatic vessels.

Patients & Methods: 31 consecutive patients with lymphedema in the lower extremity and positive pitting test were examined with lymphoscintigraphy and indocyanine green (ICG) lymphography. The causes of the lymphedema were either cancer or unknown cause/primary

lymphedema. Fourteen of the patients with pathological lymphangiographic patterns were chosen for surgery and 12 of them were operated with one to four LVAs each. The lymphedema volume in the lower extremity was measured preoperatively, 6- and 12 months after surgery according to the truncated cone formula with the patient's contralateral leg used as control. Ten patients had unilateral lymphedema and two patients had bilateral lymphedema.

Results: Five of 12 patients showed between 1-8 % edema reductions in the lower extremity after 12 months. With examination considering edema duration, number of anastomoses, radiotherapy and lymph node dissection we found a 6,2 % difference in edema reduction between patients who had undergone lymph node dissection and those who had not ($p=0.03$).

Conclusions: The current study indicates that supramicrosurgery with LVA may reduce edema volumes, where the most distinctive positive predictor for edema reduction with LVAs was previous lymph node dissection.

Key words: lymphedema, LVA, supramicrosurgery, lymphaticovenular anastomosis, indocyanin green

Highlights:

- Previous lymphnode dissection affects the outcome of supramicrosurgery in the lower limb.
- We found no significant difference in edema reduction after LVAs in patients related to edema duration, number of anastomosis or previous radiotherapy.
- The use of multiple operating microscopes facilitating multiple LVAs might affect the outcome of surgery, as seen in other studies.
- Preoperative location of a favorable recipient venule close to a functional lymphatic channel has many advantages in terms of incision length, location and operative time according to recent studies.

Introduction

Lower extremity lymphedema can be severely disabling and affect the patients' daily life with difficulties in range of motion, fitting into normal clothing, subjective discomfort, risk of soft tissue infection and can also cause psychological distress (1). Complete decongestive physiotherapy has been the most common non-surgical management in reducing edema volumes, although it is not a curative treatment method (2). Surgical treatment of lymphedema is an alternative and, except from debulking surgery, there are currently four main surgical methods described; vascularized lymph node transfer, lymphaticovenular anastomosis (LVA), lymphatico-lymphatic anastomosis and suction assisted lipectomy (3-6).

The surgical treatment depends on the severity and stage of the lymphedema. Main advantages with the different treatment methods have been described such as reduction in edema volume, reduced incidence of cellulitis and reduced need for compression garments (7). In the current study, we have focused on the surgical treatment method with LVA.

Imaging, instruments and surgical techniques have been developed during the last decades.

The most recent change in performance was introduced by Koshima et al (8) where refined techniques for supramicrosurgery made it possible to anastomose subdermal lymphatic vessels to adjacent venules to increase lymphatic drainage in the edematous extremity. The use of indocyanine green (ICG) has been introduced, and it is injected preoperatively intradermally into the first web space to emit near infrared light. Using a

Photodynamic Eye (PDE) camera which detects fluorescence it is possible to identify and visualize the lymphatic vessel system before incision and then connect lymphatic vessels to nearby veins (9). The importance of preoperative location of a favorable recipient venule close to a functional lymphatic channel has many advantages in terms of incision length, location and operative time. Unfortunately this equipment was not available at the time of the study.

The supramicrosurgery technique with lymphaticovenular anastomosis (LVA) in the lower extremity has shown variable efficacy in edema reduction in a few studies (10-15) and decreased incidence of cellulitis in the leg (16). However, there is a paucity of prospective studies with objective evaluation of long-term outcome. We report a prospective, controlled study for patients operated with LVA for lymphedema in the lower extremity. The aim of this study was to evaluate objective changes in leg volume in patients operated with LVAs for lymphedema in the lower extremity, and to find positive predictors for the treatment method.

Patients and Methods

Thirty-one consecutive patients with lymphedema in the lower extremity and positive pitting test were examined with lymphoscintigraphy and indocyanine green (ICG) lymphangiography (Indocyanin grün Pulsion, Pulsion Medical Systems SE, Feldkirchen, Germany) using a PDE (Photodynamic eye) camera, Hamamatsu Photonics, K.K, Hamamatsu, Japan. Fourteen of the patients were chosen for surgery where dermal backflow stage II-III lymphedema with partial linear, stardust PDE-pattern, was observed (17, 18). The remaining 17 patients had a stage IV-V lymphedema, and were offered conservative treatment complemented with liposuction. The patients were their own controls as the contralateral leg was used as reference. Peroperatively, one of the patients showed fibrotic lymph vessels not suitable for surgery with LVA, and one patient did not have venules close enough to lymph vessels to allow LVAs to be performed.

These two patients were offered conservative treatment complemented with liposuction. In total, 12 of the patients were operated between 2011 and 2014 and received 1-4 LVAs each (Figure 1). Ten patients had unilateral lymphedema, and two patients had bilateral lymphedema among the twelve patients that underwent surgery with LVAs. Background data were collected from the medical records (Table 1). The causes of the lymphedema in the patients were either cancer surgery or unknown cause/primary lymphedema. Edema duration, number of anastomoses, previous radiotherapy and lymph node dissection were studied to find potential positive predictors for treatment with lymphaticovenular anastomosis.

The lymphedema volume in the lower extremity was measured and calculated using the formula for a truncated cone according to Brorson et al (19), with the patient's contralateral leg used as control. The patients underwent volume measurements preoperatively, 6 and 12 months after surgery. One patient was not present at the 12-months follow up, and the 6 months' measurement was duplicated and used as the 12-month observation. All operations were performed by the same surgeon and the median operating time was 223.5 minutes. The patients were discharged within 24 hours after surgery.

Surgical technique The surgery was performed under general anesthesia. The reason for choosing general anesthesia instead of local anesthesia was the long operating time (median 223.5 minutes) due to the usage of only one operating microscope. ICG was injected intradermally into the first web space of the affected leg to locate the lymphatic vessels suitable for anastomosis. Short skin incisions were made over the selected vessels using an operating microscope, and if the vessels were difficult to locate, a complementary injection of 0.3-1.0 mL patent blue (Patentblau, Guerbet, Germany V 25 mg/mL) was given intradermally a few centimeters distal to the skin incision. Suitable subdermal venules (each 0.5 mm in diameter) were explored adjacent to the lymphatic vessels. End-to-end lymphaticovenular

anastomoses of size matched vessels were performed, using 50-micron needle sutures (with 12-0 nylon) with a supramicrosurgery needle holder under high magnification (20 to 30 times). Lymphatic flow was observed over the anastomosis after release of 1V vessel clamps (Figure 2). Postoperatively, the leg was kept elevated at night, and a low-pressure bandage was applied the day after surgery.

Data were collected and evaluated in Microsoft Excel 2016. Mann-Whitney U-test was used for the statistical analysis and the significance level was set to 0.05. Data were analyzed using SPSS statistics. The study was done in accordance with the ethical standards of the Regional Ethical Review board and with the Helsinki Declaration with informed consent obtained from each participant.

Results

Median age of the patient group was 51 years (range 41-66 years). The median duration of the lymphedema was 4 years (range 3-11 years) and median preoperative edema volume was 626 ml (range -756-1871 ml). Two of the patients had bilateral lymphedema, which explains the negative preoperative volume. One of those patients had fibrotic lymphatic vessels (stage IV-V) in the leg with larger edema volume and was therefore operated on the leg with lower edema volume. The other patient had better preoperative PDE-pattern (stardust pattern stage II) in the leg with lower edema volume (Table 1). The patient was later operated on the other leg and had a volume reduction (not included in the study). The method of using the contralateral leg as control works well in both unilateral and bilateral lymphedema, since only one limb was operated during the study time, and the contralateral leg could therefore be used as control.

Five of 12 patients showed 1-8 % edema reduction in the lower extremity after 12 months, representing from -30 ml to -1945 ml respectively. Four of 12 patients showed a slight increase of the edema and three of twelve were unchanged (Figure 3-4). No significant

decrease in volume was seen when comparing pre- and postoperative volume measurements in the whole group. The two patients not suitable for LVAs and the 17 patients not chosen for surgery were referred back to the physiotherapist for conservative treatment and to a different hospital for liposuction.

Edema duration, number of anastomoses, previous radiotherapy and lymph node dissection were compared between patients with and without edema reduction after LVAs. Five patients treated with LVAs had undergone previous lymph node dissection and seven patients treated with LVAs had not. We found a 6.2 % significant difference in edema reduction ($p = 0.03$) in patients who had undergone lymph node dissection compared to patients who had not undergone lymph node dissection (Figure 5). No comparison of previous lymph node dissection was made in the 17 patients who were not treated with LVAs. We found no significant difference in edema reduction after LVAs in patients related to edema duration, number of anastomosis or previous radiotherapy ($p=n.s$).

Discussion

Previous studies have shown that surgery with LVAs in the lower extremity can reduce edema volume, but the results are variable and in general inferior to LVAs performed in the upper extremity (10-15). Koshima et al presented a study including 25 patients where conservative treatment vs. LVA-surgery was compared. LVA-surgery had better outcome with edema reduction in 8 of the 13 LVA-operated patients compared with the 14 patients treated conservatively. The average decrease in leg circumference in the patients operated with LVA was 4.7 cm +/- 2.8 cm. Those patients had a follow up time of on average 4.6 years (10).

Furthermore, a study including over 1500 patients operated with LVAs for peripheral lymphedema done by Campisi et al shows a 75 % volume reduction in 83 % of the patients. However, the results are difficult to interpret and compare because the measurement method

and edema volumes are not presented (11). Another study from Olszewski, including 1300 patients operated in the lower extremity and followed over 45 years, demonstrates greatest edema reduction in patients operated at an early stage, young patients with congenital non-hereditary hyperplastic lymphedema and patients operated with inguinal and iliac lymphadenectomy (12). The latter finding is now further supported in a prospective setting by our results, for the first time to our knowledge. In another prospective analysis by Chang et al including 100 patients, seven were operated with LVAs in the lower limbs and the rest were operated in the upper limb. Four of the seven patients operated in the lower limb noticed symptom improvement. Only two of the patients were available for postoperative measurements and both of these patients were operated bilaterally. One of the two showed a significant decrease of maximum 33% edema reduction after three years, the other patient did not show a significant edema reduction. In that study LVAs seems to be more effective in the upper extremities than in the lower extremities (13).

A study by Maegawa et al investigated 57 patients operated with LVA in the lower extremity. Of those, 34 patients had at least one patent anastomosis 12 months postoperatively. However, the anastomoses were only investigated with ICG fluorescence in the foot and ankle, and efficiency of more proximal anastomosis could not be evaluated. Volume measurements in the group with patent anastomoses vs. the group with no sign of patent anastomoses showed no significant difference in leg volume reduction (14). Different types of anastomosis configuration can be used (Narushima et al 2010). In this study we found Y-shape veins in four patients making flow-through LVAs possible. In the other eight patients end-to-end LVAs were performed as we found veins and lymphatic vessels of matching diameters. Overall, it is difficult to find a common method for the volume measurements. Many different measurement protocols have been used; it is therefore difficult to compare the present study with previous results. We used the formula for a truncated cone,

earlier described as a reliable volume measurement method (19), compared to the contralateral leg as a reference in a prospective setting.

Limitations of the study need to be acknowledged. The study has a limited sample size, but due to its prospective, controlled design it can still contribute to the knowledge about the treatment of lymphedema. One of our patients (nr 10) had a postoperative infection, which can explain a temporary increase in edema volume 6 months postoperatively. Another patient (nr 6) had erysipelas in the leg at the time for the 12 months' control, which can explain the increase in edema volume (Figure 3-4). We also want to note that some of our patients mainly had edema in their foot and ankle, and therefore our measurement method might not describe the change properly. The protocol to select, prepare, surgically treat and follow the patients was decided on the base of the literature when the study was started, in 2011.

The interest in this field has led to a number of studies (20-29) and development of new approaches both from the surgical and the medical point of view. The recent review of the literature from Scaglioni et al (30), clearly shows how many different protocols can be applied and how difficult is to find evidence-based superiority of one method.

A multitude of factors related to patient demographics and history (etiology, severity, year from onset, infectious episodes, previous medical- or surgical treatments), diagnostic methods, single or combined surgical options, results and evaluation are involved. Critical revision of the literature is therefore very difficult. Without sufficient evidence, the optimal treatment of the lower limb lymphedema patient is still not known. However, the available literature, despite the numerous variables described, seems to confirm favorable results of LVA in the treatment of lower limb lymphedema. While hoping for a consensus on this subject, we believe that a few tips may help in approaching this field to have a more rapid learning curve and satisfactory results of a condition that highly compromises the quality of

life. Our experience, together with the retrospective comparison of the published studies, led us to a series of thoughts on optimization of LVAs in lower limb lymphedema (Table 2).

Altogether, the outcomes from many previous studies have been difficult to interpret. Especially the lack of a standardized method for lymphedema measurement has hampered adequate comparisons between techniques and indications. However, multiple lymphaticovenular anastomoses seem to be favorable for the reduction of edema volume. LVAs seem also to be more effective in upper, compared to lower, extremities. The current study indicates that patients who have undergone previous lymph node dissection have a better outcome than others after treatment with LVAs. This may be explained by the fact that patients with lymphedema of other causes (i.e. blunt trauma, radiation only and idiopathic) may have a lymphatic system with less ability to adapt to new routes of drainage. In order to select the right patients, there is a need for further evaluation of the treatment method and finding other positive predictors of importance in larger prospective controlled studies.

Conclusions

Results from the current prospective controlled study indicates that supramicrosurgery with LVAs may reduce edema volumes in the lower extremities, where the most distinctive positive predictor for edema reduction with LVAs was previous lymph node dissection.

Acknowledgements

We would like to thank Eva Hagel, statistician at Karolinska Institutet, for assistance with the statistical analyses.

This paper is part of a Supplement supported by the European Federation of Societies of Microsurgery (EFSM)

The authors have no financial interest to declare in relation to the content of this article and the study is not financially supported. The authors alone are responsible for the content and writing of the paper.

References

1. Finnane A, Hayes SC, Obermair A, Janda M. Quality of life of women with lower-limb lymphedema following gynecological cancer. *Expert Rev Pharmacoeconomics Outcomes Res.* 2011;11(3):287-97.
2. Ko DS, Lerner R, Klose G, Cosimi AB. Effective treatment of lymphedema of the extremities. *Arch Surg.* 1998;133(4):452-8.
3. Baumeister RG, Siuda S, Bohmert H, Moser E. A microsurgical method for reconstruction of interrupted lymphatic pathways: autologous lymph-vessel transplantation for treatment of lymphedemas. *Scand J Plast Reconstr Surg.* 1986;20(1):141-6.
4. Becker C, Vasile JV, Levine JL, Batista BN, Studinger RM, Chen CM, et al. Microlymphatic surgery for the treatment of iatrogenic lymphedema. *Clin Plast Surg.* 2012;39(4):385-98.
5. Brorson H, Ohlin K, Olsson G, Svensson B, Svensson H. Controlled compression and liposuction treatment for lower extremity lymphedema. *Lymphology.* 2008;41(2):52-63.
6. O'Brien BM, Sykes P, Threlfall GN, Browning FS. Microlymphaticovenous anastomoses for obstructive lymphedema. *Plast Reconstr Surg.* 1977;60(2):197-211.
7. Granzow JW, Soderberg JM, Kaji AH, Dauphine C. Review of current surgical treatments for lymphedema. *Ann Surg Oncology.* 2014;21(4):1195-201.
8. Koshima I, Inagawa K, Urushibara K, Moriguchi T. Supermicrosurgical lymphaticovenular anastomosis for the treatment of lymphedema in the upper extremities. *J Reconstr Microsurg.* 2000;16(6):437-42.
9. Ogata F, Narushima M, Mihara M, Azuma R, Morimoto Y, Koshima I. Intraoperative lymphography using indocyanine green dye for near-infrared fluorescence

- labeling in lymphedema. *Ann Plast Surg.* 2007;59(2):180-4.
10. Koshima I, Nanba Y, Tsutsui T, Takahashi Y, Itoh S. Long-term follow-up after lymphaticovenular anastomosis for lymphedema in the leg. *J Reconstr Microsurg.* 2003;19(4):209-15.
11. Campisi C, Eretta C, Pertile D, Da Rin E, Campisi C, Maccio A, et al. Microsurgery for treatment of peripheral lymphedema: long-term outcome and future perspectives. *Microsurgery.* 2007;27(4):333-8.
12. Olszewski WL. Lymphovenous microsurgical shunts in treatment of lymphedema of lower limbs: a 45-year experience of one surgeon/one center. *European journal of vascular and endovascular surgery : the official journal of the European Society for Vascular Surgery.* 2013;45(3):282-90.
13. Chang DW, Suami H, Skoracki R. A prospective analysis of 100 consecutive lymphovenous bypass cases for treatment of extremity lymphedema. *Plast Reconstr Surg.* 2013;132(5):1305-14.
14. Maegawa J, Hosono M, Tomoeda H, Tosaki A, Kobayashi S, Iwai T. Net effect of lymphaticovenous anastomosis on volume reduction of peripheral lymphoedema after complex decongestive physiotherapy. *European journal of vascular and endovascular surgery : the official journal of the European Society for Vascular Surgery.* 2012;43(5):602-8.
15. Demirtas Y, Ozturk N, Yapici O, Topalan M. Supermicrosurgical lymphaticovenular anastomosis and lymphaticovenous implantation for treatment of unilateral lower extremity lymphedema. *Microsurgery.* 2009;29(8):609-18.
16. Mihara M, Hara H, Furniss D, Narushima M, Iida T, Kikuchi K, et al. Lymphaticovenular anastomosis to prevent cellulitis associated with lymphoedema. *British J Surg.* 2014;101(11):1391-6.
17. Narushima M, Yamamoto T, Ogata F, Yoshimatsu H, Mihara M, Koshima I.

Indocyanine Green Lymphography Findings in Limb Lymphedema. *J Reconstr Microsurg.* 2016;32(1):72-9.

18. Yamamoto T, Narushima M, Doi K, Oshima A, Ogata F, Mihara M, et al.

Characteristic indocyanine green lymphography findings in lower extremity lymphedema: the generation of a novel lymphedema severity staging system using dermal backflow patterns.

Plast Reconstr Surg. 2011;127(5):1979-86.

19. Brorson H, Hoijer P. Standardised measurements used to order compression

garments can be used to calculate arm volumes to evaluate lymphoedema treatment. *J Plast Surg Hand Surg* 2012;46(6):410-5.

20. Yamamoto T, Narushima M, Yoshimatsu H, Seki Y, Yamamoto N, Oka A et al.

Minimally invasive lymphatic supermicrosurgery (MILS): Indocyanine green lymphography-guided simultaneous multisite lymphaticovenular anastomoses via millimeter skin incisions.

Ann Plast Surg. 2014;72:67-70.

21. Yang JC, Wu SC, Chiang MH, Lin WC. Targeting reflux-free veins with a vein

visualizer to identify the ideal recipient vein preoperatively for optimal lymphaticovenous anastomosis in treating lymphedema. *Plast Reconstr Surg.* 2018;141:793–797.

22. Visconti G, Salgarello M, Hayashi A. The recipient venule in supermicrosurgical

lymphaticovenular anastomosis: flow dynamic classification and correlation with surgical outcomes. *J Reconstr Microsurg* 2018;34:581–9.

23. Garza RM, Chang DW. Lymphovenous bypass for the treatment of lymphedema. *J*

Surg Oncol 2018;118:743–9.

24. Hara H, Mihara M. Multi-area lymphaticovenous anastomosis with multi-lymphosome

injection in indocyanine green lymphography: a prospective study. *Microsurgery*

2019;39:167–73.

25. Hayashi A, Giacalone G, Yamamoto T. et al. ultra high-frequency ultrasonographic

- imaging with 70 MHz scanner for visualization of the lymphatic vessels. *Plast Reconstr Surg Glob Open* 2019;7:e 2086.
26. Kajita H, Oh A, Urano M, Takemaru M, Imanishi N, Otaki M et al. Kishi K. Photoacoustic lymphangiography. *J Surg Oncol* 2019 Jun 4.
27. Al-Jindan FK, Lin CY, Cheng MH. Comparison of Outcomes between Side-to-End and End-to-End Lymphovenous Anastomoses for Early-Grade Extremity Lymphedema. *Plast Reconstr Surg*. 2019 May 10.
28. Klingelhofer E, Hesse K, Taeger CD, Prantl L, Stepniewski A, Felmerer G. Factors affecting outcomes after supermicrosurgical lymphovenous anastomosis in a defined patient population. *Clin Hemorheol Microcirc*. 2019;73(1):53-63.
29. Rosian K, Stanak M. Efficacy and safety assessment of lymphovenous anastomosis in patients with primary and secondary lymphoedema: A systematic review of prospective evidence. *Microsurgery*. 2019 Nov;39(8):763-772.
30. Scaglioni MF, Fontein DBY, Arvanitakis M, Giovanoli P. Systematic review of lymphovenous anastomosis (LVA) for the treatment of lymphedema. *Microsurgery*. 2017 Nov;37(8):947-953.

Legends

Figure 1. Inclusion and exclusion criteria.

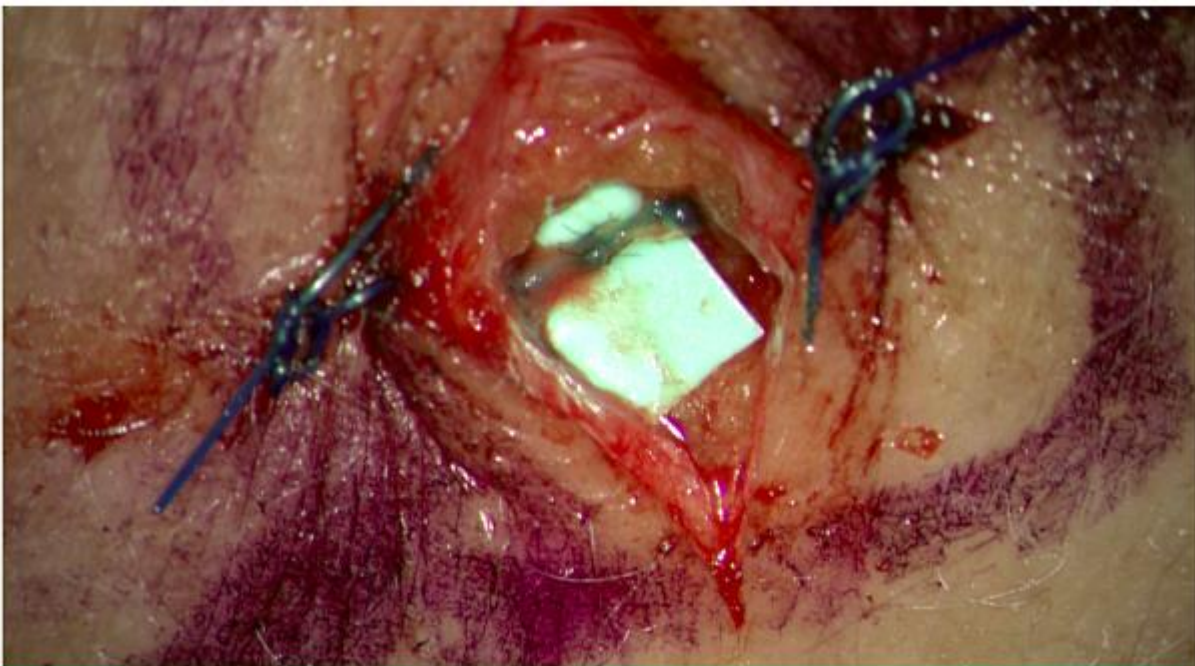
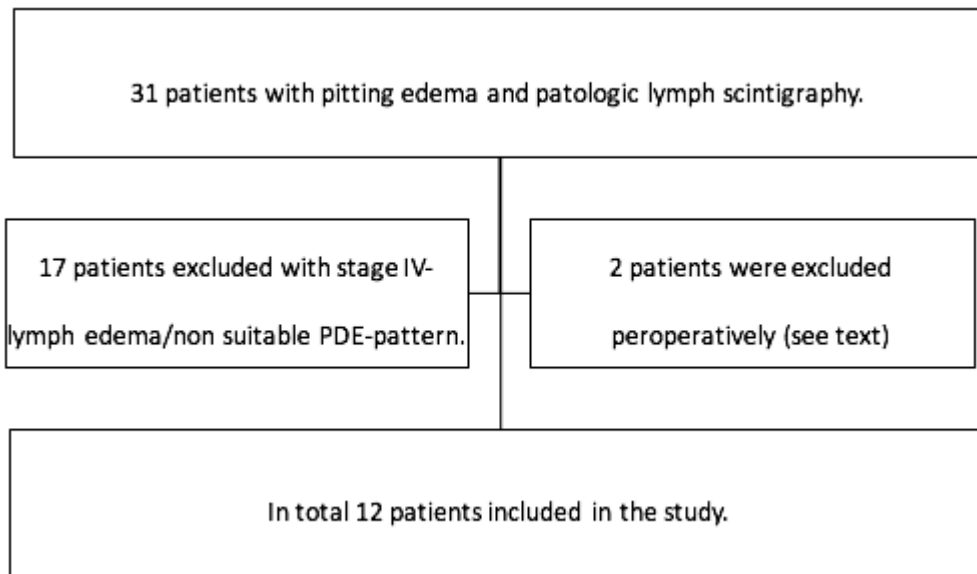
Figure 2. Lymphaticovenular anastomosis with lymphatic flow into the vein, stained with Patentblau V.

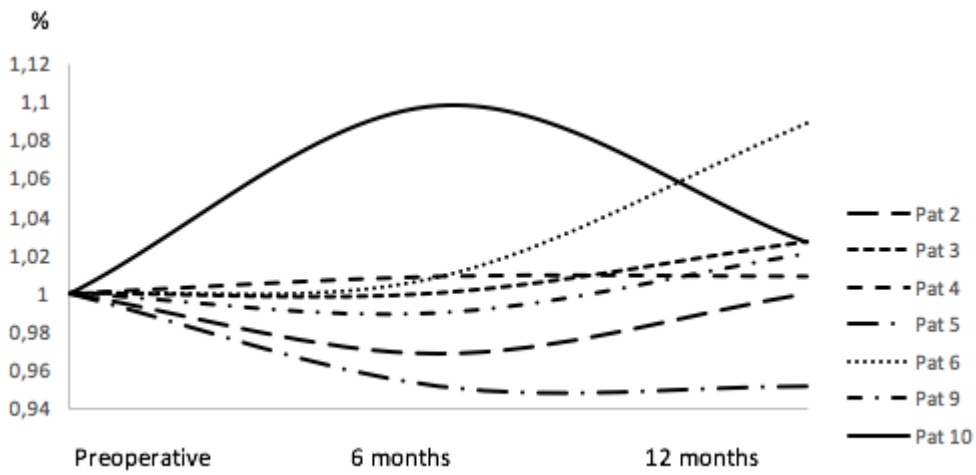
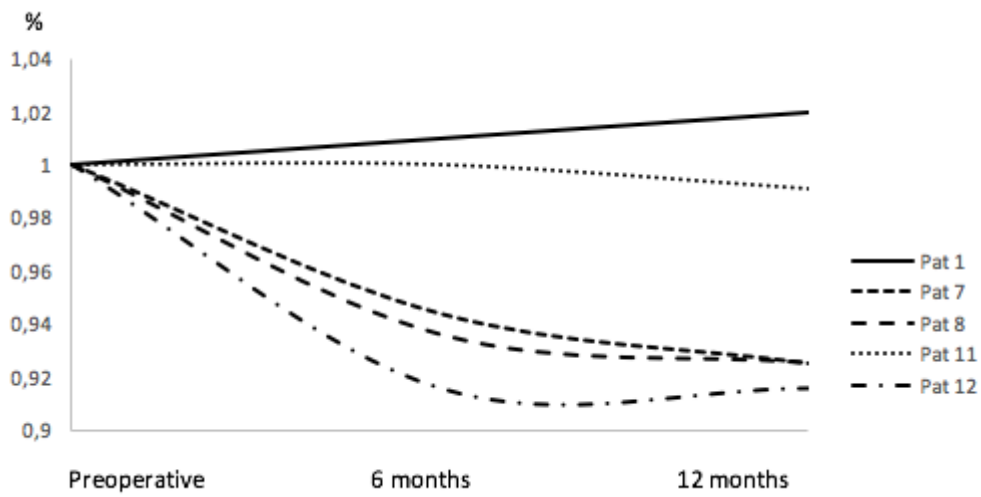
Figure 3. Patients operated with lymph node dissection (n = 5), edema reduction in percent over time.

Figure 4. Patients operated without lymph node dissection (n = 7), edema reduction in percent over time.

Figure 5. Difference in postoperative edema reduction (6.2 %) after 12 months (p = 0.03).

This paper is part of a Supplement supported by the European Federation of Societies of Microsurgery (EFSM)





Difference in percent at 12 months follow-up

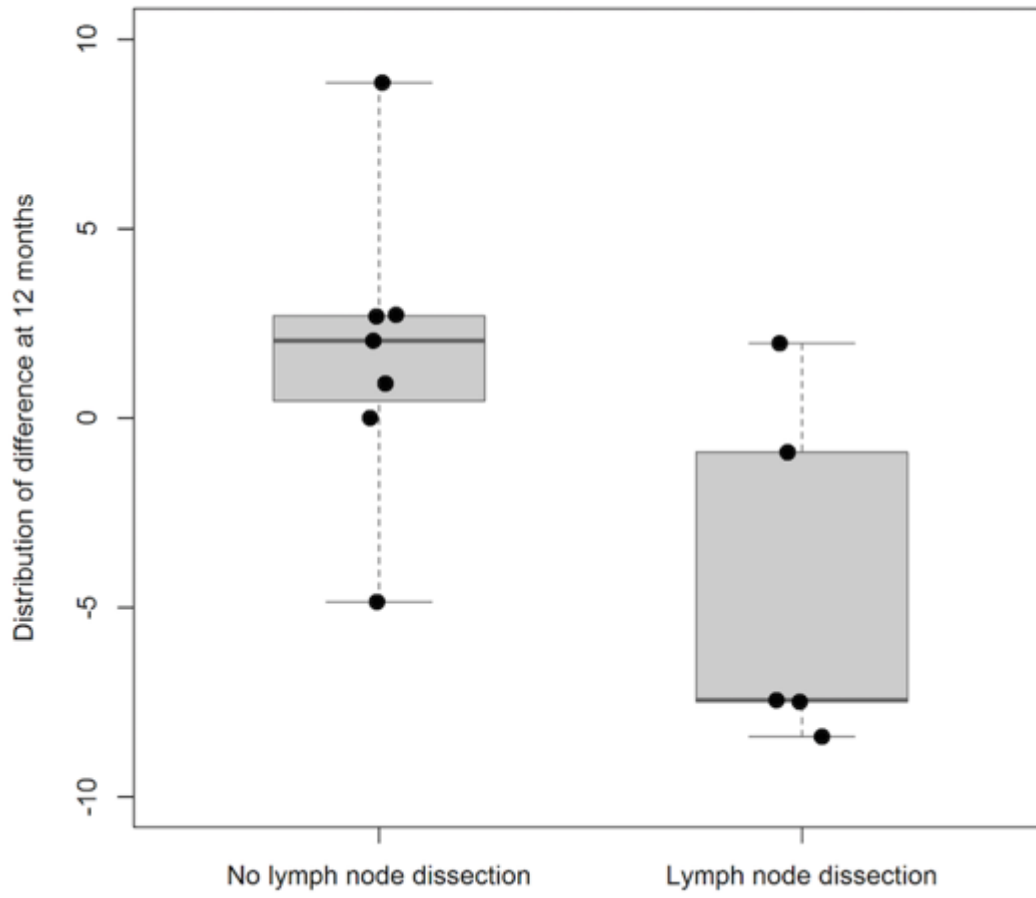


Table 1. Epidemiological aspects of the study group.
Patients operated with LVA (n = 12)

Gender (male/female)	1/11
Cause of lymphedema	
Cancer surgery	8
Unknown cause/primary lymph edema	4
Age (years)	
Median (range)	51 (41-66)
Years of edema	
Median (range)	4 (3-11)
Preoperative edema volume* (mL)	
Median (range)	626 (-756-1871)
Preoperative edema volume *(%)	
Median (range)	8.5 % (-6-27 %)
Operating time (min)	
Median (range)	223.5 (197-273)

OPTIONS in literature	OUR study		OUR preference
Age of patients	All ages	51(41-66)	Only adults in the present study
Etiology	Primary vs secondary	Primary 4 pts vs Secondary 8 pts	Two different groups. Best to divide them. (Connell et al. 2013, Scaglioni 2017)
Physiopathological factors	VEGFR3 signaling pathway	-	Subgroups of patients may be found (Mendola 2013)
Time since onset (months)	6 to 127	36 to 132	Early treatment better
Severity	Mild to severe lymphedema (Stage I to V)	Stage II to III lymphedema	Early stage better (Schaverien 2019, Rosian 2019)
Cellulitis	Direct correlation cellulitis/lymphedema	Not studied	Improving lymphedema reduces numbers of cellulitis episodes (Sharkey 2017)
Imaging for finding vessels	ICG, Ultrasound, Doppler ultrasound, Computed tomographic venography, magnetic resonance venography	ICG	ICG, Ultra sound, Vein viewer (Yang 2018, Visconti 2018)
Anastomotic technique	End-to-end, end-to-side, side-to-end	End-to-end	Technique related to anatomy of vessels (Schaverien 2019)
Number of anastomoses	2-10 mean (Chang, Suami, & Skoracki, 2013; Mihara et al., 2016; Szuba & Rockson, 1998)	1-4	Advantage with more anastomoses. Anatomy, surgical settings and time are deciding factors. (Scaglioni 2017)
Combined surgical treatment	Compressive therapy or additional debulking surgery (Liposuction). Surgical resection of excess tissue. Vascularized lymphnode transfer.	Only LVA in present study	LVA studied separately.
Following treatment	Compressive garments, massage	Compressive garments	Compressive garments
Subjective results	Symptom improvement	Symptom improvement	Symptom improvement (Scaglioni 2017)
Objective results	Circumference, Volumetric measurements, Lower Extremity Lymphedema	Lower limb volume truncated cone formula	Lower limb volume (calculated or volumetric)