

CLINICAL PRACTICE GUIDELINES

Soft tissue and visceral sarcomas: ESMO–EURACAN Clinical Practice Guidelines for diagnosis, treatment and follow-up[†]

P. G. Casali¹, N. Abecassis², S. Bauer³, R. Biagini⁴, S. Bielack⁵, S. Bonvalot⁶, I. Boukovinas⁷, J. V. M. G. Bovee⁸, T. Brodowicz⁹, J. M. Broto¹⁰, A. Buonadonna¹¹, E. De Álava¹⁰, A. P. Dei Tos¹², X. G. Del Muro¹³, P. Dileo¹⁴, M. Eriksson¹⁵, A. Fedenko¹⁶, V. Ferraresi¹⁷, A. Ferrari¹⁸, S. Ferrari¹⁹, A. M. Frezza¹, S. Gasperoni²⁰, H. Gelderblom²¹, T. Gil²², G. Grignani²³, A. Gronchi¹, R. L. Haas²⁴, A. Hannu²⁵, B. Hassan²⁶, P. Hohenberger²⁷, R. Issels²⁸, H. Joensuu²⁹, R. L. Jones³⁰, I. Judson³¹, P. Jutte³², S. Kaal³³, B. Kasper²⁷, K. Kopeckova³⁴, D. A. Krákorová³⁵, A. Le Cesne³⁶, I. Lugowska³⁷, O. Merimsky³⁸, M. Montemurro³⁹, M. A. Pantaleo⁴⁰, R. Piana⁴¹, P. Picci¹⁹, S. Piperno-Neumann⁶, A. L. Pousa⁴², P. Reichardt⁴³, M. H. Robinson⁴⁴, P. Rutkowski³⁷, A. A. Safwat⁴⁵, P. Schöffski⁴⁶, S. Sleijfer⁴⁷, S. Stacchiotti⁴⁸, K. Sundby Hall⁴⁹, M. Unk⁵⁰, F. Van Coevorden⁵¹, W. Van der Graaf³⁰, J. Whelan⁵², E. Wardelmann⁵³, O. Zaikova⁵⁴ & J. Y. Blay⁵⁵, on behalf of the ESMO Guidelines Committee and EURACAN*

¹Fondazione IRCCS Istituto Nazionale dei Tumori and University of Milan, Milan, Italy; ²Instituto Portugues de Oncologia de Lisboa Francisco Gentil, EPE, Lisbon, Portugal; ³University Hospital Essen, Essen, Germany; ⁴Department of Oncological Orthopedics, Musculoskeletal Tissue Bank, IFO, Regina Elena National Cancer Institute, Rome, Italy; ⁵Klinikum Stuttgart-Olgahospital, Stuttgart, Germany; ⁶Institut Curie, Paris, France; ⁷NORDIX, Athens, Greece; ⁸Department of Pathology, Leiden University Medical Center, Leiden, The Netherlands; ⁹Vienna General Hospital (AKH), Medizinische Universität Wien, Vienna, Austria; ¹⁰Hospital Universitario Virgen del Rocío-CIBERONC, Seville, Spain; ¹¹Centro di Riferimento Oncologico di Aviano, Aviano; ¹²Ospedale Regionale di Treviso “S.Maria di Cà Foncello”, Treviso, Italy; ¹³Integrated Unit ICO Hospitalet, HUB, Barcelona, Spain; ¹⁴Sarcoma Unit, University College London Hospitals, London, UK; ¹⁵Skane University Hospital-Lund, Lund, Sweden; ¹⁶N. N. Blokhin Russian Cancer Research Center, Moscow, Russian Federation; ¹⁷Institute of Scientific Hospital Care (IRCCS), Regina Elena National Cancer Institute, Rome; ¹⁸Pediatric Oncology Unit, Fondazione IRCCS Istituto Nazionale dei Tumori, Milan; ¹⁹Istituto Ortopedico Rizzoli, Bologna; ²⁰Azienda Ospedaliera Universitaria Careggi Firenze, Florence, Italy; ²¹Department of Medical Oncology, Leiden University Medical Centre, Leiden, The Netherlands; ²²Institut Jules Bordet, Brussels, Belgium; ²³Candiolo Cancer Institute, FPO IRCCS, Candiolo, Italy; ²⁴Department of Radiotherapy, The Netherlands Cancer Institute, Amsterdam and Department of Radiotherapy, Leiden University Medical Centre, Leiden, The Netherlands; ²⁵Turku University Hospital (Turun Yliopistollinen Keskussairaala), Turku, Finland; ²⁶Oxford University Hospitals NHS Foundation Trust, Oxford, UK; ²⁷Mannheim University Medical Center, Mannheim; ²⁸Department of Medicine III, University Hospital, Ludwig-Maximilians-University Munich, Munich, Germany; ²⁹Helsinki University Central Hospital (HUCH), Helsinki, Finland; ³⁰Royal Marsden Hospital, London; ³¹The Institute of Cancer Research, London, UK; ³²University Medical Center Groningen, Groningen; ³³Radboud University Medical Center, Nijmegen, The Netherlands; ³⁴University Hospital Motol, Prague; ³⁵Masaryk Memorial Cancer Institute, Brno, Czech Republic; ³⁶Gustave Roussy Cancer Campus, Villejuif, France; ³⁷Maria Skłodowska Curie Institute, Oncology Centre, Warsaw, Poland; ³⁸Tel Aviv Sourasky Medical Center (Ichilov), Tel Aviv, Israel; ³⁹Medical Oncology, University Hospital of Lausanne, Lausanne, Switzerland; ⁴⁰Azienda Ospedaliera, Università, Policlinico S Orsola-Malpighi Università di Bologna, Bologna; ⁴¹Azienda Ospedaliera, Università Cita della Salute e della Scienza di Torino, Turin, Italy; ⁴²Fundació de Gestió Sanitària de L'hospital de la SANTA CREU I Sant Pau, Barcelona, Spain; ⁴³Helios Klinikum Berlin Buch, Berlin, Germany; ⁴⁴YCRC Department of Clinical Oncology, Weston Park Hospital NHS Trust, Sheffield, UK; ⁴⁵Aarhus University Hospital, Aarhus, Finland; ⁴⁶Leuven Cancer Institute, Leuven, Belgium; ⁴⁷Department of Medical Oncology, Erasmus MC Cancer Institute, Rotterdam, The Netherlands; ⁴⁸Fondazione Istituto di Ricovero e Cura a Carattere Scientifico, Istituto Nazionale dei Tumori, Milan, Italy; ⁴⁹Department of Oncology, Oslo University Hospital, The Norwegian Radium Hospital, Oslo, Norway; ⁵⁰Institute of Oncology of Ljubljana, Ljubljana, Slovenia; ⁵¹Netherlands Cancer Institute Antoni van Leeuwenhoek, Amsterdam, The Netherlands; ⁵²University College Hospital, London, UK; ⁵³Gerhard-Domagk-Institut für Pathologie, Universitätsklinikum Münster, Münster, Germany; ⁵⁴Oslo University Hospital, Norwegian Radium Hospital, Oslo, Norway; ⁵⁵Centre Leon Bernard and UCBL1, Lyon, France

*Correspondence to: ESMO Guidelines Committee, ESMO Head Office, Via Ginevra 4, 6900 Lugano, Switzerland. E-mail: clinicalguidelines@esmo.org

[†]Approved by the ESMO Guidelines Committee and EURACAN: December 2017.

Soft tissue sarcomas (STSs) gather over 80 histological entities, with even more molecular subsets, characterised by a low to very low incidence in all populations. The majority of sarcomas arise from the soft tissue (close to 75%), with ~15% gastrointestinal stromal tumours (GISTs) and 10% bone sarcomas. These ESMO–EURACAN (European Society for Medical Oncology–

European Reference Network for rare adult solid cancers) Clinical Practice Guidelines cover STSs, while GISTs are covered by dedicated ESMO–EURACAN Clinical Practice Guidelines [1]. Kaposi's sarcoma is not considered in the present document. Extraskelatal Ewing and Ewing-like sarcoma is covered by ESMO Clinical Practice Guidelines on bone sarcomas [2]. In general, the

same principles for these tumours in children apply to adults. This is also the case for embryonal and alveolar rhabdomyosarcomas, which are exceedingly rare in adults. On the other hand, pleomorphic rhabdomyosarcoma is viewed as a high-grade, adult-type STS. Extraskelatal osteosarcoma is also a high-grade STS, whose clinical resemblance with osteosarcoma of bone is doubtful (prospective collection of data is encouraged to generate evidence on the therapeutic implications of such a diagnosis). Adult STS pathological subtypes occurring in adolescents should be managed the same way as in adult patients, though the same histotype might display clinical peculiarities when occurring at different ages.

Incidence and epidemiology

Adult soft tissue and visceral sarcomas (excluding GIST) are rare tumours, with an estimated incidence averaging 4–5/100 000/year in Europe [3]. STSs include over 80 different histological subtypes, and the most frequent, liposarcomas and leiomyosarcomas (LMSs), each have an incidence < 1/100 000/year. The majority of sarcoma histotypes therefore have an incidence < 2/1 000 000/year.

Diagnosis and pathology/molecular biology

STSs are ubiquitous in their site of origin and are often managed with multimodality treatment. A multidisciplinary approach is, therefore, mandatory in all cases, involving pathologists, radiologists, surgeons, radiation therapists, medical oncologists and paediatric oncologists, as well as nuclear medicine specialists and organ-based specialists, as applicable. Management should be carried out in reference centres for sarcomas and/or within reference networks sharing multidisciplinary expertise and treating a high number of patients annually. These centres are involved in ongoing clinical trials, in which the enrolment of sarcoma patients is common. This centralised referral should be pursued as early as at the time of the clinical diagnosis of a suspected sarcoma. In practice, referral of all patients with a lesion likely to be a sarcoma would be recommended. This would mean referring all patients with an unexplained deep mass of soft tissues, or with a superficial lesion of soft tissues having a diameter of > 5 cm. Quality criteria are needed for sarcoma reference centres and, increasingly, reference networks. These criteria may vary from country to country but, among others, should be based on: multidisciplinary (incorporating tools such as weekly tumour boards discussing new cases), volume of patients, availability of facilities needed to properly apply clinical practice guidelines, recording and publication of outcomes and involvement in clinical and translational research.

In primary soft tissue tumours, magnetic resonance imaging (MRI) is the main imaging modality in the extremities, pelvis and trunk. Standard radiographs may be useful to rule out a bone tumour, to detect bone erosion with a risk of fracture and to show calcifications. Computed tomography (CT) has a role in calcified lesions, to rule out a myositis ossificans, and in retroperitoneal tumours, where the performance is identical to MRI. Ultrasound may be the first exam, but it should be followed by CT or MRI.

Following appropriate imaging assessment, the standard approach to diagnosis consists of multiple core needle biopsies,

possibly by using ≥ 14 –16 G needles. However, an excisional biopsy may be the most practical option for < 3 cm superficial lesions. An open biopsy may be another option in selected cases, as decided within reference centres. An immediate evaluation of tissue viability may be considered to ensure that the biopsy is adequate at the time it is carried out. However, a frozen-section technique for immediate diagnosis is not encouraged, because it does not allow a complete diagnosis, particularly when neoadjuvant (preoperative) treatment is planned. Fine needle aspiration is used only in some institutions that have developed specific expertise on this procedure and is not recommended outside these centres. A biopsy may underestimate the tumour malignancy grade. Therefore, when preoperative treatment is an option, radiological imaging [including positron emission tomography (PET)] may be useful, in addition to pathology, in providing the clinician with information that helps to estimate the malignancy grade (e.g. necrosis). The biopsy should be carried out by a surgeon or a radiologist after multidisciplinary discussion, as needed, within reference centres. It should be planned in such a way that the biopsy pathway and the scar can be safely removed by definitive surgery [except for retroperitoneal sarcomas (RPSs)]. The biopsy entrance point can be tattooed. The tumour sample should be fixed in 4% buffered formalin rapidly (Bouin fixative should not be used, since it prevents molecular analysis). The collection of fresh frozen tissue and tumour imprints (touch preparations) is encouraged to allow new molecular pathology assessments to be made at a later stage when requested. In this perspective, the availability of a blood sample could add to the value of tumour tissues. Informed consent for biobanking should be sought, enabling later analyses and research, if this is allowed by local and international rules.

Pathological diagnosis should be made according to the 2013 World Health Organization (WHO) classification [4]. A pathological expert validation is required in all cases when the original diagnosis was made outside a reference centre/network [5].

The malignancy grade should be provided in all cases in which this is feasible based on available systems, because it has prognostic and predictive meaning. The Fédération Nationale des Centres de Lutte Contre le Cancer (FNCLCC) grading system is generally used, and distinguishes three malignancy grades based on differentiation, necrosis and mitotic rate [6]. Whenever possible, the mitotic rate should be provided independently. Grading cannot be assigned after preoperative medical treatment, by which the tumour tissue undergoes major therapy-related changes.

Tumour site should be properly recorded. Tumour size and tumour depth (in relation to the superficial fascia) should also be recorded, since they entail a prognostic value, along with the malignancy grade. The pathology report after definitive surgery should mention whether the tumour was intact and should include an appropriate description of tumour margins (i.e. the status of inked margins and the distance in millimetres between tumour edge and the closest inked margins). This allows the assessment of margin status (i.e. whether the minimum margin is intralesional, marginal or wide and distances from surrounding tissues). The pathological assessment of margins should be made in collaboration with the surgeon.

If preoperative treatment was carried out, the pathology report should include an assessment of the pathological response of the tumour. In contrast to osteosarcoma and Ewing

sarcoma, however, no validated system is available at present. A multidisciplinary judgement is recommended, involving the pathologist and the radiologist.

Pathological diagnosis relies on morphology and immunohistochemistry. It should be complemented by molecular pathology, especially when:

- the specific pathological diagnosis is doubtful;
- the clinical pathological presentation is unusual; and
- it may have prognostic and/or predictive relevance.

External quality assurance programmes are strongly encouraged for laboratories performing molecular pathology assessments.

Staging and risk assessment

Available staging classifications have limited relevance and should be improved. The Union for International Cancer Control (UICC) stage classification system, 8th edition (Table 1) stresses the importance of the malignancy grade in sarcoma [7]. In general, in addition to grading, other prognostic factors are tumour size and tumour depth for limb sarcomas. Of course, site, tumour resectability and presence of metastases are also important. Nomograms are available, which can help personalise risk assessment and thus clinical decision making, especially on adjuvant/neoadjuvant treatments [8, 9].

A chest spiral CT scan is mandatory for staging purposes. Regional lymph node metastases are rare, with the exception of some histologies, e.g. epithelioid sarcoma and clear cell sarcoma, for which regional assessment through CT/MRI may be added to the usual staging procedures. Likewise, an abdominal CT scan may be added for limb myxoid liposarcoma. The brain CT scan may be added for alveolar soft part sarcoma, clear cell sarcoma and angiosarcoma.

Bone scan, whole-body MRI and PET scan are optional. Cost-effectiveness studies on their incorporation into the staging procedures are required. The surgical report, or patient chart, should provide details on:

- preoperative and intraoperative diagnosis;
- surgical conduct, including possible contaminations (i.e. it should mention whether the tumour was opened and was 'seen' during the excision, etc.); and
- surgical actual completeness vis-a-vis planned quality of margins.

Management of local/locoregional disease (see Figures 1 and 2)

Surgery is the standard treatment of all patients with an adult type, localised STS. It must be carried out by a surgeon specifically trained in the treatment of this disease. The standard surgical procedure is a wide excision with negative margins (no tumour at the margin, R0). This implies removing the tumour with a rim of normal tissue around it [II, A] [10]. The minimal margin on fixed tissue to be considered adequate may depend on several factors, including histological subtype, preoperative therapies and the presence of resistant anatomical barriers, such as muscular fasciae, periosteum and epineurium. As an individualised option, marginal excision can be acceptable in carefully selected cases, in particular for extracompartmental atypical lipomatous tumours [IV, B].

The typical wide excision is followed by radiotherapy (RT) as the standard treatment of high-grade (G2–3), deep, > 5 cm lesions [II, B] [11–13]. RT is not given in the case of a currently unusual, truly compartmental resection of a tumour entirely contained within the compartment [IV, A]. Exceptions may be made after multidisciplinary discussion considering several variables [14]. With exceptions to be discussed in a multidisciplinary setting and faced with a lack of consensus across reference centres, high-grade, deep, < 5 cm lesions are also treated with surgery, followed by RT [IV, A]. RT is added in selected cases in the case of low- or high-grade, superficial, > 5 cm and low-grade, deep, < 5 cm STSs [II, B]. In the case of low-grade, deep, > 5 cm STSs, RT should be discussed in a multidisciplinary fashion, considering the anatomical site and the related expected sequelae versus the pathological aggressiveness.

Local control and survival are not influenced by the timing of RT, but early and late complications are. If it is anticipated that wound complications will be severe, surgery followed by adjuvant RT may be the best option. RT should then be administered with the best technique available, to a total dose of 50 Gy in 1.8–2 Gy fractions, possibly with a boost up to 66 Gy, depending on presentation and resection margins. If it is anticipated that wound complications will be a manageable problem, neoadjuvant RT, possibly in combination with chemotherapy (ChT) to a total dose of 50 Gy in 1.8–2 Gy fractions, followed by surgery may be considered [15]. In addition, with modern RT techniques such as image-guided RT and intensity-modulated radiotherapy (IMRT), the anticipated incidence of wound complications after preoperative RT is lower than historically published incidence rates. The main advantage of preoperative RT is that, with prolonged follow-up, late morbidity (fibrosis, bone fracture, etc.) is lower, translating into improved long-term functional outcome and quality of life (QoL).

Reoperation in reference centres must be considered in the case of R1 resections (microscopic tumour at the margin), if adequate margins can be achieved without major morbidity, taking into account tumour extent and tumour biology (e.g. re-excision can be spared in extracompartmental atypical lipomatous tumours) [IV, A]. In the case of R2 surgery (macroscopic tumour at the margin), reoperation in reference centres is mandatory, possibly following preoperative treatments if adequate margins cannot be achieved, or if surgery is mutilating. In the latter case, the use of multimodal therapy with less radical surgery is optional and requires shared decision making with the patient in cases of uncertainty. Plastic repairs and vascular grafting should be used as needed, and the patient should be properly referred as necessary.

RT will follow marginal or R1–R2 excisions, if these cannot be rescued through re-excision, tailoring the decision depending on further considerations, including impact on future surgeries.

Mutilating surgery may be of choice in some cases. Options for limb-preserving surgery can be discussed with the patient, including ChT and/or RT [III, A], or isolated hyperthermic limb perfusion with tumour necrosis factor alpha (TNF- α) plus melphalan [III, A], if the tumour is confined to an extremity, or regional hyperthermia combined with ChT [I, B] [16]. These options are also proposed for non-resectable tumours, i.e. in truly locally advanced disease.

Regional lymph node metastases should be distinguished from soft tissue metastases involving lymph nodes. They are rare and constitute an adverse prognostic factor in adult-type STSs. More

Table 1. STS UICC TNM 8 staging system [7]

T—primary tumour

TX	Primary tumour cannot be assessed
T0	No evidence of primary tumour
<i>Extremity and superficial trunk</i>	
T1	Tumour 5 cm or less in greatest dimension
T2	Tumour more than 5 cm but no more than 10 cm in greatest dimension
T3	Tumour more than 10 cm but no more than 15 cm in greatest dimension
T4	Tumour more than 15 cm in greatest dimension
<i>Retroperitoneum</i>	
T1	Tumour 5 cm or less in greatest dimension
T2	Tumour more than 5 cm but no more than 10 cm in greatest dimension
T3	Tumour more than 10 cm but no more than 15 cm in greatest dimension
T4	Tumour more than 15 cm in greatest dimension
<i>Head and neck</i>	
T1	Tumour 2 cm or less in greatest dimension
T2	Tumour more than 2 cm but no more than 4 cm in greatest dimension
T3	Tumour more than 4 cm in greatest dimension
T4a	Tumour invades the orbit, skull base or dura, central compartment viscera, facial skeleton, and or pterygoid muscles
T4b	Tumour invades the brain parenchyma, encases the carotid artery, invades prevertebral muscle or involves the central nervous system by perineural spread
<i>Thoracic and abdominal viscera</i>	
T1	Tumour confined to a single organ
T2a	Tumour invades serosa or visceral peritoneum
T2b	Tumour with microscopic extension beyond the serosa
T3	Tumour invades another organ or macroscopic extension beyond the serosa
T4a	Multifocal tumour involving no more than two sites in one organ
T4b	Multifocal tumour involving more than two sites but not more than five sites
T4c	Multifocal tumour involving more than five sites

N—regional lymph nodes

NX	Regional lymph nodes cannot be assessed
N0	No regional lymph node metastasis
N1	Regional lymph node metastasis

M—distant metastasis

M0	No distant metastasis
M1	Distant metastasis

Stage—extremity and superficial trunk and retroperitoneum

Stage IA	T1	N0	M0	G1, GX Low Grade
Stage IB	T2, T3, T4	N0	M0	G1, GX Low Grade
Stage II	T1	N0	M0	G2, G3 High Grade
Stage IIIA	T2	N0	M0	G2, G3 High Grade
Stage IIIB	T3, T4	N0	M0	G2, G3 High Grade
Stage IIIB	Any T	N1 ^a	M0	Any G
Stage IV	Any T	Any N	M1	Any G

Stage—head and neck and thoracic and abdominal viscera

There is no stage for soft tissue sarcoma of the head and neck and thoracic and abdominal viscera.

^aAJCC classifies N1 as stage IV for extremity and superficial trunk.

pTNM Pathological Classification: the pT and pN categories correspond to the T and N categories. The only pM category is pM1 (distant metastasis microscopically confirmed), pM0 is not a valid category.

AJCC, American Joint Committee on Cancer; STS, soft tissue sarcoma; TNM, tumour, node, metastasis; UICC, Union for International Cancer Control.

Reprinted from [7] with permission from John Wiley & Sons, Inc.

aggressive treatment planning is, therefore, felt to be appropriate for these patients, although there is a lack of formal evidence to indicate that this improves clinical results. Surgery through wide excision (mutilating surgery is exceptionally done, given the

prognosis of these patients) may be coupled with adjuvant RT and adjuvant ChT for sensitive histological types, as the standard treatment of these presentations [IV, B]. ChT may be administered as preoperative treatment, at least in part. Given the paucity of

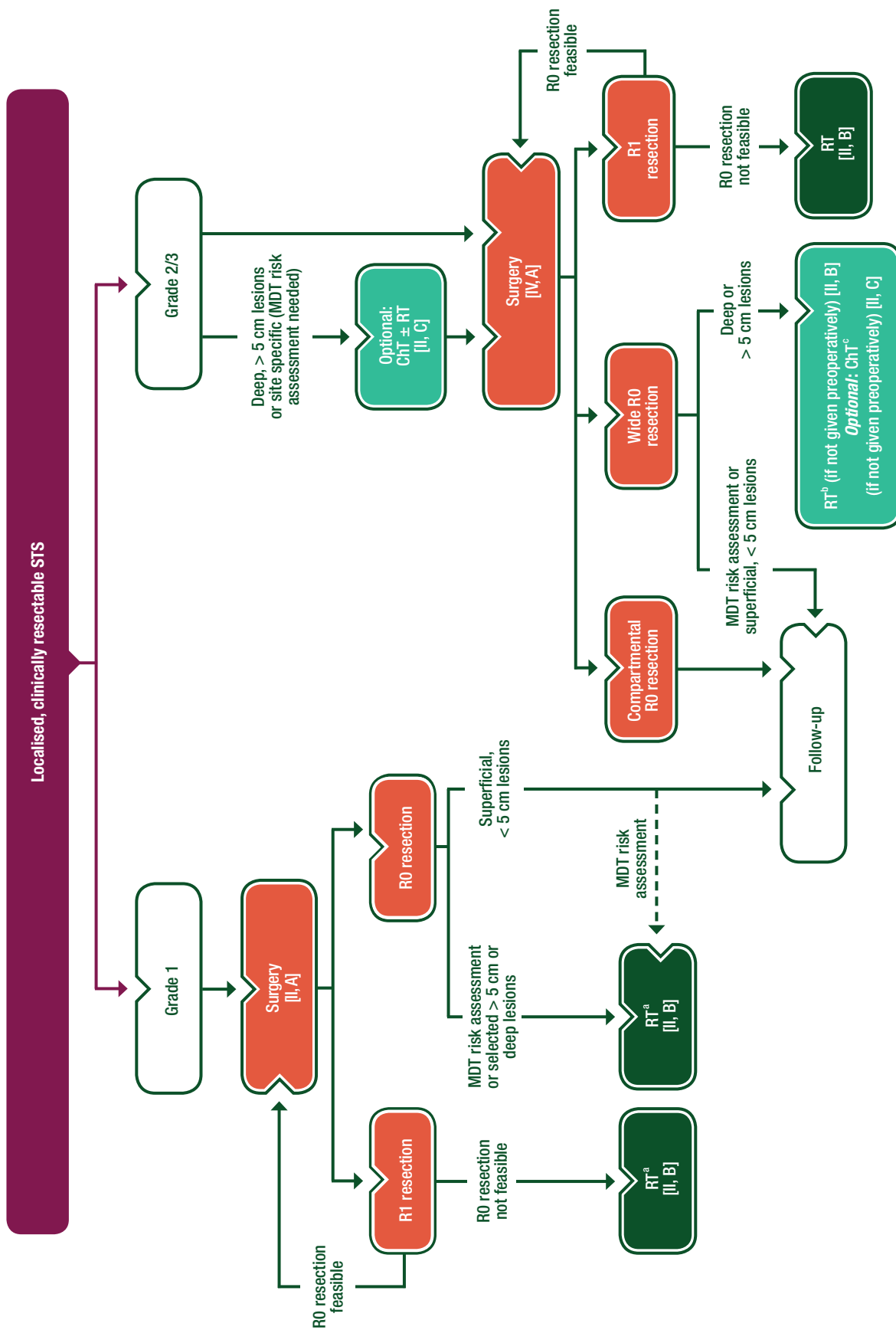


Figure 1. Management of localised, clinically resectable STS.

^aRT can be omitted in selected cases; *isolated limb perfusion* in highly selected cases.

^bRT can be omitted in selected deep cases and added in selected superficial cases; to be administered preoperatively if problematic postoperatively.

^cExtremity and superficial trunk, G3, deep, > 5 cm.

ChT, chemotherapy; MDT, multidisciplinary team; R0, no tumour at the margin; R1, microscopic tumour at the margin; RT, radiotherapy; STS, soft tissue sarcoma.

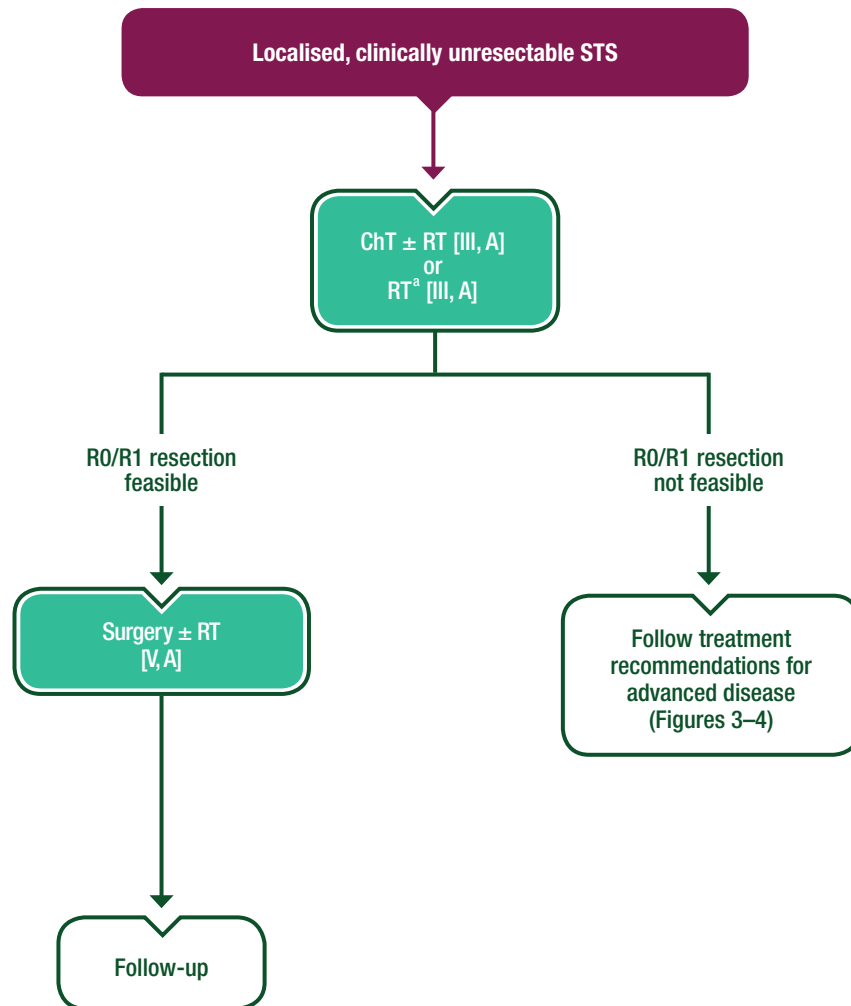


Figure 2. Management of localised, clinically unresectable STS.

^aOptional: isolated limb perfusion in selected cases.

ChT, chemotherapy; R0, no tumour at the margin; R1, microscopic tumour at the margin; RT, radiotherapy; STS, soft tissue sarcoma.

published data on adjuvant RT after lymph node dissections in regional metastatic STS, the indication should probably be reserved for patients with a relatively large number of tumour-positive lymph nodes and/or extranodal spread in the absence of haematogenous metastases. The increase in local control should be balanced against toxicity (especially peripheral lymphoedema). These treatment modalities added to surgery should not be viewed as truly ‘adjuvant’, the context being, in fact, that of a likely systemic disease. In one large, randomised phase III study (in patients with G2–3, deep, > 5 cm STSs), regional hyperthermia in addition to systemic ChT was associated with a local control and disease-free survival (DFS) advantage when compared with ChT alone [I, B]. Isolated limb perfusion may be an option in this patient population. This modality obviously has no impact on systemic control (but it can be combined with other modalities) [III, A] [17].

There is no consensus on the current role of adjuvant ChT. Study results are conflicting, in the presence of negative results from the largest studies, though data are available from smaller studies suggesting that adjuvant ChT might improve, or at least delay, distant and local recurrence in high-risk patients [18, 19]. A meta-analysis on published data found a statistically significant

limited benefit in terms of both relapse-free survival (RFS) and overall survival (OS) [20]. Gain in OS was not significant on the only meta-analysis using source data [21]. Given the conflicting results of trials included in the meta-analyses, adjuvant ChT is not standard treatment in adult-type STS. It can be proposed as an option to the high-risk individual patient (high-grade, deep, > 5 cm tumour) for a shared decision making with the patient [II, C]. ChT was used as neoadjuvant treatment, aiming at a local benefit facilitating surgery, in addition to the systemic one. A randomised trial showed no differences between three (preoperative) and five (pre- and postoperative) courses of full-dose ChT in high-risk STS patients [22]. A subsequent trial compared preoperative ChT with full-dose epirubicin plus ifosfamide versus a histology-driven ChT. This trial was closed slightly in advance because three interim analyses showed a statistically significant benefit in terms of both RFS and OS in favour of neoadjuvant therapy with epirubicin and ifosfamide. Since there is no obvious evidence that histology-driven ChT could be detrimental, this may be viewed as providing randomised evidence of the efficacy of neoadjuvant therapy with full-dose anthracyclines plus ifosfamide in high-risk extremity and superficial trunk STS ‘fit’ patients (i.e. with

lesions > 5 cm, deep, of a high-grade histology including undifferentiated pleomorphic sarcoma, liposarcoma, LMS, malignant peripheral nerve sheath tumour and synovial sarcoma). However, this evidence currently corresponds to an interim planned analysis within a trial statistically conceived to test the superiority of a histology-driven ChT [23]. The trial has been amended to test the superiority of epirubicin plus ifosfamide over the histology-driven therapy at the time of the final analysis. While awaiting these results, neoadjuvant ChT with anthracyclines plus ifosfamide for at least three cycles can be viewed as an option in the high-risk individual patient, for shared decision making [II, C^a] (see note ^a in Table 2). The evolution of the tumour lesion during preoperative ChT should be closely monitored to exclude progression, while considering possible patterns of non-dimensional tumour response.

RT should not delay the start of ChT and can be used preoperatively. Evidence has been provided about its tolerability when combined with preoperative ChT with full-dose epirubicin plus ifosfamide [III, B] [24].

In one large randomised phase III study (in patients with G2–3, deep, > 5 cm STSs), regional hyperthermia in addition to systemic ChT was associated with a local progression-free survival (PFS) and DFS advantage [I, B] [16].

In general, adjuvant ChT should never be intended to rescue inadequate surgery. In any case, adjuvant ChT is not used in histological subtypes known to be insensitive to ChT.

The standard approach to local relapses parallels the approach to primary local disease, except for a wider resort to preoperative or postoperative RT and/or ChT, if not previously carried out.

Management of advanced/metastatic disease (see Figures 3 and 4)

The decision making is complex, depending on diverse presentations and histologies, and should always be multidisciplinary. Metachronous (disease-free interval ≥ 1 year), resectable lung metastases without extrapulmonary disease are managed with surgery as standard treatment, if complete excision of all lesions is feasible [IV, B] [25]. A minimally invasive thoracoscopic approach can be used in selected cases. Other appropriate local techniques can be used, although surgery is the standard and data are required on alternative, less invasive options. Decisions must also consider the feasibility of the various options. When surgery of lung metastases is selected, an abdominal CT scan and a bone scan or a fluorodeoxyglucose (FDG)-PET are mandatory to confirm that lung metastases are 'isolated'.

ChT may be added to surgery as an option, taking into account the prognostic factors (a short previous recurrence-free interval and a high number of lesions are adverse factors, encouraging the addition of ChT), although there is a lack of formal evidence that this improves outcome [IV, B]. ChT is preferably given before surgery in order to assess tumour response and thus modulate treatment.

In cases where lung metastases are synchronous, in the absence of extrapulmonary disease, standard treatment is ChT [III, B]. Surgery of completely resectable residual lung metastases may be offered as an option, especially when a tumour response is achieved.

Extrapulmonary metastatic disease is treated with ChT as the standard treatment [I, A].

In highly selected cases, surgery of responding metastases may be offered as an option following a multidisciplinary evaluation, taking into consideration their site and the natural history of the disease in the individual patient.

Surgery, ablations or RT of extrapulmonary metastases may be an option without ChT in highly selected cases (e.g. some patients with myxoid liposarcoma, solitary fibrous tumour).

Standard ChT is based on anthracyclines as the first-line treatment [I, A]. There is no formal demonstration that multi-agent ChT is superior to single-agent ChT with doxorubicin alone in terms of OS. However, a higher response rate can be expected, in particular, in a number of sensitive histological types, according to several, although not all, randomised clinical trials [26, 27]. Therefore, multi-agent ChT with adequate-dose anthracyclines plus ifosfamide may be the treatment of choice, particularly in subtypes sensitive to ifosfamide, when a tumour response is felt to be potentially advantageous and patient performance status is good [I, B].

Recently, a relatively small phase II study tested the combination of doxorubicin with an antibody directed against platelet-derived growth factor receptor alpha (PDGFRA), olaratumab, and showed a statistically significant higher OS in comparison with doxorubicin alone, though with a lower and non-statistically significant benefit in PFS and response rate [28]. Olaratumab is available in some countries, and the results of a subsequent phase III trial (whose accrual is already completed) are awaited so that the drug can be administered more widely in Europe [II, C^b] [see note ^b in Table 2]; ESMO Magnitude of Clinical Benefit Scale (ESMO-MCBS) v1.1 score: 4]. The mechanisms for the added value of the combination of doxorubicin with a PDGFRA inhibitor are not fully understood. The standard arm in the phase II and III studies was doxorubicin alone, so it must be clarified whether the combination is superior to doxorubicin and ifosfamide. A phase III study compared single-agent doxorubicin with the combination of gemcitabine and docetaxel as an upfront treatment in advanced STS patients of all types. The combination failed to show any improvement in PFS and objective response rate (ORR) and is not generally recommended as a first-line therapy for advanced STS patients [I, D] [29].

Angiosarcoma is highly sensitive to taxanes, which can be a treatment option in this histological subtype [III, B] [30]. An alternative is gemcitabine, possibly in combination with docetaxel [V, B] [31].

Doxorubicin plus dacarbazine is an option for multi-agent, first-line ChT of LMS, in which the activity of ifosfamide is far less convincing in available retrospective evidence, or of solitary fibrous tumours [V, B] [32].

Imatinib is standard medical therapy for those rare patients with dermatofibrosarcoma protuberans who are not amenable to non-mutilating surgery or with metastases deserving medical therapy [III, A] [33].

Similarly, imatinib and nilotinib are active in tenosynovial giant cell tumours (also known as pigmented villonodular synovitis and diffuse-type giant cell tumour). This is a rare, non-metastasising, locally-aggressive neoplasm affecting the synovium and tendon sheaths in young adults. In patients with symptomatic progressive disease, imatinib, if available, can be considered, as it can induce tumour stabilisation or shrinkage and alleviate morbidity [IV, C] [34, 35].

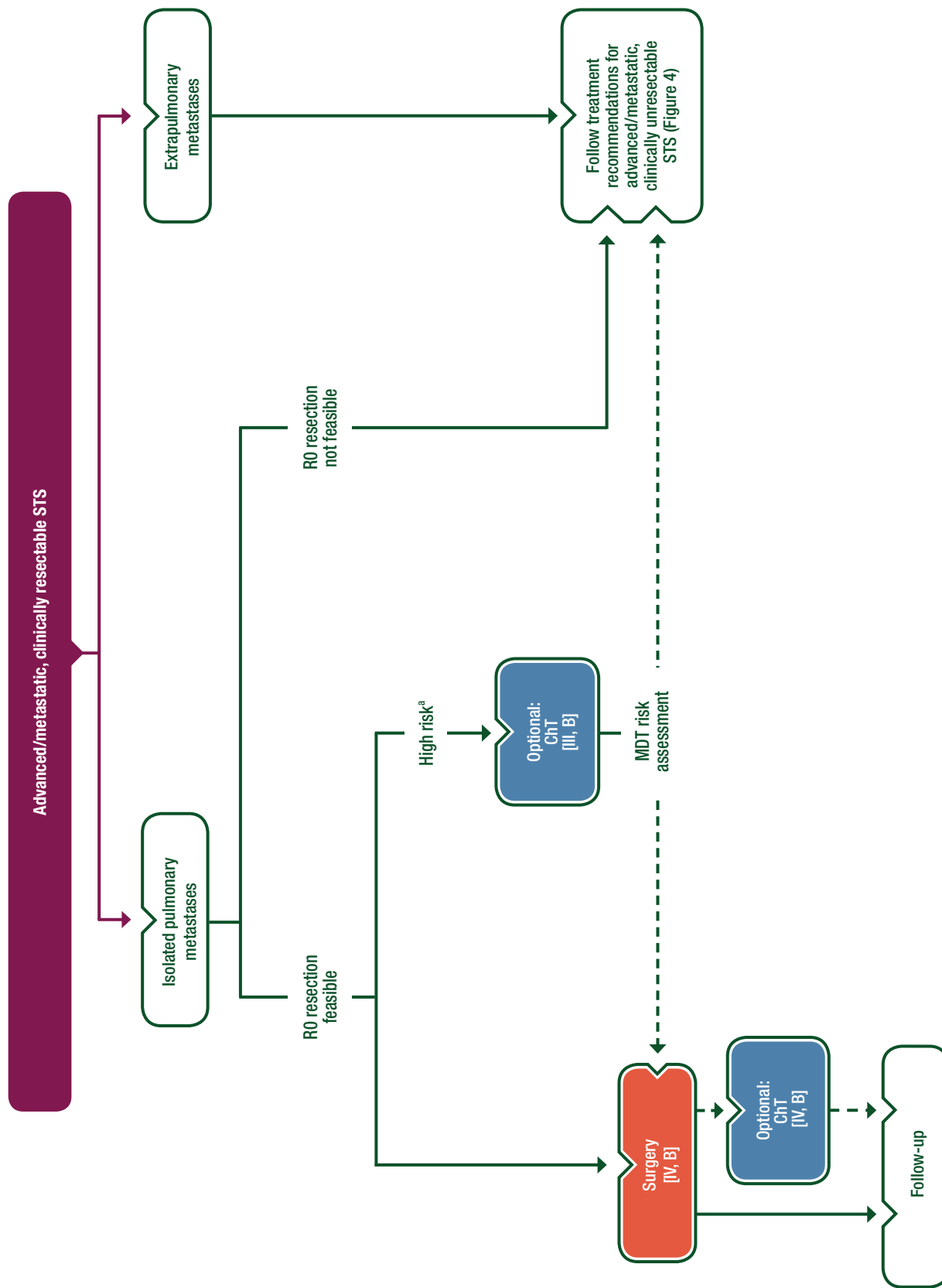


Figure 3. Management of advanced/metastatic, clinically resectable STS.

^aSynchronous and/or multiple and/or bilateral lung metastases.

ChT, chemotherapy; MDT, multidisciplinary team; R0, no tumour at the margin; STS, soft tissue sarcoma.

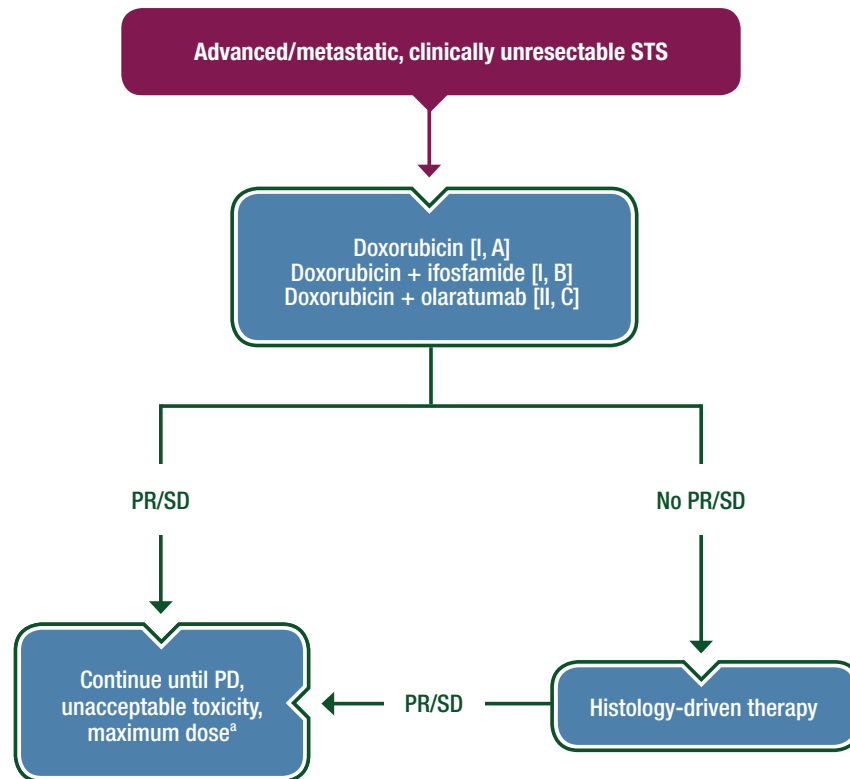


Figure 4. Management of advanced/metastatic, clinically unresectable STS.

^aOlaratumab (if used) to be maintained as single agent after reaching the dose-limiting toxicity of doxorubicin. PD, progressive disease; PR, partial response; SD, stable disease; STS, soft tissue sarcoma.

Active systemic therapies must be considered in progressing, advanced STS patients, even pre-treated, if they are fit for treatment [II, B]. Best supportive care alone is an alternative for unfit patients with advanced STS, especially if further-line therapies have already been used in the patient. In general, advanced previously treated patients are candidates for clinical trials. After failure of anthracycline-based ChT, or the impossibility to use it, the following criteria may apply, although high-level evidence is lacking:

- Patients who have already received ChT may be treated with ifosfamide, if they did not progress on it previously. High-dose ifosfamide ($\sim 14 \text{ g/m}^2$) may be an option also for patients who have already received standard-dose (9 g/m^2) ifosfamide [IV, C] [36, 37].
- Trabectedin is an option for second line and beyond [I, B] and is approved for advanced previously treated STS. It has proved effective in LMS and liposarcoma [38, 39]. In myxoid liposarcoma, a high antitumour activity has been reported, with early radiological tissue density changes. A peculiar pattern of tumour response has been reported, with an early phase of tissue changes preceding tumour shrinkage [40]. Clinical benefit with trabectedin was also demonstrated in other histological types.
- A randomised trial showed a benefit in PFS averaging 3 months for pazopanib given until progression to advanced, previously treated STS patients (excluding liposarcomas) [41]. Thus, it is an option in non-adipogenic STS [I, B].
- A randomised phase III trial showed that eribulin was superior to dacarbazine in patients with liposarcomas and LMS.

The median difference OS was 2 months [I, B], but a subgroup analysis showed that it reached 7 months in liposarcomas [42]. This led to the regulatory approval of eribulin for liposarcomas [II, A; ESMO-MCBS v1.1 score: 4].

- One trial showed that gemcitabine/docetaxel is more effective than gemcitabine alone as second-line ChT, with special reference to LMS and undifferentiated pleomorphic sarcoma, but these data have not been confirmed (equivalence in response rate, PFS and OS) in a second randomised trial conducted in LMS only; in both trials, toxicity was superior with the combination of docetaxel and gemcitabine [II, C] [43]. Gemcitabine was also shown to have antitumour activity in LMS and angiosarcoma as a single agent. The combination of dacarbazine and gemcitabine was shown to improve the OS and PFS over dacarbazine in a randomised trial [II, B] [44].
- Dacarbazine has some activity as a second-line therapy (mostly in LMS and solitary fibrous tumour).
- In a randomised placebo-controlled phase II trial, regorafenib improved PFS for patients with doxorubicin-pretreated, advanced STS. No survival advantage was observed in the liposarcoma cohort. A post hoc exploratory analysis showed improved quality-adjusted survival in comparison with a placebo. Regorafenib should be considered as an option, if available, in doxorubicin-pretreated advanced, non-adipogenic STS patients [II, C] [45, 46].

RT should be used as a palliative resource in all cases as appropriate to the clinical need (e.g. bone lesions at risk of fracture).

With reference to selected histological types, there is anecdotal evidence of activity of several molecular targeted agents, building

Table 2. Summary of recommendations**Diagnosis and pathology/molecular biology**

- Management of STS should be carried out in reference centres for sarcomas
- Pathological diagnosis should be made according to the 2013 WHO classification

Management of local/locoregional disease

- Surgery is the standard treatment of all patients with an adult type, localised STS. It must be carried out by a surgeon specifically trained in the treatment of this disease. The standard surgical procedure is a wide excision with negative margins (absence of residual tumour, R0) [II, A]
- The typical wide excision is followed by RT as the standard treatment of high-grade (G2–3), deep, > 5 cm lesions [II, B]. Exceptions may be made after multidisciplinary discussion considering several variables
- Options for limb-preserving surgery include ChT and/or RT [III, A], or isolated hyperthermic limb perfusion with tumour necrosis factor-alpha + melphalan [III, A], or regional hyperthermia combined with ChT [I, B]
- Adjuvant ChT is not standard treatment in adult-type STS. It can be proposed as an option to the high-risk individual patient [II, C]
- Neoadjuvant ChT with anthracyclines plus ifosfamide for at least 3 cycles is an option in the high-risk individual patient [II, C^a]

Management of advanced/metastatic disease

- Metachronous (disease-free interval \geq 1 year), resectable lung metastases without extrapulmonary disease are managed with surgery as standard treatment, if complete excision of all lesions is feasible [IV, B]
- Standard ChT is based on anthracyclines as the first-line treatment [I, A]. Multi-agent ChT with adequate-dose anthracyclines plus ifosfamide may be the treatment of choice, particularly in subtypes sensitive to ifosfamide, when a tumour response is felt to be potentially advantageous and patient PS is good [I, B]
- The combination of doxorubicin with an anti-PDGFR α agent, olaratumab, is option [II, C^b; ESMO-MCBS v1.1 score: 4]
- Gemcitabine/docetaxel combination is not generally recommended as a first-line therapy for advanced STS patients [I, D]
- Imatinib is standard medical therapy for those rare patients with dermatofibrosarcoma protuberans [III, A]
- Trabectedin is an option for second line and beyond [I, B] and is approved for advanced previously treated STS
- Pazopanib is an option in non-adipogenic STS [I, B]
- Eribulin is an option in patients with liposarcomas and LMS [II, A; ESMO-MCBS v1.1 score: 4]
- The combination of dacarbazine and gemcitabine or gemcitabine/docetaxel is an option in doxorubicin-pretreated patients [II, B]
- Regorafenib is an option in doxorubicin-pretreated advanced, non-adipogenic STS patients [II, C]
- There is anecdotal evidence of activity of several molecular targeted agents:
 - mTOR inhibitors in malignant PEComas [IV, C];
 - Crizotinib in inflammatory myofibroblastic tumours associated with ALK translocations [IV, C];
 - Sunitinib and cediranib in alveolar soft part sarcoma, where the molecular target is as yet unclear [IV, C]; and
 - Sunitinib in solitary fibrous tumours [IV, C]

Special presentation and entities

- *Retroperitoneal sarcomas*. Patients with suspected RPS need to be referred to high-volume sarcoma centres
- *Uterine sarcomas*. Standard local treatment of uterine LMSs, ESSs and UESs (when localised) is *en bloc* total hysterectomy. Adjuvant RT is not recommended [I, D]
- *Desmoid-type fibromatosis*. For progressing cases, the optimal strategy needs to be individualised on a multidisciplinary basis and may consist of watchful waiting, surgery [IV, C], isolated limb perfusion (if the lesion is confined to an extremity) [IV, C] or systemic therapies, percutaneous cryoablation [IV, C]
- *Breast sarcomas*. These patients should be referred to sarcoma units

^aThe experts noted that no GoR described the accurate situation in term of scientific evidence. GoR B is 'Strong or moderate evidence for efficacy but with a limited clinical benefit, generally recommended', and GoR C is 'Insufficient evidence for efficacy or benefit does not outweigh the risk or the disadvantages (adverse events, costs, etc), optional'. In the present question, the experts observed that 'Moderate evidence for efficacy but with a major clinical benefit' would have been a better description of the scientific evidence at this stage.

^bThe experts noted that no GoR described the accurate situation in terms of scientific evidence. Indeed, GoR B is 'Strong or moderate evidence for efficacy but with a limited clinical benefit, generally recommended', while GoR C is 'Insufficient evidence for efficacy or benefit does not outweigh the risk or the disadvantages (adverse events, costs, . . .), optional'. In the present question, the experts observed that 'Moderate evidence for efficacy but with a major clinical benefit' would have been a better description of the scientific evidence at this stage, while waiting for the results of the completed phase III trial.

ALK, anaplastic lymphoma kinase; ChT, chemotherapy; ESMO, European Society for Medical Oncology; ESS, endometrial stromal sarcoma; GoR, grade of recommendation; LMS, leiomyosarcoma; MCBS, Magnitude of Clinical Benefit Scale; mTOR, mammalian target of rapamycin; PDGFRA, platelet-derived growth factor receptor alpha; PEComa, perivascular epithelioid cell tumour; PS, performance status; R0, no tumour at the margin; RPS, retroperitoneal sarcoma; RT, radiotherapy; STS, soft tissue sarcoma; UES, undifferentiated endometrial sarcoma; WHO, World Health Organization.

Table 3. ESMO-MCBS table for olaratumab and eribulin in soft tissue and visceral sarcomas^a

Therapy	Disease setting	Trial	Control	Absolute survival gain	HR gain (95% CI)	QoL/Toxicity	MCBS score
Olaratumab with doxorubicin	Unresectable or metastatic soft tissue sarcoma with a histologically confirmed diagnosis, PS of 0–2 and not previously treated with an anthracycline	Olaratumab and doxorubicin versus doxorubicin alone for treatment of soft-tissue sarcoma: an open-label phase Ib and randomised phase II trial Phase Ib/II NCT01185964 [28]	Doxorubicin Median OS: 14.7 months	OS gain: 11.8 months	OS: HR 0.46 (0.30–0.71)	QoL not available AEs similar (or slightly worse for leukopaenia and neutropaenia)	4 (Form 2a ^b ; secondary end point of OS in a small phase II randomised study)
Eribulin, a microtubule dynamics inhibitor	Intermediate-grade or high-grade advanced liposarcoma who had received at least two previous systemic regimens for advanced disease	Eribulin versus dacarbazine in previously treated patients with advanced liposarcoma or leiomyosarcoma: a randomised, open-label, multicentre, phase III trial. NCT01327885 [42]	Dacarbazine	OS gain: 7.2 months	OS: HR 0.51 (0.35–0.75)	Similar	4 (Form 2a) ^b

^aEMA approvals since January 2016 to end March 2018.

^bESMO-MCBS version 1.1 [83].

AE, adverse event; CI, confidence interval; EMA, European Medicines Agency; ESMO, European Society for Medical Oncology; HR, hazard ratio; MCBS, Magnitude of Clinical Benefit Scale; OS, overall survival; PS, performance status; QoL, quality of life.

Table 4. Levels of evidence and grades of recommendation (adapted from the Infectious Diseases Society of America–United States Public Health Service Grading System^a)

Levels of evidence	
I	Evidence from at least one large randomised, controlled trial of good methodological quality (low potential for bias) or meta-analyses of well-conducted randomised trials without heterogeneity
II	Small randomised trials or large randomised trials with a suspicion of bias (lower methodological quality) or meta-analyses of such trials or of trials with demonstrated heterogeneity
III	Prospective cohort studies
IV	Retrospective cohort studies or case–control studies
V	Studies without control group, case reports, experts opinions
Grades of recommendation	
A	Strong evidence for efficacy with a substantial clinical benefit, strongly recommended
B	Strong or moderate evidence for efficacy but with a limited clinical benefit, generally recommended
C	Insufficient evidence for efficacy or benefit does not outweigh the risk or the disadvantages (adverse events, costs, etc), optional
D	Moderate evidence against efficacy or for adverse outcome, generally not recommended
E	Strong evidence against efficacy or for adverse outcome, never recommended

^aBy permission of the Infectious Diseases Society of America [84].

on consistent preclinical data and small retrospective cohort studies. Examples are:

- Mammalian target of rapamycin (mTOR) inhibitors in malignant perivascular epithelioid cell tumours (PEComas), which are often associated with the loss of tuberous sclerosis complex 1/2 (TSC1/TSC2) [IV, C] [47, 48];
- Sirolimus activity in epithelioid haemangiopericytoma [IV, C] [49];
- Crizotinib in inflammatory myofibroblastic tumour associated with anaplastic lymphoma kinase (ALK) translocations [IV, C] [50];
- Sunitinib and cediranib in alveolar soft part sarcoma, where the molecular target is as yet unclear [IV, C] [51, 52]; and
- Sunitinib in solitary fibrous tumours, where the molecular target is as yet unclear [IV, C] [53].

Follow-up

There are few published data to indicate the optimal routine follow-up policy of surgically treated patients with localised disease [54].

The malignancy grade affects the likelihood and speed at which relapses may occur. The risk assessment, based on tumour grade, tumour size and tumour site, therefore helps in choosing a routine follow-up policy. High-risk patients generally relapse within 2–3 years, whereas low-risk patients may relapse later, although it is less likely. Relapses most often occur to the lungs. Early detection of local or metastatic recurrence to the lungs may have prognostic implications, and lung metastases are asymptomatic at a stage in which they are suitable for surgery. Therefore, routine follow-up may focus on these sites. Although the use of MRI to detect local relapse and CT to scan for lung metastases is likely to pick up recurrences earlier, it has not been demonstrated that this is beneficial, or cost effective, compared with the clinical assessment of the primary site and regular chest X-rays.

While prospective studies are needed, a practical approach in place at several institutions is as follows: surgically-treated intermediate-/high-grade patients may be followed every 3–4 months in the first 2–3 years, then twice a year up to the fifth year, and once a year thereafter; low-grade sarcoma patients may be followed for local relapse every 4–6 months, with chest X-rays or CT scan at longer intervals in the first 3–5 years, then annually.

Special presentation and entities

Retroperitoneal sarcomas

Patients with suspected RPS need to be referred to high-volume sarcoma centres [55].

Chest, abdomen and pelvis intravenous (i. v.) contrast-enhanced CT are standard for staging; i.v. contrast-enhanced MRI is an option, especially for pelvic tumours, to assess specific aspects of tumour extent. Functional assessment of the contralateral kidney is necessary. Pre-treatment biopsy for pathological diagnosis should be carried out, to allow tailored present and future therapeutic decisions, unless otherwise indicated by a sarcoma tumour

board. A multiple core biopsy with an adequate coaxial needle of sufficient size (14–16 G) is the standard procedure. Risk of needle track seeding is minimal and should not be a reason to avoid a biopsy. Nonetheless, the pathway of the biopsy should be carefully planned to minimise contamination and complications, and should not be carried out transperitoneally. Open or laparoscopic biopsies must be avoided.

Comprehensive imaging evaluation is critical to accurately assess extent of tumour. Certain areas (e.g. inguinal canal, retrohepatic vena cava, diaphragm, neural foramina) are particularly challenging to evaluate and may require additional specialised radiological input. Specific appreciation of the well-differentiated versus the dedifferentiated component(s) of liposarcoma is critical to surgical decision making. Histology-specific nomograms for RPS patients are available that can help personalise risk assessment and clinical decision making [9].

The best chance of cure is at primary presentation. An individualised management plan should be made, following a multidisciplinary sarcoma case discussion based on both imaging and pathological findings. The standard treatment of primary lesions is surgery, to be carried out by a surgeon with specific sarcoma expertise. Surgery should be aimed at achieving a one-specimen *en bloc*, macroscopically complete resection, minimising microscopically positive margins. This is best done by resecting the tumour *en bloc* with adherent structures, even if not overtly infiltrated [III, A] [56, 57]. Preservation of specific organs (i.e. kidney, head of the pancreas and/or liver) should be considered on an individualised basis and mandates a specific expertise in the disease to make the right decisions. Judgement must be used in deciding which neurovascular structures to sacrifice, weighing the potential for local control against expected long-term dysfunctions.

Grossly incomplete resection of RPSs is of questionable benefit and potentially harmful, and can only be regarded as potentially palliative in carefully selected patients. Grossly incomplete resection is to be avoided by imaging review, thoughtful planning and referral to appropriate centres.

Although no randomised trials of neoadjuvant therapy versus resection alone for RPS have been reported to date, neoadjuvant treatment, in the form of ChT, external beam radiotherapy (EBRT), regional hyperthermia or combinations, is safe in well-selected patients and may be considered after careful review by a multidisciplinary sarcoma tumour board [IV, C]. This is particularly relevant in the case of technically unresectable/borderline resectable RPS that could be surgically converted by downsizing, and in chemosensitive histologies such as synovial sarcoma. The sensitivity of solitary fibrous tumour to RT should also be considered. In one large randomised phase III study (in patients with G2–3, deep, > 5 cm STSs), regional hyperthermia in addition to systemic ChT was associated with a local PFS and DFS advantage [I, B] [58].

Preoperative RT in resectable tumours has been investigated in a randomised clinical trial, which has completed its accrual. In principle, preoperative treatments are not intended to change the extent of surgery, but to improve the quality of surgical margins.

Postoperative/adjuvant EBRT following complete gross resection is of limited value, and is associated with significant short- and long-term toxicities. A therapeutic radiation treatment dose can be achieved in a minority of patients following resection. In selected cases, it may be an option in well-defined anatomical areas considered to be at high risk. Brachytherapy is of unproven

value and is associated with significant short- and long-term complications. Intraoperative RT is of unproven value.

The value of adjuvant ChT is not established, though the rarity of the subtypes of RPSs forces extrapolation of data available in other settings.

Surgery of local recurrences could be offered on an individualised basis, especially to patients affected by well-differentiated liposarcoma and having a long disease-free interval between initial resection and subsequent recurrence, and possibly to patients experiencing a response to medical therapies [59–61].

Uterine sarcomas

The group of uterine sarcomas includes LMSs, endometrial stromal sarcomas (ESSs, formerly low-grade ESSs) and undifferentiated endometrial sarcomas (UESs). Carcinosarcomas (malignant Müllerian mixed tumours) are currently viewed as epithelial cancers, and treatment should be tailored accordingly. Thus, before a final diagnosis of sarcoma is made, the pathologist should be certain that an epithelial component is absent, through proper immunohistochemical analysis.

We do not yet have clinical and radiological criteria to differentiate leiomyomas from malignant uterine tumours. Thus, procedures resulting in potential tumour cell spillage, such as morcellation out of endobags, are discouraged because they entail a high risk of worsening patient prognosis when malignancy is the postoperative pathological diagnosis [62, 63].

Smooth tumours of undefined malignant potential (STUMPs) constitute a negative definition, which is used when both leiomyoma and LMS cannot be diagnosed with certainty [64]. There are remarkable variations with this diagnosis among pathologists that implies a degree of subjectivity. Some of these lesions might actually represent ‘low-grade’ LMSs, whose existence is disputed. Due to the uncertainty about their prognosis, hysterectomy is usually proposed to patients with a diagnosed STUMP, but there may be room for individualised decision making with an informed patient. Careful follow-up is then recommended.

Standard local treatment of uterine LMSs, ESSs and UESs (when localised) is *en bloc* total hysterectomy (including laparoscopy/assisted or robotic surgery, provided the tumour is resected with the same criteria as for open surgery). With a diagnosis of sarcoma, fertility-preserving surgery in young women is not supported by any evidence and should not be regarded as standard, though of course it may be the choice made by an informed patient. The added value of bilateral salpingo-oophorectomy is not established, particularly in pre-menopausal women, and systematic lymphadenectomy has not been demonstrated to be useful. In ESS, however, lymph nodes may be positive in roughly 10% of cases. Although in uterine LMS retrospective studies suggested a possible decrease in local relapses, RT has not improved RFS and OS in a prospective randomised trial, and therefore is not recommended [I, D] [65]. The use of RT as an adjuvant to surgery can be an option in selected cases, after shared decision making with the patient, following multidisciplinary discussion considering special risk factors, including: local relapse, cervical involvement, parametral involvement, serosal involvement and UES histology [IV, C]. Adjuvant ChT in uterine LMS is not standard, since its value is undetermined [IV, C]. Uncontrolled studies suggested a benefit in comparison with external controls for four courses of gemcitabine/

docetaxel followed by four courses of doxorubicin, as well as four courses of gemcitabine/docetaxel [66, 67]. A prospective randomised trial with a no-treatment control arm versus four courses of gemcitabine/docetaxel followed by four courses of doxorubicin was attempted but closed early due to lack of accrual (IRCI 001, NCT01533207). The value of adjuvant ChT for somatic LMSs is not established, and the details in the ‘Management of local/locoregional disease’ section might be applicable to uterine LMSs as well, though with the added uncertainty about whether these are actually superimposable to LMSs of other sites.

The medical treatment of advanced LMSs, UESs and adenocarcinoma with sarcomatous overgrowth parallels that for adult-type STSs. It should be kept distinct from malignant Müllerian mixed tumours, which are currently treated with therapies for epithelial tumours. As for all LMSs, doxorubicin, dacarbazine, trabectedin and pazopanib are active agents and may be used in a stepwise fashion. There is retrospective evidence that ifosfamide may be less active as a single agent in LMSs.

ESSs are low-grade tumours, with a consistent pathological appearance. The diagnosis is supported by typical cytogenetics, marked by a chromosomal $t(7;17)$ with *JAZF1-SUZ12* or related translocations joining *EPC1-PHF1* or *JAZF1-PHF1* genes. Adjuvant hormonal therapy is not standard, though it may be an option, given retrospective evidence suggesting its role in decreasing relapses. However, the sensitivity of the advanced disease to hormones makes the benefit questionable overall [IV, C]. The systemic treatment of metastatic low-grade ESS exploits their sensitivity to hormonal therapies [V, B]. Therefore, progestins, aromatase inhibitors and gonadotropin-releasing hormone (GnRH) analogues (for premenopausal patients) can be used [68]. Tamoxifen is contraindicated due to a possible agonist activity, as is hormonal replacement therapy (HRT) containing oestrogens. ChT may be an option when hormonal therapy has failed. Surgery of lung metastases is an option, even in presentations which might not be surgically approached in other STSs, given the long natural history of the disease. This may apply to pelvic disease as well, even in the presence of metastatic disease.

Currently, a subgroup of high-grade ESS is recognised, which is defined by specific cytogenetics, marked by $t(10;17)$, carrying the *YWHAE-FAM22* transcript [69]. Their behaviour is more aggressive. Currently, they are considered to be insensitive to hormonal therapies, and cytotoxic ChT is considered appropriate in the metastatic setting, with notable responses reported with anthracycline-based regimens [IV, B] [70].

High-grade ESS, adenocarcinoma with sarcomatous overgrowth and UES are high-grade malignancies. There are no data on the value of adjuvant ChT, though their high-risk status may justify a shared decision with the patient in conditions of uncertainty, especially in UES [V, C]. Hyperthermic peritoneal ChT has not been shown to be effective and is an experimental-only option.

For benign metastasising leiomyomas, clinical observation is the treatment of choice at diagnosis, with hormonal therapy (as for ESS) being standard treatment for progressing disease and surgery. The same applies to peritoneal leiomyomatosis, if non-mutilating surgery is not feasible.

For pelvic aggressive angiomyxoma, surgery is the treatment of choice if not mutilating, with observation thereafter. In progressing disease, hormonal therapy, or interruption of any ongoing

stimulation with oestrogens, may allow mutilating surgery to be avoided and the disease to be kept under control [71].

Desmoid-type fibromatosis

While principles for the diagnosis of STS apply also to desmoids, beta-catenin mutational analysis may be useful when the pathological differential diagnosis is difficult.

Given the unpredictable natural history of the disease (with the possibility of long-lasting stable disease and even occasional spontaneous regressions, along with a lack of metastatic potential) and functional problems implied by some tumour anatomical locations, an initial watchful waiting policy can be proposed [III, B] [72, 73]. This should follow a shared decision making with the patient, with careful monitoring of potentially life-threatening extra-abdominal locations (e.g. head and neck region) and intra-abdominal desmoids (mesenteric fibromatosis). Under such a policy, treatment is reserved for progressing cases. The preferred imaging modality is MRI, taking into consideration that the tumour signal is not meaningful with regard to the disease evolution.

For progressing cases, the optimal strategy needs to be individualised on a multidisciplinary basis and may consist of watchful waiting, surgery without any adjuvant therapy [IV, C], isolated limb perfusion (if the lesion is confined to an extremity) [IV, C] or systemic therapies [73, 74]. Percutaneous cryoablation can be an option for recurrent extra-abdominal cases [IV, C] [75]. Definitive RT should be considered after multiple failed lines of treatment or for tumours in critical anatomical locations where surgery would involve prohibitive risk or functional impairment [III, C] [75]. When a systemic therapy is chosen, available options include: hormonal therapies (tamoxifen, toremifene and GnRH analogues), non-steroidal anti-inflammatory drugs; low-dose ChT (such as methotrexate/vinblastine or methotrexate/vinorelbine); sorafenib/pazopanib; imatinib; interferon; full-dose ChT (using regimens active in sarcomas, including liposomal doxorubicin) [76–82]. It is reasonable to employ the less toxic therapies before the more toxic ones in a stepwise fashion. A comprehensive clinical judgement of progression should be used. Hormonal contraception should be discussed with the patient and definitely stopped in the case of progressing disease.

Breast sarcomas

These patients should be referred to sarcoma units.

Breast sarcomas encompass radiation- and non-radiation-induced sarcomas. Therefore, sarcomas of the skin of the breast area should be conceptually distinguished from mammary gland sarcomas. Angiosarcoma has a more aggressive behaviour than other histological types, while malignant phyllodes tumours [i.e. those having > 10 mitoses/10 high-power field (HPF) and marked stromal overgrowth] have a 20%–30% metastatic rate. On the other hand, metaplastic breast carcinomas, also known as carcinosarcomas, are epithelial neoplasms, whose treatment should be tailored to their mainly epithelial nature.

The best treatment of breast sarcomas is far from being defined, given their rarity and heterogeneity. In general, breast-conserving surgery may be carried out, depending on the quality of margins versus the size of the tumour and the breast, along with the feasibility of RT. In addition, angiosarcomas of the mammary gland

have such a tendency to recur that mastectomy (involving the muscular fascia) is recommended in most cases, even in combination with postoperative RT. Lymphadenectomy is not carried out in the absence of clinical evidence of involvement.

As far as adjuvant and neoadjuvant ChT is concerned, the same principles of STS apply. Considering the high risk of angiosarcoma to develop local and systemic relapses, preoperative treatments including ChT and RT may be used. Re-irradiation should be considered in radiation-induced angiosarcomas.

Methodology

These Clinical Practice Guidelines have been produced by ESMO in partnership with EURACAN, the European Reference Network for rare adult solid cancers. These Clinical Practice Guidelines were developed in accordance with the ESMO standard operating procedures for Clinical Practice Guidelines development (<http://www.esmo.org/Guidelines/ESMO-Guidelines-Methodology>). They are conceived to provide the standard approach to diagnosis, treatment and survivorship on sarcomas and GISTs. Recommended interventions are intended to correspond to the ‘standard’ approaches, according to current consensus among the European multidisciplinary sarcoma community of experts. These are represented by the members of the ESMO Sarcoma Faculty and experts appointed by all institutions belonging to the Sarcoma domain of EURACAN. Experimental interventions considered to be beneficial are labelled as ‘investigational’. Other non-standard approaches may be proposed to the single patient as ‘options’ for a shared patient–physician decision in conditions of uncertainty, as long as some supporting evidence (though not conclusive) is available. Algorithms accompany the text, covering the main typical presentations of disease, and are meant to guide the user throughout the text. The relevant literature has been selected by the expert authors. A summary of recommendations is shown in Table 2. An MCBS table with ESMO MCBS scores is included in Table 3. ESMO-MCBS v1.1 [83] was used to calculate scores for new therapies/indications approved by the EMA since 1 January 2016. Levels of evidence and grades of recommendation have been applied using the system shown in Table 4. Statements without grading were considered justified standard clinical practice by the experts.

Disclosure

PGC has reported advisory roles for Deciphera Pharmaceuticals, Eisai, Eli Lilly, Nektar Therapeutics, speaker’s honoraria from Eisai, Eli Lilly, Pfizer, PharmaMar, and conducted studies sponsored by Amgen Dompé, AROG Bayer, Blueprint Medicines, Eli Lilly, Daiichi Sankyo Pharma, Epizyme, GlaxoSmithKline, Novartis, Pfizer, PharmaMar; SBa has reported research support from Novartis, Incyte, Blueprint Medicines, has received honoraria or consultation fees from Novartis, Lilly, Pfizer, PharmaMar and Bayer; SBi has reported advisory/consultant roles for Lilly, Bayer, Pfizer, Novartis, Isolfol and Clinigen and conducted studies sponsored by Janssen-Cilag, Eisai and Loxo Oncology; SBo has reported honoraria and travel grants from Nanobiotix and

Lilly and received travel grants from PharmaMar; IB has received research funds from Bristol-Myers Squibb, Merck Sharp & Dohme, Novartis, Roche, Amgen and has reported advisory roles for AstraZeneca, Roche, Merck Sharp & Dohme, LEO Pharma, Amgen, Bristol-Myers Squibb, Pfizer and Novartis; TB has reported honoraria from Roche and PharmaMar and advisory board and honoraria from Amgen, Bayer, Novartis, Eisai and Eli Lilly; JMB has reported consulting advisory role for PharmaMar, Lilly, Bayer, Novartis and being a member of the speaker's bureau for PharmaMar and received travel grants from PharmaMar and Lilly; APDT is a member of the speakers' bureau for Lilly, Pfizer and Merck Sharp & Dohme; XGDM has reported advisory role for Lilly, PharmaMar and Novartis; PD has reported conducted research sponsored by Eli Lilly; ME has participated in advisory boards for Bayer, Sobi, Lilly, Eisai and Novartis; AMF has conducted studies sponsored by Amgen Dompé, AROG Bayer, Blueprint Medicines, Eli Lilly, Daiichi Sankyo Pharma, Epizyme, GlaxoSmithKline, Novartis, Pfizer, PharmaMar; SG has received research grants and honoraria from Novartis, Pfizer and Bayer; HG has received research grants from Novartis, Daiichi Sankyo Pharma and Pfizer; AG has reported compensation for advisory boards from Novartis, Pfizer, Bayer, Lilly, PharmaMar and Nanobiotix, honoraria from Novartis, Lilly, PharmaMar and Nanobiotix, and research funds from PharmaMar and travel grants from PharmaMar and Nanobiotix; BH has received research grants from EuroSarc and has conducted research with EIT Health in collaboration with GE healthcare and Philips, he has received reagents from Takeda and Astellas to conduct clinical trials without direct funding; PH has reported conducting research sponsored by Novartis, Blueprint Medicines, Nanobiotix and Lilly and has received honoraria and travel grants from PharmaMar, Eisai and Lilly; HJ has reported co-appointment with Orion Pharma and holds stock in Sartar Therapeutics, Faron Pharmaceuticals and Orion Pharma; RLJ is a consultant for Adaptimmune, Blueprint Medicines, Clinigen, Eisai, Epizyme, Daichii, Deciphera, Immunodesign, Lilly, Merck and PharmaMar; IJ has received honoraria from Lilly for lectures; PJ has reported being a consultant for Stryker for the design of a new tumour prosthesis; BK has reported honoraria from Novartis, Pfizer and Bayer and advisory role for Bayer; KK has received travel grants from Novartis and Pfizer; ALC has received honoraria from Pfizer, Novartis, Lilly, Amgen, Bayer and PharmaMar; Pfizer and Bayer; IL has received honoraria from Bristol-Myers Squibb, MDS, Roche, Novartis and Pfizer for scientific presentations or research; MAP has served on advisory boards for Bayer and Pfizer, and has received research grants from Novartis; PR has served on advisory boards for Novartis, Pfizer, PharmaMar, Ariad, Merck, Deciphera, Roche, Clinigen and Lilly and has received honoraria from Novartis, Pfizer, Bayer, PharmaMar and Lilly; PRu has received honoraria for lectures from Novartis, Pfizer, Bristol-Myers Squibb, Merck Sharp & Dohme, Roche and has served as a member of advisory board for Novartis, Amgen, Merck Sharp & Dohme, Bristol-Myers Squibb, Blueprint Medicines; PS has received honoraria from Daiichi Sankyo Pharma, Eisai, Eli Lilly, Medspace, Novartis and Swedish Orphan Biovitrium, has reported consulting or advising roles for Sixth Element Capital, Adaptimmune, Amcure, AstraZeneca, Bayer, Blueprint Medicines, Bristol-Myers Squibb, Boehringer Ingelheim, Cristal Therapeutics, Daiichi Sankyo Pharma, Eisai,

Eli Lilly, Epizyme, Genzyme, Ipsen, Loxo Oncology, Medspace, Nektar, Novartis, Philogen, Piquar Therapeutics, Plexxikon, is a member of speaker's bureau of Bayer, Eisai, Eli Lilly, GlaxoSmithKline, Novartis, PharmaMar, Swedish Orphan Biovitrium, has received research grants from Bayer, Blueprint Medicines, CoBioRes, Exelixis, Bristol-Myers Squibb, Novartis, Plexxikon, and has received travel grants from Sixth Element Capital, Adaptimmune, Amcure, AstraZeneca, Bayer, Blueprint Medicines, Bristol-Myers Squibb, Boehringer Ingelheim, Cristal Therapeutics, Daichii Sankyo Pharma, Eisai, Eli Lilly, Epizyme, Genzyme, GlaxoSmithKline, Ipsen, Loxo Oncology, Medpace, Nektar, Novartis, PharmaMar, Philogen, Piquar Therapeutics, Plexxikon, Swedish Orphan Biovitrium; SS has received honoraria from Eli Lilly and PharmaMar, research grants from Amgen Dompé, Advenchen, Bayer, Eli Lilly, Daiichi Sankyo Pharma, Epizyme Inc., Novartis, Pfizer and PharmaMar; travel grants from PharmaMar and has reported advisory/consultant roles for Bayer, Eli Lilly, ImmuneDesign, Maxivax and PharmaMar; WVG has received research grants from Novartis; EW has reported travel/research grants and/or honoraria from Novartis Oncology, Milestone, Menarini, PharmaMar, Roche, Nanobiotix and Bayer; JYB has declared research grants and honoraria from Novartis, GlaxoSmithKline, Pfizer and Bayer; IL has received honoraria from Bristol-Myers Squibb, MDS, Roche, Novartis and Pfizer for scientific presentations or research; NA, RB, JVMGB, AB, EDA, AFed, VF, AFer, GG, TG, RLH, RI, SK, DAK, RP, PP, SP-N, ALP, OM, MM, MHR, AAS, SSL, KSH, MU, JW and FVC have declared no conflict of interest. SF, AH and OZ have not reported any potential conflicts of interest.

References

- Casali PG, Abecassis N, Bauer S et al. Gastrointestinal stromal tumours: ESMO–EURACAN Clinical Practice Guidelines for diagnosis, treatment and follow-up. *Ann Oncol* 2018; 29(Suppl 4): iv68–iv78.
- Casali PG, Bielack S, Abecassis N et al. Bone sarcomas: ESMO–PaedCan–EURACAN Clinical Practice Guidelines for diagnosis, treatment and follow-up. *Ann Oncol* 2018; 29(Suppl 4): iv79–iv95.
- Stiller CA, Trama A, Serraino D et al. Descriptive epidemiology of sarcomas in Europe: report from the RARECARE project. *Eur J Cancer* 2013; 49: 684–695.
- Fletcher CDM, Bridge JA, Hogendoorn PC, Mertens F (eds). WHO Classification of Tumours of Soft Tissue and Bone. Lyon: IARC 2013.
- Ray-Coquard I, Montesco MC, Coindre JM et al. Sarcoma: concordance between initial diagnosis and centralized expert review in a population-based study within three European regions. *Ann Oncol* 2012; 23: 2442–2449.
- Trojani M, Contesso G, Coindre JM et al. Soft-tissue sarcomas of adults; study of pathological prognostic variables and definition of a histopathological grading system. *Int J Cancer* 1984; 33: 37–42.
- Brierley JD, Gospodarowicz MK, Wittekind C (eds). TNM Classification of Malignant Tumours, 8th edn. Oxford: John Wiley & Sons, Inc. 2016.
- Callegaro D, Miceli R, Bonvalot S et al. Development and external validation of two nomograms to predict overall survival and occurrence of distant metastases in adults after surgical resection of localised soft-tissue sarcomas of the extremities: a retrospective analysis. *Lancet Oncol* 2016; 17: 671–680.
- Gronchi A, Miceli R, Shurell E et al. Outcome prediction in primary resected retroperitoneal soft tissue sarcoma: histology-specific overall survival and disease-free survival nomograms built on major sarcoma center data sets. *J Clin Oncol* 2013; 31: 1649–1655.
- Rosenberg SA, Tepper J, Glatstein E et al. The treatment of soft-tissue sarcomas of the extremities: prospective randomized evaluations of (1)

- limb-sparing surgery plus radiation therapy compared with amputation and (2) the role of adjuvant chemotherapy. *Ann Surg* 1982; 196: 305–315.
11. Pisters PW, Harrison LB, Leung DH et al. Long-term results of a prospective randomized trial of adjuvant brachytherapy in soft tissue sarcoma. *J Clin Oncol* 1996; 14: 859–868.
 12. Yang JC, Chang AE, Baker AR et al. Randomized prospective study of the benefit of adjuvant radiation therapy in the treatment of soft tissue sarcomas of the extremity. *J Clin Oncol* 1998; 16: 197–203.
 13. Beane JD, Yang JC, White D et al. Efficacy of adjuvant radiation therapy in the treatment of soft tissue sarcoma of the extremity: 20-year follow-up of a randomized prospective trial. *Ann Surg Oncol* 2014; 21: 2484–2489.
 14. Cahlon O, Brennan MF, Jia X et al. A postoperative nomogram for local recurrence risk in extremity soft tissue sarcomas after limb-sparing surgery without adjuvant radiation. *Ann Surg* 2012; 255: 343–347.
 15. O'Sullivan B, Davis AM, Turcotte R et al. Preoperative versus postoperative radiotherapy in soft-tissue sarcoma of the limbs: a randomised trial. *Lancet* 2002; 359: 2235–2241.
 16. Issels RD, Lindner LH, Verweij J et al. Neo-adjuvant chemotherapy alone or with regional hyperthermia for localised high-risk soft-tissue sarcoma: a randomised phase 3 multicentre study. *Lancet Oncol* 2010; 11: 561–570.
 17. Deroose JP, Eggermont AM, van Geel AN et al. Long-term results of tumor necrosis factor alpha- and melphalan-based isolated limb perfusion in locally advanced extremity soft tissue sarcomas. *J Clin Oncol* 2011; 29: 4036–4044.
 18. Frustaci S, Gherlinzoni F, De Paoli A et al. Adjuvant chemotherapy for adult soft tissue sarcomas of the extremities and girdles: results of the Italian randomized cooperative trial. *J Clin Oncol* 2001; 19: 1238–1247.
 19. Woll PJ, Reichardt P, Le Cesne A et al. Adjuvant chemotherapy with doxorubicin, ifosfamide, and lenograstim for resected soft-tissue sarcoma (EORTC 62931): a multicentre randomised controlled trial. *Lancet Oncol* 2012; 13: 1045–1054.
 20. Pervaiz N, Colterjohn N, Farrokhyar F et al. A systematic meta-analysis of randomized controlled trials of adjuvant chemotherapy for localized resectable soft-tissue sarcoma. *Cancer* 2008; 113: 573–581.
 21. Adjuvant chemotherapy for localised resectable soft-tissue sarcoma of adults: meta-analysis of individual data. *Sarcoma Meta-analysis Collaboration*. *Lancet* 1997; 350: 1647–1654.
 22. Gronchi A, Frustaci S, Mercuri M et al. Short, full-dose adjuvant chemotherapy in high-risk adult soft tissue sarcomas: a randomized clinical trial from the Italian Sarcoma Group and the Spanish Sarcoma Group. *J Clin Oncol* 2012; 30: 850–856.
 23. Gronchi A, Ferrari S, Quagliuolo V et al. Histotype-tailored neoadjuvant chemotherapy versus standard chemotherapy in patients with high-risk soft-tissue sarcomas (ISG-STSS 1001): an international, open-label, randomised, controlled, phase 3, multicentre trial. *Lancet Oncol* 2017; 18: 812–822.
 24. Palassini E, Ferrari S, Verderio P et al. Feasibility of preoperative chemotherapy with or without radiation therapy in localized soft tissue sarcomas of limbs and superficial trunk in the Italian Sarcoma Group/Grupo Español de Investigación en Sarcomas randomized clinical trial: three versus five cycles of full-dose epirubicin plus ifosfamide. *J Clin Oncol* 2015; 33: 3628–3634.
 25. Blackmon SH, Shah N, Roth JA et al. Resection of pulmonary and extrapulmonary sarcomatous metastases is associated with long-term survival. *Ann Thorac Surg* 2009; 88: 877–884; discussion 884–885.
 26. Antman K, Crowley J, Balcerzak SP et al. An intergroup phase III randomized study of doxorubicin and dacarbazine with or without ifosfamide and mesna in advanced soft tissue and bone sarcomas. *J Clin Oncol* 1993; 11: 1276–1285.
 27. Judson I, Verweij J, Gelderblom H et al. Doxorubicin alone versus intensified doxorubicin plus ifosfamide for first-line treatment of advanced or metastatic soft-tissue sarcoma: a randomised controlled phase 3 trial. *Lancet Oncol* 2014; 15: 415–423.
 28. Tap WD, Jones RL, Van Tine BA et al. Olaratumab and doxorubicin versus doxorubicin alone for treatment of soft-tissue sarcoma: an open-label phase 1b and randomised phase 2 trial. *Lancet* 2016; 388: 488–497.
 29. Seddon BM, Whelan J, Strauss SJ et al. GeDDiS: a prospective randomised controlled phase III trial of gemcitabine and docetaxel compared with doxorubicin as first-line treatment in previously untreated advanced unresectable or metastatic soft tissue sarcomas (EudraCT 2009-014907-29). *J Clin Oncol* 2015; 33(Suppl 15); Abstr 10500.
 30. Penel N, Bui BN, Bay JO et al. Phase II trial of weekly paclitaxel for unresectable angiosarcoma: the ANGIOTAX Study. *J Clin Oncol* 2008; 26: 5269–5274.
 31. Stacchiotti S, Palassini E, Sanfilippo R et al. Gemcitabine in advanced angiosarcoma: a retrospective case series analysis from the Italian Rare Cancer Network. *Ann Oncol* 2012; 23: 501–508.
 32. Lorigan P, Verweij J, Papai Z et al. Phase III trial of two investigational schedules of ifosfamide compared with standard-dose doxorubicin in advanced or metastatic soft tissue sarcoma: a European Organisation for Research and Treatment of Cancer Soft Tissue and Bone Sarcoma Group Study. *J Clin Oncol* 2007; 25: 3144–3150.
 33. Rutkowski P, Klimczak A, Ługowska I et al. Long-term results of treatment of advanced dermatofibrosarcoma protuberans (DFSP) with imatinib mesylate - the impact of fibrosarcomatous transformation. *Eur J Surg Oncol* 2017; 43: 1134–1141.
 34. Cassier PA, Gelderblom H, Stacchiotti S et al. Efficacy of imatinib mesylate for the treatment of locally advanced and/or metastatic tenosynovial giant cell tumor/pigmented villonodular synovitis. *Cancer* 2012; 118: 1649–1655.
 35. Gelderblom H, Cropet C, Chevreau C et al. Nilotinib in locally advanced pigmented villonodular synovitis: a multicentre, open-label, single-arm, phase 2 trial. *Lancet Oncol* 2018; March 20 [Epub ahead of print].
 36. Le Cesne A, Antoine E, Spielmann M et al. High-dose ifosfamide: circumvention of resistance to standard-dose ifosfamide in advanced soft tissue sarcomas. *J Clin Oncol* 1995; 13: 1600–1608.
 37. Martin-Liberal J, Alam S, Constantinidou A et al. Clinical activity and tolerability of a 14-day infusional ifosfamide schedule in soft-tissue sarcoma. *Sarcoma* 2013; 2013: 868973.
 38. Demetri GD, Chawla SP, von Mehren M et al. Efficacy and safety of trabectedin in patients with advanced or metastatic liposarcoma or leiomyosarcoma after failure of prior anthracyclines and ifosfamide: results of a randomized phase II study of two different schedules. *J Clin Oncol* 2009; 27: 4188–4196.
 39. Demetri GD, von Mehren M, Jones RL et al. Efficacy and safety of trabectedin or dacarbazine for metastatic liposarcoma or leiomyosarcoma after failure of conventional chemotherapy: results of a phase III randomized multicenter clinical trial. *J Clin Oncol* 2016; 34: 786–793.
 40. Grosso F, Jones RL, Demetri GD et al. Efficacy of trabectedin (ecteinascidin-743) in advanced pretreated myxoid liposarcomas: a retrospective study. *Lancet Oncol* 2007; 8: 595–602.
 41. van der Graaf WT, Blay JY, Chawla SP et al. Pazopanib for metastatic soft-tissue sarcoma (PALETTE): a randomised, double-blind, placebo-controlled phase 3 trial. *Lancet* 2012; 379: 1879–1886.
 42. Schoffski P, Chawla S, Maki RG et al. Eribulin versus dacarbazine in previously treated patients with advanced liposarcoma or leiomyosarcoma: a randomised, open-label, multicentre, phase 3 trial. *Lancet* 2016; 387: 1629–1637.
 43. Maki RG, Wathen JK, Patel SR et al. Randomized phase II study of gemcitabine and docetaxel compared with gemcitabine alone in patients with metastatic soft tissue sarcomas: results of sarcoma alliance for research through collaboration study 002 [corrected]. *J Clin Oncol* 2007; 25: 2755–2763.
 44. García-Del-Muro X, López-Pousa A, Maurel J et al. Randomized phase II study comparing gemcitabine plus dacarbazine versus dacarbazine alone in patients with previously treated soft tissue sarcoma: a Spanish Group for Research on Sarcomas study. *J Clin Oncol* 2011; 29: 2528–2533.
 45. Berry V, Basson L, Bogart E et al. REGOSARC: regorafenib versus placebo in doxorubicin-refractory soft-tissue sarcoma—a quality-adjusted time without symptoms of progression or toxicity analysis. *Cancer* 2017; 123: 2294–2302.
 46. Mir O, Brodowicz T, Italiano A et al. Safety and efficacy of regorafenib in patients with advanced soft tissue sarcoma (REGOSARC): a randomised,

- double-blind, placebo-controlled, phase 2 trial. *Lancet Oncol* 2016; 17: 1732–1742.
47. Benson C, Vitfell-Rasmussen J, Maruzzo M et al. A retrospective study of patients with malignant PEComa receiving treatment with sirolimus or temsirolimus: the Royal Marsden Hospital experience. *Anticancer Res* 2014; 34: 3663–3668.
 48. Wagner AJ, Malinowska-Kolodziej I, Morgan JA et al. Clinical activity of mTOR inhibition with sirolimus in malignant perivascular epithelioid cell tumors: targeting the pathogenic activation of mTORC1 in tumors. *J Clin Oncol* 2010; 28: 835–840.
 49. Stacchiotti S, Provenzano S, Dagrada G et al. Sirolimus in advanced epithelioid hemangioendothelioma: a retrospective case-series analysis from the Italian Rare Cancer Network database. *Ann Surg Oncol* 2016; 23: 2735–2744.
 50. Butrynski JE, D'Adamo DR, Hornick JL et al. Crizotinib in ALK-rearranged inflammatory myofibroblastic tumor. *N Engl J Med* 2010; 363: 1727–1733.
 51. Kummar S, Allen D, Monks A et al. Cediranib for metastatic alveolar soft part sarcoma. *J Clin Oncol* 2013; 31: 2296–2302.
 52. Stacchiotti S, Tamborini E, Marrari A et al. Response to sunitinib malate in advanced alveolar soft part sarcoma. *Clin Cancer Res* 2009; 15: 1096–1104.
 53. Stacchiotti S, Negri T, Libertini M et al. Sunitinib malate in solitary fibrous tumor (SFT). *Ann Oncol* 2012; 23: 3171–3179.
 54. Rothermundt C, Whelan JS, Dileo P et al. What is the role of routine follow-up for localised limb soft tissue sarcomas? A retrospective analysis of 174 patients. *Br J Cancer* 2014; 110: 2420–2426.
 55. Trans-Atlantic RPS Working Group. Management of primary retroperitoneal sarcoma (RPS) in the adult: a consensus approach from the Trans-Atlantic RPS Working Group. *Ann Surg Oncol* 2015; 22: 256–263.
 56. Bonvalot S, Rivoire M, Castaing M et al. Primary retroperitoneal sarcomas: a multivariate analysis of surgical factors associated with local control. *J Clin Oncol* 2009; 27: 31–37.
 57. Gronchi A, Miceli R, Colombo C et al. Frontline extended surgery is associated with improved survival in retroperitoneal low- to intermediate-grade soft tissue sarcomas. *Ann Oncol* 2012; 23: 1067–1073.
 58. Angele MK, Albertsmeier M, Prix NJ et al. Effectiveness of regional hyperthermia with chemotherapy for high-risk retroperitoneal and abdominal soft-tissue sarcoma after complete surgical resection: a subgroup analysis of a randomized phase-III multicenter study. *Ann Surg* 2014; 260: 749–754; discussion 754–756.
 59. MacNeill AJ, Miceli R, Strauss DC et al. Post-relapse outcomes after primary extended resection of retroperitoneal sarcoma: a report from the Trans-Atlantic RPS Working Group. *Cancer* 2017; 123: 1971–1978.
 60. Gronchi A, Strauss DC, Miceli R et al. Variability in patterns of recurrence after resection of primary retroperitoneal sarcoma (RPS): a report on 1007 patients from the multi-institutional collaborative RPS Working Group. *Ann Surg* 2016; 263: 1002–1009.
 61. Trans-Atlantic RPS Working Group. Management of recurrent retroperitoneal sarcoma (RPS) in the adult: a consensus approach from the Trans-Atlantic RPS Working Group. *Ann Surg Oncol* 2016; 23: 3531–3540.
 62. Kho KA, Nezhat CH. Evaluating the risks of electric uterine morcellation. *JAMA* 2014; 311: 905–906.
 63. Raspagliesi F, Maltese G, Bogani G et al. Morcellation worsens survival outcomes in patients with undiagnosed uterine leiomyosarcomas: a retrospective MITO group study. *Gynecol Oncol* 2017; 144: 90–95.
 64. Ip PP, Cheung AN. Pathology of uterine leiomyosarcomas and smooth muscle tumours of uncertain malignant potential. *Best Pract Res Clin Obstet Gynaecol* 2011; 25: 691–704.
 65. Reed NS, Mangioni C, Malmstrom H et al. Phase III randomised study to evaluate the role of adjuvant pelvic radiotherapy in the treatment of uterine sarcomas stages I and II: an European Organisation for Research and Treatment of Cancer Gynaecological Cancer Group study (protocol 55874). *Eur J Cancer* 2008; 44: 808–818.
 66. Hensley ML, Ishill N, Soslow R et al. Adjuvant gemcitabine plus docetaxel for completely resected stages I-IV high grade uterine leiomyosarcoma: results of a prospective study. *Gynecol Oncol* 2009; 112: 563–567.
 67. Hensley ML, Wathen JK, Maki RG et al. Adjuvant therapy for high-grade, uterus-limited leiomyosarcoma: results of a phase 2 trial (SARC 005). *Cancer* 2013; 119: 1555–1561.
 68. Rauh-Hain JA, del Carmen MG. Endometrial stromal sarcoma: a systematic review. *Obstet Gynecol* 2013; 122: 676–683.
 69. Lee CH, Ou WB, Mariño-Enriquez A et al. 14-3-3 fusion oncogenes in high-grade endometrial stromal sarcoma. *Proc Natl Acad Sci USA* 2012; 109: 929–934.
 70. Hemming ML, Wagner AJ, Nucci MR et al. YWHAE-rearranged high-grade endometrial stromal sarcoma: two-center case series and response to chemotherapy. *Gynecol Oncol* 2017; 145: 531–535.
 71. Schwartz PE, Hui P, McCarthy S. Hormonal therapy for aggressive angioomyxoma: a case report and proposed management algorithm. *J Low Genit Tract Dis* 2014; 18: e55–e61.
 72. Gronchi A, Colombo C, Le Pechoux C et al. Sporadic desmoid-type fibromatosis: a stepwise approach to a non-metastasising neoplasm—a position paper from the Italian and the French Sarcoma Group. *Ann Oncol* 2014; 25: 578–583.
 73. Kasper B, Baumgarten C, Garcia J et al. An update on the management of sporadic desmoid-type fibromatosis: a European Consensus Initiative between Sarcoma Patients EuroNet (SPAEN) and European Organization for Research and Treatment of Cancer (EORTC)/Soft Tissue and Bone Sarcoma Group (STBSG). *Ann Oncol* 2017; 28: 2399–2408.
 74. van Broekhoven DL, Deroose JP, Bonvalot S et al. Isolated limb perfusion using tumour necrosis factor alpha and melphalan in patients with advanced aggressive fibromatosis. *Br J Surg* 2014; 101: 1674–1680.
 75. Schmitz JJ, Schmit GD, Atwell TD et al. Percutaneous cryoablation of extraabdominal desmoid tumors: a 10-year experience. *AJR Am J Roentgenol* 2016; 207: 190–195.
 76. de Camargo VP, Keohan ML, D'Adamo DR et al. Clinical outcomes of systemic therapy for patients with deep fibromatosis (desmoid tumor). *Cancer* 2010; 116: 2258–2265.
 77. Palassini E, Frezza AM, Mariani L et al. Long-term efficacy of methotrexate plus vinblastine/vinorelbine in a large series of patients affected by desmoid-type fibromatosis. *Cancer J* 2017; 23: 86–91.
 78. Skapek SX, Anderson JR, Hill DA et al. Safety and efficacy of high-dose tamoxifen and sulindac for desmoid tumor in children: results of a Children's Oncology Group (COG) phase II study. *Pediatr Blood Cancer* 2013; 60: 1108–1112.
 79. Constantidou A, Jones RL, Scurr M et al. Pegylated liposomal doxorubicin, an effective, well-tolerated treatment for refractory aggressive fibromatosis. *Eur J Cancer* 2009; 45: 2930–2934.
 80. Szucs Z, Messiou C, Wong HH et al. Pazopanib, a promising option for the treatment of aggressive fibromatosis. *Anticancer Drugs* 2017; 28: 421–426.
 81. Kasper B, Gruenwald V, Reichardt P et al. Imatinib induces sustained progression arrest in RECIST progressive desmoid tumours: final results of a phase II study of the German Interdisciplinary Sarcoma Group (GISG). *Eur J Cancer* 2017; 76: 60–67.
 82. Munhoz RR, Lefkowitz RA, Kuk D et al. Efficacy of sorafenib in patients with desmoid-type fibromatosis. *J Clin Oncol* 2015; 34 (Suppl 15): Abstr 11065.
 83. Cherny NI, Dafni U, Bogaerts J et al. ESMO-Magnitude of Clinical Benefit Scale Version 1.1. *Ann Oncol* 2017; 28: 2340–2366.
 84. Dykewicz CA. Summary of the guidelines for preventing opportunistic infections among hematopoietic stem cell transplant recipients. *Clin Infect Dis* 2001; 33: 139–144.