

HEAD AND NECK

# Anatomic and radiologic relationships of neck structures to cervical spine: implications for anterior surgical approaches

## *Rapporti anatomici e radiologici delle strutture cervicali in relazione al rachide: implicazioni per gli approcci cervicotomici anteriori al rachide*

Matteo Alicandri-Ciuffelli<sup>1,2</sup>, Matteo Fermi<sup>1</sup>, Giulia Molinari<sup>1</sup>, Elisa Aggazzotti Cavazza<sup>1</sup>, Anna Maria Billi<sup>4</sup>, Giuliano Gilliberto<sup>2</sup>, Francesca Cavalleri<sup>3</sup>, Giacomo Pavesi<sup>2</sup>, Livio Presutti<sup>1</sup>

<sup>1</sup> Otorhinolaryngology-Head and Neck Surgery Department, University Hospital of Modena, Italy; <sup>2</sup> Neurosurgery Department, New Civil Hospital Sant'Agostino-Estense, Baggiovara (MO), Italy; <sup>3</sup> Neuroradiology Department, New Civil Hospital Sant'Agostino-Estense, Baggiovara (MO), Italy; <sup>4</sup> Department of Biomedical and Neuromotor Sciences, University of Bologna, Italy

### SUMMARY

The position of the pharyngolaryngeal framework is very important in choosing the best surgical approach for cervical spine disease. The aim of the present paper is to investigate the position of the hyoid bone and cricoid cartilage in relation to the cervical spine. Moreover, the surgical implications for anterior transcervical approaches to the upper spine and the prevertebral space are discussed. To minimise complication rates and increase surgical effectiveness, the location and extent of the cervical spine disease should be evaluated in the context of the patient's specific anatomy. A retrospective analysis of 100 cervical spine MRIs was conducted. Patients with diseases that could alter anatomic relationships of cervical structures were excluded. The mid-sagittal view of the hyoid and the inferior margin of the cricoid cartilage were projected perpendicularly to the anterior surface of the cervical vertebrae. The distance between these two landmarks was measured on the same view. The distribution of hyoid projections ranged between C2-C3 and C4-C5 intervertebral space, while the cricoid cartilage ranged between C4-C5 and C7-T1 intervertebral spaces. The mean distance between these two landmarks was  $49.1 \pm 7.7$  mm, with statistically significant differences between males and females. The position of the cricoid cartilage significantly influenced the length of the pharyngolaryngeal framework, while the position of hyoid did not. A wide range of variability in the position of the hyoid bone and the cricoid cartilage in relation to cervical levels exists. This implies that an *a priori* association of a cervical level to neck structures at risk might be inaccurate. The use of these easily identifiable landmarks on pre-operative imaging may help to guide the choice among different anterior surgical approaches to cervical spine and reduce the risk of surgical complications.

**KEY WORDS:** cervical vertebrae, recurrent laryngeal nerve, vocal cord paralysis, swallowing disorders, hypoglossal nerve

### RIASSUNTO

La posizione del framework faringolaringeo è importante nel decidere quale approccio al rachide cervicale adottare. L'obiettivo dello studio è di analizzare la posizione dell'osso ioide e della cartilagine cricoide in relazione ai livelli del rachide cervicale e discuterne le possibili implicazioni per gli accessi cervicotomici al rachide cervicale ed allo spazio prevertebrale. Infatti, per ridurre al minimo le complicanze legate a tale chirurgia ed incrementare l'efficacia del trattamento, la posizione ed estensione del processo patologico a carico del rachide dovrebbe essere inquadrata rispetto ai rapporti anatomici con l'asse faringo-laringeo del singolo paziente. È stata condotta un'analisi retrospettiva di 100 risonanze magnetiche cervicali, escludendo i pazienti che presentavano lesioni che potessero alterare i rapporti anatomici con le vertebre cervicali. Prendendo in esame le scansioni sagittali sulla linea mediana, l'osso ioide ed il margine inferiore della cricoide sono stati proiettati perpendicolarmente sulla superficie anteriore del rachide ed è stata misurata la distanza di queste dal punto di proiezione sulla colonna vertebrale. La distribuzione delle proiezioni dell'osso ioide si attestava tra gli spazi intervertebrali

Received: October 11, 2019  
Accepted: February 16, 2020

### Correspondence

**Matteo Fermi**  
Department of Otorhinolaryngology,  
Head & Neck Surgery, University Hospital  
of Modena, largo del Pozzo 71, 41125 Modena, Italy  
Tel. +39 059 4222402. Fax +39 059 4222454  
E-mail: matteo.fermi.med@gmail.com

### Funding

None.

### Conflict of interest

The Authors declare no conflict of interest.

**How to cite this article:** Alicandri-Ciuffelli M, Fermi M, Molinari G, et al. Anatomic and radiologic relationships of neck structures to cervical spine: implications for anterior surgical approaches. *Acta Otorhinolaryngol Ital* 2020;40:248-253. <https://doi.org/10.14639/0392-100X-N0503>

© Società Italiana di Otorinolaringoiatria e Chirurgia Cervico-Facciale



This is an open access article distributed in accordance with the CC-BY-NC-ND (Creative Commons Attribution-NonCommercial-NoDerivatives 4.0 International) license. The article can be used by giving appropriate credit and mentioning the license, but only for non-commercial purposes and only in the original version. For further information: <https://creativecommons.org/licenses/by-nc-nd/4.0/deed.en>

C2-C3 and C4-C5, mentre quella della cartilagine cricoide tra C4-C5 e C7-T1. La distanza media tra queste due strutture era di  $49,1 \pm 7,7$  mm e vi era differenza statisticamente significativa tra sesso maschile e femminile. La posizione della cricoide influenzava significativamente la lunghezza dell'asse faringo-laringeo, mentre la posizione dell'osso ioide era spesso costante. Da quanto osservato, si evince che esista un ampio raggio di variabilità nella posizione dell'osso ioide e della cartilagine cricoidea rispetto ai livelli delle vertebre cervicali. Da ciò ne deriva che una associazione a priori tra specifici livelli cervicali e strutture del collo a rischio sarebbe poco accurata. L'utilizzo dei reperi proposti, facilmente identificabili radiologicamente, può guidare la scelta tra i diversi approcci cervicotomici anteriori al rachide cervicale, riducendo il rischio di complicanze chirurgiche.

**PAROLE CHIAVE:** vertebre cervicali, nervo laringeo ricorrente, paralisi delle corde vocali, disfagia, nervo ipoglossale

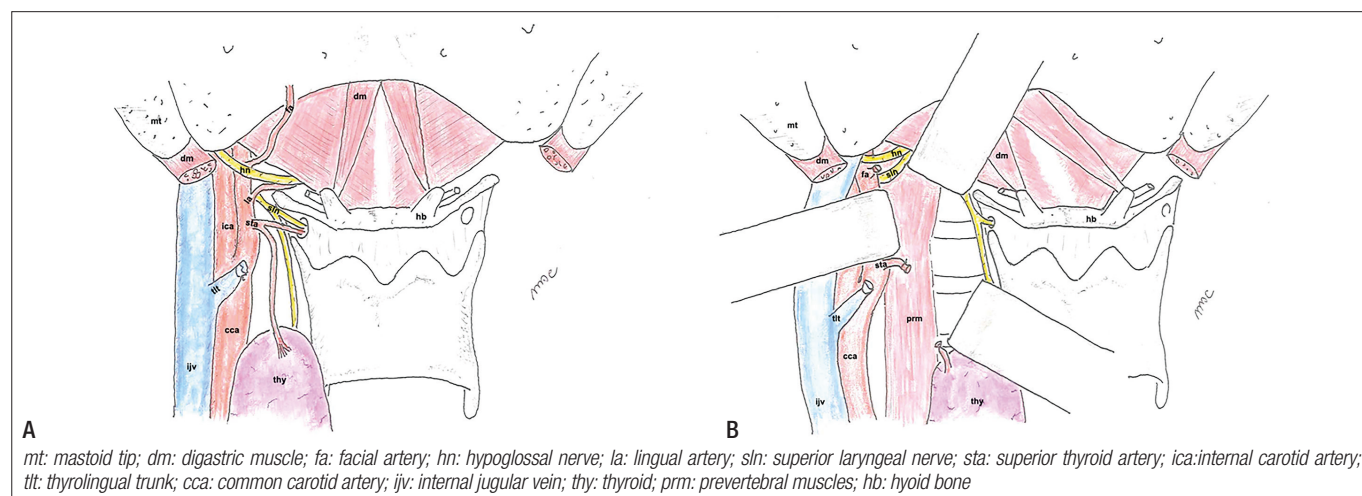
## Introduction

The cervical region is a delicate anatomic site, crossed by several vascular, nervous, respiratory and digestive structures, whose injury can lead to serious complications during or after surgery <sup>1</sup>. Several surgical approaches provide access to the cervical spine (CS). Among these, anterior, lateral and posterior approaches have been described <sup>2</sup>. Cervical disc herniation is traditionally treated by anterior surgical approaches, as described by Cloward in 1958 <sup>3</sup>. The Cloward technique provides an anterior horizontal neck incision, and a dissection performed through an "avascular" pathway between the superficial cervical fascia and the middle layer of the deep cervical fascia. The location and extent of the CS lesion to treat are the major determinants that influence the selection of the most appropriate surgical approach. Moreover, the surgeon should select the approach that allows the widest and most comfortable surgical field and the lowest rate of morbidity. The location and extent of the CS disease should be evaluated in the context of the patient's specific anatomy in order to minimise complication rates and increase surgical effectiveness. Pre-operative imaging, mostly CS magnetic resonance imaging (MRI), provides clear visualisation of the area that has to be treated, as well

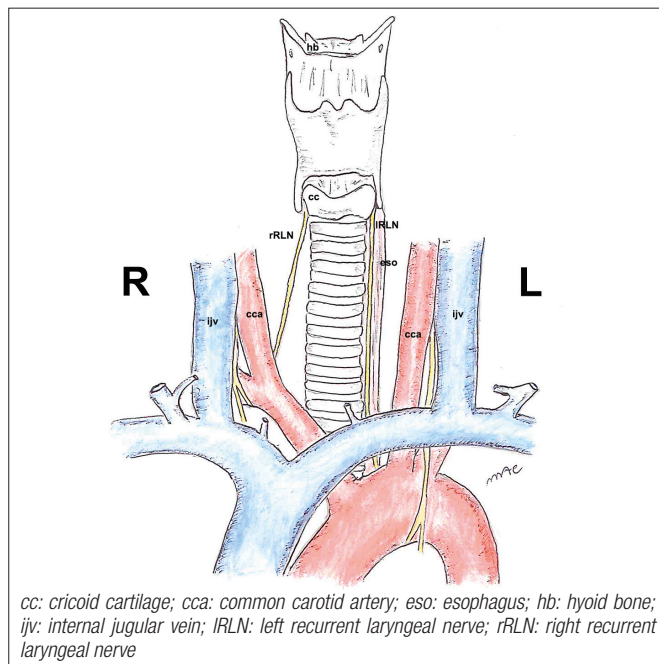
as some surgical landmarks in the neck. When the upper CS (C0-C2) is affected by the disease, the Cloward approach may not guarantee an adequate area of exposure and manoeuvring. Thus, wider incisions and appropriate dissection of superior laryngeal nerve (SLN), hypoglossal nerve (HN), and external carotid artery branches are required, possibly in cooperation with a head and neck surgeon. The hyoid bone (HB) has a central position in the neck, and it has a close relationship with all the above-mentioned structures (Fig. 1).

The primary aim of this radiologic study is to evaluate the position and variability of HB in relation to the cervical spine (i.e. level of vertebrae or discs) in a cohort of patients. Relationship of the HB with the CS may help in planning the best approach based on the position of the pathology relative to the HB.

Another important structure that can be encountered during anterior cervical spine (ACS) approaches is the recurrent laryngeal nerve (RLN). As is well known, the RLN has a different path between the right and left side, having a more lateral course on the right side and thus being traditionally considered at greater risk of iatrogenic damage on this side (Fig. 2). The RLN enters the larynx at the level of the inferior margin of the cricoid cartilage (IMCC). Therefore, as a



**Figure 1.** Anterior cervical region, coronal view. (A) anatomical structures to be aware of during a high prevascular retrovisceral approach. Note the anatomic relationship among the superior laryngeal nerve and the hyoid bone; (B) ligature of the superior thyroid artery and retraction of the neurovascular bundle to expose the prevertebral muscles and the upper/mid cervical spine. Careful cranial retraction of the hypoglossal nerve and the superior laryngeal nerve can widen the surgical space.



**Figure 2.** Anterior cervical region, coronal view. Schematic drawing showing the pathway of inferior laryngeal nerves. Note the oblique direction on the right side toward the inferior margin of the cricoid cartilage.

secondary outcome, the position of the IMCC compared to CS level and its variability are analysed. This finding may help surgeons to choose the optimal side of the approach.

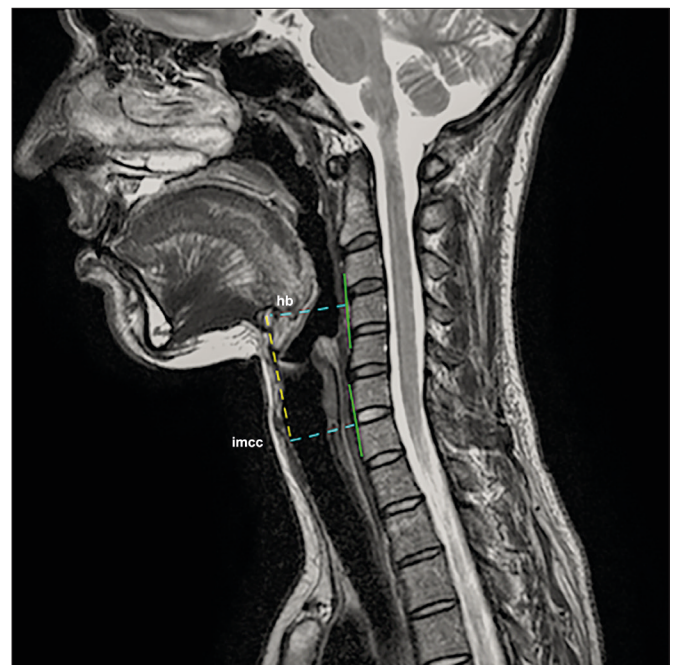
## Materials and methods

The CS MRIs of 100 patients were randomly selected among MRIs performed between 2005 and 2017. 50 males and 50 females (age range: 25-96) were selected. MRI was performed at the same institution using a 1.5-T scanner (Intera; Philips Medical Systems, Best, The Netherlands). Being a purely retrospective observational radiologic study, neither institutional research board/ethics committee approval nor patient consent were required at our institution. Poor-quality MRI images, such as those with movement artefacts or with inappropriate radiologic positioning of the patient, were discarded. Patients with a cervical pathology markedly altering the anatomy of the neck or of the spine were excluded. All the distances and projections were assessed by an experienced neuroradiologist (F.C.) on either T1 weighted or T2 weighted MRI on sagittal plane, depending on which sequence had the best image definition of HB, IMCC and CS vertebrae. The anatomical landmark usually used to describe the RLN's relationships was the inferior cornua of the thyroid cartilage. Nevertheless, the IMCC was chosen as a radiologic landmark due to its easier detection on MRI images. The position of the HB and IMCC were assessed, choosing the cut

where their entire sagittal image was visualised. To determine their projection on the cervical spine, a roughly parallel line to the anterior surface of the cervical vertebrae was considered. The centre of the sagittal view of the HB and the posterior edge of the IMCC were projected perpendicularly on this line. Specifically, when the projection was either on the intervertebral disk, the superior quarter of the lower vertebral body (VB), or the inferior quarter of the upper vertebral body, the projection level was C (number of the superior VB) - C (number of the inferior VB). When the projection level was on the central two quarters of the VB, the level attribution was C (number of that VB).

To define the length of the laryngeal framework, the distance between the HB and the IMCC was measured in the same view, drawing a perpendicular line between the centre of the HB and the line passing through the IMCC (Fig. 3).

All data were tabulated and results for continuous variables are presented as mean  $\pm$  standard deviation. All statistic analyses were conducted with SPSS 17.0 software (SPSS Inc., Chicago, Illinois, USA). The data were analysed with a Student's t test for continuous variables. HB and IMCC projections on the spine were subgrouped for statistical analysis as follows: C2-C3/C3, C3-C4/C4, C4-C5/C5, C5-C6/C6 and C6-C7/C7. To analyse the relationships between HB and IMCC projections on the spine (categorical variables) and the distance between the HB and IMCC



**Figure 3.** Magnetic resonance imaging, sagittal plane, T2-weighted. Green line: roughly parallel line to the anterior surface of the cervical vertebrae bodies; blue line: projection of the hyoid bone and inferior margin of cricoid cartilage to the cervical spine; yellow line: distance between the hyoid bone and the inferior margin of cricoid cartilage (length of the laryngeal framework).

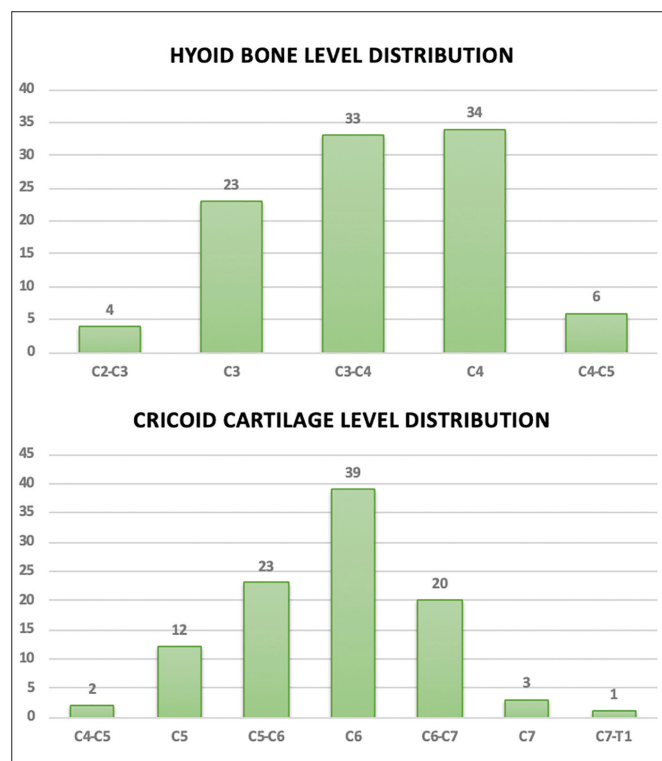


(continuous variables), one-way analysis of variance tests (ANOVA) were performed. Bonferroni post-hoc test was applied to the results. A P value < 0.05 were considered statistically significant.

## Results

The mean distance between the HB and the IMCC was  $49.1 \pm 7.7$  mm. Significant differences between males and females were observed: the mean distance was  $53.5 \pm 6.1$  mm and  $44.7 \pm 6.5$  mm, respectively ( $p = 0.00$ ). The projections of the HB and the IMCC on the CS were evaluated. The distribution of HB projections ranged between C2-C3 and C4-C5 intervertebral space with 4% located at C2-C3 intervertebral space, 23% at C3 vertebral body, 33% at C3-C4 space, 34% at C4 vertebral body and 6% at C4-C5 intervertebral space (Fig. 4). These data were compared between males and females, with no statistical differences between groups ( $p = 0.06$ ).

The distribution of IMCC projections ranged between C4-C5 and C7-T1 intervertebral spaces with 2% among C4-C5, 12% at C5 body level, 23% at C5-C6 intervertebral space, 39% at C6 vertebral body, 20% at C6-C7 intervertebral space, 3% at the level of C7 body and just in one case below C7 (1%). In the female group, none



**Figure 4.** Histograms showing the distribution of projection on the cervical spine of hyoid bone (HB) and inferior margin of cricoid cartilage (IMCC) in the case series analysed.

of the cricoid cartilages was located more caudally than C6-C7 intervertebral space. (Fig. 4) These data as well were compared in men and women, showing significant differences ( $p = 0.03$ ).

The one-way analysis of variance tests (ANOVA) showed no significant relationship among HB-IMCC distance and HB projections on the spine ( $p > 0.05$ ), while statistical significance was found among HB-IMCC distance and IMCC projections, in particular among C4-C5/C5 and C6-C7/C7 subgroups ( $p = 0.00$ ) and C5-C6/C6 and C6-C7/C7 subgroups ( $p = 0.002$ ).

## Discussion

The anterior approach to the cervical spine is a widely used technique to deal with diseases that arise primarily from the anterior spinal column, such as trauma or degenerative conditions. Since 1958, when it was first described by Cloward RB and Smith GW, it was evident that the main obstacles to the achievement of the anterior aspect of the cervical spine were anatomical<sup>3-5</sup>. Various authors made the effort to thoroughly describe the key anatomical structures (e.g. SLN, superior thyroid artery, RLN, inferior thyroid artery, sympathetic trunk, oesophagus, etc.) that surgeons had to be aware of during dissection<sup>6-10</sup>. Nevertheless, different intraoperative and postoperative complications can still occur. Accurate location and extent of the skin incision are helpful to decrease technical difficulties and surgical time in ACS surgery. Adequate exposure of the surgical field can ease surgical manoeuvring, increase light, and reduce retraction of soft tissues, with less pressure damage to vital organs. Spine surgeons can use neck palpatory landmarks (e.g. HB, thyroid cartilage and cricoid cartilage) to decide the site of the surgical incision, which should be performed at the midpoint of the level of surgery<sup>11</sup>. However, Liu et al. demonstrated in their radiologic study that the HB, the thyroid and cricoid cartilages were not reliable to predict cervical levels, while the angle of the mandible was found to be the most accurate landmark for identifying C2/C2-C3 disc space<sup>12</sup>. They postulated that, due to a great variability in intraoperative neck flexo-extension and spinal degeneration, those superficial landmarks were not reliable to decide the site of the incision.

Haller et al. investigated the anatomic relationship of the HN, SLN and its branches, superior thyroid and laryngeal artery with the cervical spine to demonstrate their vulnerability during upper ACS surgery. They postulated that spine surgeons can be aware of which neurovascular structures are at risk at a given cervical level<sup>13</sup>. Nevertheless, the relationship between cervical spine levels and neck structures can be highly variable, so that *a priori* association of a cervical level to structures

at risk, as described by Haller et al, can be inaccurate <sup>13</sup>. As shown in the present radiologic study, a wide range of variability in terms of the size of the pharyngo-laryngeal framework and the projections of two key landmarks of the neck (HB and IMCC) to cervical levels does exist. Since this was a radiologic study, the position of the patient while performing the MRI could vary from the final position in the operative room, where in most cases the head is more extended. However, it is common for spinal surgeons to perform an intraoperative x-ray in latero-lateral projection to choose the position of the incision. Since the HB and IMCC are easily identifiable on radiographs, this intraoperative imaging would possibly help in confirming the optimal approach selected on the basis of the MRI. Moreover, patients with CS disease usually have neck stiffness and can rarely modify their extension significantly. Melamed et al. thoroughly described the SLN anatomy and its position posteriorly to the superior thyroid pedicle at the level of the HB. Its damage often results in the loss of the high-pitched tones and in decreasing of the sensitive reflexes of the supraglottic and hypopharyngeal regions, leading to increased risk of dysphagia and aspiration <sup>9</sup>. Dysphagia is a common complication after ACS surgery, and its occurrence is possibly due not only to SLN damage, but also to RLN impairment, HN damage, oesophageal ischemia, reperfusion injury, or soft tissue swelling. The reported incidence of dysphagia is widely variable in the literature. However, an incidence up to 71% during the two postoperative weeks has been reported in well-designed prospective studies <sup>14</sup>. The wide variation may be partially explained by the fact that dysphagia is routinely underestimated. Tasiou et al. reported that the incidence of dysphagia was 11% when based on physician's notes, while it increased to 57% when the patients were surveyed <sup>15</sup>. HN injury, which is a well-documented complication after soft tissue surgery of the neck, is a rare event after ACS surgery. It can lead to persistent or transient dysphagia of the oral phase and dysarthria. It occurs more frequently in upper ACS surgery, and the reason is anatomical <sup>16,17</sup>. HN exits the posterior skull base through the hypoglossal canal in the occipital bone and runs inferiorly towards the carotid sheath, together with the vagus nerve in its first segment. Below C1/C2, it proceeds between the carotid artery and the internal jugular vein, while below C2/C3 it runs medially <sup>13</sup>. At this level, during a retropharyngeal approach to the upper CS, the hypoglossal nerve may mimic a venous vessel crossing the field, so great caution should be taken when interrupting venous-like structures in this location <sup>17</sup>. Below C2/C3, the path of the HN becomes lateral and it does not appear in the operative field during ACS surgery <sup>16</sup>. Careful preoperative assessment of the position of the

HB and its projection on the cervical spine may improve the management of the SLN and its branches, leading to a significant reduction in postoperative dysphagia or dysarthria. Our results demonstrated that the position of the HB was inconstant. The position ranged between C2-C3 and C4-C5 intervertebral spaces with no significant differences among males and females. Thus, it might be postulated that, based on the position of the disease with respect to this landmark, a specific anterior approach could be indicated in order to limit the possible complications involving the SLN and the HN. When the disease was located more cephalad to the HB, a standard anterolateral approach could be inadequate due to the limited exposure of important landmarks such as the SLN and the HN and could expose patients to the above-mentioned complications. In these cases, a longitudinal cervical incision, possibly extending anteriorly toward submandibular/submental spaces might be more appropriate. Pre-emptive identification and isolation of the SLN and HN should be performed. Moreover, ligation of the thyrolingual trunk could help to further improve manoeuvring and exposure. Furthermore, identification and ligation of the external carotid artery branches could be performed *à la demande* to extend the dissection even more cranially in order to reach the upmost tract of the cervical spine (C1-C2) by an upper prevascular retrovisceral approach (Tab. I) <sup>18</sup>. The incidence of vocal cord palsy/paralysis due to RLN injury during ACS surgery ranges from 2.3% to 24.2% <sup>19</sup>. The differences in percentages are possibly due to significant heterogeneity in study designs and definition of vocal cord impairment by various authors. Moreover, some studies suggested that RLN palsy (RNLN) is underreported <sup>15</sup>. Indeed, asymptomatic RLNPs are more frequent than symptomatic ones with hoarseness <sup>20</sup>. This may explain why this complication may be underestimated. Different authors have described the anatomy of the RLN and its relationship to vascular and fascial structures <sup>10</sup>. Jung et al. showed that a left-sided approach in ACS surgery significantly reduced the incidence of both early postoperative and permanent (3-months follow up) RLNP from 24.2% and 13.3% respectively, to 14% and 6.5% <sup>21</sup>. This is probably

**Table I.** Surgical approaches suggested based on disease extension compared to neck structures: hyoid bone (HB); inferior margin of cricoid cartilage (IMCC).

Disease level related to neck structures	Surgical anterior approach
Cranial to HB	High prevascular retrovisceral approach HPRA
Between HB and IMCC	Standard Cloward approach
Caudal to IMCC	Standard Cloward approach (left side preferred)

due to the more vertical course of the nerve on the left side, where it lies in a relatively protected position within the oesophagotracheal groove<sup>6</sup>. Nevertheless, it is sometimes mandatory to reach the CS from the right side (e.g. right spinal cervical nerve compression) and some authors still prefer the right-sided approach to the lower CS due to easier dissection for right-handed surgeons<sup>11</sup>. Shan et al. postulated that the pathway of the right RLN in the space between the carotid and visceral sheaths is located below the C7-T1 disc<sup>10</sup>. This would imply that the IMCC would lie at this level or below. On the contrary, based on our findings, the RLN extends cranially even to C4/C5 intervertebral disc in some patients, and is located more cephalad to C7 and C6 in 96% and 37% of cases, respectively. These results have direct impact on the surgical approach for ACS and underline the importance of careful preoperative assessment of the location of the lesion with respect to the IMCC, especially in case of any disease that has to be approached by anterior access from the right side, where the pathway of the RLN is oblique and where it might be jeopardised by the retraction applied to the trachea/oesophagus and neurovascular bundle (Tab. I). Moreover, when deemed appropriate, an x-ray can be performed intraoperatively in order to verify the cervical spine level and to check the relationship with the cartilaginous skeleton of the larynx. The present authors are aware that surgeons' habits and experience can play a major role in choosing the surgical approach (e.g. the side based on handedness), but the aim of the study was to stimulate the surgical community to consider the variability in neck structures in relation with the CS and foster cooperation among spinal and head and neck surgeons for selected CS surgeries, when deemed appropriate.

## Conclusions

A wide range of variability in the projections of the HB and IMCC to cervical spine levels and in the length of the pharyngo-laryngeal framework exists. This implies that an *a priori* association of a cervical level to specific anatomical structures at risk can be inaccurate. Instead, the use of anatomical landmarks that are easily identifiable on pre-operative and intra-operative radiology, such as HB and IMCC, can help guide the choice of anterior surgical approach in terms of level, side and type of incision. Thus, thorough evaluation of pre-operative MRI, especially in sagittal planes, is recommended to better understand the position of critical anatomic structures in the neck area and to define the best surgical approach for each specific case.

## References

<sup>1</sup> Bambakidis NC, Dickman CA, Spetzler R, et al. Surgery of the craniovertebral junction. Second Edition. New York: Thieme; 2013.

- <sup>2</sup> Boriani S, Presutti L, Gasbarrini A, et al. Atlas of craniocervical junction and cervical spine surgery. First Edition. New York: Springer; 2017.
- <sup>3</sup> Cloward RB. The anterior approach for removal of ruptured cervical disks. *J Neurosurg* 1958;15:602-17. <https://doi.org/10.3171/jns.1958.15.6.0602>
- <sup>4</sup> Smith GW, Robinson RA. The treatment of certain cervical-spine disorders by anterior removal of the intervertebral disc and interbody fusion. *J Bone Joint Surg Am* 1958;40-A:607-24.
- <sup>5</sup> Southwick WO, Robinson RA. Surgical approaches to the vertebral bodies in the cervical and lumbar regions. *J Bone Joint Surg Am* 1957;39-A:631-44.
- <sup>6</sup> Ebraheim NA, Lu J, Skie M, et al. Vulnerability of the recurrent laryngeal nerve in the anterior approach to the lower cervical spine. *Spine* 1997;22:2664-7. <https://doi.org/10.1097/00007632-199711150-00015>
- <sup>7</sup> Ebraheim NA, Lu J, Yang H, et al. Vulnerability of the sympathetic trunk during the anterior approach to the lower cervical spine. *Spine* 2000;25:1603-6. <https://doi.org/10.1097/00007632-200007010-00002>
- <sup>8</sup> Lu J, Ebraheim NA, Nadim Y, et al. Anterior approach to the cervical spine: surgical anatomy. *Orthopedics* 2000;23:841-5.
- <sup>9</sup> Melamed H, Harris MB, Awasthi D. Anatomic considerations of superior laryngeal nerve during anterior cervical spine procedures. *Spine* 2002;27:E83-6. <https://doi.org/10.1097/00007632-200202150-00005>
- <sup>10</sup> Shan J, Jiang H, Ren D, et al. Anatomic relationship between right recurrent laryngeal nerve and cervical fascia and its application significance in anterior cervical spine surgical approach. *Spine* 2017;42:E443-7. <https://doi.org/10.1097/BRS.0000000000001881>
- <sup>11</sup> Cheung KMC, Mak KC, Luk KDK. Anterior approach to cervical spine. *Spine* 2012;37:E297-302. <https://doi.org/10.1097/BRS.0b013e318239ccd8>
- <sup>12</sup> Liu J-M, Du L-X, Xiong X, et al. Radiographic evaluation of the reliability of neck anatomic structures as anterior cervical surgical landmarks. *World Neurosurg* 2017;103:133-7. <https://doi.org/10.1016/j.wneu.2017.03.129>
- <sup>13</sup> Haller JM, Iwanik M, Shen FH. Clinically relevant anatomy of high anterior cervical approach. *Spine* 2011;36:2116-21. <https://doi.org/10.1097/BRS.0b013e31820408af>
- <sup>14</sup> Rihn JA, Kane J, Albert TJ, et al. What is the incidence and severity of dysphagia after anterior cervical surgery? *Clin Orthop Relat Res* 2011;469:658-65. <https://doi.org/10.1007/s11999-010-1731-8>
- <sup>15</sup> Tasiou A, Giannis T, Brotis AG, et al. Anterior cervical spine surgery-associated complications in a retrospective case-control study. *J Spine Surg* 2017;3:444-59. <https://doi.org/10.21037/jss.2017.08.03>
- <sup>16</sup> Yasuda T, Togawa D, Hasegawa T, et al. Hypoglossal nerve palsy as a complication of an anterior approach for cervical spine surgery. *Asian Spine J* 2015;9:295-8. <https://doi.org/10.4184/asj.2015.9.2.295>
- <sup>17</sup> Sengupta DK, Grevitt MP, Mehdi SMH. Hypoglossal nerve injury as a complication of anterior surgery to the upper cervical spine. *Eur Spine J* 1999;8:78-80. <https://doi.org/10.1007/s005860050131>
- <sup>18</sup> Mattioli F, Ghirelli M, Trebbi M, et al. Improvement of swallowing function after surgical treatment of diffuse idiopathic skeletal hyperostosis: our experience. *World Neurosurg* 2020;134:e29-e36. <https://doi.org/10.1016/j.wneu.2019.08.124>
- <sup>19</sup> Tan TP, Govindarajulu AP, Massicotte EM, et al. Vocal cord palsy after anterior cervical spine surgery: a qualitative systematic review. *Spine J* 2014;14:1332-42. <https://doi.org/10.1016/j.spinee.2014.02.017>
- <sup>20</sup> Govindarajulu AP, Massicotte EM, Tan TP, Venkatraghavan L: Vocal cord palsy after anterior cervical spine surgery: a qualitative systematic review. *Spine J* 2014;14:1332-42.
- <sup>21</sup> Jung A, Schramm J. How to reduce recurrent laryngeal nerve palsy in anterior cervical spine surgery. *Neurosurgery* 2010;67:10-5. <https://doi.org/10.1227/01.NEU.0000370203.26164.24>