

Clinico-Pathological Correlation in Dermatopathology

An Ulcerated Reddish Nodule of the Chest: When You See, Think ...

Giulia Maria Ravaioli Carlotta Baraldi Emi Dika Pier Alessandro Fanti
Cosimo Misciali

Dermatology Unit, Department of Experimental, Diagnostic and Specialty Medicine,
University of Bologna, Bologna, Italy

Keywords

Histopathology · Immunohistochemistry · Melanocytic neoplasms · Melanoma · Skin cancer

Abstract

A 97-year-old man with a previous personal history of multiple nonmelanoma skin cancers presented with a fast-growing, ulcerated reddish nodule on his chest. The nodule was surgically removed, and hematoxylin and eosin stains of the specimen showed an asymmetrical, nonpigmented lesion with architectural and structural impairment, round cells with clear, whitish, foamy cytoplasm, multiple dermal mitoses and nuclear pleomorphism. Our first hypothesis was sebaceous carcinoma, a rare malignant neoplasm derived from epithelial cells showing sebaceous differentiation. A further histopathologic examination showed the presence of pigment in a few areas of the neoplasm. On immunohistochemical study, neoplastic cells were negative for wide-spectrum cytokeratin and diffusely positive for S-100, MART-1, and HMB-45 proteins. Our final diagnosis was nodular malignant melanoma (MM) with balloon epithelioid cells, a “bizarre” presentation of MM in vertical growth phase, mimicking metastatic and primary neoplasms of different lineage derivations.

© 2018 The Author(s)
Published by S. Karger AG, Basel

Case Report

A 97-year-old man presented with a reddish nodule on his chest. The lesion was fast growing, of 3 months' duration, and ulcerated.

The patient had phototype II and a personal history of multiple nonmelanoma skin cancers, i.e., 2 basal cell carcinomas and 2 squamous cell carcinomas, excised during the

Pier Alessandro Fanti
Dermatology Unit, Department of Experimental, Diagnostic and Specialty Medicine
University of Bologna, via Massarenti 1
IT-40138 Bologna (Italy)
E-Mail pieralessandro.fanti@unibo.it

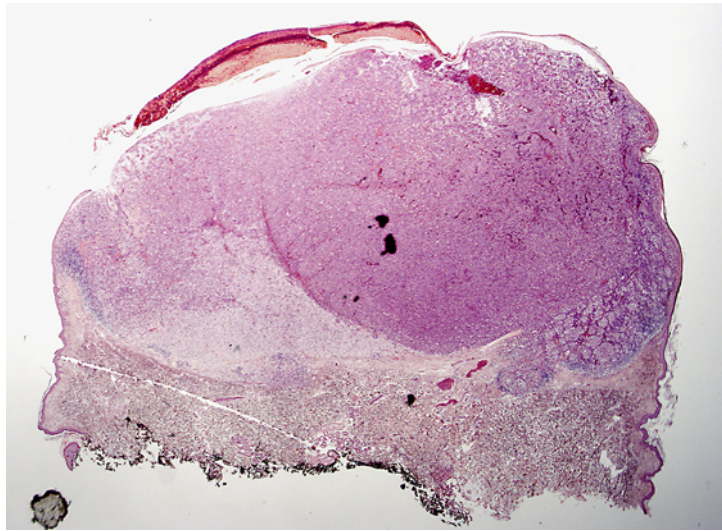


Fig. 1. Hematoxylin and eosin stain (original magnification $\times 10$) of the neoplasm showing a nodular, asymmetrical lesion.

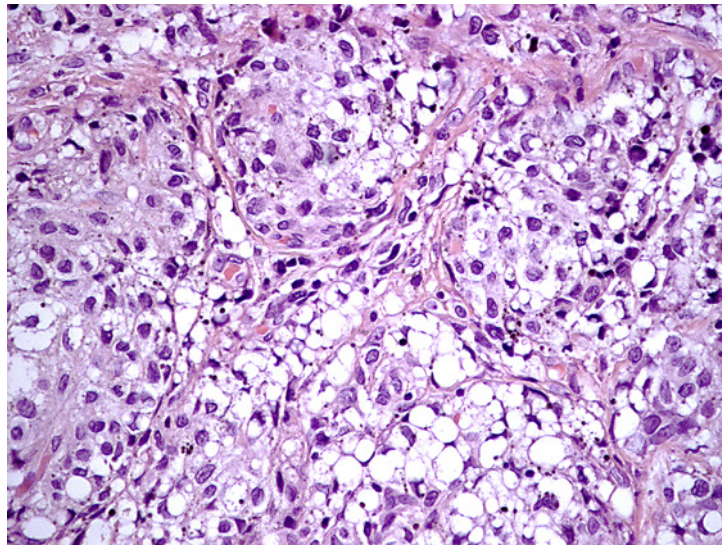


Fig. 2. Hematoxylin and eosin stain (original magnification $\times 40$) of the neoplasm showing round cells with clear, foamy cytoplasm and nuclear pleomorphism.

previous 6 years and followed up at the Dermatology Department of our University Hospital. In addition, he had been treated with cryotherapy and photodynamic therapy for multiple actinic keratoses.

We performed a surgical excision of the nodule and histopathologic examination of the specimen. Hematoxylin and eosin stains showed an asymmetrical, nonpigmented lesion with architectural and structural impairment (Fig. 1). Higher magnification enlightened round cells with clear, whitish, foamy cytoplasm. Moreover, there were multiple dermal mitoses and nuclear pleomorphism (Fig. 2).

Our first hypothesis was sebaceous carcinoma, a rare malignant neoplasm derived from epithelial cells showing sebaceous differentiation [1]. Sebaceous carcinoma is in fact known to affect 1–2:1,000,000 individuals every year, with a predilection for male sex and advanced age. However, it is also often associated with Muir-Torre and Lynch syndrome and usually occurs as a yellow to red-brown, fast-growing, and ulcerated nodule on the face and periorcular areas, while the extraocular variant accounts only for 25% of the cases [2, 3]. Despite the suggestive clinical and histological appearance, the latter clinical features and history were not found in our patient.

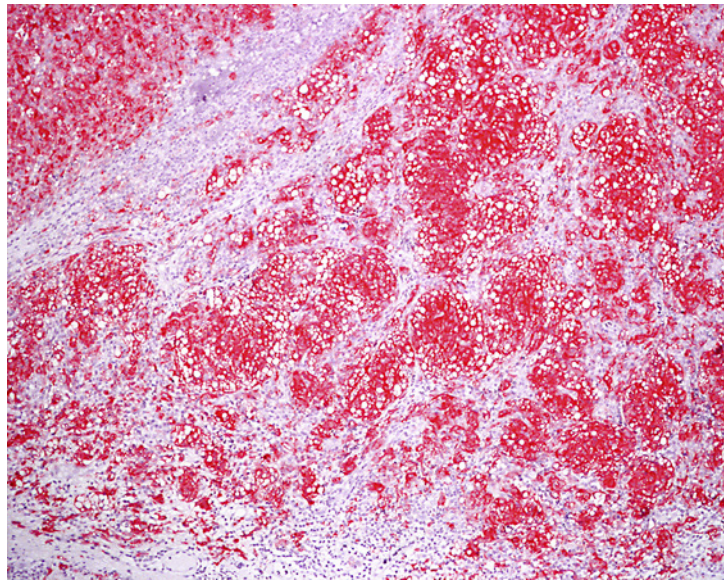


Fig. 3. MART-1 immunohistochemical analysis (original magnification $\times 10$) showing diffuse positivity throughout the lesion.

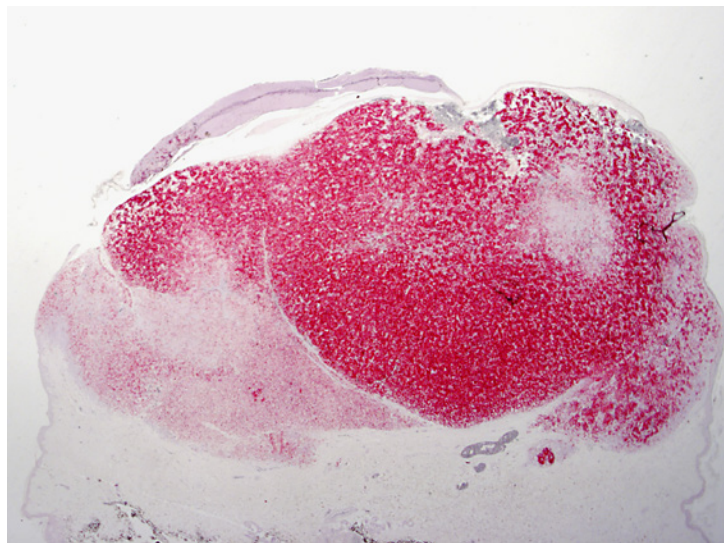


Fig. 4. HMB-45 immunohistochemical analysis (original magnification $\times 10$) showing diffuse positivity throughout the lesion.

By further microscopic examination of the specimen, we noticed the presence of pigment in a few areas of the neoplasm. On immunohistochemical study, neoplastic cells were negative for wide-spectrum cytokeratin and diffusely positive for S-100, MART-1, and HMB-45 proteins (Fig. 3, 4).

Our final diagnosis was nodular malignant melanoma (MM) with balloon epithelioid cells, vertical growth phase, ulceration, 5-mm Breslow thickness, 2 mitoses/mm², and presence of microsatinellites. Histopathologic stage was pT4b.

Discussion

Balloon cell melanoma is a “bizarre” presentation of MM in vertical growth phase, mimicking metastatic and primary neoplasms of different lineage derivations. Balloon cells are the result of melanocytic cytoplasmic vacuolization probably related to a defective melanosome formation [4, 5].

The clinical presentation of balloon cell MM resembles that of other nodular MM. It can present as a primary as well as metastatic MM lesion, also in the absence of a known primary tumor, being a source of concern for dermatopathologists. The final diagnosis should be made by excluding other melanocytic (e.g., balloon cell nevus) and nonmelanocytic neoplasms (e.g., sebaceous carcinoma) and considering together microscopic and architectural features of the neoplasm, peculiar cellular morphology, and immunocytochemical results.

Statement of Ethics

The authors have no ethical conflicts to disclose.

Disclosure Statement

The authors have no conflicts of interest to disclose.

Funding Sources

The authors have not received any funding.

References

- 1 Kylo RL, Brady KL, Hurst EA: Sebaceous carcinoma: review of the literature. *Dermatol Surg* 2015;41:1–15.
- 2 Dasgupta T, Wilson LD, Yu JB: A retrospective review of 1,349 cases of sebaceous carcinoma. *Cancer* 2009;115:158.
- 3 Deprez M, Uffer S: Clinicopathological features of eyelid skin tumors. A retrospective study of 5504 cases and review of literature. *Am J Dermatopathol* 2009;31:256–262.
- 4 Magro CM, Crowson AN, Mihm MC: Unusual variants of malignant melanoma. *Mod Pathol* 2006;19(suppl 2):S41–S70.
- 5 Han JS, Won CH, Chang SE, Lee MW, Choi JH, Moon KC: Primary cutaneous balloon cell melanoma: a very rare variant. *Int J Dermatol* 2014;53:e535–e536.