

Alma Mater Studiorum Università di Bologna
Archivio istituzionale della ricerca

Post-radiotherapy vascular lesions of the breast: immunohistochemical and molecular features of 74 cases with long term follow up and literature review

This is the final peer-reviewed author's accepted manuscript (postprint) of the following publication:

Published Version:

Corradini, A.G., Asioli, S., Morandi, L., Brotto, M., Righi, A., Iommi, M., et al. (2020). Post-radiotherapy vascular lesions of the breast: immunohistochemical and molecular features of 74 cases with long term follow up and literature review. *HISTOPATHOLOGY*, 77(2), 293-302 [10.1111/his.14090].

Availability:

This version is available at: <https://hdl.handle.net/11585/753211> since: 2020-03-27

Published:

DOI: <http://doi.org/10.1111/his.14090>

Terms of use:

Some rights reserved. The terms and conditions for the reuse of this version of the manuscript are specified in the publishing policy. For all terms of use and more information see the publisher's website.

This item was downloaded from IRIS Università di Bologna (<https://cris.unibo.it/>).
When citing, please refer to the published version.

(Article begins on next page)

DR ANGELO CORRADINI (Orcid ID : 0000-0001-7558-1012)

DR ALBERTO RIGHI (Orcid ID : 0000-0002-1074-0155)

MISS CLAUDIO AGOSTINELLI (Orcid ID : 0000-0002-4945-1422)

PROFESSOR MARIA P. FOSCHINI (Orcid ID : 0000-0001-7079-7260)

Article type : Original Article

Corresponding Author Email ID: angelo.corradini@studio.unibo.it

Post-radiotherapy vascular lesions of the breast: immunohistochemical and molecular features of 74 cases with long term follow up and literature review.

Angelo G. Corradini¹, Sofia Asioli¹, Luca Morandi¹, Maurizio Brotto², Alberto Righi³, Marica Iommi⁴, Agostinelli C,⁵ Paola Rucci ⁴, Silvia Asioli⁶, Anna Sapino^{7,8}, Giuseppe Viale⁹, Maria P. Foschini¹

1: Department of Biomedical and Neuromotor Sciences, Section of Anatomic Pathology at Bellaria Hospital, Bologna, Italy.

2: Department of Pathology, Singleton Hospital, Swansea University, Abertawe Bro Morgannwg University Hospital Trust, Wales, UK.

3: Department of Pathology, Istituto Ortopedico Rizzoli, Bologna, Italy.

4: Advanced School for Health Policy - Specialization School for Public Administration, University of Bologna, Italy.

This article has been accepted for publication and undergone full peer review but has not been through the copyediting, typesetting, pagination and proofreading process, which may lead to differences between this version and the [Version of Record](#). Please cite this article as [doi: 10.1111/his.14090](https://doi.org/10.1111/his.14090)

This article is protected by copyright. All rights reserved

5. Haematopathology Unit, Department of Experimental Diagnostic and Specialty Medicine, S. Orsola-Malpighi Hospital, Bologna, Italy.

6: Pathology Unit, Morgagni-Pierantoni Hospital, Forlì, Italy.

7: Candiolo Cancer Institute-FPO-IRCCS, Candiolo (To), Italy.

8: Department of Medical Sciences, University of Torino, Torino, Italy

9: Department of Pathology and Laboratory Medicine, IBCSG Central Pathology Laboratory, European Institute of Oncology, and University of Milan, Italy.

Abstract

Introduction: A wide range of post-radiotherapy vascular lesions can occur, ranging from Benign lymph-angiomaticous papule of the skin (BLAP), to Atypical vascular Lesions (AVL) and post-RT angiosarcomas (Post-RT AS). The relationship between benign and malignant post-RT breast lesions and their prognostic features is still controversial.

Aim of the study is to investigate the relationship between benign and malignant mammary post-RT vascular lesions and to define post-RT AS prognostic features.

Materials and methods: Seventy four cases of post-RT vascular lesions were obtained and stained with antibodies against CD 34, CD 31, D2-40, Ki67, and c-Myc. Mutational analysis was performed by deep sequencing for the following genes: *KRAS*, *NRAS*, *HRAS*, *BRAF*, *PIK3CA*, *TP53*, *NOTCH1*, *PTEN*, *CDKN2A*, *EGFR*, *AKT1*, *CTNNB1*, *hTERT*, *PTPRB*. Post-RT AS were graded according to a previously reported breast AS grading system.

Results: AVL cases showed a low number of mutations in *HRAS* and *hTERT*, while post-RT AS showed a high mutation frequency for *EGFR*, *TP53*, *HRAS*, and *hTERT*. On follow-up, all BLAP and AVL were alive with no evidence of disease. Post-RT AS 5-years overall survival declined with the increase of grade as follows: 85.7% in G1, 83.3% in G2 and 40.4% in G3.

Conclusions: Our findings confirm that BLAP and AVL have a good prognosis, while post-RT AS prognosis is strongly related to histological grading. On molecular analysis, AVL and post-RT AS shared mutations in *HRAS* and *hTERT*, suggesting a relation between the two lesions.

Keywords: Breast, Hemangiosarcoma, Atypical Vascular Lesions, Neoplasms, Genes.

Introduction

Post-radiotherapy (post-RT) vascular lesions of the breast include a wide spectrum of entities that can be classified into 3 types, namely: *Benign lymph-angiomatic papule of the skin (BLAP)*, *Atypical vascular Lesions (AVL)* and *post-RT angiosarcomas (Post-RT AS)*.

BLAP manifest as pink, often vesicular, occasionally multiple papules of the skin, in the field of the previous radiotherapy. Histologically, they are characterized by dilated empty vessels lined by endothelial cells devoid of any atypia (Fig. 1A) (1). Endothelial cells show a lymphatic phenotype being positive for D2-40 and in 50% of cases for CD 31 (2), while CD 34 is only occasionally and faintly positive (3, 4). These lesions present a favorable prognosis (3).

AVL (3) appear as red to brown papules or small plaques of the skin. Histology is characterized by elongated capillary-like vessels containing erythrocytes. The lesions are neatly circumscribed. These same vessels are lined by endothelial cells showing on hyperchromatic, irregular nuclei very similar to those observed in cutaneous AS (Fig. 1B) (5). The vessels are lined by cells with a blood vascular phenotype being CD 31 and CD 34 positive and D2-40 negative (3). AVL have been rarely described to recur or transform into angiosarcomas (3). AVL like areas are seen at the periphery of AS (6,7).

Post-RT AS arise in patients who received radiotherapy (8) after surgical treatment for breast carcinoma (9). Post-RT AS show a variable histological appearance, ranging from anastomosed vessels lined by atypical endothelial cells to solid anaplastic lesions (1). Donnell and Rosen proposed a grading system based on histological features, having a prognostic impact both in primary and post-RT AS (10,11). Nevertheless, the same prognostic impact was not confirmed by Nascimento et al. (12) in a series of 49 primary breast AS.

To date, no molecular data are available on BLAP and AVL.

The aims of the present study are to better elucidate the spectrum of breast post-RT lesions, including BLAP, AVL, and post-RT AS, by studying the molecular profile, the clinical behavior and comparing the results obtained with those reported in the literature. The prognostic value of Donnell & Rosen (10) grading system was tested on a multi-institutional series of post-RT AS.

Materials and methods

Tissue collection

Cases were obtained from the following Pathology Units: Unit of Pathology at Bellaria Hospital, Department of Biomedical and Neuromotor Sciences, University of Bologna, Italy; IBCSG Central Pathology Laboratory, Department of Pathology and Laboratory Medicine, European Institute of Oncology, and University of Milan (part of the cases were previously reported in reference 2, as secondary AS); Department of Pathology, Singleton Hospital, Swansea University, Abertawe Bro Morgannwg University Hospital Trust, Wales, UK; Department of Pathology, Istituto Ortopedico Rizzoli, Bologna; Department of Pathology, Candiolo Cancer Institute-FPO-IRCCS, University of Turin; Pathology Unit, Morgagni-Pierantoni Hospital, Forlì.

Cases were included in the present series when slides were available for review and follow-up information was obtained.

Haematoxylin and eosin (H&E) and unstained sections from all cases and paraffin blocks of 21 cases were available.

BLAP and AVL cases were included when biopsy was performed on skin papules appearing on RT field.

All post-RT AS were graded applying the Donnell & Rosen (10) criteria. Accordingly low-grade (G1) post-RT AS were composed of a vascular proliferation with minimal endothelial tufting, absence of papillary formation, absence of solid or spindle cell areas, absence or rarity of atypical mitoses, blood lakes and necrosis (Fig. 1C); intermediate grade (G2) post-RT AS presented endothelial tufting and focal papillary or fronds formation, solid or spindle cell areas were absent or minimal, atypical mitoses were rare and present in papillary areas, blood lakes or necrosis were absent (Fig. 1D); high-grade (G3) post-RT were characterized by prominent endothelial tufting, papillary formations, solid or spindle cell areas, mitoses were numerous and observed everywhere, even in structurally low-grade areas, and blood lake and/or necrosis were present (Fig. 1E).

All cases had received radiotherapy after surgery for breast cancer. The primary breast cancer was invasive carcinoma no special type (NST) in all but one cases of BLAP/AVL, the only exception being a case of medullary carcinoma. Primary breast cancer in post-RT AS were invasive

carcinoma NST (52 cases), lobular invasive carcinoma (7 cases), tubular carcinoma (1 case) and ductal in situ carcinoma (2 cases) with microinvasive features.

Immunohistochemistry

Sections of 4 microns from all 74 cases were stained with antibodies against CD 31 (JC 70, prediluted; Cell Marque Rocklin, CA); CD 34 (QBEND/10, prediluted; Ventana, Tucson, AZ), D2-40 (D240, prediluted; Cell Marque); Ki67 (MIB-1, 1:300; Dako, Carpinteria, CA.) and c-Myc (EP121-Y69, 1:100; Epitomics, Burlingame, CA).

Immunoreactions were performed using a standard automated immunohistochemical procedure (Ventana X, Tucson, Arizona).

Fluorescence In Situ Hybridization (FISH)

MYC translocations, copy gains and aberrations were tested with FISH. FISH studies were conducted on paraffin sections using the following probes: Vysis LSI MYC dual color break-apart. The slides were deparaffinized, co-denatured with probe, hybridized overnight, washed and then mounted with DAPI/Antifade.

Mutation Analysis

Representative blocks were obtained from 21 cases of post-RT vascular lesions (4 AVL and 17 AS). Mutational analysis was performed by deep sequencing for the following hotspot genes previously described in AS (13,14): *KRAS* (Exons 2-4), *NRAS* (Exons 2-4), *HRAS* (Exons 2-3), *BRAF* (Exon 15), *PIK3CA* (Exons 10,21), *TP53* (Exons 4-9), *NOTCH1* (Exons 26-27), *PTEN* (Exons 5-8), *CDKN2A* (Exons 1-2), *EGFR* (Exons 18-21), *AKT1* (Exon 2), *CTNNB1* (Exon 3), *hTERT* (Promoter), *PTPRB* (Exon 15, 20, 28, 29).

Methods applied are reported in the “Supporting information” section.

Statistical analysis

Clinical and pathological data were described using summary statistics, with continuous variables being expressed as mean \pm SD or median and interquartile range.

Mann-Whitney test and χ^2 -test were used to compare continuous and categorical variables between patients with post-RT AS and AVL.

Kruskal-Wallis test was used to compare continuous variables across grading groups in post-RT AS.

The overall survival (OS) and disease-free survival (DFS) curves for the overall sample were estimated using Kaplan-Meier product limit. Differences in survival between subgroups were assessed using log-rank test. The following cut-offs were used to define subgroups: age (≥ 70 years), tumor size (≥ 2 cm), latency period from radiotherapy were used (≥ 80 months), the number of mitoses ($\geq 5/10$ high power field), Ki67 labeling index (25%). The cut-off was selected using the mean value of the tested parameters.

Cox proportional-hazards regression model was used to estimate hazard ratios. Statistical analysis was performed using IBM SPSS version 25.0. The significance level was set to $p < 0.05$.

Ethics statement: The study was approved by the local Ethics Committee (Bologna-Imola CE-BI, study number: Cod. CE: 16010). Sensitive data were anonymized.

RESULTS

Clinico-pathological data and immunohistochemical profile (Table 1)

The study sample includes 74 cases, classified as follows: BLAP: N=4, mean age 63.8 years, (range 48-79); AVL: N=8, mean age 66.5 years, (range 57-85); post RT AS: N=62, mean age 64.7 years (range 25-94).

All tumors were located in the site of previous radiotherapy (31 left, 43 right side). No bilateral or multifocal cases were observed.

As BLAP and AVL clinical features were similar (see supplementary material table 1s) they were merged for subsequent analyses.

Differences between BLAP/AVL and post-RT AS groups were evident. Specifically, post-RT AS size was larger (median 2.6 cm, Interquartile range 1.5-5.0) than BLAP\AVL (median 1 cm, Interquartile range 0.7-1.3) (Mann-Whitney test=427; $p=0.007$). A longer interval from RT to the development of the lesion was found for AS compared with AVL (median 90 months vs. 65 months, Mann-Whitney test=342; $p=0.041$). Besides, AS differed from AVL in the number of mitoses (median 7 mitoses/ 10 high power field in AS vs. 0 mitoses in AVL, $p<0.001$).

Grading of post-RT AS: 13 cases were G1, 17 cases were G2 and 32 cases were G3. Clinical and pathological data of post-RT AS according to the grade are summarized in table 2. Differences were noted in the number of mitoses and the presence of necrosis.

Immunohistochemistry: Table 3 summarizes the immunohistochemical results.

All 4 BLAP cases were positive for D2-40 (Fig. 2A). The 8 cases of AVL showed a prevalent CD31 positivity (Fig. 2B) with D2-40 co-expression in one case. C-Myc was negative in all but one AVL. This latter case was investigated by FISH, however no translocations or copy number aberration of *C-Myc* gene were detected.

All but 3 of the 62 cases of post-RT AS showed strong CD31 and CD34 expression (Fig. 2C). Post-RT AS presented D2-40 expression in 9 cases. *C-Myc* was positive in 10 out of the 17 cases (Fig. 2D). The majority (87.5%) of post-RT AS G1 and of G2 (83.3%) showed Ki67 $\leq 25\%$, while 53.3% of cases of post-RT AS G3 had Ki67 $>25\%$. The mean Ki67 proliferative index was 28% in AS versus 5% in AVL, $p<0.001$.

Mutational profile

Adequate gene library for NGS was obtained from 4 AVL and 17 post-RT AS tested. A mean coverage depth of 2235 reads was achieved. The mutational pattern is summarized in Table 4.

Two AVL cases showed a mutation in *hTERT* promoter. One case AVL showed *HRAS* p.G12V, while the fourth case of AVL showed no mutations in the tested genes.

The mutational pattern in post-RT AS was evaluated in 8 cases of G1, 3 cases of G2 and 6 cases of G3.

Post-RT AS G1 showed *PTEN*, *hTERT*, *NOTCH1* and *TP53* mutations in 3/4 cases. Post-RT AS G2 cases did not show missense mutations except for *hTERT* in one case. Post-RT AS G3 cases showed missense mutations as follows: *KRAS* (1/6), *NRAS* (2/6), *HRAS* (1/6), *EGFR* (3/6), *TP53* (4/6), *CDKN2A* (1/6), *CTNNB1* (2/6), *PTEN* (2/6), *PIK3CA* (1/6), *hTERT* (3/4). Two cases showed no missense mutations. (Fig. 3 A and B).

Survival analyses

No recurrences were observed among cases of BLAP and AVL, after a follow-up interval of 3-132 months (mean=46 months, median=42 months). Therefore, survival analysis was conducted only on the 62 post-RT AS with complete data on grading and outcome (follow-up interval 4-164 months, mean=50.3 months, median=33 months).

Overall survival

One, three and five-year OS in post-RT AS was 94.8%, 69.5%, 59.5% respectively. Five-year OS declined with increasing grade. It was 85.7% in G1 AS, 83.3% in G2 AS and 40.4% in G3 AS. Survival was significantly longer for grade 1-2 vs. grade 3 (log-rank test=8.08, p=0.0045) (Fig. 4A). A hazard ratio of 4.95 (95% CI 1.441-17.014) for grade 3 *versus* grade 1-2 was obtained in a Cox regression analysis.

No difference in 5-years OS was found between patients with $Ki67 \leq 25\%$ and those with $Ki67 > 25\%$ (log-rank test=1.45, p=0.229), between age groups, size groups, interval from RT, number of mitoses.

Disease-free survival

One, three and five-year DFS in post-RT AS was 91.7%, 64.2%, 53.2%. Similarly to OS, 5-years DFS declined with increasing grade. It was 85.7% in G1 AS, 77.8% in G2 AS and 33.3% in G3 AS. A longer DFS was found for grade 1-2 vs. 3 (log-rank test=9.51, p=0.002 (Fig. 4B). The hazard ratio for grade 3 was significantly higher compared to grade 1-2 (HR=4.599, 95% CI 1.571- 13.471).

No difference in 5-years DFS was found between patients with $Ki67 \leq 25\%$ and those with $Ki67 > 25\%$, between age groups, size groups, RT interval, however patients with more than 5 mitoses had a significantly higher risk of recurrence (HR=2.907, 95% CI 1.085-7.790).

Discussion

The present study focused on a wide spectrum of vascular lesions affecting the breast after RT. The results suggest a possible molecular relation between benign and malignant mammary post-RT vascular lesions and highlight the prognostic impact of grading in post-RT AS. Differences in grading are additionally supported by a different mutational profile, showing a high mutations burden in high-grade RT-AS.

Genes known to be mutated in AS (13,14) were studied in AVL. One case revealed *HRAS* p.G12V, two cases showed two different mutations in *hTERT* each. The benign mammary post-RT vascular lesions here studied (11) showed no recurrence or transformation into AS, after a median of 42 months of follow up. Nevertheless, 5 cases of benign vascular lesions (4 AVL and 1 BLAP) have been reported to progress to AS (3, 2). The identification of mutated genes in common between AVL and post-RT AS (*hTERT*), but with low mutational burden, suggest that AVL can be non-obligate precursors of AS. This data can explain why, on rare occasions, they can transform to AS.

Moreover, the prognostic value of Donnell-Rosen's grading for AS and its relationship with our molecular data was studied. Prognostic value of histological grading is rarely considered. Depla et al (15) made a comprehensive review of the literature on breast AS. Unfortunately, histological grading was reported on limited number of cases, using different grading criteria, therefore grading prognostic value could not be evaluated.

In the present series, Donnell-Rosen's grading (10) was useful to prognostically stratify post-RT ASs. Accordingly, five-year OS and DFS declined with the increasing grade in post-RT AS patients. Specifically, the hazard ratio for grade 3 was significantly higher compared to grade 1-2 (HR=4.3, 95% CI 1.5-12). Our results are consistent with those of Donnell et al. (10). However, our findings differ from those of Nascimento et al. (12) who found no statistically significant differences among different post-RT AS grades.

A possible explanation of the inconsistency among studies might be the adoption of different inclusion/exclusion criteria, the incomplete information about grade and the small number of

studied cases. On the other side, the follow-up impact of the Donnell et al (10) grading system here observed, is supported by the results obtained by molecular analyses.

The genes here analyzed in 17 cases of post-RT AS showed a similar mutational profile for grade 1 and 2 in post-RT AS consisting with absence or the low number of mutations. On the contrary, post-RT AS grade 3 exhibited a different mutational profile, with a high mutations burden in *TP53*, *EGFR*, *KRAS*, *HRAS*, *NRAS*, and *hTERT* genes, as previously reported (14).

While low grade post-RT AS showed the most favorable prognosis, post-RT AS G3, according to Donnell-Rosen's grading, showed a more complex mutational profile and, accordingly, the worst prognosis. These data suggest that a dichotomous grading of post-RT AS (low versus high grade) should be more practical and useful to predict prognosis.

Furthermore, the different genomic condition related to grading may be associated to overall and disease-free survival. Since the genetic alterations are likely to be heterogeneous (see Table 4), such analysis would require a larger sample dataset with clinical follow-up, to confirm the poorer prognosis associated with grade 3 AS cases.

The *C-MYC* mutation associated with MAPK pathway genetic alteration (as reported in Murali's series (14)) represents possible therapeutic target.

In summary, this is the first report on molecular data of BLAP/AVL showing that AVL shares genetic mutations with AS. The shared mutations between AVL and post-RT AS in *hTERT* suggest a possible relation with post-RT AS, to be corroborated in further studies with a larger sample size and a longer FU.

Donnell and Rosen's grading system applied to post- RT AS had a prognostic value in our post-RT AS patients. This grading system could identify a subgroup of aggressive neoplasm with peculiar molecular signaling that involves the MAPK pathway and that should be useful in the therapeutic targeting of this aggressive neoplasm.

Disclosure/Conflict of Interest

All Authors declare the absence of any conflict of interest

Funding

This work was supported by the Fundamentally Oriented Research (RFO) 2015, University of Bologna, Italy to S.A.

Acknowledgement: Prof. V. Eusebi is thanked for critically revising the manuscript.

Table 1. Clinic-pathological features of post-RT AS and BLAP/AVL.

	Post-RT AS (n=62)	BLAP/AVL (n=12)	<i>p-value</i>
Age (Years)			
Mean± SD	64.7 ± 14.4	65.6 ± 9.6	0.665
Tumor size (cm)			
Median (IQR)	2.6 (1.5-5.0)	1 (0.7-1.3)	0.007
Interval from RT (months)			
Median (IQR)	90 (90-96)	65 (56-108)	0.041
N. Mitoses/ 10 high power field			
Median (IQR)	7 (2-11)	0 (0-0)	<0.001
Ki67			
0-10%	25.7%	100%	<0.001
>10-25%	42.9%	0%	
>25%	31.4%	0%	

Legend: SD (standard deviation), IQR (interquartile range), post-RT AS (post-radiotherapy angiosarcoma), BLAP/AVL (Benign lymphangiomatous papules of the skin/atypical vascular lesions).

Table 2: Clinic-pathological features of post-RT AS according to grade.

	G1 post-RT AS (N=13)	G2 post-RT AS (N=17)	G3 post-RT AS (N=32)
Age			
Mean ± SD	65.7±10.9	61.9±15.7	65.7±15.2
(range)	(41-80)	(33-80)	(25-94)
Size (cm)			
Mean	2.92	2.53	4.51
Median	2.5	2.2	3.0
(range)	(0.4-8)	(0.4-6)	(0.4-12)
Time interval (months)			
Mean	86.91	115.92	102.28
Median	90	90	90
(range)	(12-130)	(42-324)	(60-264)
Mitoses			
Mean	<1/10 HPF	5.13/10 HPF	14.09/10 HPF
Median	1/10 HPF	4.5/10 HPF	11/10 HPF
(range)	(0-3/10 HPF)	(1-15/10 HPF)	(2-63/10 HPF)

Necrosis	0/13	1/17	14/32
-----------------	------	------	-------

Legend: SD (standard deviation), post-RT AS (post-radiotherapy angiosarcoma), G1 (grade 1), G2 (grade 2), G3 (grade 3).

Table 3: Immunohistochemical parameters in post-RT vascular lesions of the breast

Immunohistochemical Markers	BLAP (N=4)	AVL (N=8)	post-RT AS (N=62)
C-Myc	0/4	1/3 (33.3%)	10/17 (58.8%)
D2-40	4/4 (100%)	1/8 (12.5%)	9/62 (14.5%)
CD31	1/4 (25%)	8/8 (100%)	62/62 (100%)
CD34	0/4 (0%)	8/8 (100%)	60/62 (96.7%)

Legend: N: number; post-RT AS (post-radiotherapy angiosarcoma), BLAP/AVL (Benign lymphangiomatous papules of the skin/atypical vascular lesions)

Table 4: Mutational analysis of 4 AVL and 17 post-RT AS.

<i>Gene</i>	Number of mutated cases and type of mutation			
	AVL	AS G1	AS G2	AS G3
KRAS	0/4	0/8	0/3	1/6 p.A146T(VAF:15%; Pph: 1, damaging)
NRAS	0/4	0/8	0/3	2/6 p.Q61R(VAF:43%; Pph:0.085, benign) p.A146S(VAF:4%; Pph: 0.991, damaging)
HRAS	p.G12V(VAF:16%; Pph: 0.738, damaging) 1/4	1/8 p.H27H(VAF:50%)	0/3	1/6 p.M1I(VAF:33%; Pph: 0.883, damaging)
BRAF	0/4	0/8	0/3	0/6
EGFR	0/4	0/8	1/3 p.C781C(VAF:11%)	3/6 p.D770N(VAF:25%; Pph:0.143, benign) p.P848S(VAF:35%; Pph: 1, damaging) p.R831L(VAF:16%; Pph: 0.921, damaging)
TP53	0/4	1/8 p.V272L(VAF:50%; Pph:0.998 damaging)	0/3	4/6 p.G279E(VAF:60%; Pph:1 damaging) P.E271K(VAF:23%; Pph:1 damaging)

				p.K305F(VAF:24%; Pph:1 damaging) P.H179G(VAF:11%; Pph:0.997, damaging)
CDKN2A	0/4	0/8	0/3	1/6 P.P105L(VAF:99%; Pph:0.012 benign)
AKT1	0/4	0/8	0/3	1/6 P.G33G(25%)SILENT
CTNNB1	0/4	0/8	0/3	2/6 P.G38S(VAF:36%; Pph:0.917, damaging) p.Q27*(VAF:56%; Pph:1, damaging)
PTEN	0/4	1/8 P.V249M(VAF:6%; Pph:0.968 damaging)	0/3	1/6 p.E114K(VAF:22%; Pph:0.005 benign) +in cis p.S113N (VAF:22%; Pph:0.979 damaging)
NOTCH1	1/4 p.D1698D(9%)SILENT	2/8 p.S1690L(VAF:20%;Pph:0.05,b enign) p.D1698D(50%)SILENT	1/3 p.E1679E(22%)SILENT	4/6 p.D1698D(79%)SILENT p.D1698D(9%)SILENT p.D1698D(67%)SILENT p.D1698D(52%)SILENT
PIK3CA	0/4	0/8	0/3	1/6 P.A1046V(VAF:21%; Pph:1 damaging)

TERT	2/4 minus104T>C(30%) and minus1	2/8 minus14 minus153C>G(40%)	0/3	3/6 minus12 minus15 minus14
PTPRB	0/4	0/8	0/3	1/6 P.K1062K(71%)SILENT

Legend: WT: wild type; Variant Allele Frequency (VAF) is reported in brackets and the score calculated by Polyphen-2 (Pph:X) is reported in bracket.

Figure legends:

Fig. 1A: *BLAP*. Dilated empty vessels lined by endothelial cells devoid of any atypia.

Fig. 1B: *AVL*. Capillary-like vessels containing red blood cells

Fig. 1C: *Post-RT AS grade 1*. Anastomosed vessels lined by atypical endothelial cells.

Fig. 1D : *Post-RT AS grade 2*. Endothelial tufting is present and focal papillary or fronds formation is seen. Solid or spindle cell areas were absent or minimal, atypical mitoses were rare and present in papillary areas, blood lakes or necrosis were absent

Fig. 1E: *Post-RT AS grade3*. Solid lesion composed of atypical endothelial cells.

Fig. 2A: D240 expression in *BLAP*. Endothelial cells show lymphatic phenotype.

Fig. 2B: CD31 expression in post-RT AS.

Fig. 2C: C-MYC expression in *AVL*. Nuclear positivity.

Fig. 2D: C-MYC expression in post-RT AS. Nuclear positivity.

Fig. 3A: Mutations visualized using IGV in *TP53* p.G279E (VAF 60%).

Fig. 3B: Mutations visualized using IGV in *NRAS* p.Q61R(VAF: 43%).

Fig. 4A: Kaplan-Meier estimate of overall survival by grade in post-RT AS (log-rank test=8.08, p=0.0045).

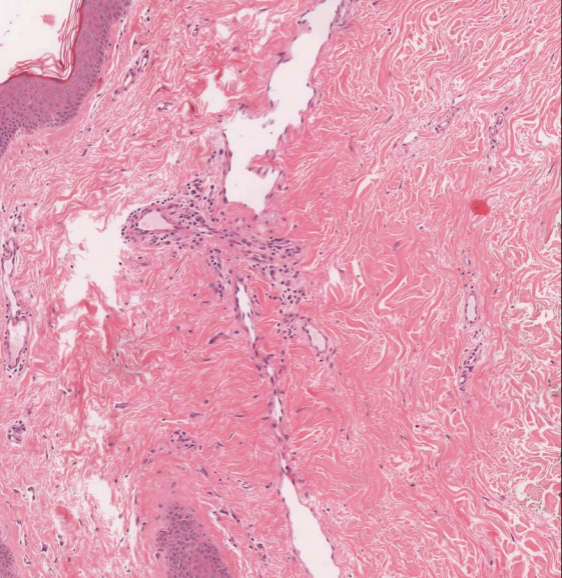
Fig. 4B: Kaplan-Meier estimate of disease-free survival by grade in post-RT AS (log-rank test=9.51, p=0.0020).

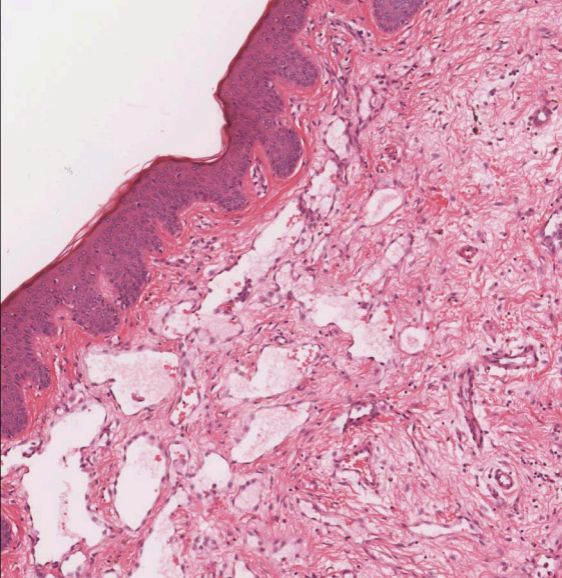
Reference

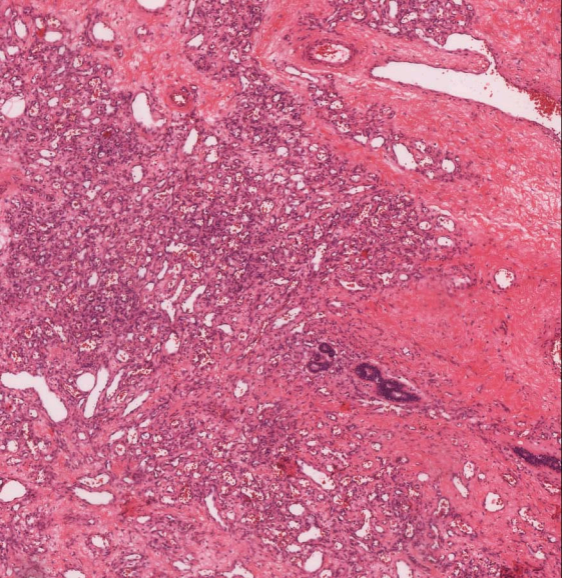
- 1) Tavassoli A. Eusebi V. Tumors of the mammary gland. AFIP atlas of tumor pathology, series 4.

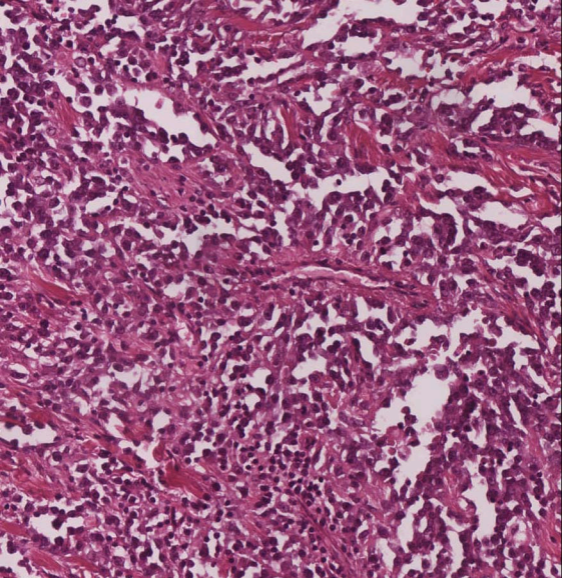
- 2) Fraga-Guedes C, André S, Mastropasqua MG, Botteri E, Toesca A, Rocha RM, Peradze N, Rotmensz N, Viale G, Veronesi P, Gobbi H. Angiosarcoma and atypical vascular lesions of the breast: diagnostic and prognostic role of MYC gene amplification and protein expression. *Breast Cancer Res Treat.* 2015 May;151(1):131-40.
- 3) Patton KT, Deyrup AT, Weiss SW. Atypical vascular lesions after surgery and radiation of the breast: a clinicopathologic study of 32 cases analyzing histologic heterogeneity and association with angiosarcoma. *Am J Surg Pathol.* 2008 Jun;32(6):943-50.
- 4) Fineberg S, Rosen PP. Cutaneous angiosarcoma and atypical vascular lesions of the skin and breast after radiation therapy for breast carcinoma. *Am J Clin Pathol.* 1994 Dec;102(6):757-63.
- 5) Brenn T, Fletcher CD. Radiation-associated cutaneous atypical vascular lesions and angiosarcoma: clinicopathologic analysis of 42 cases. *Am J Surg Pathol.* 2005;29(8):983–996.
- 6) Ginter PS, Mosquera JM, MacDonald TY, D'Alfonso TM, Rubin MA, Shin SJ. Diagnostic utility of MYC amplification and anti-MYC immunohistochemistry in atypical vascular lesions, primary or radiation-induced mammary angiosarcomas, and primary angiosarcomas of other sites. *Hum Pathol.* 2014 Apr;45(4):709-16.
- 7) Ginter PS, McIntire PJ, Shin SJ. Vascular tumours of the breast: a comprehensive review with focus on diagnostic challenges encountered in the core biopsy setting. *Pathology.* 2017 Feb;49(2):197-214.
- 8) Strobbe LJA, Peterse HL et al. Angiosarcoma of the breast after conservation therapy for invasive cancer, the incidence and outcome: an unforeseen sequela. *Breast cancer Res treat* 1998;47:101-9
- 9) Fletcher C.D.M. Bridge J. Vascular tumors. In WHO classification of tumors of soft tissue and bone. 4th edition, 2013
- 10) Donnell RM, Rosen PP, Lieberman PH, et al. Angiosarcoma and other vascular tumors of the breast. *Am J Surg Pathol* 1981;5:629-642.

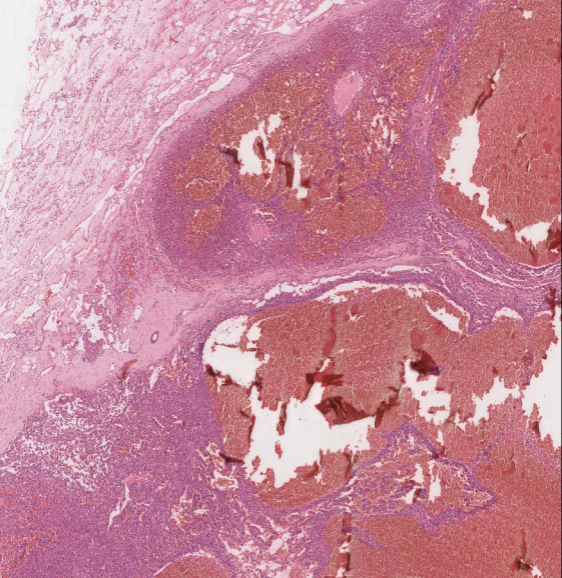
- 11) Rosen PP, Kimmel M, Mammary angiosarcoma. The prognostic significance of tumor differentiation. *Cancer* 1988;62:2145-2151
- 12) Nascimento AF, Raut CP, Fletcher CD. Primary angiosarcoma of the breast: clinicopathologic analysis of 49 cases, suggesting that grade is not prognostic. *Am J Surg Pathol.* 2008 Dec;32(12): :1896-904.
- 13) Hung J, Hiniker SM. Sporadic versus Radiation-Associated Angiosarcoma: A Comparative Clinicopathologic and Molecular Analysis of 48 Cases. *Sarcoma.* 2013;2013:798403
- 14) Murali R, Chandramohan R. Targeted massively parallel sequencing of angiosarcomas reveals frequent activation of the mitogen activated protein kinase pathway. *Oncotarget.* 2015 Nov 3;6(34): 36041-52
- 15) Depla AL, Scharloo-Karels CH. Treatment and prognostic factors of radiation-associated angiosarcoma (RAAS) after primary breast cancer: a systematic review. *Eur J Cancer.* 2014 Jul;50(10):1779-88
- 16) Morandi L, Righi A, Maletta F, Rucci P, Pagni F, Gallo M, Rossi S, Caporali L, Sapino A, Lloyd RV, Asioli S. Somatic mutation profiling of hobnail variant of papillary thyroid carcinoma. *Endocr Relat Cancer.* 2017 Feb;24(2):107-117.
- 17) Gabusi A, Gissi DB, Tarsitano A, Asioli S, Marchetti C, Montebugnoli L, Foschini MP, Morandi L. Intratumoral Heterogeneity in Recurrent Metastatic Squamous Cell Carcinoma of the Oral Cavity: New Perspectives Afforded by Multiregion DNA Sequencing and mtDNA Analysis. *J Oral Maxillofac Surg.* 2019 Feb;77(2):440-455
- 18) Adzhubei IA, Schmidt S, Peshkin L, Ramensky VE, Gerasimova A, Bork P, Kondrashov AS, Sunyaev SR. A method and server for predicting damaging missense mutations *Nat Methods* 7(4):248-249 (2010)
- 19) Diaz-Cascajo C, Borghi S. et al. Benign lymphangiomatous papules of the skin following radiotherapy: a report of five new cases and review of the literature. *Histopathology.* 1999; 35:319-327

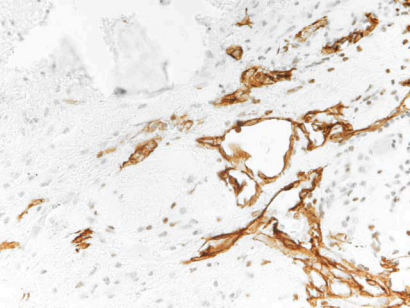


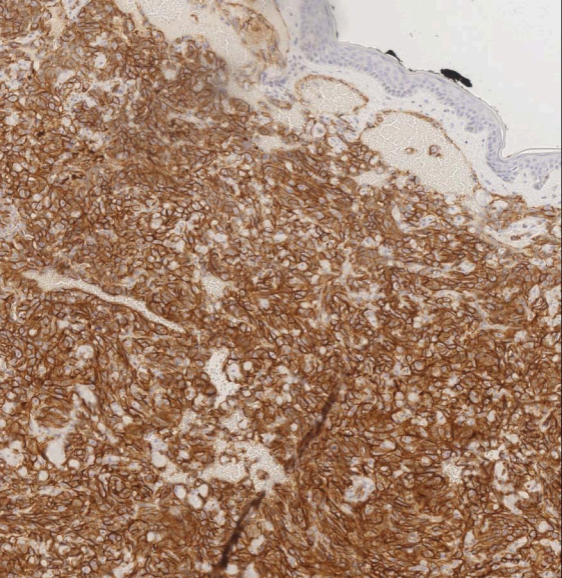


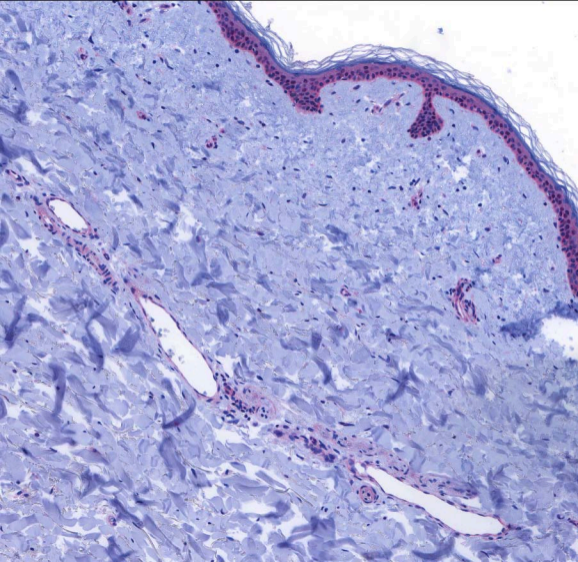


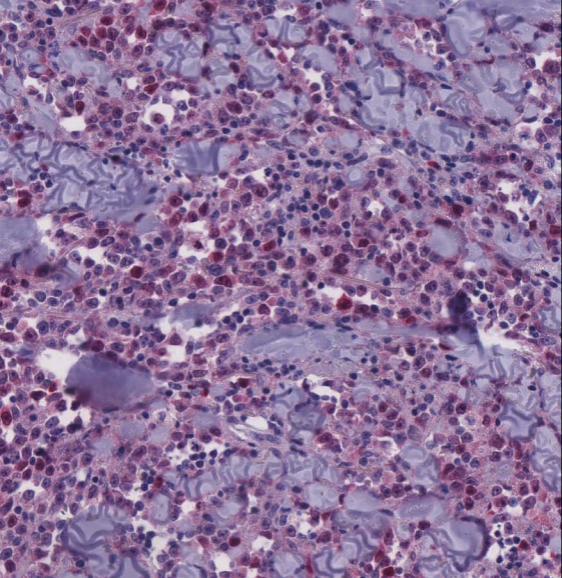











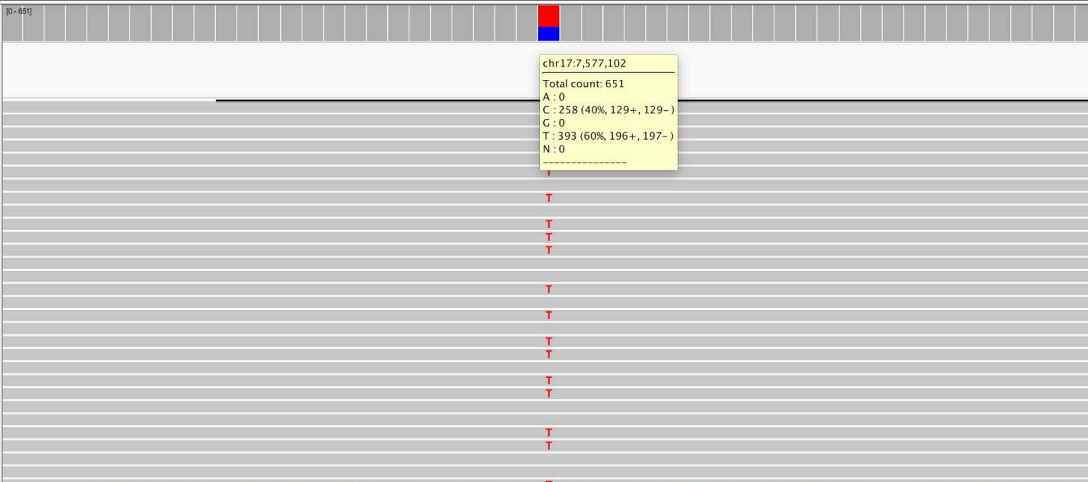




AN4_S1.bam Coverage

AN4_S1.bam Junctions

AN4_S1.bam

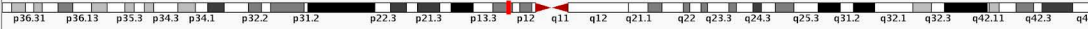

Sequence

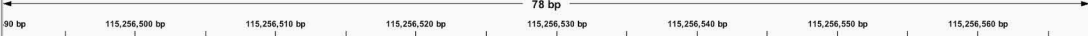RefSeq Genes

C T C T T C C T C T G T G C G C C G G T C T C T C C C A G G A C A G G C A C A A A C A C G C A C C T C
 E E E T R R D R G P C A C V R V E

TP53



NAME
DATA TYPE
DATA FILE




AN4_S1.bam Coverage



AN4_S1.bam Junctions



AN4_S1.bam



Sequence

T C C T C A T G T A T T G G T C T C T C A T G G C A C T G T A C T C T T C T T G T C C A G C T G T A T C C A G T A T G T C C A A C A A A C A G G T T T C A C

RefSeq Genes

R M Y Q D R M A S Y E E Q G A T D L I D L L C T E C

NRAS

