



ARCHIVIO ISTITUZIONALE DELLA RICERCA

Alma Mater Studiorum Università di Bologna Archivio istituzionale della ricerca

Tinea capitis in children: a systematic review of management.

This is the final peer-reviewed author's accepted manuscript (postprint) of the following publication:

Published Version:

Tinea capitis in children: a systematic review of management / Gupta AK, Mays RR, Versteeg SG, Piraccini BM, Shear NH, Piguat V, Tosti A, Friedlander SF.. - In: JOURNAL OF THE EUROPEAN ACADEMY OF DERMATOLOGY AND VENEREOLOGY. - ISSN 0926-9959. - STAMPA. - 32:(2018), pp. 2264-2274. [10.1111/jdv.15088]

This version is available at: <https://hdl.handle.net/11585/716125> since: 2020-02-19

Published:

DOI: <http://doi.org/10.1111/jdv.15088>

Terms of use:

Some rights reserved. The terms and conditions for the reuse of this version of the manuscript are specified in the publishing policy. For all terms of use and more information see the publisher's website.

(Article begins on next page)

This item was downloaded from IRIS Università di Bologna (<https://cris.unibo.it/>).
When citing, please refer to the published version.

This is the final peer-reviewed accepted manuscript of:

Gupta AK, Mays RR, Versteeg SG, Piraccini BM, Shear NH, Piguet V, Tosti A,
Friedlander SF. Tinea capitis in children: a systematic review of management.

J Eur Acad Dermatol Venereol. 2018 Dec;32(12):2264-2274

The final published version is available online at: <https://doi.org/10.1111/jdv.15088>

Rights / License:

The terms and conditions for the reuse of this version of the manuscript are specified in the publishing policy. For all terms of use and more information see the publisher's website.

This item was downloaded from IRIS Università di Bologna (<https://cris.unibo.it/>)

When citing, please refer to the published version.

Tinea capitis in children: a systematic review of management

A.K. Gupta^{1,2} R.R. Mays¹ S.G. Versteeg¹ B.M. Piraccini³ N.H. Shear^{5,6} V. Piguet^{4,5,6} A. Tosti⁷
S.F. Friedlander⁸

1. Mediprobe Research Inc, London Canada
2. Department of Medicine, University of Toronto School of Medicine, Toronto, Canada
3. Department of Experimental, Diagnostic and Specialty Medicine, University of Bologna, Italy
4. Division of Infection & Immunity, Cardiff University School of Medicine, Cardiff.
5. Division of Dermatology Women's College Hospital Toronto Canada.
6. Division of Dermatology, Dept of Medicine, University Toronto Canada
7. Fredric Brandt Endowed Professor of Dermatology, University of Miami, USA
8. University of California San Diego School of Medicine USA

ABSTRACT

Background

Tinea capitis is the most common cutaneous fungal infection in children.

Objectives

This review aims to evaluate the differences that exist between medications for the treatment of tinea capitis, to determine whether there are any significant adverse effects associated and to define the usefulness of sample collection methods.

Methods

We conducted a systematic literature search of available papers using the databases PubMed, OVID, Cochrane Libraries and ClinicalTrials.gov. 21 RCTs and 17 CTs were found.

Results

Among the different antifungal therapies (oral and combination thereof), continuous itraconazole and terbinafine had the highest mycological cure rates (79% and 81%, respectively), griseofulvin and terbinafine had the highest clinical cure rates (46% and 58%, respectively) and griseofulvin and terbinafine had the highest complete cure rate (72% and 92%, respectively). Griseofulvin more effectively treated *Microsporum* infections; terbinafine and itraconazole more effectively cured *Trichophyton* infections. Only 1.0% of children had to discontinue medication based on adverse events. *T. tonsurans* was the most common organism found in North America, and hairbrush collection method is the most efficient method of sample collection. Additionally, using a hairbrush, toothbrush or cotton swab to identify the infecting organism(s) is the least invasive and most efficient method of tinea capitis sample collection in children.

Conclusions

Current dosing regimens of reported drugs are effective and safe for use in tinea capitis in children.

INTRODUCTION

Tinea capitis is a superficial cutaneous fungal infection or dermatophytosis of the scalp also referred to as ringworm. The infection originates from a variety of sources including humans, animals and soil. It remains the most common cutaneous fungal infection in children, most prevalent between 3 and 7 years of age.¹ The diagnosis of tinea capitis is made by a focused history, physical examination, trichoscopy and microscopy test. Methods of sample collection for microscopy diagnosis vary among location and investigator. The epidemiological distribution of tinea capitis has diverse geographical and seasonal variations depending on several factors, including lifestyle, population, migration of people and climatic conditions. This review aims to evaluate the differences between medications for the treatment of tinea capitis, to determine whether there are any significant adverse effects associated with this treatment and to determine the usefulness of the different diagnosing methods.

METHODS

Search strategy and selection criteria

A systematic review examined randomized controlled trials (RCTs) and clinical trials of tinea capitis in children. No date ranges were set. Potentially relevant studies were identified through a literature search for articles published as of 1 June 2017, using multiple research databases (PubMed, Ovid, Scopus, Cochrane libraries and ClinicalTrials.gov). The search identified any citations containing 'tinea capitis' or 'ringworm of the scalp' and 'children, child or children, childhood or paediatric or young'. Additional limits included removing duplicates, and searches were limited to English only articles, humans and children aged 18 years or younger. References within retrieved articles were also searched to identify additional articles that may have been missed in the primary database search.

Study eligibility

Studies were selected for analysis if the following criteria were met: (a) clinical trial (CT) or RCT (b) participants were 18 years of age or younger; (c) tinea capitis was clinically (as defined by investigators) and mycologically (as defined by mycological testing) diagnosed and (d) reported efficacy rates (e.g. mycological cure, clinical cure, complete cure) and/or safety measures. Papers which met explicit inclusion criteria were included for full-text review.

Evaluation of efficacy

Primary measures were efficacy rates examined across eligible studies and included mycological cure, clinical cure and complete cure. Mycological cure was defined as negative mycological testing (e.g. negative culture, negative potassium hydroxide (KOH), periodic acid–Schiff stain (PAS)). Clinical cure was defined as the absence of signs and symptoms of tinea capitis (could be Total Signs and Symptoms (TSSS) score of 0 or a clinical parameter score of 0). Complete cure was defined as both mycological and

clinical cure. The TSSS is a scale that rates the severity of 5 different signs and symptoms (erythema, desquamation/scaling, papules, pustules and pruritus) on a 4-point scale (0, absent; 1, mild; 2, moderate; 3, severe). These were summed to obtain a TSSS, with a maximum value of 15 points.² Secondary measures were qualitative evaluation of frequency and severity of reported adverse events and were obtained for each antifungal drug across all included studies. Study characteristics such as the year, location, method of collecting samples for investigation and infecting organisms were also reported and analysed.

RESULTS

Study characteristics

Our search yielded 4190 studies (Figure 1). The most common organisms found in each continent were *T. violaceum* in Africa,³⁻⁵ *M. canis* in Asia,⁶⁻¹⁰ *M. canis* in Europe,¹¹⁻²² *T. tonsurans* in North America^{5, 23-37} and *M. canis* in South America^{5, 38, 39} (Fig. 2). The most common hair sample collection method was the Wood's light examination/light microscopic examination (9/18)^{3, 4, 10, 15, 17, 18, 22, 33, 36} (Table 1). Across all studies, five oral antifungals (terbinafine, griseofulvin, itraconazole, ketoconazole and fluconazole) were examined in 3998 children.^{4-10, 13-18, 20, 21, 24, 25, 27-29, 32-40} A few included studies also evaluated the efficacy and safety of combinations of oral and topical therapies across a total of 833 treated children^{11, 12, 18, 19, 22, 23, 26, 30, 31} and 25 children used only topical therapies.³

Efficacy rates

Terbinafine was evaluated in twelve included studies using weighted averages^{4, 7-10, 15, 16, 20, 24, 37-39} with a pooled total of 1592 children (Table 2). Using the predefined definition of mycological cure (negative mycological testing) and after one or 2 weeks of treatment, terbinafine had a weighted average of 53.8% (57/106) children mycologically cured. Mycological cure after 4 weeks of treatment was 81.4% (48/59) and after six to 8 weeks of treatment 50.9% (535/1052). Clinical cure was 58.1% (50/86) and was evaluated in one study after one to 2 weeks of treatment. After one or 2 weeks of treatment, the average was 54.8% (57/104), and after 4 weeks of treatment, the average measured at week 6 was 91.7% (22/24), at week 8 was 69.4% (25/36) and then week 12 post-treatment was 60.9% (42/69).

Twelve studies examined the effects of griseofulvin.^{6, 7, 9, 13-15, 24, 25, 28, 29, 38, 40} The mycological cure after 6 weeks of treatment was a weighted average of 51.5% (421/818) and after 8 weeks of treatment was 67.2% (43/64). The clinical cure after 6 weeks of treatment was a weighted average of 46.6% (373/801). Complete cure had a weighted average after 6 weeks of treatment of 32.8% (263/801) and after 8 weeks the average increased to 71.8% (46/64).

Itraconazole continuous therapy was found in two studies,^{17, 35} and the weighted average of the mycological cure at 12 weeks of the capsules is 79.0% (83/105). Ketoconazole was found in four

studies,^{14, 25, 28, 29} and the weighted average of the mycological cure measured at 12 weeks was 15.1% (11/73).

Terbinafine for 4 weeks was combined with either selenium sulphide shampoo¹¹ or 1% terbinafine cream²² for a mycological cure weighted average of 46.8% (61/126). Griseofulvin plus ciclopirox or selenium sulphide shampoo had a mycological cure weighted average of 32.7% (32/98). Itraconazole capsules plus selenium sulphide shampoo had a mycological cure weighted average of 79.1% (53/67).

Efficacy rates per species

Nine RCTs (9/21)^{3, 4, 7, 11, 15, 24, 26, 28, 39} and nine CTs (9/17)^{5, 16, 18-22, 30, 35} reported cure rates that met our inclusion criteria. The fungi genus *Microsporum* (*canis* and *audouinii*), an exophytic invasion, was identified in combination therapy,^{11, 18, 19, 22} griseofulvin,^{15, 24, 38} fluconazole,⁵ itraconazole,³⁵ terbinafine,^{8, 15, 20, 24, 38, 39} squalamine³ and ketoconazole.²⁸ The fungi genus *Trichophyton* (*tonsurans*, *violaceum*, *mentagrophytes*, *rubrum*, *schoelini* and *verrucosum*), an endophytic invasion, was identified in combination therapy,^{11, 18, 26, 30} griseofulvin,^{15, 24, 28, 38} fluconazole,⁵ itraconazole,³³ terbinafine^{8, 15, 16, 24, 38, 39} and ketoconazole.²⁸ One RCT reported the species *Penicillium* and *Scopulariopsis* for the treatment with ketoconazole with only two participants and 100% mycological cure rate.²⁸ One topical treatment squalamine was tested in the *Microsporum* species with none of the five participants cured.³

Griseofulvin more effectively treated *Microsporum* than *Trichophyton* infections (mycological cure rate 60% and 54%, complete cure rate 49% and 40%, respectively) (Table 3). This is further improved with the combination of selenium shampoo to oral griseofulvin (mycological cure 61% and 31%, respectively). Fluconazole was equally effective in treating both *Microsporum* and *Trichophyton* infections (mycological cure 94% and 100%, respectively). Lastly, *Trichophyton* infections were more effectively cured than *Microsporum* with continuous itraconazole (mycological cure 91% and 74%, respectively) and terbinafine (mycological cure 66% and 46%, complete cure 50% and 27%, clinical cure 69% and 40%, respectively).

Adverse events reported

A total of 295 adverse effects (AEs) from terbinafine 51.2% (151/295), griseofulvin 26.8% (79/295), fluconazole 12.2% (36/295), itraconazole 8.5% (25/295) and ketoconazole 1.4% (4/295) related to drug use were reported (Table 3). No adverse events were considered life-threatening, and all were mild to moderate in severity and transient. Therefore, a total 318 children experienced some level of AEs related to drug use, at a frequency of 6.5% (318/4856). A total of 50 children ceased treatment 1.0% (50/4856) due to drug effects (Tables 4 and 5).

DISCUSSION

Among the 75 different combinations of antifungal therapies identified in our literature search, continuous itraconazole and terbinafine had the highest mycological cure rates; griseofulvin and

terbinafine had the highest clinical cure rates; and griseofulvin and terbinafine had the highest complete cure rate. Adverse events were transient and limited to mild to moderate in severity. Griseofulvin more effectively treated *Microsporum* than *Trichophyton* infections. Fluconazole was reasonably equally effective in treating both *Microsporum* and *Trichophyton* infections. Finally, *Trichophyton* infections were more effectively cured than *Microsporum* with continuous itraconazole and terbinafine.

Traditionally, griseofulvin is the most widely prescribed medication for tinea capitis treatment in children, as it is one of the more cost-effective and accessible approaches. It is most effective for the treatment of *Microsporum* infections, but it is not available in paediatrics form in many countries. Table 6 outlines the paediatric drug availability per country. Microsized and ultramicrosized tablet versions of the drug show that co-administration of griseofulvin with fatty food will tend to reduce the difference between the bioavailability of the two types of preparations and microsized will be absorbed more easily.⁴¹ Griseofulvin is fungistatic and is quickly eliminated from the body so it must be continuously given for a long period of time to be effective. This longer duration of treatment may also contribute to a higher level of adverse events experienced compared to agents such as itraconazole, ketoconazole and fluconazole. A higher dose of griseofulvin is also needed for endothrix infections than ectothrix. This may contribute to the reduction in patient compliance and decreased efficacy, specifically in children. Griseofulvin, itraconazole and fluconazole are available as liquid suspensions, and fluconazole is also available as suppositories which are preferable methods of treatment for young children who are unable to swallow capsules and tablets. After puberty, the incidence of tinea capitis becomes more infrequent as an increase in fungistatic and fungicidal saturated lipid acids is associated with puberty.⁴²

Azole antifungal agents itraconazole and fluconazole, as well as the allylamine agent terbinafine, have high affinity for keratinizing tissues, so these agents remain in keratin and hair for a period beyond the end of active dosing meaning dosage periods can be shorter than that of griseofulvin. Terbinafine for *Microsporum* infections needs to be given for a longer period of time, 6 to 8 weeks, compared to 4 weeks for *Trichophyton* infections. Oral terbinafine accounted for over half of the reported adverse events, possibly due to its extensive biodistribution. It is recommended that baseline transaminase is monitored in children taking terbinafine.⁴³ A 2016 Cochrane review concluded that the best evidence suggests that these newer treatments (terbinafine, itraconazole and fluconazole) have comparable results to griseofulvin in children with tinea capitis caused by *Trichophyton* species.⁴⁴ However, newer treatments are more expensive and as this is a fungal infection that generally infects the lower socio-economical communities of the world.

Topical treatment may be useful as an adjunct to systemic therapy to decrease the carriage rate of infected species; however, oral treatment is necessary to effectively eradicate tinea capitis.⁴⁵ Treatments such as selenium sulphide, ketoconazole or ciclopirox shampoo are not FDA-approved for

tinea capitis specifically; however, (likely as they are ineffective on their own) it can be applied 2 to 3 times per week and left in place for 5 to 10 min for the duration of therapy or at least 2 weeks.⁴⁵ Some experts recommend topical treatment is continued until clinical and mycological cure occurs.⁴⁵ Mycological cure should be interpreted with caution, as the presence of a topical antifungal in a culture media would likely lead to a false negative result, so a clinical confirmation is necessary.

Bodyweight is used to determine drug dosing in most paediatric medicine to ensure a safe dose. Paediatric weight estimation methods have been varied due to problems with bias, precision and restrictions in the population to whom they can be applied. Physicians must rely on parental recall or provider estimation as strategies for estimating bodyweight or refer to the child's age or length.⁴⁶ The effectiveness of these methods may be insufficient as most methods overestimate weight in children who are underweight and underestimate weight in children who are overweight or obese.⁴⁶ Additionally, these methods may not take into account the race and ethnicity of children.⁴⁶ More recent clinical trials have suggested that children require significantly larger weight-normalized doses to approximate the exposure estimates detected in adults.⁴⁷

Trichophyton tonsurans is the most common aetiology in North America, and recent data show that it accounts for the rise in the prevalence of tinea capitis. *T. tonsurans* is an anthropophilic dermatophyte more likely to infect human skin and hair and can maintain viability for extended periods on inanimate objects such as combs, brushes, sheets and blankets. The highest incidence of infection occurs between the ages 3 and 7 years old, and boys and girls are equally affected.¹ The continued rise of *T. tonsurans* as the primary cause of tinea capitis in North America can be attributed to a few factors. For one, the immigrant workers who have found their way into the USA, mostly from countries such as Mexico and Puerto Rico since the late 1890s, have been suspected to have carried the organism over the border.⁴⁸ Additionally, many physicians still consider fluorescence (Wood's light examination) to be synonymous with tinea capitis, and *T. tonsurans* does not show up with fluorescence and may not contain the classic appearance of black dots. This means many cases of tinea capitis are misdiagnosed as other scalp conditions (seborrhoea, dandruff and impetigo) and often inadequately treated, leading to spread of the infection.

Microsporum canis is a zoophilic dermatophyte that causes infection carried by infected animals. It is the most common cause of tinea capitis in children in Europe, although cases due to anthropophilic dermatophytes such as *M. audouinii*, *Trichophyton soudanense*, *Trichophyton violaceum* are reported with increasing incidence since the 1990s.

Anthropophilic and zoophilic tinea capitis differ clinically, as the latter is characterized by more evident inflammatory changes. *M. canis* tinea capitis develops rapidly as a single round area of alopecia, with hair irregularly broken a few mm from the scalp, scales and erythema, associated with itching (Figure 3). The incidence is highest in hot months and history frequently reveals contact of the child with a wildcat. Tinea capitis due to anthropophilic dermatophytes, on the other hand, is often a chronic condition.

Several small areas of alopecia due to hair broken at the scalp emergence (black dot tinea capitis) associated with mild scalp scaling are a typical feature (Figure 4). Scalp scaling associated or not with alopecia is found in family members, which should be checked and treated as they are asymptomatic carriers. Trichoscopy confirms the diagnosis showing the typical features of tinea capitis, which vary depending on the hair type and not on the causative agent.⁴⁹ Comma hairs, corkscrew hairs and morse-code hairs are exclusive typical findings (Figures 3, 4).

Of the techniques included in our review, the fastest way to diagnose tinea capitis is microscopy which provides confirmation of the diagnosis and establishes whether the fungus is small-spore or large-spore ectothrix or endothrix; however, it is not always the most accurate. Direct microscopy will not yield species identification, whereas culturing the scrapings will express the species in the sample, but it will not distinguish causative agents from contaminants. Culturing the scrapings should be done to confirm diagnosis and provide precise identification of the species for epidemiologic purposes, even though this takes extended time (approximately 3 weeks, or longer).⁵⁰ In the future, PCR-based techniques and DNA sequencings will be used more often as they are even faster than microscopy; they were not used in any of our included papers most likely due to the lack of availability of the necessary specialized equipment.

Over half of the studies in this review used some form of the Wood's light examination as a way to initially diagnose the infecting organism; this method is of little significance in western countries as the majority of infections are due to *T. tonsurans*, which does not fluoresce. In North Africa and Europe, *Microsporum* infections still dominate and Wood's light may still be useful as it is the least invasive method of organism identification (Figure 2). Hair clippings are not mentioned as a form of collecting the sample in our literature search, this is probably due to the fact that not all hair is long enough or not all children want a section of their hair to be clipped. The hairbrush method has the least invasive and most accurate sample collection process. The cotton swab method was mentioned by one paper³⁸ and is similarly a good option as it is simple, inexpensive and useful for areas hard to scrape (eyelids, eyebrows) or areas that have lesions. The scalpel and hair plucking methods have better rates of identification; however, they are invasive specifically in children and particularly with active infected lesions. Diagnosis of inflammatory tinea capitis can sometimes be difficult as microscopy and even pathology might give negative results (Figures 5a,b).⁵¹

Infection from fomites and hair care practices all play a role in the acquisition of tinea capitis due to anthropophilic dermatophytes.¹ Predisposing factors of this type of tinea capitis include large family size, crowded living conditions and low socio-economic status.^{48, 50, 52} Individuals in contact with an infected person should be assessed for asymptomatic carriers of infection and may need to be treated to prevent spread of the infection. In case of tinea capitis by zoophilic dermatophytes, pets that may have carried the infection should be checked by a veterinarian, sampled by the toothbrush technique and treated accordingly, keeping in mind that cat can be asymptomatic carriers of *Microsporum canis*.⁵³ Fomites that may be infected should be discarded or disinfected with bleach or hot soapy water to

prevent infection. Recent studies have indicated that it is impractical to keep children recently treated with oral therapy out of the classroom, particularly those in higher grade levels, because shedding of spores can occur for months, despite therapy.⁵² Tinea capitis, however, still remains a relatively rare entity among infants. One reference cites only 50 known reported cases of tinea capitis in infants less than 1 year of age at the time of their evaluation.⁵⁴ Guidelines for infant care are not established.

In conclusion, the importance of early diagnosis and proper treatment for children with tinea capitis cannot be overstated as the psychosocial impact of permanent baldness in a child's life, and the overall lower quality of health is substantial. Current dosing regimens of reported drugs are effective and safe for use in tinea capitis in children. Wood's light should not be used as the only method of organism identification; this study recommends the use of hairbrushes, toothbrushes or cotton swabs as viable alternatives.

REFERENCES

1. Michaels BD, Del Rosso JQ. Tinea capitis in infants: recognition, evaluation, and management suggestions. *J Clin Aesthet Dermatol* 2012; **5**: 49–59
2. Friedlander SF, Aly R, Krafchik B *et al.* Terbinafine in the treatment of Trichophyton tinea capitis: a randomized, double-blind, parallel-group, duration-finding study. *Pediatrics* 2002; **109**: 602–607.
3. Coulibaly O, Thera MA, Koné AK *et al.* A double-blind randomized placebo-controlled clinical trial of squalamine ointment for tinea capitis treatment. *Mycopathologia* 2015; **179**: 187–193.
4. Nejjam F, Zagula M, Cabiach MD, Guessous N, Humbert H, Lakhdar H. Pilot study of terbinafine in children suffering from tinea capitis: evaluation of efficacy, safety and pharmacokinetics. *Br J Dermatol* 1995; **132**: 98–105.
5. Gupta AK, Dlova N, Taborda P *et al.* Once weekly fluconazole is effective in children in the treatment of tinea capitis: a prospective, multicentre study. *Br J Dermatol* 2000; **142**: 965–968.
6. Dastghaib L, Azizzadeh M, Jafari P. Therapeutic options for the treatment of tinea capitis: griseofulvin versus fluconazole. *J Dermatolog Treat* 2005; **16**: 43–46.
7. Deng S, Hu H, Abliz P *et al.* A random comparative study of terbinafine versus griseofulvin in patients with tinea capitis in Western China. *Mycopathologia* 2011; **172**: 365–372.
8. Haroon TS, Hussain I, Aman S *et al.* A randomized double-blind comparative study of terbinafine for 1, 2 and 4 weeks in tinea capitis. *Br J Dermatol* 1996; **135**: 86–88.
9. Khan SU, Khan AR, Wazir SM. Efficacy of terbinafine vs. Griseofulvin in tinea: capitis in the Northern areas of Pakistan. *J Pak Assoc Dermatol* 2011; **21**: 281–284.
10. Ungpakorn R, Ayutyanont T, Reangchainam S, Supanya S. Treatment of Microsporum spp. tinea capitis with pulsed oral terbinafine. *Clin Exp Dermatol* 2004; **29**: 300–303.
11. Fuller LC, Smith CH, Cerio R *et al.* A randomized comparison of 4 weeks of terbinafine vs. 8 weeks of griseofulvin for the treatment of tinea capitis. *Br J Dermatol* 2001; **144**: 321–327.
12. Grin EI. A controlled trial of home versus hospital treatment of tinea capitis with griseofulvin. *Bull World Health Organ* 1965; **33**: 193–196.
13. López-Gómez S, Del Palacio A, Van Cutsem J, Soledad Cuétara M, Iglesias L, Rodríguez-Noriega A. Itraconazole versus griseofulvin in the treatment of tinea capitis: a double-blind randomized study in children. *Int J Dermatol* 1994; **33**: 743–747.
14. Martínez-Roig A, Torres-Rodríguez JM, Bartlett-Coma A. Double blind study of ketoconazole and griseofulvin in dermatophytoses. *Pediatr Infect Dis J* 1988; **7**: 37–40.
15. Memişoğlu HR, Erboz S, Akkaya S *et al.* Comparative study of the efficacy and tolerability of 4 weeks of terbinafine therapy with 8 weeks of griseofulvin therapy in children with tinea capitis. *J Dermatolog Treat* 1999; **10**: 189–193.
16. De Freitas C, Marote J, Faria A, Fernandes A, Sequeira H, Rodrigo G. Tinea capitis in children of Canical, Madeira island, Portugal: isolation of an endemic focus of Trichophyton violaceum: treatment with terbinafine. *J Dermatolog Treat* 1998; **9**: 247–249.
17. Ginter-Hanselmayer G, Smolle J, Gupta A. Itraconazole in the treatment of tinea capitis caused by Microsporum canis: experience in a large cohort. *Pediatr Dermatol* 2004; **21**: 499–502.
18. Möhrenschrager M, Schnopp C, Fesq H *et al.* Optimizing the therapeutic approach in tinea capitis of childhood with itraconazole. *Br J Dermatol* 2000; **143**: 1011–1015.
19. Haedersdal M, Svejgaard EL. Once-weekly fluconazole in children with tinea capitis due to Microsporum canis. *Acta Derm Venereol* 2005; **85**: 177–178
20. Koumantaki E, Georgala S, Rallis E, Papadavid E. Microsporum canis tinea capitis in an 8-month-old infant successfully treated with 2 weekly pulses of oral itraconazole. *Pediatr Dermatol* 2001; **18**: 60–62.
21. Koumantaki-Mathioudaki E, Devliotou-Panagiotidou D, Rallis E *et al.* Is itraconazole the treatment of choice in Microsporum canis tinea capitis? *Drugs Exp Clin Res* 2005; **31**(Suppl): 11–15.
22. Silm H, Karelson M. Terbinafine: efficacy and tolerability in young children with tinea capitis due to Microsporum canis. *J Eur Acad Dermatol Venereol* 2002; **16**: 228–230.

23. Chen C, Koch LH, Dice JE *et al.* A randomized, double-blind study comparing the efficacy of selenium sulfide shampoo 1% and ciclopirox shampoo 1% as adjunctive treatments for tinea capitis in children. *Pediatr Dermatol* 2010; **27**: 459–462.
24. Elewski BE, Cáceres HW, DeLeon L *et al.* Terbinafine hydrochloride oral granules versus oral griseofulvin suspension in children with tinea capitis: results of two randomized, investigator-blinded, multicenter, international, controlled trials. *J Am Acad Dermatol* 2008; **59**: 41–54.
25. Gan VN, Petruska M, Ginsburg CM. Epidemiology and treatment of tinea capitis: ketoconazole vs. griseofulvin. *Pediatr Infect Dis J* 1987; **6**: 46–49.
26. Givens TG, Murray MM, Baker RC. Comparison of 1% and 2.5% selenium sulfide in the treatment of tinea capitis. *Arch Pediatr Adolesc Med* 1995; **149**: 808–811.
27. Solomon BA, Collins R, Sharma R *et al.* Fluconazole for the treatment of tinea capitis in children. *J Am Acad Dermatol* 1997; **37**: 274–275.
28. Tanz RR, Stagl S, Esterly NB. Comparison of ketoconazole and griseofulvin for treatment of tinea capitis in childhood: a preliminary study. *Pediatr Emerg Care* 1985; **1**: 16–18.
29. Tanz RR, Hebert AA, Esterly NB. Treating tinea capitis: should ketoconazole replace griseofulvin? *J Pediatr* 1988; **112**: 987–991.
30. Abdel-Rahman SM, Powell DA, Nahata MC. Efficacy of itraconazole in children with Trichophyton tonsurans tinea capitis. *J Am Acad Dermatol* 1998; **38**: 443–446.
31. Lorch Dauk KC, Comrov E, Blumer JL, O'Riordan MA, Furman LM. Tinea capitis: predictive value of symptoms and time to cure with griseofulvin treatment. *Clin Pediatr (Phila)* 2010; **49**: 280–286.
32. Montero-Gei F. Fluconazole in the treatment of tinea capitis. *Int J Dermatol* 1998; **37**: 870–871.
33. Gupta AK, Alexis ME, Raboobee N *et al.* Itraconazole pulse therapy is effective in the treatment of tinea capitis in children: an open multicentre study. *Br J Dermatol* 1997; **137**: 251–254.
34. Gupta AK, Solomon RS, Adam P. Itraconazole oral solution for the treatment of tinea capitis. *Br J Dermatol* 1998; **139**: 104–106.
35. Gupta AK, Nolting S, de Prost Y *et al.* The use of itraconazole to treat cutaneous fungal infections in children. *Dermatology* 1999; **199**: 248–252.
36. Gupta AK, Adam P, Hofstadter SL *et al.* Intermittent short duration therapy with fluconazole is effective for tinea capitis. *Br J Dermatol* 1999; **141**: 304–306.
37. Krafchik B, Pelletier J. An open study of tinea capitis in 50 children treated with a 2-week course of oral terbinafine. *J Am Acad Dermatol* 1999; **41**: 60–63.
38. Cáceres-Ríos H, Rueda M, Ballona R, Bustamante B. Comparison of terbinafine and griseofulvin in the treatment of tinea capitis. *J Am Acad Dermatol* 2000; **42**: 80–84.
39. Filho ST, Cucé LC, Foss NT, Marques SA, Santamaria JR. Efficacy, safety and tolerability of terbinafine for Tinea capitis in children: Brazilian multicentric study with daily oral tablets for 1,2 and 4 weeks. *J Eur Acad Dermatol Venereol* 1998; **11**: 141–146.
40. Foster KW, Friedlander SF, Panzer H, Ghannoum MA, Elewski BE. A randomized controlled trial assessing the efficacy of fluconazole in the treatment of pediatric tinea capitis. *J Am Acad Dermatol* 2005; **53**: 798–809.
41. Bijanzadeh M, Mahmoudian M, Salehian P, Khazainia T, Eshghi L, Khosravy A. The bioavailability of griseofulvin from micro-sized and ultramicro-sized tablets in nonfasting volunteers. *Indian J Physiol Pharmacol* 1990; **34**: 157–161.
42. Rothman S, Smijanjan AM, Weitkamp AW. Mechanism of spontaneous cure in puberty of ringworm of the scalp. *Science* 1946; **104**: 201–203.
43. Patel D, Castelo-Soccio LA, Rubin AI, Streicher JL. Laboratory monitoring during systemic terbinafine therapy for pediatric onychomycosis. *JAMA Dermatol* 2017; **153**: 1326–1327.
44. Chen X, Jiang X, Yang M *et al.* Systemic antifungal therapy for tinea capitis in children. *Cochrane Database Syst Rev* 2016; **12**: CD004685.
45. Committee on Infectious Diseases, American Academy of Pediatrics. *Red Book [Electronic Resource] : 2015 Report of the Committee on Infectious Diseases/Committee on Infectious Diseases, American Academy of Pediatrics*, 13th edn. American Academy of Pediatrics, Elk Grove Village, Illinois, 2015.

46. Abdel-Rahman SM, Ahlers N, Holmes A *et al*. Validation of an improved pediatric weight estimation strategy. *J Pediatr Pharmacol Ther* 2013; **18**: 112–121.
47. Pan S, Zhu L, Chen M, Xia P, Zhou Q. Weight-based dosing in medication use: what should we know? *Patient Prefer Adherence* 2016; **10**: 549–560.
48. Ajello L. Geographic distribution and prevalence of the dermatophytes. *Ann N Y Acad Sci* 1960; **89**: 30–38.
49. Rudnicka L, Rakowska A, Kerzeja M, Olszewska M. Hair shafts in trichoscopy: clues for diagnosis of hair and scalp diseases. *Dermatol Clin* 2013; **31**: 695–708.
50. Fuller LC, Child FC, Midgley G, Higgins EM. Scalp ringworm in south-east London and an analysis of a cohort of patients from a paediatric dermatology department. *Br J Dermatol* 2003; **148**: 985–988.
51. LaSenna CE, Miteva M, Tosti A. Pitfalls in the diagnosis of kerion. *J Eur Acad Dermatol Venereol* 2016; **30**: 515–517.
52. Honig PJ. Tinea capitis: recommendations for school attendance. *Pediatr Infect Dis J* 1999; **18**: 211–214.
53. Pasquetti M, Min ARM, Scacchetti S, Dogliero A, Peano A. Infection by microsporum canis in paediatric patients: a veterinary perspective. *Vet Sci* 2017; **19**: 4.
54. Gilaberte Y, Rezusta A, Gil J *et al*. Tinea capitis in infants in their first year of life. *Br J Dermatol* 2004; **151**: 886–890.
55. Sporanox. Package Insert (Itraconazole) Capsules, 100 mg [Internet]. Drugs@FDA: FDA Approved Drug Products. 2009.
56. Diflucan. Package Insert (Fluconazole) Tablets, 50, 100, 150, or 200 mg [Internet]. Drugs@FDA: FDA Approved Drug Products. 2011.
57. Nizoral. Package Insert (Ketoconazole) Tablets, 200 mg [Internet]. Drugs@FDA: FDA Approved Drug Products. 2013.
58. Gris-Peg. Package Insert (Griseofulvin Ultramicrosized) Tablets, 125 mg; 250 mg [Internet]. Drugs@FDA: FDA Approved Drug Products. 2016.
59. Lamisil. Package Insert: LAMISIL (terbinafine hydrochloride) Tablets, 250 mg Drugs@FDA: FDA Approved Drug Products 2012

Figure 1

Summary of literature search for RCTs and CTs on the treatment of tinea capitis in children

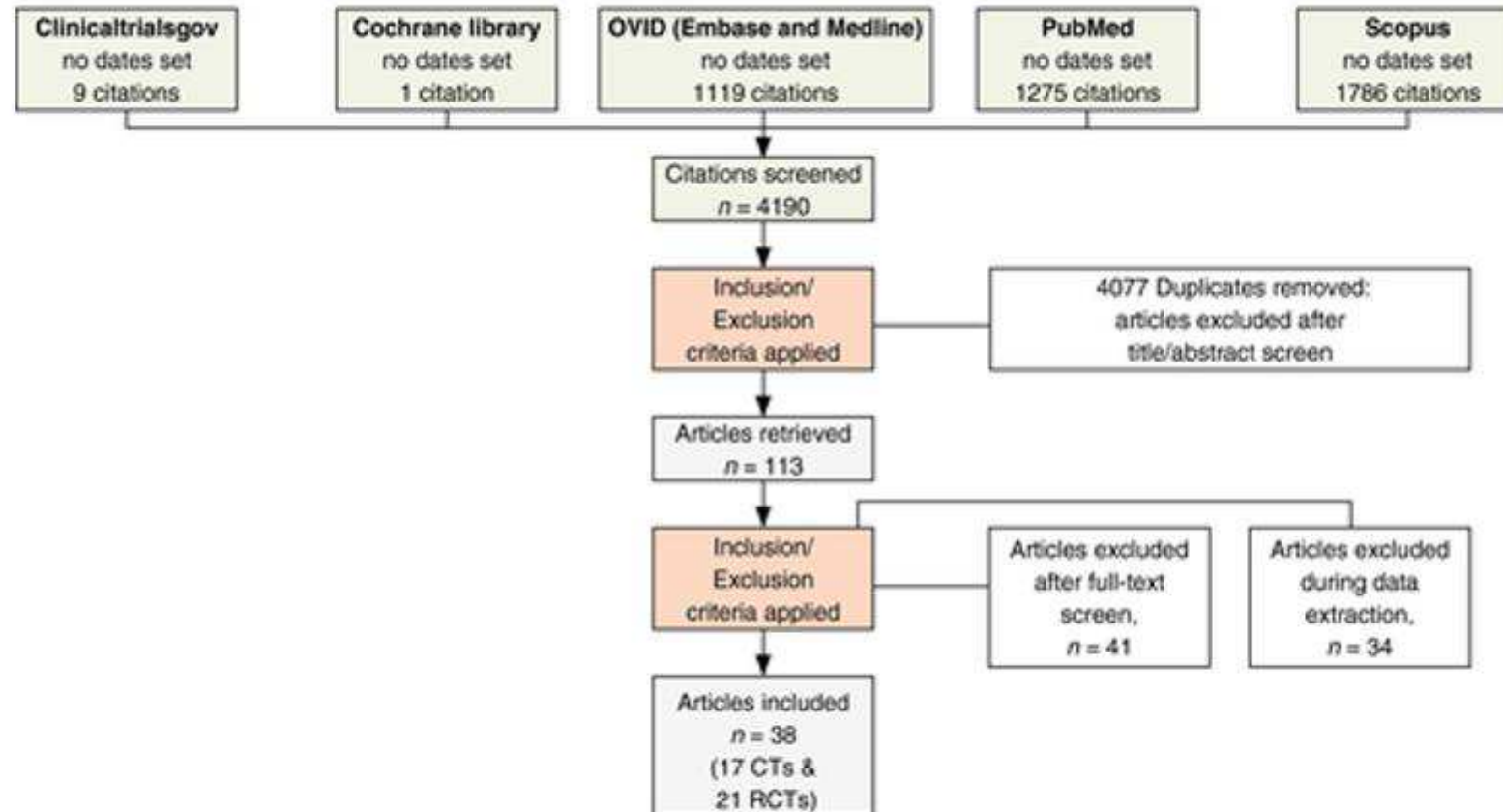


Figure 2

Map of most common organisms in each country. Countries in grey do not have sufficient information to include.

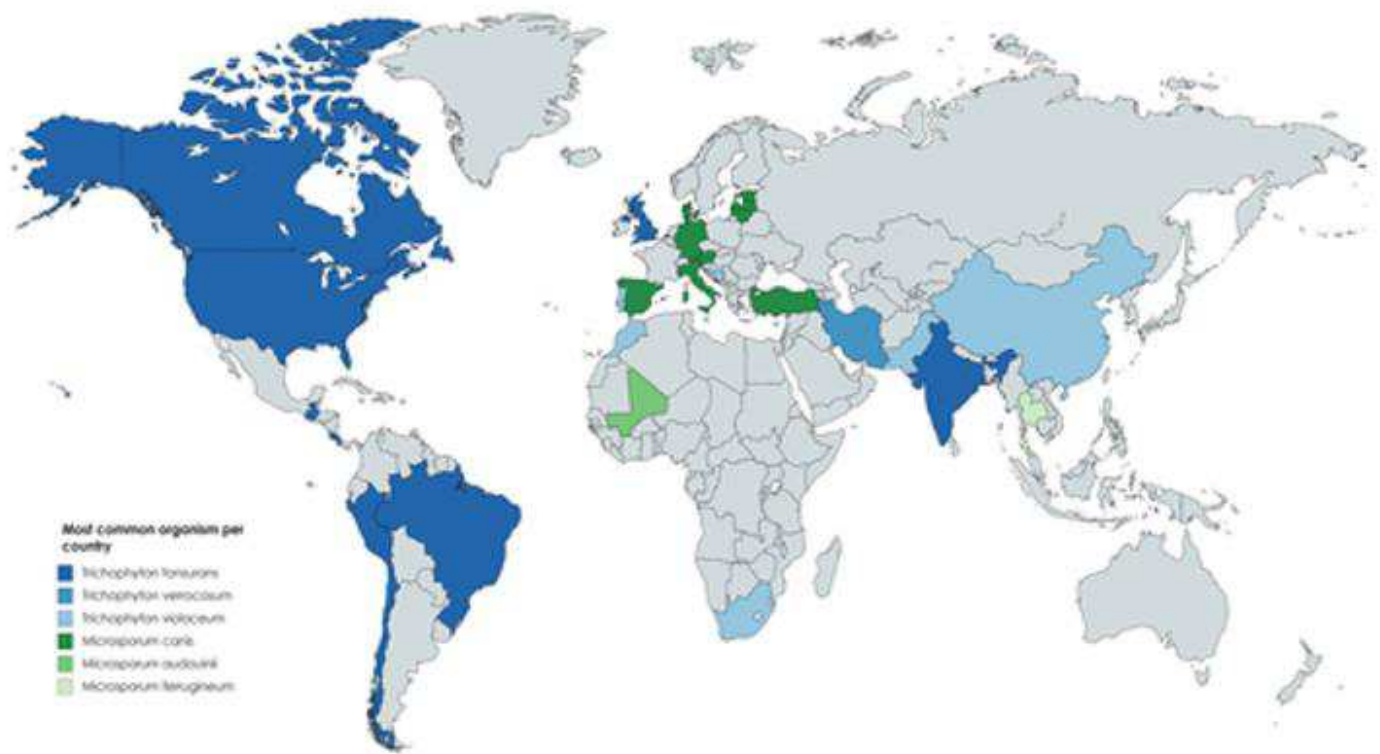


Figure 3

Tinea capitis due to *Microsporum canis*: scaly red patch of alopecia with broken hair shafts; trichoscopy shows coma hairs, morse-code hairs and hair casts.

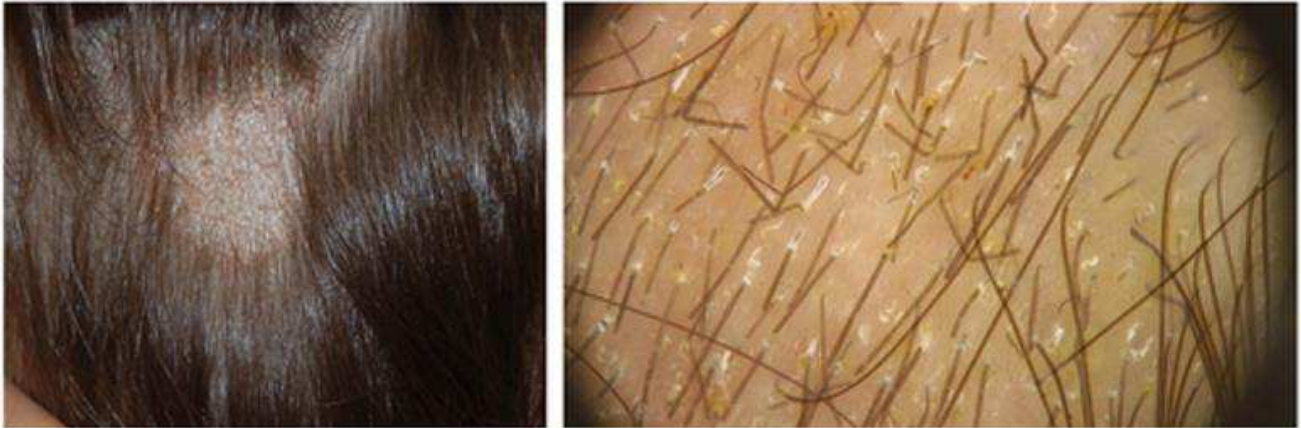

Figure 4

Tinea capitis due to *Tricophyton tonsurans*: scaly patches of alopecia; trichoscopy shows corkscrew hairs.

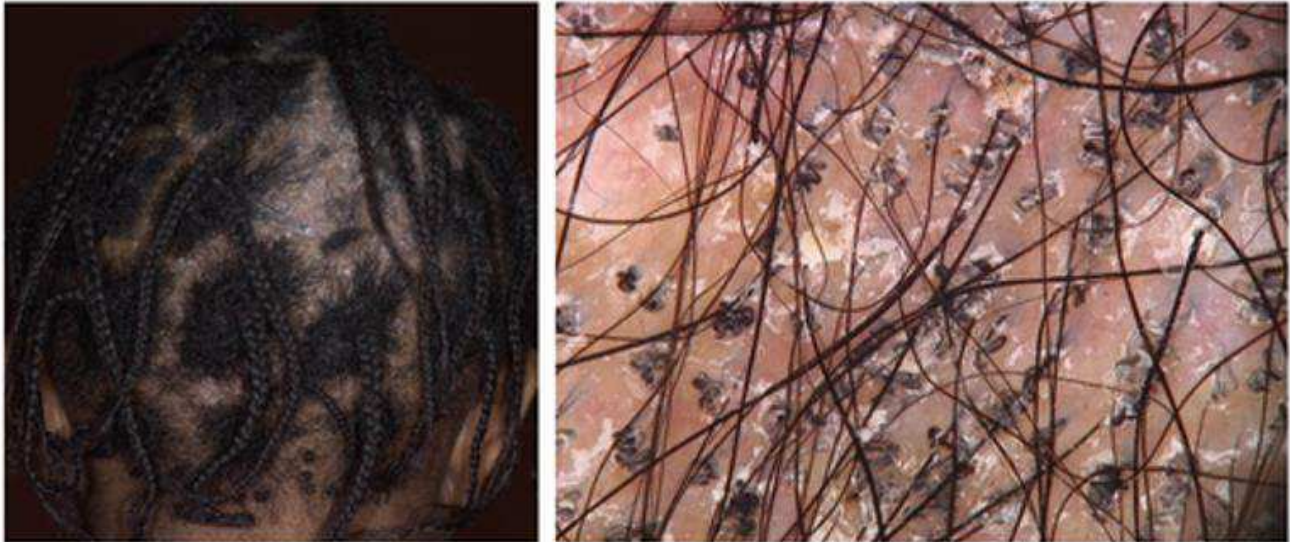

Figure 5

Kerion negative pathology and fungal staining.

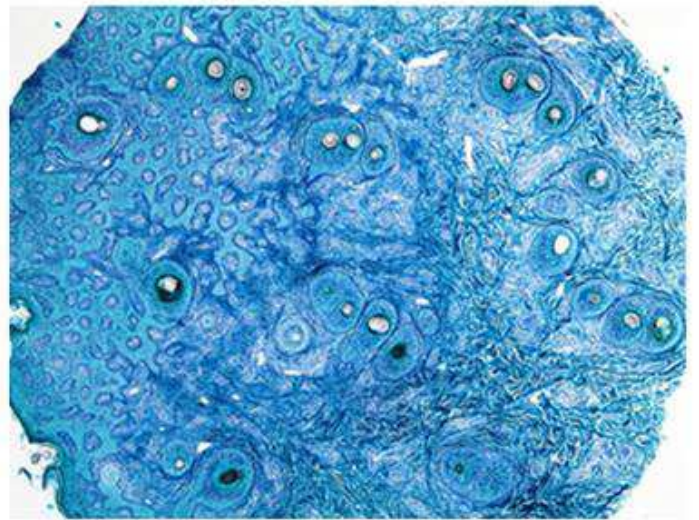
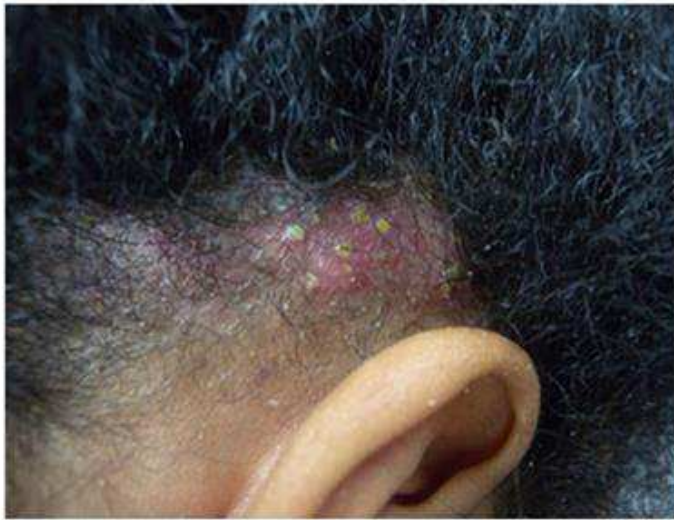

Table 1

Positives and negatives list of the methods of collection samples for the diagnosis tinea capitis in children

<u>Collection method</u>	<u>Technique</u>	<u>Positives</u>	<u>Negatives</u>
Cotton swabbing method ¹⁴	A tap water, moistened sterile cotton tip applicator is vigorously rubbed and rotated over an affected area of scalp for maximum 15 s	<ul style="list-style-type: none"> • Cotton swabs are readily available in most physicians' offices • Inexpensive • Easy to use • Useful for areas hard to scrape (eyelids, eyebrows) or that have lesions • Low pain 	<ul style="list-style-type: none"> • Low efficacy in isolating the dermatophytes from scalp • Lack of ability to predict the spore load • Must scrub vigorously
Hair clipping method	A few hairs from involved areas of the scalp are clipped from scalp	<ul style="list-style-type: none"> • Hair clippers are readily available in most physicians' offices • Easy to use • No pain • Inexpensive 	<ul style="list-style-type: none"> • Risking pain or trauma to the patient • Not all hair can be clipped
Hair plucking method ^{19, 26}	A few hairs from involved areas of the scalp are plucked from scalp	<ul style="list-style-type: none"> • Tweezers are readily available in most physicians' offices • Easy to use • Inexpensive 	<ul style="list-style-type: none"> • Risking pain or trauma to the patient • Not all hair can be plucked • May remove uninvolved hairs
Hairbrush culture technique ^{3, 56}	Brush is rubbed on scalp. The friction from massaging the bristles around the affected areas makes the bristles negatively charged so that they pick up hairs and scalp scales. The brush is then sent to the laboratory	<ul style="list-style-type: none"> • Easy to use • Brush covers a greater surface area to collect samples • Low pain 	<ul style="list-style-type: none"> • Hairbrushes are not readily available in most physicians' offices • Must scrub vigorously • Isolation power at 64% • Incubation period required for the hairbrush culture is at least 2 week

<u>Collection method</u>	<u>Technique</u>	<u>Positives</u>	<u>Negatives</u>
			<ul style="list-style-type: none"> • Poor results children with closely cropped or shaved scalps, or tightly braided hair
Scalpel blade method	Obtained by scraping the affected area with the blunt side of a scalpel (to avoid slicing through the infected hairs) onto a piece of folded paper	<ul style="list-style-type: none"> • Can tests for KOH easily • Scalpels are readily available in most physicians' offices 	<ul style="list-style-type: none"> • Expensive • Risking pain or trauma to the patient • This technique requires some practice
Toothbrush culture technique ^{11, 15, 37}	The friction from massaging the bristles around the affected areas makes the bristles negatively charged so that they pick up hairs and scalp scales	<ul style="list-style-type: none"> • Inexpensive • Low pain 	<ul style="list-style-type: none"> • Low efficacy in isolating the dermatophytes from scalp and their lack of ability to predict the spore load • Toothbrushes are not readily available in most physicians' offices • Provides greater inoculum for culture
Wood's light/lamp examination ^{4, 10, 16, 20, 38} or light microscopy examination ^{6, 13, 24, 31}	Hair is examined and exposed to the black light	<ul style="list-style-type: none"> • No pain • Easy to use 	<ul style="list-style-type: none"> • Expensive • Not readily available in most physicians' offices • Can only detect <i>Microsporum spp.</i> species with a blue-green fluoresce and <i>T. schoenleinii</i> has a dull blue fluoresce

Table 2

Efficacy rates

<u>Dose</u>	<u>Mycological cure</u>	<u>Complete cure</u>	<u>Clinical cure</u>
Griseofulvin			
Based on weight for 8 weeks	Wk 12: 67.2% (<i>n</i> = 64)	Wk 8: 40.6% (<i>n</i> = 64) Wk 12: 71.8% (<i>n</i> = 64)	
Based on weight for 6 weeks	Wk 6: 52.3% (<i>n</i> = 321) Wk 10: 51.5% (<i>n</i> = 818)	Wk 10: 32.8% (<i>n</i> = 801)	Wk 10: 46.4% (<i>n</i> = 801)
10–15 mg/kg/day for 8 weeks (plus ciclopirox or selenium sulphide shampoo)	Wk 2: 16.7% (<i>n</i> = 78) Wk 4: 37.4% (<i>n</i> = 155) Wk 6: 44.4% (<i>n</i> = 45) Wk 8: 41.3% (<i>n</i> = 155) Wk 12: 32.7% (<i>n</i> = 98)		
Itraconazole			
100 mg/day for 4 weeks (plus selenium sulphide shampoo)	Wk 4: 55.2% (<i>n</i> = 67) Wk 6: 68.7% (<i>n</i> = 67) Wk 8: 79.1% (<i>n</i> = 67)		
3–5 mg/kg/day for 4 to 8 weeks	Wk 12: 79.0% (<i>n</i> = 105)		
Ketoconazole			
3.3–6.6 mg/kg/day for 2 weeks	Wk 4: 24.7% (<i>n</i> = 73) Wk 12: 15.1% (<i>n</i> = 73)		

Terbinafine			
Based on weight for 1 to 2 weeks	Wk 4: 53.8% (<i>n</i> = 106)	Wk 12: 54.8% (<i>n</i> = 104)	Wk 12: 58.1% (<i>n</i> = 86)
Based on weight for 4 weeks	Wk 4: 66.3% (<i>n</i> = 83) Wk 8: 69.6% (<i>n</i> = 56) Wk 12: 81.4% (<i>n</i> = 59)	Wk 3: 8.3%(<i>n</i> = 24) Wk 6: 91.7% (<i>n</i> = 24) Wk 8: 69.4% (<i>n</i> = 36) Wk 12: 60.9% (<i>n</i> = 69)	
Based on weight for 6 to 8 weeks	Wk 6: 50.9% (<i>n</i> = 1052)		
Based on weight for 4 weeks plus selenium sulphide shampoo or 1% terbinafine cream	Wk 4: 46.8% (<i>n</i> = 126)	Wk 4: 32.9% (<i>n</i> = 158)	

Table 3

<u>Treatment (dosage)</u>		<u>Mycological cure</u>		<u>Complete cure</u>		<u>Clinical cure</u>	
		<i>Microsporum</i> spp.	<i>Trichophyton</i> spp.	<i>Microsporum</i> spp.	<i>Trichophyton</i> spp.	<i>Microsporum</i> spp.	<i>Trichophyton</i> spp.
Griseofulvin	Dose based on wgt for 6 to 8 wks	Wks 8 to 12: 60.0% (<i>n</i> = 86)	Wks 6 to 12: 54.4% (<i>n</i> = 388)	Wks 8 to 12: 48.5% (<i>n</i> = 99)	Wks 6 to 12: 39.8% (<i>n</i> = 357)	Wks 8 to 12: 57.3% (<i>n</i> = 82)	Wks 6 to 12: 59.0% (<i>n</i> = 339)
Griseofulvin plus selenium sulphide shampoo	10 to 15 mg/kg/dy plus 1 to 2.5% for 8 wks	Wks 4 to 24: 60.6% (<i>n</i> = 33)	Wks 2 to 8: 30.7% (<i>n</i> = 238)	–	–	–	–
Fluconazole	8 mg/kg/dy for 8 wks	Wks 8: 94.1% (<i>n</i> = 17)	Wks 8: 100.0% (<i>n</i> = 44)	–	–	–	–
Itraconazole ^a	3 to 5 mg/kg/dy for 4 to 8 wks	Wks 4 to 6: 73.5% (<i>n</i> = 34)	Wks 4 to 8: 90.9% (<i>n</i> = 22)	–	–	–	–
Itraconazole ^a plus selenium sulphide shampoo	Dose based on wgt plus 1 to 2.5% for 4 wks	Wks 4 to 8: 93.6% (<i>n</i> = 78)	Wks 2 to 8: 52.7% (<i>n</i> = 148)	–	–	–	–
Terbinafine	Dose based on wgt 6 to 8 wks	Wks 8 to 12: 45.9% (<i>n</i> = 170)	Wks 8 to 12: 66.4% (<i>n</i> = 699)	Wks 10: 27.0% (<i>n</i> = 152)	Wks 10: 49.5% (<i>n</i> = 667)	Wks 10: 39.5% (<i>n</i> = 152)	Wks 10: 68.8% (<i>n</i> = 667)
Terbinafine plus selenium sulphide shampoo or terbinafine cream	Dose based on wgt plus 1 or 2.5% or 1% for 4 wks	Wks 4 to 24: 26.1% (<i>n</i> = 115)	Wks 4 to 8: 47.8% (<i>n</i> = 67)	–	–	–	–

a continuous itraconazole treatment.

Wk, week; Wgt, weight

Table 4

<u>Drug</u>	<u>Reported circulatory events</u>	<u>Reported dermatological events</u>	<u>Reported gastrointestinal events</u>	<u>Reported respiratory events</u>	<u>Reported miscellaneous events</u>	<u>Total reported drug related events</u>	<u>Number of children experiencing AEs</u>	<u>Number of children disc. drug due to AE (n=)</u>
Fluconazole (n = 758) LFT ^a	–	Rash (3/36)	AP (6/36) Diarrhea (4/36) Dyspepsia (1/36) Gastritis (4/36)	Fever (3/36) Rhinitis (1/36) URTI (1/36) Otitis media (1/36)	Headache (5/36) Nausea (3/36) Vomiting (2/36) Unspecified (2/36)	36	36/758	10/758
Griseofulvin (n = 1665) None ^a	↑triglycerides (1/79) ^b Anemia (2/79) SGOT (1/79)	Rash (1/79)	AP (10/79) Diarrhea (7/79) Dyspepsia (3/79)	Fever (1/79)	Headache (12/79) Nausea (9/79) Weight gain (3/79) Vomiting (12/79) Unspecified (17/79)	79	83/1665	15/1665
Itraconazole (n = 521) LFT initially and after 4 wks of use ^a	–	Atopic dermatitis (2/25) Skin lesions (4/25)	AP (2/25) Diarrhea (4/25) General events (3/25) Indigestion (2/25)	Viral infection (3/25) Epistaxis (1/25)	Headache (1/25) Vomiting (3/25)	25	23/521	4/521
Ketoconazole (n = 169) LFT initially and after 4 wks of use ^a	–	Urticaria (1/4)	AP (2/4)	–	Nausea (1/4)	4	4/169	0/169
Terbinafine (n = 1718) LFT initially and after 6 wks of use ^a	Eosinophilia (5/151) PVE (1/151) ↑ triglycerides(5/151) ^b ↑hepatic enzymes(8/151) ^b Leucytosis (4/151)	Erythema (1/151) Itch (2/151) ID reaction (7/151) Pruritus (1/151) Urticaria (1/151)	AP (24/151) Diarrhea (12/151) Obstipation (2/151)	–	Anorexia (1/151) Headache (12/151) Nausea (13/151) Vomiting (18/151) Weight gain (4/151) Taste disorder (2/151) Unspecified (28/151)	151	172/1718	21/1718

<u>Drug</u>	<u>Reported circulatory events</u>	<u>Reported dermatological events</u>	<u>Reported gastrointestinal events</u>	<u>Reported respiratory events</u>	<u>Reported miscellaneous events</u>	<u>Total reported drug related events</u>	<u>Number of children experiencing AEs</u>	<u>Number of children disc. drug due to AE (n=)</u>
Topicals (n = 25)	–	–	–	–	–	0	0/25	0/25
Total						295 individual events	318/4856 (6.5%) children	50/4856 (1.0%) children disc.

^a Recommended laboratory tests

^b Laboratory events recorded

LFT, Liver function test; URTI, Upper respiratory tract infection; PVE, Pruritic vesiculopustular eruption; AP, Abdominal pain; Disc., discontinued; wks, weeks.

Table 5

<u>Drug</u>	<u>Dosage</u>	<u>Duration</u>
Tablets		
Fluconazole	6 mg/kg/day	3 and 6 weeks
Griseofulvin – microsized	20–25 mg/kg/day	≥6 weeks; continue until clinically clear
Griseofulvin – ultramicrosized	10–15 mg/kg/day	≥6 weeks; continue until clinically clear
Itraconazole	5 mg/kg/day	Trichophyton spp.: 2–4 weeks Microsporum spp.: 4–6 weeks
Ketoconazole	4 mg/kg/day	12 weeks
Terbinafine tablets – 250 mg	4–6 mg/kg/day 10–20 kg: 62.5 mg 20–40 kg: 125 mg >40 kg: 250 mg	<i>T. tonsurans</i> : 2–6 weeks <i>M. canis</i> : 8–12 weeks
Terbinafine granules – 125 mg and 187.5 mg	<25 kg: 125 mg 25–35 kg: 187.5 mg >35 kg: 250 mg	FDA-approved for children ≥4 years 6-week duration for all species
Oral solution		
Griseofulvin microsized - (125 mg/5 mL)	20–25 mg/kg/day	≥6 weeks; continue until clinically clear
Itraconazole	3 mg/kg/day	6 weeks
Fluconazole	3 to 6 mg/kg/day	3 weeks

Table 6

<u>Drug</u>	<u>Available as branded drug</u>	<u>Available as generic drug</u>	<u>Approved for tinea capitis in children (<18 years old)</u>
Griseofulvin	Brazil, Italy, India, USA	Italy, India, UK, USA	South Africa, Brazil, Italy, USA
Terbinafine	South Africa, Brazil, Canada, Italy, India, USA	Brazil, Canada, Italy, India, UK, USA	South Africa, Brazil, Canada, USA
Itraconazole	South Africa, Brazil, Canada, Italy, India, USA	South Africa, Brazil, Canada, Italy, India, UK, USA	South Africa, Brazil
Fluconazole	South Africa, Brazil, Canada, Italy, India, USA	South Africa, Brazil, Canada, Italy, India, UK, USA	South Africa

Global paediatric drug availability⁵⁵⁻⁵⁹