

Porcine Model for Gluteal Artery Perforator Flap: Anatomy and Technique

Nicoló Favuzza, MD*
Salvatore D'Arpa, MD, PhD†‡
Marta Cajozzo, MD†
Tiziana Roggio, MD†
Pierluigi Tos, MD, PhD§
Giorgio De Santis, MD, PhD¶
Mario Cherubino, MD||
Francesco Moschella, MD, PhD†
Adriana Cordova, MD, PhD†
Marco Pignatti, MD¶

BACKGROUND

Although flap anatomy is well studied on cadavers and microsurgical techniques are well practiced on rats, still there are few training models for learning the techniques of perforator flap harvesting. The cadaver has no bloodstream, so accuracy of dissection cannot be evaluated and flap viability cannot be verified. Training on humans carries a high risk of flap damage. A living model for perforator flap harvest is needed to learn the technique before starting with its clinical application.

The aim of this study was to optimize the use of the porcine gluteal artery perforator flap as a living model in the training for the superior gluteal artery perforator flap harvest.

METHODS

A female pig (*Sus scrofa domesticus*), weighing about 25 kg was operated on under general anesthesia. With the pig in lateral decubitus, a line from the anterior superior iliac spine (ASIS) to the greater trochanter was marked

*From the *Private Practice, Palermo, Italy; †Chirurgia Plastica e Ricostruttiva, Dipartimento di Discipline Chirurgiche, Oncologiche e Stomatologiche, Università degli Studi di Palermo, Palermo, Italy; ‡Department of Plastic and Reconstructive Surgery, Gent University Hospital, Ghent, Belgium; §UOC di Microchirurgia e Chirurgia della Mano – ASST Gaetano Pini – CTO Milano, Milano, Italy; ¶Dipartimento di Chirurgia Plastica Ricostruttiva, Azienda Ospedaliero-Universitaria Policlinico di Modena, Modena, Italy; and || Division of Plastic and Reconstructive Surgery, Department of Biotechnology and Life Sciences (DBSV), University of Insubria, Varese, Italy. Nicoló Favuzza MD. Email: nicola.fav@gmail.com*
Copyright © 2018 The Authors. Published by Wolters Kluwer Health, Inc. on behalf of The American Society of Plastic Surgeons. This is an open-access article distributed under the terms of the Creative Commons Attribution-Non Commercial-No Derivatives License 4.0 (CCBY-NC-ND), where it is permissible to download and share the work provided it is properly cited. The work cannot be changed in any way or used commercially without permission from the journal. *Plast Reconstr Surg Glob Open* 2018;6:e1661; doi: 10.1097/GOX.0000000000001661; Published online 20 February 2018.

parallel to the fibers of the gluteus muscle.¹ A skin island with its major axis transversal to this line was drawn similarly to planning of a superior gluteal artery perforator (SGAP) flap, used in humans for breast reconstruction.

The procedure was recorded by means of a GoPro camera and simultaneously with a head mounted (4× magnification) Loupecam system. Photographs were taken using 2 cameras during surgery at relevant time points.

RESULTS

Three perforating vessels larger than 1 mm were identified along the line connecting the ASIS and the greater trochanter and the greatest of these was selected.² The identification and dissection of perforating vessels appeared to be very similar to what is done in humans both in the intramuscular component and in the last part of the dissection deep to the muscle, which closely resembles that of a human SGAP. At the end of the dissection, the flap was well perfused (Figs. 1, 2).

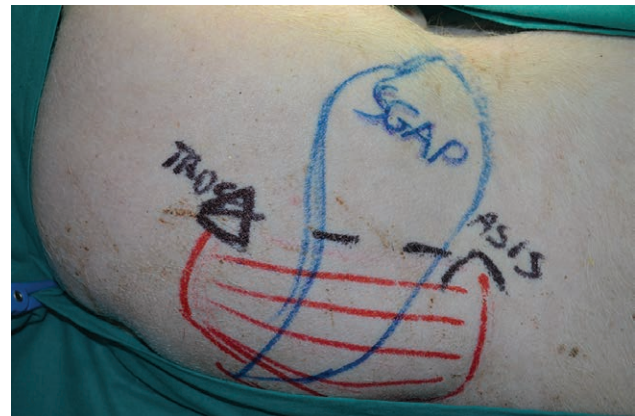


Fig. 1. Close up view of the buttock region of a female pig in the lateral decubitus with the head on the right hand side and the buttocks on the bottom of the image. The black dotted line connects the ASIS to the greater trochanter (Troca). This line is parallel to the gluteus muscle fibers marked in red. A blue skin island with its major axis transversal to the above mentioned line is drawn similarly to the planning of an SGAP flap, used in humans for breast reconstruction.

Disclosure: The authors have no financial interest to declare in relation to the content of this article. The Article Processing Charge was paid for by the authors.

SICPRE: SICPRE, Società Italiana di Chirurgia Plastica Ricostruttiva ed Estetica, national meeting, in Turin on September 21-24, 2016.

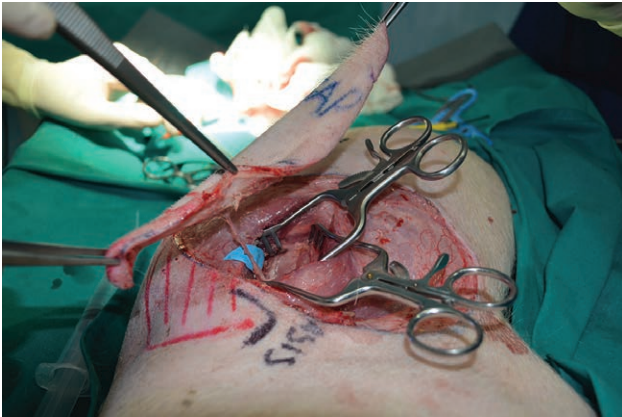

Fig. 2. Intraoperative view at the end of flap dissection. The observer is placed at the pig's head; the flap is lifted. The 2 Weitlaner retractors hold the split muscle fibers spread apart. The isolated perforator pedicle is placed on top of a blue background. Compared with humans, the flap is a lot thinner in pigs.

CONCLUSIONS

The porcine gluteal artery perforator flap model, although presenting some anatomical differences compared with humans, is a good model for SGAP flap harvesting. The size of the vessels is similar to the one found

in humans. Compared with nonliving models like the cadaver or living models of smaller size, the pig allows accurate simulation of human surgery.³ These features make it complementary to the cadaver dissections training model that is very useful for learning the human anatomy but does not reproduce the real surgical conditions of an active bloodstream and living tissues.⁴

Nicolò Favuzza, MD

Palermo, Italy

Email: nicola.fav@gmail.com

ACKNOWLEDGMENTS

The donation was paid for by Egle Muti for Aldo Fontana.

REFERENCES

1. Bodin F, Diana M, Koutsomanis A, et al. Porcine model for free-flap breast reconstruction training. *J Plast Reconstr Aesthet Surg.* 2015;68:1402–1409.
2. Zhang HM, Yan YP, Sun GC, et al. Cutaneous blood vessels in scent pigs. *Plast Reconstr Surg.* 2000;106:1555–1565.
3. Nistor A, Jiga L, Georgescu D, et al. The pig as an ideal training model for perforator flap dissection in living tissue. *Plast Reconstr Surg.* 2014;133(3).
4. Stefanidis D, Younce TC, Green JM, et al. Cadavers versus pigs: which are better for procedural training of surgery residents outside the OR? *Surgery.* 2013;154:34–37.