

External auditory canal atresia (E.A.C.A.) in a ferret (*Mustela putorius furo*)



External auditory canal atresia (EACA) is an anomaly involving the closure or absence of the ear canal and represents an occurrence reported in humans, dogs and cats but it has never been previously described in the ferret. The present clinical case describes the experience gained with a ferret affected by EACA referred to the clinic for a physical examination and diagnostic investigation in order to evaluate the degree of the anomaly. A computed tomography (CT) performed in sedation and without contrast agent showed the complete absence of the external ear canal, confirming the malformation.

Pierfrancesco Bo*,
Med Vet, SPCAA,
Bologna

Monica Alberti,
Med Vet,
Zola Predosa

Claudio Tagliavia¹,
Med Vet,
GPCert (ExAP),
PhD Student

Keywords - Ferret, external auditory canal, atresia, EACA, CT.

INTRODUCTION

External auditory canal atresia (EACA) is a disorder that results in the closure or absence of the external auditory canal.¹

EACA may result from congenital or acquired conditions;² widely reported in humans, often in association with other congenital malformations,^{3,4} EACA is rarely encountered in domestic pets; cases have been reported in the dog^{1,5,6,7} and in the cat,^{5,8} but never in the ferret.

Based on the literature that we have been able to consult this work describes the first reported case of EACA in the ferret.

CASE DESCRIPTION

Kratos, a 6-month-old male ferret, weighing 1.43 kg, was referred to the clinic for instrumental diagnostic investigations in order to study the morphology of the left ear, to assess the presence and extent of the external auditory canal (EAC) as well as of any other lesions involving the middle ear canal.

The clinical history had in fact reported the non-opening of the left external auditory canal, in spite of the presence of the pinna, as well as a family predisposition to congenital anomalies and disorders.

External auditory canal atresia is a congenital or acquired disorder that results in the closure or absence of the external acoustic meatus.

A complete bilateral examination of the auricular region was thus carried out. The investigation revealed the absence of the opening of the left external acoustic meatus at the level of the conchal fossa occupied by the medial root of the helix (Figure 1) and the absence of adjacent skin lesions attributable to scratching; on palpation, no thickening and/or deformation of the skin and auricular cartilage were appreciated and no painful reactions were evoked. In order to assess the condition of the middle ear it was therefore necessary to assess the symptoms and clinical signs resulting from its eventual involvement.

¹ Dipartimento di Scienze Mediche Veterinarie - Università di Bologna, Ozzano dell'Emilia

*Corresponding Author (fraecol@libero.it)

Received: 02/02/2018 - Accepted: 20/06/2018

The case was partially presented as a poster at the 3rd International SIVAE Congress in Rimini, May 27-28, 2017.

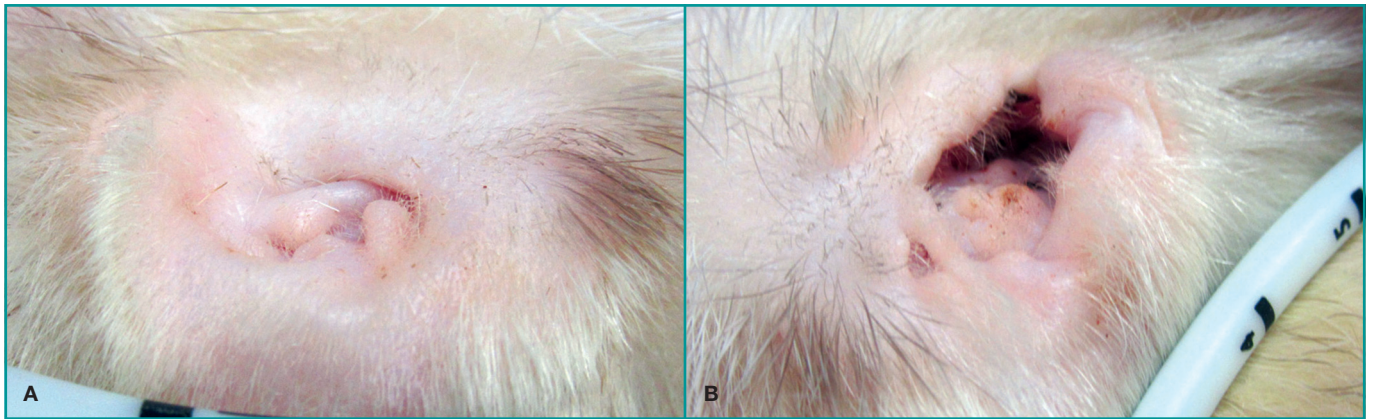


Figure 1 - Comparison of ferret ears. Notice in the left ear the absence of the conchal cavity which is the conduit for the external acoustic meatus.

The contralateral ear appeared normal in all of its characteristics, as well as the rest of the general physical examination and no neurological abnormalities were found.

The blood chemistry examination, which resulted within the norm, was followed by a CT scan (Toshiba Aquilion 16 - Helical method 100 kV- 150 Ma- thickness 0.5 mm - pitch 1 - rotation time 0.75 s. and Dicom OsiriX

Non-contrast CT revealed the absence of the left EAC.

reconstruction method) performed under general anaesthesia, with the ferret placed in sternal decubitus.

The CT, performed without contrast medium, revealed the absence of the left EAC; the tympanic bullae appeared free from accumulations of pathological material and were normally-conformed, similarly to the right EAC and the bony structures (Figures 2,3). The resulting diagnosis was of complete agenesis of the left external auditory canal.

Surgery,² the only resolutive treatment for this type of condition, was proposed to the owners, but they refused, pointing out that the malformation was not causing any alteration in the ferret's activity attributable to unilateral deafness. The subject was then followed regularly and today, more than a year after the initial diagnosis, its life

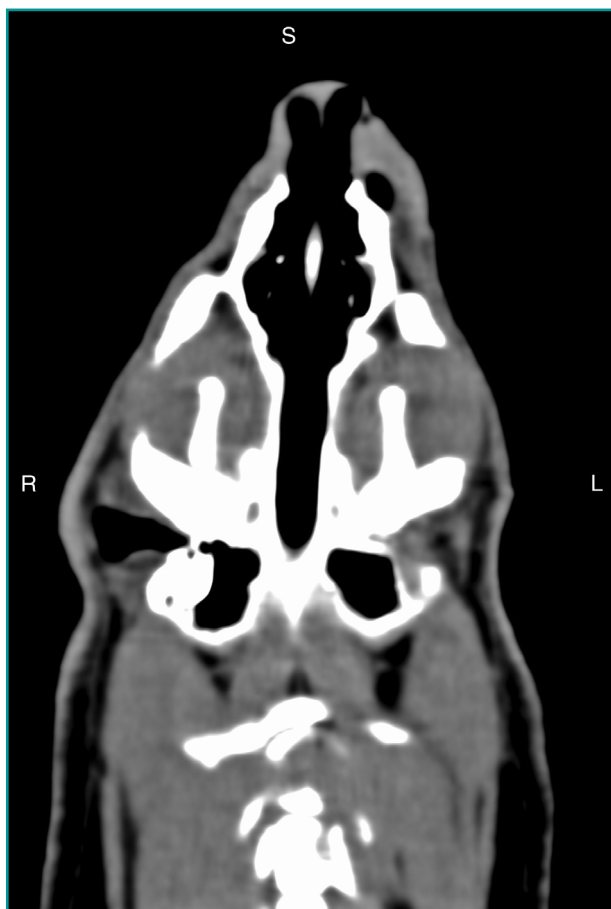

Figure 2 - The CT scan shows the lack of formation of the external acoustic meatus starting from the tympanic bulla of the left ear.

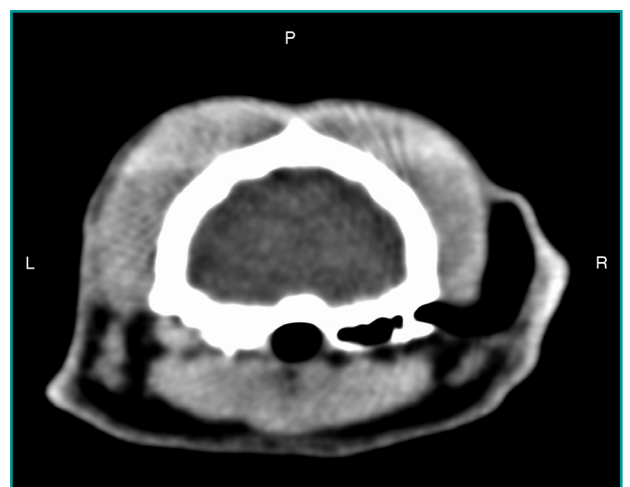

Figure 3 - CT scan from which it is possible to detect the lack of formation of the left external acoustic meatus.

is entirely comparable to that of a totally healthy ferret, with no limitations or handicaps.

DISCUSSION

In animals, atresia of the external auditory canal is an uncommon occurrence^{1,2,5,6,7,8}. In the present clinical case, the young age of the subject, the absence of the external auditory meatus at physical examination and the absence of lesions in the auricular region were immediately suggestive of a congenital disorder.

The ear, the sensory organ associated with hearing and balance in vertebrates, is made up of three distinct constituent parts: the outer ear, the middle ear and the inner ear.

Each of these constituent parts has a different embryological origin. The outer ear, in particular, whose function is to direct sounds towards the middle ear, derives from the first pharyngeal groove,^{6,9} the brachial cleft according to Barone.¹⁰ The ectodermal cells, located in the terminal end of the first pharyngeal groove, proliferate, forming a solid epithelial cord, the meatal plug. This plug persists for most of the fetal period; it then undergoes lysis during the perinatal period and in the dog it usually opens at 6-14 days.¹¹ At this point, the cord canalizes itself and the external acoustic meatus is formed. At the terminal end of the canal, in correspondence with the tympanic cavity, the external portion of the tympanic membrane differentiates itself,¹² separating it from the middle ear.

Macroscopically, the outer ear is inserted dorsocaudally to the temporomandibular joint, centred on the acoustic meatus and characterized in domestic mammals by the presence of a raised pinna, or auricle, inserted on the conduit of this meatus. The external acoustic meatus extends from the fundus of the concha to the tympanic membrane and is formed by two parts: the cartilaginous external acoustic meatus placed laterally and the bony external acoustic meatus placed medially.¹¹

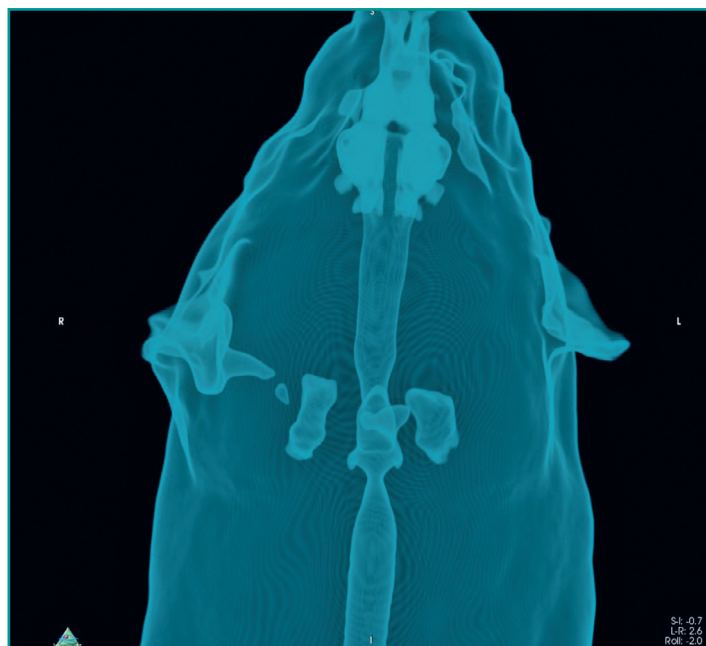


Figure 4 - Volume rendering image for the reconstruction of gas-containing structures with the evident absence of the left external auditory canal.

The use of computer tomography (CT) for the study of the external auditory canal is described not only in the dog^{1,2,5,13} and in the cat^{8,13} but also in the lama,¹⁴ and is also used for establishing the degrees of atresia or agenesis of the duct itself;⁴ in addition, recent volume rendering programs (figures 4 and 5) have allowed new diagnostic possibilities.

The outer ear is inserted dorsocaudally to the temporomandibular joint. Embryologically, it derives from the first pharyngeal groove and its function is to direct sounds towards the middle ear.

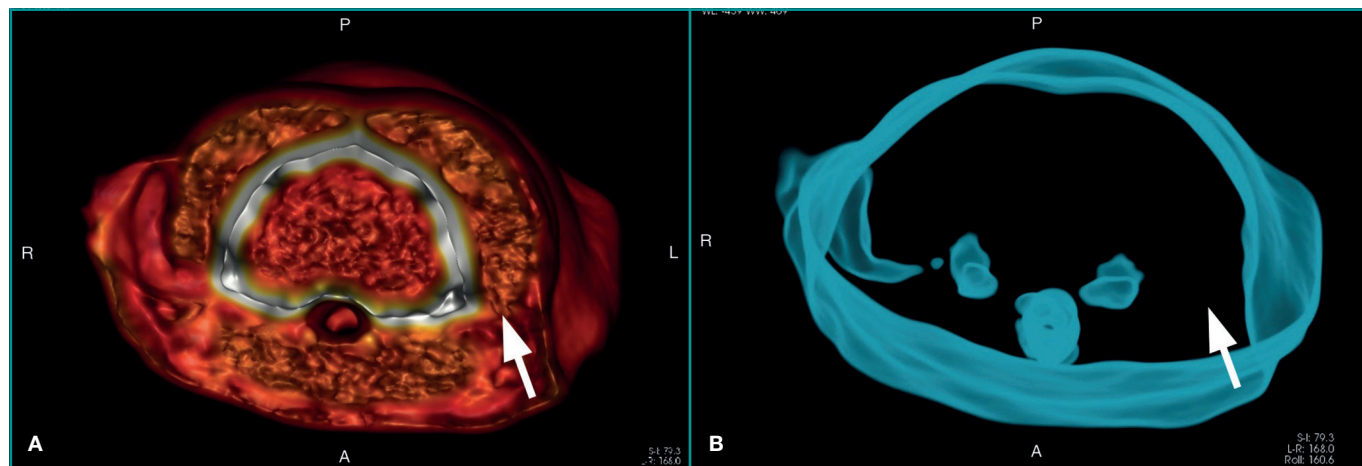


Figure 5 - Volume rendering image which highlights aplasia of the left external acoustic meatus (arrow).

In this case, CT scans performed without contrast medium showed the absence of the left EAC and the normal conformation of the tympanic bullae, which appeared free from the accumulation of pathological material.

The fact that an intravenous contrast agent was not used is a limitation of the study: its use would have allowed

a better evaluation of the soft tissues. However, it was not considered to be indispensable, as already with the non-contrast CT scans the total absence of both the vertical and the horizontal canal of the EAC was evident. In conclusion, this study presents the first confirmed and reported case of EACA in a ferret.

KEY POINTS

- The term atresia, when referred to the external auditory canal (EACA), refers to all congenital or acquired abnormalities that lead to its closure or absence.
- In humans, the incidence of EACA is of about 1 case per 10,000-20,000 births; in dogs and cats the incidence is unknown and in the ferret it has never been previously reported.
- Acquired causes of EACA include traumas, neoplasms, abscesses, haematomas and foreign bodies.
- For a correct diagnosis of EACA CT is the preferred diagnostic technique.
- The only resolute treatment is surgery.

REFERENCES

1. Béraud R. Surgical management of 2 different presentations of ear canal atresia in dogs. *Canadian Veterinary Journal* 53: 412-418, 2012.
2. Schmidt K, Piaia T, Bertolini G, et al. External auditory canal atresia of probable congenital origin in a dog. *Journal of Small Animal Practice* 48: 233-236, 2007.
3. Tassano E, Jagannathan V, Drögemüller C, et al. Congenital aural atresia associated with agenesis of internal carotid artery in a girl with a FOXI3 deletion. *American Journal of Medical Genetics Part A* 167A: 537-544, 2015.
4. Jafek BW, Nager GT, Strife J, et al. Congenital aural atresia, an analysis of 311 cases. *Transactions. Section on Otolaryngology American Academy of Ophthalmology and Otolaryngology* 80:588-595, 1975.
5. Anwer C, Schwarz T, Volk SW, et al. BAER testing in a dog with bilateral external ear canal atresia. *Journal of the American Animal Hospital Association* 47: 370-374, 2011.
6. Caine AR, Herrtage ME, Ladlow JF. Imaging diagnosis--ear canal distension following external auditory canal atresia. *Veterinary Radiology & Ultrasound* 49: 267-269, 2008.
7. Simpson D. Atresia of the external acoustic meatus in a dog. *Australian Veterinary Journal* 75:18-20, 1997.
8. Coomer AR, Bacon N. Primary anastomosis of segmental external auditory canal atresia in a cat. *Journal of Feline Medicine and Surgery* 11:864-868, 2009.
9. McGeady TA, Quinn PJ, Fitzpatrick ES, et al. Chapter 21: eye and ear. In: *Veterinary embryology*, 1st ed. Hoboken, Blackwell publishing 2006, 295-312.
10. Barone R, Simoens P. Orecchio. In *Anatomia comparata dei mammiferi domestici*. Vol. 7 Neurologia. Milano: Edagricole, 2012, pp. 635-708.
11. Sturgess K. Chapter 14: infectious diseases of young puppies and kittens. In: Simpson G, England GCW, Harvey M. (eds): *BSAVA manual of small animal reproduction and neonatology*, 1st ed. BSAVA publishing, 1998;159-169.
12. Pelagalli GV, Castaldo L, Lucini C, et al. Cap. 18 Sviluppo dell'apparato acustico. In: *Embriologia, morfogenesi e anomalie dello sviluppo*. Napoli: Idelson-Gnocchi, 2009, pp. 219-225.
13. Garosdi LS, Dennism R, Schwarz T. Review of diagnostic imaging of ear diseases in the dog and cat. *Veterinary Radiology Ultrasound* 44:137-146, 2003.
14. Concha-Albornoz I, Stieger-Vanegas SM, Cebra CK. Computed tomographic features of the osseous structures of the external acoustic meatus, tympanic cavity, and tympanic bulla of llamas (*Lama glama*). *American Journal of Veterinary Research* 73: 42-52, 2012.