



Original Article

Investigation of the treatment of sand accumulations in the equine large colon with psyllium and magnesium sulphate

K.E. Niinistö*, M.O. Ruohoniemi, F. Freccero¹, M.R. Raekallio

Department of Equine and Small Animal Medicine, Faculty of Veterinary Medicine, P.O. Box 57, 00014 University of Helsinki, Finland

ARTICLE INFO

Article history:

Accepted 8 June 2018

Keywords:

Equine
Geosediment
Nasogastric tubing
Plantago ovata
Sand

ABSTRACT

Enteropathy associated with sand accumulation in the large colon of horses has been reported worldwide. Intestinal sand accumulations are commonly treated medically, but randomised controlled clinical trials on horses are scarce. This prospective study evaluated the efficacy of an enterally administered combination of psyllium and magnesium sulphate (MgSO₄) for the removal of large colonic sand accumulations in horses without clinical signs of acute colic. The two groups comprised 20 untreated control horses and 20 horses treated with 1 g/kg bodyweight (bwt) of psyllium and 1 g/kg bwt of MgSO₄ administered by nasogastric intubation once daily for 4 days.

Both groups had no access to soil during the study period. The amounts of accumulated sand were evaluated radiographically before and after treatment. Significantly more treated horses cleared their sand accumulations than horses in the control group. This clearance was determined by observing the estimated quantity by area of sand remaining in the large colon ($P < 0.001$) and by comparing the numbers of successfully treated horses ($P = 0.004$) between the two groups after 4 days of treatment. However, there were unexplained individual variations in the clearance of sand accumulation.

© 2018 The Author(s). Published by Elsevier Ltd. This is an open access article under the CC BY license (<http://creativecommons.org/licenses/by/4.0/>).

Introduction

Enteropathy associated with sand accumulation in the large colon of horses has been reported worldwide. Even though medical (Ruohoniemi et al., 2001; Hart et al., 2013; Niinistö et al., 2014; Kaikkonen et al., 2016) and surgical removal of sand (Specht and Colahan, 1988; Ragle et al., 1989, 1992; Granot et al., 2008; Kilcoyne et al., 2017) has been described both in clinical cases (Ruohoniemi et al., 2001; Hart et al., 2013; Kaikkonen et al., 2016) and experimentally (Hammock et al., 1998; Hotwagner and Iben, 2008; Landes et al., 2008), randomised controlled clinical trials are lacking.

Currently, the most commonly used medical treatments for removing sand accumulations include psyllium mucilloid (*Plantago ovata*; hereafter 'psyllium'), magnesium sulphate (MgSO₄) and combinations of these products (Colahan, 1987; Ruohoniemi et al., 2001; Hart et al., 2013; Niinistö et al., 2014; Kaikkonen et al., 2016). The efficacy of administering mineral oil alone has been challenged (Rakestraw, 2012), but it has been described in combination with

other treatments (Colahan, 1987; Hotwagner and Iben, 2008; Blikslager, 2010; Hart et al., 2013). One experimental study has questioned the efficacy of psyllium (Hammock et al., 1998), but later studies have demonstrated its usefulness for resolving naturally occurring intestinal sand accumulations (Ruohoniemi et al., 2001; Hart et al., 2013; Niinistö et al., 2014; Kaikkonen et al., 2016). A recent retrospective study reported on the efficacy of repeated nasogastric tubing with psyllium and/or MgSO₄, compared with orally administering psyllium (Kaikkonen et al., 2016) and another study suggested beneficial effects of combining psyllium with MgSO₄ for the removal of intestinal sand accumulations, but this study lacked an untreated control group (Niinistö et al., 2014).

Radiography is a two-dimensional method and therefore cannot precisely assess the exact quantity of sand in the intestine, but researchers have used this modality to diagnose sand accumulations and to estimate the relative amount of sand in the colon of horses (Kaikkonen et al., 2000; Ruohoniemi et al., 2001; Korolainen and Ruohoniemi, 2002; Kendall et al., 2008; Keppie et al., 2008; Hart et al., 2013; Niinistö et al., 2014; Kaikkonen et al., 2016). The estimated amount of sand has been evaluated radiographically as the area of accumulated sand (Niinistö et al., 2014), as the length and height of the accumulation (Ruohoniemi et al., 2001; Korolainen and Ruohoniemi, 2002; Kendall et al., 2008; Keppie et al., 2008), or by grading the amount

* Corresponding author.

E-mail address: kati.niinisto@helsinki.fi (K.E. Niinistö).¹ Current address: Department of Veterinary Medical Sciences, University of Bologna, Via Tolara di Sopra 50, Ozzano dell'Emilia, 40064, Bologna, Italy.

of sand compared to the colonic lumen (Hart et al., 2013). Furthermore, radiography has been useful in monitoring the resolution of sand accumulations (Ruohoniemi et al., 2001; Hart et al., 2013; Niinistö et al., 2014).

The aim of this randomised controlled clinical trial was to compare the efficacy of an enterally administered combination of psyllium and $MgSO_4$ for the removal of sand accumulations from the large colon of horses to that of untreated controls, as determined by radiography. The radiographic appearance of the sand accumulation was also investigated.

Materials and methods

Horses

The study was approved by the National Medicines Agency (Vetkl-no 03/04) and by the local ethical committee of the University of Helsinki (29 November 2011; Approval number 04/2011). Informed consent was obtained from the owners prior to enrolment in the study.

Horses were admitted to the hospital as clinical cases with suspected sand-related problems or referred from other clinics because of sand accumulation. A faecal sand sedimentation test was not performed on admission. All horses were examined clinically and had a complete blood count and a routine serum panel for screening of possible systemic diseases. The cranioventral abdomen was radiographed by a computed radiography system (maximum tube voltage 131 kV, current 80 mAs) using a right-to-left standing lateral view and viewed using dedicated software (JiveX, VISUS Technology Transfer). Horses were sedated with detomidine ($10 \mu\text{g}/\text{kg}$ bodyweight [bwt] IV, Domosedan, Orionpharma Animal Health) when needed.

If there was more than 100 cm^2 of sand in the large colon (area of geosediment type of opacity) based on radiography (Figs. 1 and 2), the horse owners were offered the opportunity to take part in the study. Small ponies and miniature horses (body mass $<300 \text{ kg}$) and horses younger than 1 year were excluded. Horses were also excluded from the study if they manifested clinical signs of acute (severe) colic at the time of presentation, if they had been administered laxatives ($MgSO_4$, psyllium, or paraffin oil) within 24 h prior to admission, or if they had a serum total magnesium concentration $>1.20 \text{ mmol/L}$ or a creatinine concentration $>170 \mu\text{mol/L}$.

Treatment and control groups

Forty horses met the selection criteria and were randomly assigned to the two study groups, using simple randomisation by drawing lots. The treatment group underwent nasogastric intubation and were administered $1 \text{ g}/\text{kg}$ bwt psyllium (Vi-Siblin, Pfizer) and $1 \text{ g}/\text{kg}$ bwt $MgSO_4$ daily ($n=20$). The control group received no medical treatment ($n=20$). The attending veterinarians were aware of which group each horse was assigned to, but the owners were masked to group allocation. All medications were mixed with water ($15 \text{ mL}/\text{kg}$), administered once daily (between 8.00–10.00 am) via nasogastric intubation for 4 days (i.e. four treatments). Both study groups had no access to soil during the study period. Water and timothy hay




Fig. 2. Radiograph of the abdomen of a horse (left cranial) showing one of the smallest sand accumulations at the beginning of the study (area 109 cm^2).

were available ad libitum. However, hay was withheld at the discretion of the treating veterinarian when clinical signs of abdominal discomfort were observed. Horses were allowed access to a concrete floored enclosure. Alternatively, horses were hand-walked, according to owners' preference. Monitoring included physical examination three times daily. Criteria for withdrawing the horse from the study were as follows: (1) clinical signs of colic (abdominal discomfort that did not resolve with a single dose of non-steroidal anti-inflammatory medication); (2) profuse diarrhoea; or (3) the owner decided to withdraw the horse from the study.

Radiographic data

Abdominal radiographs were repeated in the afternoon of day 4 after enrolment in the study. When the radiographically determined area of sand was $<25 \text{ cm}^2$ (Fig. 3), or if there was no longer evidence of sand accumulation, sand accumulation was considered resolved (Niinistö et al., 2014). Horses were either discharged from the hospital upon completion of the study protocol, or the treatment was continued as needed. Cases presenting with persistent sand accumulation received three additional treatments (days 5 to 7) and were re-radiographed on the afternoon of day 7 (post-study radiograph). On completion of the study period, owners of untreated control horses were subsequently offered treatment for their horses if the sand accumulation had not resolved at day 4, as indicated by the post-treatment radiograph. Any unresolved cases from the control group were medicated four times (days 4 to 7), as per the study treatment group.

The first author monitored the horses clinically and evaluated the sand area in each radiograph on the day of the examination, according to a previously described




Fig. 1. Radiograph of the abdomen of a horse (left cranial) showing a large accumulation of sand in which the outer edges could not be precisely measured. Only the area seen in the radiograph was measured (391 cm^2).

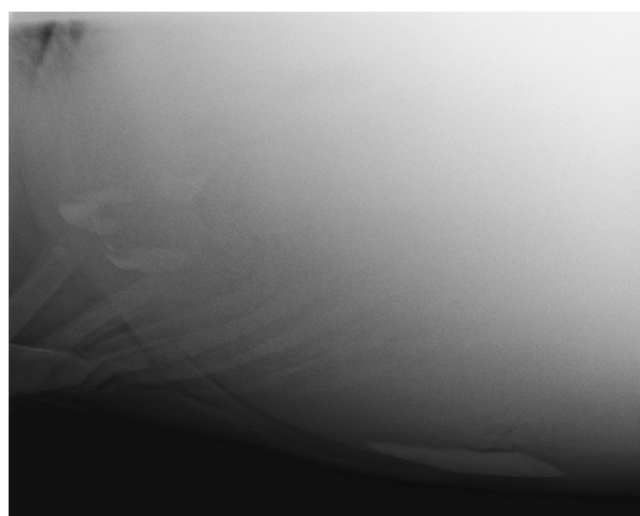


Fig. 3. Radiograph of the abdomen of a horse (left cranial) showing an example of sand accumulation that was classified as resolved (area 21 cm^2).

Table 1

Breed, age (mean ± standard deviation), body mass (mean ± standard deviation) and sex of horses in the treatment and control groups.

Horses	Control group (n=20)	Treatment group (n=20)	
Breed (n)	12 Finnhorses, 2 Icelandic horses, 2 Warmblood horses, 4 Ponies	8 Finnhorses, 5 Icelandic horses, 5 Warmblood horses, 2 Ponies	
Age	8.5 ± 4.5 years	9.8 ± 5.7 years	P=0.409
Body mass	492 ± 106 kg	493 ± 109 kg	P=0.987
Sex	9 Mares, 11 geldings	14 Mares, 6 geldings	P=0.245

method (Niinistö et al., 2014). Large accumulations cannot always be completely visualised radiographically (Ruohoniemi et al., 2001). Consequently, only the most cranioventral radiograph was used to estimate the area of sand accumulation. This view was available from all horses and showed the relative size of the accumulation (Fig. 1). In cases of multiple discrete accumulations (Fig. 3), areas were summed. After all horses had been treated, radiographs were also evaluated by the second author, who was masked to horse, date and treatment allocation. To detect changes during the study, the height and length of the accumulations were measured, their homogeneity was graded (1 = even opacity, 2 = varying opacity, 3 = non-homogeneous, mixed with other intestinal contents), the base of the accumulation was graded (1 = flat, with or without sacculations, 2 = rounded, 3 = pointed), and the shape and location of the accumulation was recorded using drawings and written notes. In the case of discordancy between the measurements of the first and second authors, the corresponding radiographs were re-evaluated, and a consensus was reached.

Statistical analysis

When calculating the sample size, we considered differences between treatments to be clinically relevant if at least 75% of the treated horses and no more than 25% of the control horses were resolved by day 4. In that case, 16 horses per group were needed to attain the 5% type I error rate (α) and a power of 90% in a two-tailed analysis.

Horse age, body mass and sex were compared between groups using unpaired *t* tests and Fischer's exact tests. The height and length of the sand accumulations were compared between groups using Mann–Whitney *U* tests. The areas of the sand accumulations in the large colon were compared between groups before treatment and at day 4 using Mann–Whitney *U*-tests. Two-sided Fisher's exact tests were used to compare the number of resolved cases between groups on day 4. For all statistical analysis, SPSS (IBM) statistical software was used. *P*-values of <0.05 were considered to be statistically significant.

Results

Detailed information for all horses is presented in Table 1. Both study groups contained horses from similar breeds, and there were no statistically significant differences in age, body mass or sex between the groups.

The area of the sand accumulation did not significantly differ between groups at the start of the treatment (Table 2), nor did the height ($P=0.881$) or length ($P=0.091$) of the accumulations. The homogeneity and appearance of the base of the accumulations is shown in Table 3. The small number of resolved cases in the control group and unresolved cases in the treatment group precluded statistical analysis of the association between the final outcome

Table 2

Results of horses with colonic sand accumulations after 4 days of treatment by daily nasogastric administration of a combination of psyllium and MgSO₄ vs. the untreated control horses, with sand area (cm²) expressed as median (range).

	Control (n=20)	Treatment (n=20)
Initial sand area	285 (128–665)	250 (109–710)
Sand area on day 4	176 (0–558) ^a	0 (0–336) ^a
Number of resolved horses (<25 cm ²) on day 4	4/20 ^b	15/20 ^b
Number of horses treated further during days 4–7	15	4
Sand area on day 4 in horses treated further	217 (66–558)	106 (60–159)
Sand area on day 7 in horses treated further	19 (0–398)	72 (30–105)
Number of resolved horses (<25 cm ²) on day 7	9/15	0/4

^a Significant difference between groups, $P<0.001$

^b Significant difference between groups, $P=0.004$

Table 3

Radiographically evaluated homogeneity and appearance of the base of the sand accumulation in the treatment and control groups at the start of the study, and the number of resolved accumulations in both groups at day 4 (brackets).

	Control (n=20)	Treatment (n=20)
Homogeneity of the accumulation		
Even opacity	12 (0)	10 (7)
Varying opacity	7 (4)	7 (6)
Non-homogenous	1 (0)	3 (2)
Total	20 (4)	20 (15)
Base of the accumulation		
Flat	14 (1)	16 (12)
Rounded	6 (3)	3 (2)
Pointed	–	1 (1)
Total	20 (4)	20 (15)

and the initial height, length and homogeneity of the accumulation and the appearance of its base.

None of the horses were withdrawn during the study. All horses tolerated the treatment well, and no adverse effects were observed. Some treated horses developed mild softening of the faeces, but no diarrhoea was detected. Four horses required a single dose of flunixin meglumine (1.1 mg/kg bwt IV) during the study (one because of fever and the other three for alleviation of mild abdominal discomfort). One horse in the control group received flunixin meglumine on the first day of the study but did not require further medication during the treatment phase. Three of the four horses that received flunixin meglumine cleared the sand within 4 days of treatment. Most horses in both groups required sedation for radiography, but this did not appear to affect the clearance of sand. Two horses in the treatment group also required sedation for nasogastric tubing, but in both cases, the accumulation was resolved during the 4-day study period.

Treatment group

The treated horses cleared their sand accumulations significantly better than horses in the control group, as indicated by the reduction in the relative size of the area of sand, based on the radiographs and by the number of horses with resolved sand accumulations on day 4 (Table 2). The sand accumulation in 15/20 (75%) horses resolved with 4 days of treatment (Table 2). Additionally, in one horse, sand accumulation was not resolved but it decreased markedly in size and radiographically; the sand appeared to be mixed with other intestinal contents. That horse was discharged from the hospital with a recommendation of further oral treatment with psyllium.

In the remaining four horses, the treatment was continued for 3 additional days. On day 4, the height of the sand accumulations in all four horses was approximately 8 cm, and the length varied between 26 and 36 cm. The amount of sand diminished in all four horses and all accumulations fragmented into smaller

accumulations during the continued treatment. However, none of these horses had completely cleared the sand by day 7 (Table 2). In all four horses, the height of the accumulation remained between 5 and 8 cm and the length remained between 7 and 27 cm. The shape of the accumulation changed in three horses, but remained the same in one horse.

Control group

Four horses in the control group had cleared the sand accumulation by day 4 without any treatment except for interruption of sand intake (Table 2). All these accumulations were initially relatively high (10–17 cm) and their length varied between 16 and >41 cm.

In 10 horses, the size of the sand accumulation on day 4 was decreased; in two horses, it remained approximately the same; in four horses, the accumulation became larger. One of the latter horses received treatment for 2 days but was discharged from the clinic before the radiograph was taken on day 7, as the accumulation had already changed shape and started to mix with other intestinal contents based on the radiograph taken on day 4.

After completion of the study period, 15 control horses were treated according to the same protocol as the initial treatment group (Table 2). On day 7, the sand accumulations in 9/15 horses (60%) had resolved. The accumulations in the six remaining horses diminished (markedly in three horses and only negligibly in the other three horses) and the shape of the accumulations had also changed.

Discussion

This study demonstrated that treating colonic sand accumulation in horses with daily nasogastric tubing of a combination of psyllium (1 g/kg bwt) and MgSO₄ (1 g/kg bwt) for 4 days resolved the sand accumulation or reduced its relative size significantly more than no treatment.

In addition to the laxative effect attributed to its fibre content, psyllium stimulates the intestine partially by muscarinic and 5-HT₄ receptor activation (Mehmood et al., 2011). However, psyllium may also inhibit intestinal motility by blocking Ca²⁺ channels and activating NO-cyclic guanosine monophosphate pathways (Mehmood et al., 2011). These antagonistic effects of psyllium on intestinal motility could explain the lack of or the delayed effect in some horses in this study, similar to an earlier study (Hammock et al., 1998). Psyllium is a simple bulk laxative (Boothe and Jenkins, 1995), whereas MgSO₄ acts as an osmotic cathartic that accumulates water in the intestine and enhances intestinal motility (Freeman et al., 1992). The combination of these mechanisms could explain the efficacy of the psyllium and MgSO₄ combination in our study, and its superiority to psyllium alone, which was demonstrated in a previous study (Niinistö et al., 2014).

Some of the control horses spontaneously cleared the ingested sand accumulation when they had no access to soil. The mechanism by which sand clearance occurs solely when access to the source is denied is still unclear, but it is possible that normal colonic motility is sufficient to remove the sand. Additionally, most of the control horses that did not clear the sand subsequently responded well to nasogastric tubing of psyllium and MgSO₄. It has been suggested that nasogastric administration of water alone could be enough to promote sand removal, but in clinical cases, nasogastric tubing with plain water is not recommended for large sand accumulations. Hammock et al. (1998) did not observe a difference in sand removal, regardless of whether psyllium was fed or administered with a nasogastric tube. Additionally, treatment with MgSO₄ mixed with water (Niinistö et al., 2014) was not as efficient as the combination used in the present study. None of the

non-responders in the treatment group had fully resolved their sand accumulation even after the treatment had been prolonged for 3 additional days, even though the accumulation had decreased in size somewhat in these horses. Presumably, these horses either had abnormal colonic motility or a more compact sand accumulation and therefore did not respond as well to therapy.

Individual horse outcome could not be predicted by the size or appearance of the initial accumulation, as reported previously (Ruohoniemi et al., 2001). The individual differences could be due to variations in ingested soil types, the duration of the accumulation, or intestinal movements and the activity of colonic pacemakers (Fintl et al., 2004). The exact quantity of sand that causes clinical signs cannot be determined, but horses with colic attributed to sand accumulation have been reported to have larger median sand accumulations (9 cm height × 26.5 cm length) than controls that did not manifest clinical signs (0.9 cm height × 8.3 cm length; Kendall et al., 2008). It is plausible that larger sand accumulations would take longer to resolve. Surprisingly, in this study, accumulations ≤10 cm high seemed to be more difficult to resolve, possibly because their small size allowed the passage of other intestinal contents.

The actual texture of the accumulation can rarely be determined from radiographs, unless the accumulation is comprised of mixed gravel, which has a characteristic coarse appearance. Attempts to increase the objectivity of radiographic assessment have included grading the opacity and the homogeneity of the accumulations (Kendall et al., 2008; Keppie et al., 2008).

Radiography has its limitations when used for the evaluation of total amounts of sand accumulation. For example, we noted that although sand was moving, some horses seemed to have a larger area of sand accumulation in the post-treatment radiograph than in the baseline radiograph, despite treatment and lack of access to sand. A possible explanation is the relocation of ingested sand previously accumulated anterior to the large colon in response to partial clearing of sand accumulations in the large colon. This relocation of sand may result in no net resolution of the accumulation radiographically, as reported earlier (Ruohoniemi et al., 2001). Another challenge may be the effect of sand accumulation in the left vs. right ventral colon, and the correspondingly different magnification effects in abdominal radiographs. It is considered unlikely that this caused any clinically relevant measurement effects, because magnification was probably only minor compared with the magnitude of the reduction of sand area in cases considered resolved.

Conclusions

This study demonstrated that medical treatment of horses with sand accumulation in the large colon by daily nasogastric tubing of a combination of psyllium (1 g/kg bwt) and MgSO₄ (1 g/kg bwt) for 4 days resolved the sand accumulation more efficiently than only preventing access to soil. However, in some horses, sand accumulations did not fully resolve, even after continuation of medication for 7 days, although the area of the sand accumulation decreased by at least 50%.

Conflict of interest statement

None of the authors has any financial or personal relationships that could inappropriately influence or bias the content of the paper.

Acknowledgements

We would like to thank all referring veterinarians for helping us to enrol sufficient clinical patients in this study. Ben Sykes is

thanked for the original research idea. The Foundation for Veterinary Research (Finland) provided financial support for the study materials.

References

- Blikslager, A.T., 2010. Sand impactions of the large colon. In: Reed, S.M., Bayly, W.M., Sellon, D.C. (Eds.), *Equine Internal Medicine*. Third Ed. Saunders Elsevier St Louis, MO, USA p. 890.
- Boothe, D.M., Jenkins, W., 1995. Gastrointestinal function. In: Adams, H.R. (Ed.), *Veterinary Pharmacology and Therapeutics*. Seventh Ed. Iowa State University Press, Ames, USA, pp. 1020–1021.
- Colahan, P., 1987. Sand colic. In: Robinson, N.E. (Ed.), *Current Therapy in Equine Medicine*. Second Ed. Saunders, Philadelphia, PA, USA, pp. 55–58.
- Fintl, C., Hudson, N.P.H., Mayhew, I.G., Edwards, G.B., Proudman, C.J., Pearson, G.T., 2004. Interstitial cells of Cajal (ICC) in equine colic: an immunohistochemical study of horses with obstructive disorders of the small and large intestines. *Equine Veterinary Journal* 36, 474–479.
- Freeman, D.E., Ferrante, P.L., Palmer, J.E., 1992. Comparison of the effects of intragastric infusions of equal volumes of water, dioctyl sodium sulfosuccinate, and magnesium sulphate on fecal composition and output on clinically normal horses. *American Journal of Veterinary Research* 53, 1347–1353.
- Granot, N., Milgram, J., Bdolah-Abram, T., Steinman, A., 2008. Surgical management of sand colic impactions in horses: a retrospective study of 41 cases. *Australian Veterinary Journal* 86, 404–407.
- Hammock, P.D., Freeman, D.E., Baker, G.J., 1998. Failure of psyllium mucilloid to hasten evacuation of sand from the equine large intestine. *Veterinary Surgery* 27, 547–554.
- Hart, K.A., Linnenkohl, W., Mayer, J.R., House, A.M., Gold, J.R., Giguere, S., 2013. Medical management of sand enteropathy in 62 horses. *Equine Veterinary Journal* 45, 465–469.
- Hotwagner, K., Iben, C., 2008. Evacuation of sand from the equine intestine with mineral oil, with and without psyllium. *Journal of Animal Physiology and Animal Nutrition* 92, 86–91.
- Kaikkonen, R., Raekallio, M., Luukkanen, L., Ruohoniemi, M., 2000. Radiographic appearance of sand accumulations in the large colon and their relationships with age, breed and clinical signs of the horse. *Suomen Eläinlääkärilehti* 106, 16–22.
- Kaikkonen, R., Niinistö, K., Lindholm, T., Raekallio, M., 2016. Comparison of psyllium feeding at home and nasogastric intubation of psyllium and magnesium sulfate in the hospital as a treatment for naturally occurring colonic sand (geosediment) accumulations in horses: a retrospective study. *Acta Veterinaria Scandinavica* 58, 73.
- Kendall, A., Ley, C., Egenvall, A., Bröjer, J., 2008. Radiographic parameters for diagnosing sand colic in horses. *Acta Veterinaria Scandinavica* 50, 17.
- Keppie, N.J., Rosenstein, D.S., Holcombe, S.J., Schott II, H.C., 2008. Objective radiographic assessment of abdominal sand accumulation in horses. *Veterinary Radiology and Ultrasound* 49, 122–128.
- Kilcoyne, I., Dechant, J.E., Spier, S.J., Spriet, M., Nieto, J.E., 2017. Clinical findings and management of 153 horses with large colon sand accumulations. *Veterinary Surgery* 46, 860–867.
- Korolainen, R., Ruohoniemi, M., 2002. Reliability of ultrasonography compared to radiography in revealing intestinal sand accumulations in horses. *Equine Veterinary Journal* 34, 499–504.
- Landes, A.N., Hassel, D.M., Funk, J.D., Hill, A., 2008. Fecal sand clearance is enhanced with a product combining probiotics, prebiotics, and psyllium in clinically normal horses. *Journal of Equine Veterinary Science* 28, 79–84.
- Mehmood, M.H., Aziz, N., Ghayur, M.N., Gilani, A.H., 2011. Pharmacological basis for the medicinal use of psyllium husk (Ispaghula) in constipation and diarrhea. *Digestive Diseases and Sciences* 56, 1460–1471.
- Niinistö, K., Hewetson, M., Kaikkonen, R., Sykes, B.W., Raekallio, M., 2014. Comparison of the effects of enteral psyllium, magnesium sulphate and their combination for removal of sand from the large colon of horses. *Veterinary Journal* 202, 608–611.
- Ragle, C., Meagher, D., Lacroix, C., Honnas, C., 1989. Surgical treatment of sand colic: Results in 40 horses. *Veterinary Surgery* 18, 48–51.
- Ragle, C., Schrader, J., Meagher, D., Honnas, C., 1992. Surgical treatment of colic in American Miniature horses: 15 cases (1890–1987). *Journal of American Veterinary Medical Association* 201, 329–331.
- Rakestraw, P., 2012. Sand impaction. In: Auer, J.A., Stick, J.A. (Eds.), *Equine surgery*. Fourth Ed. Elsevier, St. Louis, Missouri, USA, pp. 467–469.
- Ruohoniemi, M., Kaikkonen, R., Raekallio, M., Luukkanen, L., 2001. Abdominal radiography in monitoring the resolution of sand accumulations from the large colon of horses treated medically. *Equine Veterinary Journal* 33, 59–64.
- Specht, T.E., Colahan, P.T., 1988. Surgical treatment of sand colic in equids: 48 cases (1978–1985). *Journal of American Veterinary Medical Association* 193, 1560–1564.