

## A rare case of nasal osteoma in a dog: a case report

G. GALIAZZO, M. PIETRA\*, D. TINTO, N. LINTA, M. MORINI, O. CAPITANI

University of Bologna, Bologna, Italy

\*Corresponding author: marco.pietra@unibo.it

**ABSTRACT:** A 35-month-old female German shepherd weighing 33.2 kg was referred to our department with a 10-month history of sneezing and left nasal swelling. On clinical examination, the dog showed deformity of the left nasal plane in the absence of any cutaneous lesions or nasal discharge, and presented with nasal snoring noises during both the inspiratory and expiratory phases. The patency of nasal cavities was evaluated using the cotton swab test, and was found to be preserved only on the right side. Endoscopic, radiographic and computed tomographic examination revealed an osteoproliferative lesion that distorted the nasal, maxillary and frontal bones, completely occupying the left nasal cavity and frontal sinuses, resulting in destruction of the nasal septum and invasion of the contralateral nasal cavity. Five biopsic samples of the mass were collected from the cutaneous surface using a 9G Jamshidi bone marrow biopsic instrument. Histologically, the lesion consisted of a non-encapsulated, multilobulated mass composed of dense coalescing trabeculae of well-differentiated bone, which was lined by osteogenic cells. The morphology was suggestive of nasal osteoma. Due to the large size of the mass, evidenced by computed tomography, chronic systemic nonsteroidal anti-inflammatory treatment with carprofen was proposed instead of surgery. The description of this case is useful for veterinarians, who should consider osteoma as a possible differential diagnosis for nasal tumours.

**Keywords:** nasal neoplasia; computed tomography; endoscopy

In dogs, primary bone tumours are usually malignant, and benign tumours are rare (Dobson and Morris 2001). Osteoma is an uncommon benign tumour composed of abnormally dense, but histologically normal, mature bone originating from the periosteal surface. Osteomas typically involve the bones of the skull and mandible (Misdorp and Van Der Heul 1976; Pool 1990; Dernell et al. 2007).

Due to the rare nature of this tumour, the precise incidence of osteoma in dogs by age, breed and sex remain unknown. It usually affects adult dogs, although a few cases have also been reported in younger dogs (Ling et al. 1974; Volker and Luskin 2014).

Osteoma is a slow-growing tumour, becoming compact and forming cortical-type osteonal bone. This tumour causes clinical symptoms if it interferes with adjacent structures, and does not undergo malignant transformation or metastasis

(Pool 1990; Woldenberg et al. 2005; Volker and Luskin 2012).

The purpose of this case report, given the low prevalence of this disease in dogs, was to describe the patient history, clinical presentation and diagnosis of a case of osteoma involving the nasal bones in a young German shepherd.

### Case description

A 35-month-old female German shepherd weighing 33.2 kg (body condition score of 5/9) that had been regularly vaccinated and dewormed was referred to our department. The owner reported a 10-month history of sneezing and left nasal swelling.

The patient history included an explorative rhinotomy six months previously, which had been performed together with a rhinoscopy by a practi-

doi: 10.17221/30/2017-VETMED

tioner. The diagnosis was subcutaneous granuloma associated with a foreign body (grass seed) localised in the left dorsal nasal meatus. No suspicion of nasal neoplasia was reported by the practitioner. There was no improvement in nasal swelling after removal of the foreign body, even with drainage and antibiotic therapy, and after some months the owner contacted our department for a second opinion.

On clinical examination, the dog showed deformity of the left nasal plane from about 3 cm from the nostril to the left eye (Figures 1A and 1B), in the absence of any cutaneous lesions or nasal discharge. These findings were associated with nasal snoring noises in both the inspiratory and expiratory phases. The patency of nasal cavities was assessed using the cotton swab test, and was found to be preserved only on the right side. The oral examination revealed no alterations of the soft or hard palate, nor any changes in the gums or teeth of the upper left side, and no enlargement of the homolateral mandibular and medial retropharyngeal lymph node was observed. No other clinical signs were reported.

Haematological and serum biochemical tests revealed only mild neutrophilia (neutrophil count  $12.29 \times 10^9/l$ , reference range [RR]  $3.0\text{--}12.0 \times 10^9/l$ ), with the white blood cell count within the normal range ( $15.11 \times 10^9/l$ , RR  $6.0\text{--}17.0$ ). There was no change in alkaline phosphatase levels ( $0.93 \mu\text{kat/l}$ , RR  $0.7\text{--}3.0 \mu\text{kat/l}$ ), corrected calcium level based

on the serum albumin level ( $2.65 \text{ mmol/l}$ , RR  $2.0\text{--}3.0 \text{ mmol/l}$ ) or phosphate levels ( $1.49 \text{ mmol/l}$ , RR  $0.84\text{--}1.58 \text{ mmol/l}$ ). The coagulation profile was normal, as were the results of faecal flotation. Testing for the presence of *Dirofilaria immitis* antigen was negative.

Further examination was performed under general anaesthesia. The patient was pre-medicated with  $0.3 \text{ mg/kg}$  body weight methadone and  $2 \mu\text{g/kg}$  body weight dexmedetomidine *i.m.*, then induced with propofol and maintained with isoflurane.

Radiographic examination of the skull was performed under general anaesthesia, and latero-lateral, ventrodorsal open-mouth, dorsoventral intra-oral and rostrocaudal skyline views were obtained. An osteoproliferative lesion that distorted the nasal, maxillar and frontal bones and completely occupied the left nasal cavity and frontal sinuses was identified. This mass had caused destruction of the nasal septum and had invaded the contralateral nasal cavity. The surrounding soft tissue appeared swollen (Figure 2). Radiological diagnosis indicated a probable neoplastic process originating from bone or cartilaginous tissue; however, as a differential diagnosis, a granulomatous mycotic process could not be ruled out. In order to exclude neoplastic metastatic lesions, thoracic radiographs were obtained, which were found to be normal.

Nasal swabs were taken for bacteriological examination, performed before the endoscopic procedure

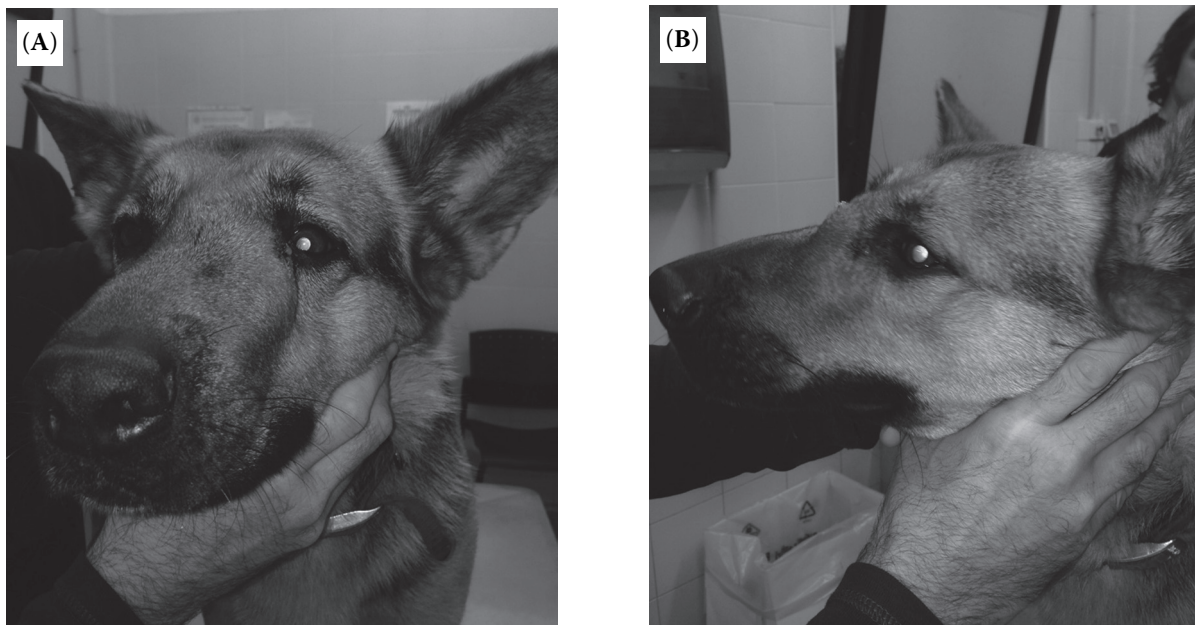


Figure 1. Dog showing deformity of the left nasal plane: rostral view (A) and lateral view (B)

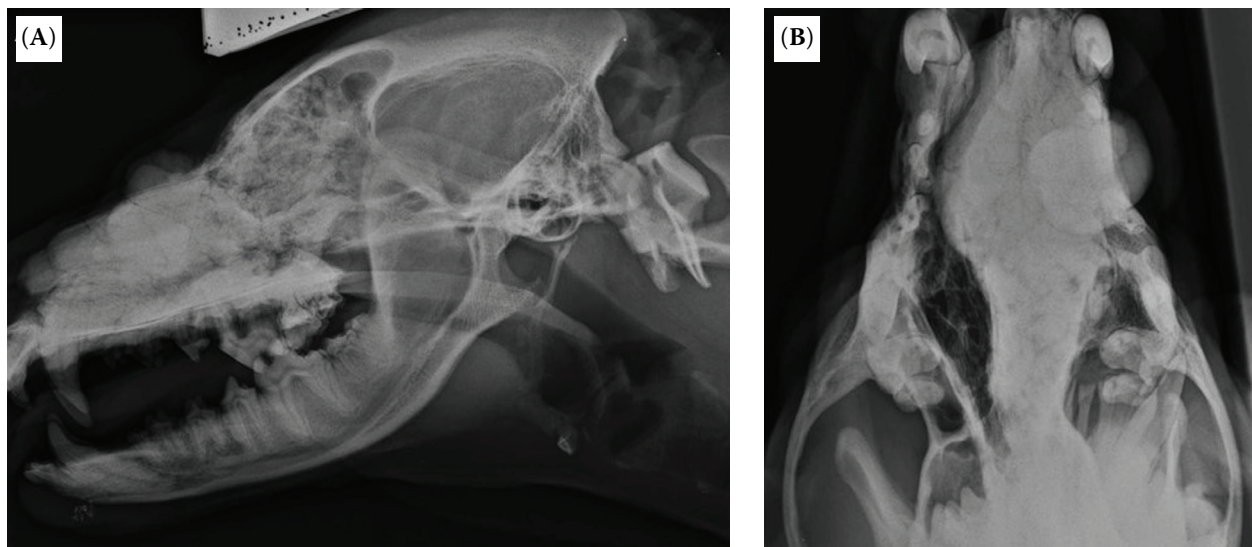


Figure 2. Latero-lateral (A) and ventrodorsal open-mouth (B) radiography of the skull. The image shows the presence of an area with calcific radiopacity that distorts the nasal, maxillary and frontal bones. This area encapsulates the left nasal cavity and frontal sinuses, and resulted in the destruction of the nasal septum and invasion of the contralateral nasal cavity. Also note the swollen soft tissues surrounding the mass

after intubation and blocking of the maxillary nerve with 2% lidocaine. The results showed positivity for *Bordetella bronchiseptica*, which was found to be susceptible to amikacin, amoxicillin/clavulanate, ceftazidime, enrofloxacin, tetracycline, gentamicin and tobramycin upon sensitivity testing.

Endoscopic examination of the nasal cavity was first performed with a flexible bronchoscope (EG-1840; Pentax, USA; 6 mm diameter × 1.050 mm length) to examine the rhinopharynx using a retrograde approach. The pharynx was packed with tampons to prevent aspiration of nasal exudates or irrigation fluid, then a rigid endoscope (Karl Storz, Germany; 2.7 mm diameter × 18 cm length, 0°) was employed for inspection of the rostral part of the nasal cavities.

No abnormalities were identified in the rhinopharynx; however, a mass that completely occupied the left cavity starting 3 cm from the left nostril and encompassing the aboral part of right dorsal meatus was identified. The surface of the mass appeared smooth and was pale pink in colour, without any erosions or ulcers. A dense vascular network was visible below the mucosa (Figure 3).

Attempts to perform a biopsy by endoscopy failed due to the stone-like hardness of the mass. Five biopsies of the mass, collected from the cutaneous surface with a 9G Jamshidi bone marrow bioptic instrument, were fixed in 10% neutral buffered for-

malin, then routinely processed in paraffin, sectioned at 4 mm and stained with haematoxylin and eosin (HE). Histologically, the lesion consisted of a non-encapsulated, multilobulated mass composed of dense coalescing trabeculae of well-differentiated bone, which was lined with osteogenic cells (Figure 4). The morphologic diagnosis was suggestive of nasal osteoma.

After the procedure, the patient was treated with antibiotics (oral amoxicillin/clavulanate at 12.5 mg/

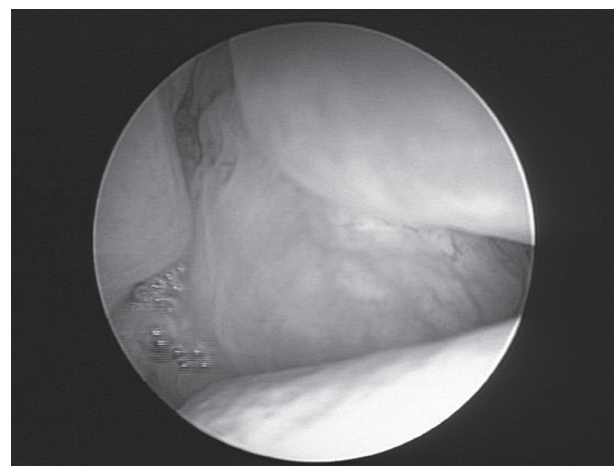


Figure 3. Endoscopic image of the left nasal meatus showing the presence of a round mass that completely occupies the nasal lumen, characterised by a smooth surface with evident vasculature (Karl Storz, Germany; 2.7 mm diameter × 18 cm length, 0°)

doi: 10.17221/30/2017-VETMED

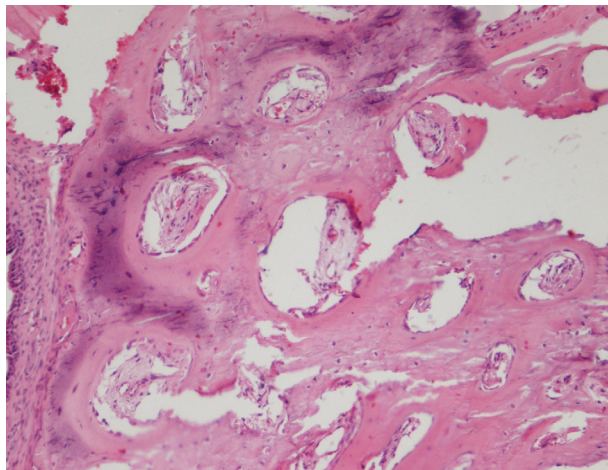


Figure 4. Histology of a full-thickness biopsy of the left nasal plane. Note the presence of a non-encapsulated, multilobulated mass composed of dense coalescing trabeculae of well-differentiated bone, lined with osteogenic cells. EE × 10

kg body weight two times daily for 10 days), analgesic therapy (oral tramadol at 2 mg/kg body weight two times daily for 7 days) and a gastroprotective agent (oral lansoprazole at 1 mg/kg body weight once per day for 10 days).

Fifteen days later, in order to better define the extension and the eventual involvement of other structures, the patient underwent a whole body

computed tomography (CT) scan. This scan identified a mass located 3 cm from the entrance of the left nostril, measuring 11 (cranio-caudal) × 5.3 (medio-lateral) × 5.1 (dorso-ventral) cm, with mineral density that filled the entire left nasal cavity and 70% of the right cavity, also extending into the left frontal sinuses. The mass was made up of bony tissue areas with a multilobular aspect, and had caused left nasal and maxillary bone lysis. The mass extended dorso-laterally outside the nasal cavity to the left for about 3.5 (cranio-caudal) × 2 (medio-lateral) × 4 (dorso-ventral) cm (Figure 5).

There was no involvement of any other structures or presence of metastasis in the lymph nodes, lungs or liver.

The position and extension of the mass made intervention with surgical excision complex. Radiation therapy represented a possible treatment option (Soltero-River et al. 2015), but the owner decided not to proceed for financial reasons.

With reference to what was previously reported in the literature (Grozdanic et al. 2013), the dog was prescribed carprofen (2.2 mg/kg body weight four times daily taken orally) for four weeks to slow the growth of the tumour, with the dosage reassessed at follow up, combined with lansoprazole for gastroprotective purposes (1 mg/kg body weight once a day taken orally) over the whole treatment period.

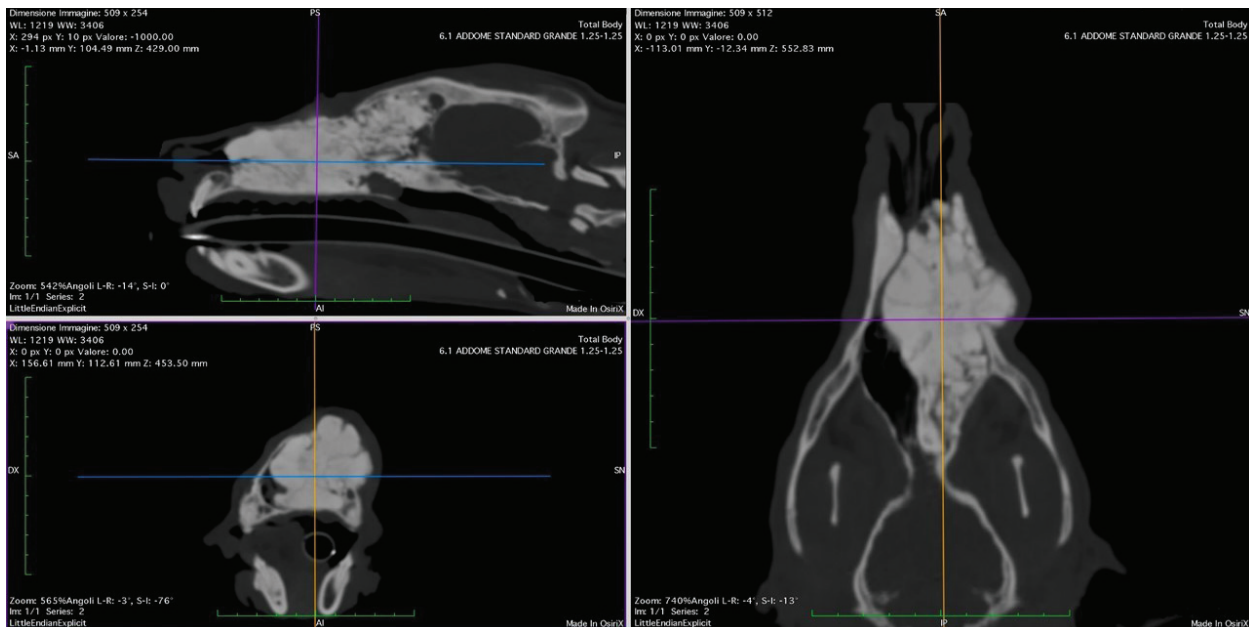


Figure 5. Multiple planar reconstruction from a CT scan of the skull. A large mass with mineral density is shown to fill the entire left nasal cavity and 70% of the right cavity, also extending into the left frontal sinuses. The mass was made up of areas of bone tissue with a multilobular profile, which caused left nasal and maxillary bone lysis. The mass extended outside the nasal cavity dorso-laterally to the left

Unfortunately, the owner refused further contact with our medical staff, and, therefore, the success of the treatment remains unknown.

## DISCUSSION AND CONCLUSIONS

In human medicine, osteoma is the most common benign tumour of the nose and paranasal sinuses (Chahed et al. 2016). In small animals, however, the presence of osteoma in these areas is uncommon (Vanel et al. 2013). The clinical signs are secondary to compression of the surrounding structures. The growth of the tumour is slow, as in the case reported here, in which the owner reported that symptoms had appeared 10 months earlier.

Differential diagnoses of osteoma include malignant osteosarcoma, chondrosarcoma and multilobular osteochondrosarcoma and other benign tumours such as osteochondroma and ossifying fibroma (Thomson and Pool 2002; Dennis 2005; Grozdanic et al. 2013). Differentiation between malignant and benign bone disease cannot be made radiographically, because cranial neoplasms often show unstructured new bone formation and osteolysis (Dennis 2005).

Differential diagnosis is performed exclusively by pathological examination of the tissue sample acquired by biopsy. It should be noted that laboratory tests are not useful for the diagnosis of osteoma in either human or veterinary medicine, unlike radiology or CT.

In the case of nasal osteoma, previous radiological analysis revealed a well-circumscribed calcific and inhomogeneous radiopacity occupying the nasal cavities (Soltero-Rivera et al. 2015).

The characteristic radiographic features evidenced in our radiographs and confirmed by the CT exam was the strong radiopacity of the nasal mass, which could be compared to a stone.

In our case, endoscopic examination revealed a mass occupying the nasal lumen associated with turbinate atrophy, characterised by low involvement of the mucosal surface, with the exception of the submucosal vascular bed. While the endoscopic appearance was non-specific and did not allow evaluation of the extent of the mass, the inability to perform an endoscopic biopsy of the mass due to the hardness of the structure could represent a useful tool for diagnosis. It should be stressed that unlike human medicine, where the suggested therapeutic approach for nasal osteoma is endo-

nasal endoscopic surgery (Yazici et al. 2014), this procedure was not possible in our case due to the size of the mass. Indeed, in human medicine, the slow-growing osteoma is generally detected before the dimensions of the mass exceed those compatible with endoscopic surgery. Conversely, early diagnosis is often difficult in veterinary medicine, and osteoma is frequently diagnosed when the dimensions are considerable, having led to occlusion of the nasal cavity or deformity of the skull profile.

Histological aspects of osteoma usually highlight the presence of dense bone with irregularly spaced osteocytes within the lacunae. The medullary spaces may contain adipose tissue, blood vessels, fibrous connective tissue, and less frequently, loosely arranged bone marrow stromal cells, osteoblasts and osteoclasts (Soltero-Rivera et al. 2015).

The gold standard treatment is complete surgical resection of the mass with up to 2-cm margins, followed by reconstruction using preformed moulded polymethylmethacrylate prosthetic implants in the case of coarse removal of tissue (Bryant et al. 2003). No chemotherapy after surgery is recommended. Radiofrequency ablation may be considered when complete surgical excision is not possible (Soltero-Rivera et al. 2015; Faddoul et al. 2016). Another treatment which is technically feasible in human medicine is image-guided cryoablation (Whitmore et al. 2016). Chronic treatment with systemic nonsteroidal anti-inflammatory drugs, both in human (Goto et al. 2011; Aiba et al. 2014) and veterinary (Grozdanic et al. 2013) medicine is also recommended. In fact, as reported by Kneisl and Simon (1992), nonsteroidal anti-inflammatory drugs are able to accelerate the healing of osteoma. The mechanism is not entirely clear, but seems to depend on the ability of nonsteroidal anti-inflammatory drugs to inhibit prostaglandin  $E_2$  and prostacyclin, the concentration of which is high in osteoma and which may play a fundamental role in osteoma development (Wold et al. 1988).

Due to the large extension of the mass, as evidenced by CT, chronic systemic nonsteroidal anti-inflammatory treatment with carprofen was proposed instead of surgery. However, due to a lack of information from the owner, we cannot affirm whether this treatment was effective.

In summary, osteoma is a benign neoplasia that should be considered in the differential diagnosis of nasal mass in dogs, as its gradual growth, even if slow, reduces the possibility of removal.

doi: 10.17221/30/2017-VETMED

## REFERENCES

- Aiba H, Hayashi K, Inatani H, Satoshi Y, Watanabe N, Sakurai H, Tsuchiya H, Otsuka T (2014): Conservative treatment for patients with osteoid osteoma: a case series. *Anticancer Research* 34, 3721–3725.
- Bryant KJ, Steinberg H, McAnulty JF (2003): Cranioplasty by means of molded polymethylmethacrylate prosthetic reconstruction after radical excision of neoplasms of the skull in two dogs. *Journal of the American Veterinary Medical Association* 223, 67–72.
- Chahed H, Hachicha H, Bachraoui R, Marrakchi J, Mediouni A, Zanine R, Ben Amor M, Beltaief N, Besbes G (2016): Paranasal sinus osteomas: diagnosis and treatment. *Revue de Stomatologie, de Chirurgie Maxillo-faciale et de Chirurgie Orale* 117, 306–310.
- Dennis R (2005): Skull – general. In: Barr FJ, Kirberger RM (eds): *BSAVA Manual of Canine and Feline Musculoskeletal Imaging*. 1<sup>st</sup> edn. BSAVA. 173–191.
- Dernell WS, Ehrhart NP, Straw RC, Vail DM (2007): Tumors of the skeletal system. In: Withrow SJ, Vail DM (eds): *Small Animal Clinical Oncology*. 4<sup>th</sup> edn. Elsevier. 540–582.
- Dobson J, Morris J (2001): Skeletal system. In: Dobson J, Morris J (eds): *Small Animal Oncology*. Iowa State University Press, Ames. 78–93.
- Faddoul J, Faddoul Y, Kobaiter-Maarrawi S, Moussa R, Rizk T, Nohra G, Okais N, Samaha E, Maarrawi J (2016): Radiofrequency ablation of spinal osteoid osteoma: a prospective study. *Journal of Neurosurgery: Spine* 2, 1–6.
- Goto T, Shinoda Y, Okuma T, Ogura K, Tsuda Y, Yamakawa K, Hozumi T (2011): Administration of nonsteroidal anti-inflammatory drugs accelerates spontaneous healing of osteoid osteoma. *Archives of Orthopaedic and Trauma Surgery* 131, 619–625.
- Grozdanic S, Riedesel EA, Ackermann MR (2013): Successful medical treatment of an orbital osteoma in a dog. *Veterinary Ophthalmology* 16, 135–139.
- Kneisl JS, Simon MA (1992): Medical management compared with operative treatment for osteoid-osteoma. *Journal of Bone Joint Surgery* 74, 179–185.
- Ling GV, Morgan JP, Pool RR (1974): Primary bone tumors in the dog: a combined clinical, radiographic and histologic approach to early diagnosis. *Journal of the American Veterinary Medical Association* 165, 55–67.
- Misdorp W, Van der Heul RO (1976): Tumours of bones and joints. *Bulletin of the World Health Organization* 53, 265–282.
- Pool RR (1990): Tumours of bone and cartilage. In: Moulton JE (ed.): *Tumors in Domestic Animals*. 3<sup>rd</sup> edn. University of California Press, Berkeley. 160–161.
- Soltero-Rivera M, Engiles JB, Reiter AM, Reetz J, Lewis JR, Sanchez MD (2015): Benign and malignant proliferative fibro-osseous and osseous lesions of the oral cavity of dogs. *Veterinary Pathology* 52, 894–902.
- Thomson KG, Pool RR (2002): Benign tumors of bone. In: Meuten DJ (ed.): *Tumors of Domestic Animals*. 4<sup>th</sup> edn. Iowa State Press, Ames. 248–298.
- Vanel M, Blond L, Vanel D (2013): Imaging of primary bone tumors in veterinary medicine: which differences? *European Journal of Radiology* 82, 2129–2139.
- Volker MK, Luskin IR (2012): Diagnostic imaging in veterinary dental practice. *Journal of the American Veterinary Medical Association* 241, 1573–1575.
- Volker MK, Luskin IR (2014): Oral osteoma in 6 dogs. *Journal of Veterinary Dentistry* 31, 88–91.
- Whitmore MJ, Hawkins CM, Prologo JD, Marshall KW, Fabregas JA, Yim DB, Monson D, Oskouei SV, Fletcher ND, Williams RS (2016): Cryoablation of osteoid osteoma in the pediatric and adolescent population. *Journal of Vascular and Interventional Radiology* 27, 232–237.
- Wold LE, Pritchard DJ, Bergert J, Wilson DM (1988): Prostaglandin synthesis by osteoid osteoma and osteoblastoma. *Modern Pathology* 1, 129–131.
- Woldenberg Y, Nach M, Bodner L (2005): Peripheral osteoma of the maxillofacial region. Diagnosis and management: a study of 14 cases. *Medicina Oral, Patologia Oral y Cirugia Bucal* 10, 139–142.
- Yazici H, Soy FK, Kulduk E, Dundar R, Dogan S, Kaymakci M, Bulbul E (2014): Endonasal endoscopic excision of a rare tumor: nasal bone osteoid osteoma. *Journal of Craniofacial Surgery* 25, 471–473.

Received: February 25, 2017

Accepted after corrections: September 15, 2017