



## CASE REPORT

### Diagnosis and Treatment of Foetal Anasarca in Two English Bulldog Puppies

M Cunto, D Zambelli, C Castagnetti, N Linta and C Bini\*

Department of Veterinary Medical Sciences – Alma Mater Studiorum, University of Bologna, 40064 Ozzano Emilia (Bo), Italy

\*Corresponding author: [costanza.bini2@unibo.it](mailto:costanza.bini2@unibo.it)

#### ARTICLE HISTORY (14-311)

Received: June 19, 2014

Revised: July 28, 2014

Accepted: September 25, 2014

#### Key words:

Anasarca

English bulldog

Neonatal disease

Puppy

#### ABSTRACT

This case report provides the first description of foetal anasarca, from prenatal diagnosis to neonatal treatment, in two English Bulldog puppies. Anasarca affected 2 out of 3 puppies of the same litter. The dam was a 3 year-old primipara and was ultrasonographically monitored during pregnancy. The diagnosis of foetal anasarca was performed on d53. The most severely affected puppy was a female, which showed subcutaneous oedema and fluid in the thoracic and abdominal cavities. The other affected puppy was a male, which showed subcutaneous oedema but no fluid in thoracic and abdominal cavities. At birth, the female puppy did not respond to resuscitation, whereas the male puppy was successfully treated with furosemide after resuscitation and completely recovered within 36 hours. The third puppy was a healthy female. Two weeks after birth, the male puppy was healthy, although it was lighter compared to its sister puppy. In conclusion, ultrasound examination during routine pregnancy monitoring permits an early diagnosis of foetal anasarca, at least in the most severe cases. Prenatal diagnosis can be useful for the planned c-section, in order to apply an adequate treatment as soon as possible at delivery.

©2014 PVJ. All rights reserved

**To Cite This Article:** Cunto M, D Zambelli, C Castagnetti, N Linta, and C Bini, 2015. Diagnosis and treatment of foetal anasarca in two English Bulldog puppies. *Pak Vet J*, 35(2): 251-253.

#### INTRODUCTION

Foetal anasarca, also known as congenital oedema or hydrops fetalis, is characterised by an excessive accumulation of subcutaneous fluids, with or without visceral effusions. The affected pups, referred to as “water puppies” or “walrus puppies”, are typically enlarged and often cause dystocia. A higher prevalence is recognised for specific breeds, such as English and French Bulldogs and Pugs. The condition may involve the whole or a variable part of the litter and is usually associated with a high neonatal mortality rate. The administration of thiazide diuretics is reported as the main medical treatment for foetal anasarca (Hopper *et al.*, 2004; Hoskins, 2008)

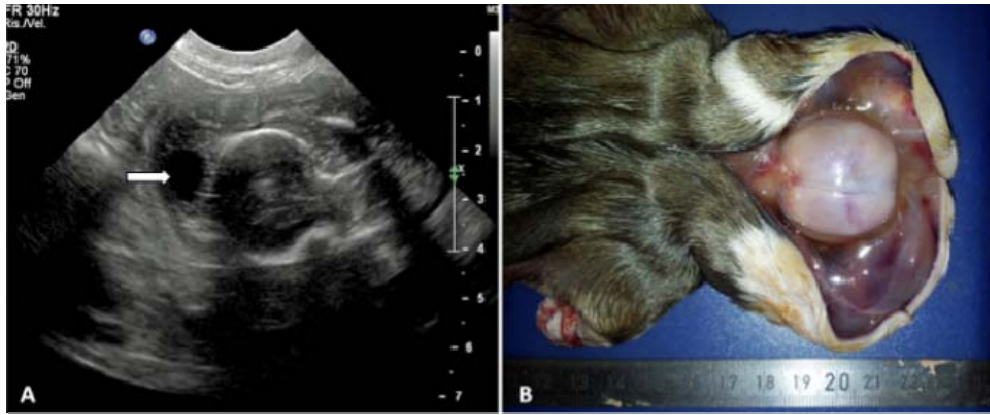The aim of this report is to describe two cases of foetal anasarca within the same litter from diagnosis to neonatal treatment and follow-up. Prenatal diagnosis was performed ultrasonographically on the more severely affected puppy, while another milder case was diagnosed at birth and successfully treated.

**Case presentation:** The first pregnancy of a 3 year-old English bulldog female was monitored.

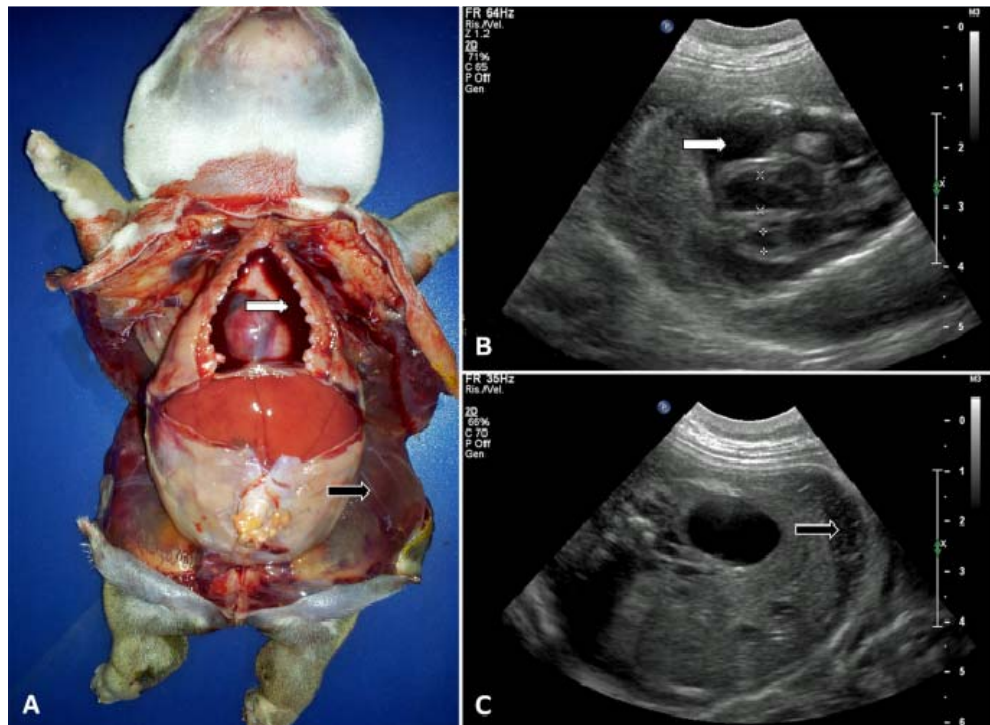
Transrectal ultrasonographic diagnosis of pregnancy was made on d17 from the first day of diestrus using a 5-8 MHz convex probe. Three gestational sacs were detected, with one located in the right uterine horn and two located in the left. After the first assessment, the bitch was subjected to a weekly ultrasound monitoring until the time of the elective C-section (d55). By d50, the foetus located within the right uterine horn appeared larger than the others and on d53 foetal anasarca was diagnosed. The affected foetus showed subcutaneous fluid accumulation, which appeared as a hypoechoic layer separating the skin from the underlying tissues (Fig. 1A and Fig. 2C). On d54, the affected foetus also showed marked pleural effusion, with anechoic fluid surrounding the heart, while the lungs appeared small and retracted from the thoracic wall due to fluid accumulation (Fig. 2B). No peritoneal effusion was detected. The other two foetuses appeared ultrasonographically normal.

The planned C-section was performed on d55, on the basis of serum progesterone level (6.30 ng/ml). Two out of 3 puppies showed different degrees of subcutaneous oedema at gross appearance (Fig. 3).

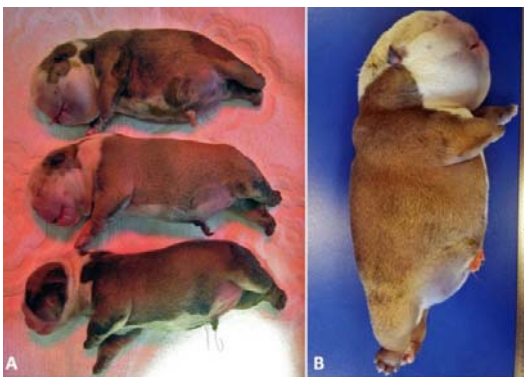
The female foetus previously diagnosed with anasarca was delivered first; the whole body appeared



**Fig. 1:** Comparison between ultrasonographic (A) and necropsic (B) appearance of subcutaneous oedema of the head in the most severely affected puppy. Subcutaneous oedema is marked with the white arrow in the ultrasound capture.



**Fig. 2:** Comparison between necropsic findings (A) and ultrasonographic findings (B & C) in the most severely affected puppy: pleural effusion (white arrows) and subcutaneous oedema (black arrows).



**Fig. 3:** Comparison between the three puppies of the litter (A). From the top to the bottom: the most severely affected female (also shown in figure B), the mildly affected male and the healthy female.

**Table 1:** Body weight of the two surviving puppies during their first 2 weeks of life

Time from birth	Male (g)	Female (g)
0 h (birth)	420	359
2 h	391	350
12 h	370	361
1 d	336	321
2 d	290	288
3 d	282	325
4 d	287	354
5 d	300	384
6 d	327	419
7 d	357	469
14 d	600	848

markedly swollen due to generalized subcutaneous oedema. Neonatal resuscitation was not successful and the puppy never breathed. Apgar score (Veronesi *et al.*, 2009) was 0. Positive pressure ventilation with a pediatric Ambu

and thoracentesis were attempted to achieve pulmonary expansion, but were ineffective. Subcutaneous oedema, pleural and peritoneal effusions were found at post-mortem examination (Fig. 2A).

The second puppy delivered was a male, which was mildly affected by anasarca. Subcutaneous oedema involved mainly the head. It was successfully resuscitated, although its Apgar score was 0. The puppy was treated with a single administration of furosemide i.m. (10 mg total dose - Lasix; Sanofi), which allowed a 30 g weightloss within 2 hours. During its first 8 hours of life, the puppy was stimulated to urinate and defecate each 30 minutes, with the aid of a moist cotton ball. The third puppy was a healthy female with an Apgar score of 5.

The two surviving puppies were initially kept in a neonatal incubator (32.2°C, oxygen 3 LPM) and monitored for 36 hours. During the first 12 hours they were fed using a 10 Fr oro-gastric feeding tube, since they did not demonstrate the suckle reflex.

Thirty-six hours after birth the puppies were discharged as they appeared completely recovered. The owner was recommended to monitor the puppies' weight during the following days; two weeks after discharge the puppies were both healthy, even though the male was smaller than its sister puppy (Table 1).

## DISCUSSION

Foetal anasarca is a congenital condition resulting from an imbalance in the homeostasis of the foetal fluids (Lumbers *et al.*, 2001), nevertheless the precise aetiology of congenital oedema is not known. Cardiac malformations are considered among the most common causes of hydrops foetalis in dogs but in many cases, as in the present report, no apparent cause has been identified (Buchanan, 2001; Heng *et al.*, 2011). Familial tendencies have been noted and the role of genetic factors has been supposed (Allen *et al.*, 1989; Hopper *et al.*, 2004). Infectious and traumatic causes have also been reported (Veronesi, 2013). Neither the foetus diagnosed antenatally with anasarca nor its mildly affected littermate showed any cardiac malformation nor other morphologic alterations at the ultrasound examination, nor at necropsy when performed, which can explain the presence of subcutaneous and pleural fluid accumulation. The dam was a primipara; parity is considered an important risk factor, since foetal anasarca involves more frequently the litters of primiparous bitches (Hopper *et al.*, 2004).

There are only a few reports about the ultrasonographic diagnosis of foetal anasarca during routine pregnancy diagnosis or pregnancy monitoring (Allen *et al.*, 1989; Hopper *et al.*, 2004; Heng *et al.*, 2011). To the author's knowledge, this is the first report documenting two cases from prenatal diagnosis to neonatal treatment within the same litter.

The diagnosis was made on d53, whereas no alteration was previously detected with the ultrasound examinations, performed weekly from midgestation. Moreover, only one out of 3 fetuses appeared to be

affected on d53, while the second was found to be affected at birth, on d55. These findings suggest that the syndrome has developed late in gestation, during the last days of pregnancy.

Ladds *et al.* (1971) stated that the edematous pup was frequently the sole occupant of a uterine horn. In our case, the most severely affected foetus was the sole occupant of the right horn.

Ultrasonography allowed the identification of the high-risk litter through the detection of subcutaneous and pleural fluid accumulations in the more severely affected foetus, findings that were confirmed at post-mortem examination. Peritoneal fluid, identified at necropsy, was not ultrasonographically evident; this might have been due to the high cellularity of the free abdominal fluid (Allen *et al.*, 1989).

The medical treatment recommended for walrus puppies involves the administration of furosemide (10 mg, total dose, intramuscularly); if necessary, the injection can be repeated every 3 hours until the affected puppy weights no more than 30-45 g over its healthy littermates (Hoskins, 2008). The treated puppy required a single administration of diuretic, which permitted the loss of the excess fluids within 2 hours. An early treatment, together with the supportive care, allowed the complete recovery of the affected puppy.

**Conclusion:** Ultrasound examination during routine pregnancy monitoring permits an early diagnosis of foetal anasarca, at least in the most severe cases. Prenatal diagnosis can be useful for the planned c-section, in order to apply an adequate treatment as soon as possible at delivery. In fact an early treatment, together with the supportive care, has proven to allow the complete recovery of the mildly affected puppy.

## REFERENCES

- Allen WE, GCW England and KB White, 1989. Hydrops fetalis diagnosed by real-time ultrasonography in a bichon frise bitch. *J Small Anim Pract*, 30: 465-467.
- Buchanan JV, 2001. Pathogenesis of single right coronary artery and pulmonic stenosis in English Bulldogs. *J Vet Intern Med*, 15: 101-104.
- Heng HG, E Randall, K Williams and C Johnson, 2011. What is your diagnosis? Hydrops fetalis *J Am Vet Med Assoc*, 239: 51-52.
- Hopper BJ, JL Richardson and NV Lester, 2004. Spontaneous antenatal resolution of canine hydrops fetalis diagnosed by ultrasound. *J Small Anim Pract*, 45: 2-8.
- Hoskins JD, 2008. Emergency in neonatology. Proceedings of the International SCIVAC Congress. Rimini, Italy, 30 May to 1 June, 2008, pp: 255-266.
- Ladds PVW, SM Dennis and HW Leipold, 1971. Lethal congenital edema in Bulldog pups. *J Am Vet Med Assoc*, 159: 81-86.
- Lumbers ER, AJ Gunn, DY Zhang, JJ Wu, L Maxwell and L Bennet, 2001. Nonimmune hydrops fetalis and activation of the renin-angiotensin system after asphyxia in preterm fetal sheep. *Am J Physiol Regul Integr Comp Physiol*, 280: 1045-1051.
- Veronesi MC, S Panzani, M Faustini and A Rota, 2009. An Apgar scoring system for routine assessment of newborn puppy viability and short-term survival prognosis. *Theriogenology*, 72: 401-407.
- Veronesi MC, 2013. Patologie neonatali. In: *Neonatalogia veterinaria*. EdiSES, Napoli, Italy, pp: 94-96.