

Serum Cardiac Troponin I Concentration in Dogs with Precapillary and Postcapillary Pulmonary Hypertension

C. Guglielmini, C. Civitella, A. Diana, M. Di Tommaso, M. Cipone, and A. Luciani

Background: Pulmonary hypertension (PH) is a disease condition leading to right-sided cardiac hypertrophy and, eventually, right-sided heart failure. Cardiac troponin I (cTnI) is a circulating biomarker of cardiac damage.

Hypothesis: Myocardial damage can occur in dogs with precapillary and postcapillary PH.

Animals: One hundred and thirty-three dogs were examined: 26 healthy controls, 42 dogs with mitral valve disease (MVD) without PH, 48 dogs with pulmonary hypertension associated with mitral valve disease (PH-MVD), and 17 dogs with precapillary PH.

Methods: Prospective, observational study. Serum cTnI concentration was measured with a commercially available immunoassay and results were compared between groups.

Results: Median cTnI was 0.10 ng/mL (range 0.10–0.17 ng/mL) in healthy dogs. Compared with the healthy population, median serum cTnI concentration was increased in dogs with precapillary PH (0.25 ng/mL; range 0.10–1.9 ng/mL; $P < .001$) and in dogs with PH-MVD (0.21 ng/mL; range 0.10–2.10 ng/mL; $P < .001$). Median serum cTnI concentration of dogs with MVD (0.12 ng/mL; range 0.10–1.00 ng/mL) was not significantly different compared with control group and dogs with PH-MVD. In dogs with MVD and PH-MVD, only the subgroup with decompensated PH-MVD had significantly higher cTnI concentration compared with dogs with compensated MVD and PH-MVD. Serum cTnI concentration showed significant modest positive correlations with the calculated pulmonary artery systolic pressure in dogs with PH and some echocardiographic indices in dogs with MVD and PH-MVD.

Conclusions and Clinical Importance: Serum cTnI is high in dogs with either precapillary and postcapillary PH. Myocardial damage in dogs with postcapillary PH is likely the consequence of increased severity of MVD.

Key words: Canine; Cardiac biomarkers; Cardiovascular diseases; Echocardiography.

Pulmonary hypertension (PH) refers to an increase in pulmonary arterial pressure and is defined by systolic and diastolic pulmonary artery pressure >25 and 15 mmHg, respectively, at rest.^{1–5} Different cardiovascular modifications can accompany PH, including right ventricular hypertrophy (RVH) and dilatation, right atrial enlargement, and, eventually, right-sided heart failure. The clinical classification of PH in humans includes 5 categories: pulmonary arterial hypertension caused by vascular diseases affecting pulmonary arterioles; PH associated with pulmonary venous hypertension caused by left-sided cardiac diseases; PH associated with lung diseases, hypoxemia or both; PH associated with thromboembolic disorders; and PH associated with miscellaneous disorders.⁶ In dogs, the most common causes of PH include heartworm infection, mitral valve disease (MVD), and respiratory tract disease, while primary pulmonary arterial hypertension is rare.^{1–5,7–13,a} A more simplified classification, still used in the dog, distinguishes precapillary PH from postcapillary PH, which is PH associated with left-sided cardiac disorders.^{2,4,5,12}

From the Department of Veterinary Clinical Sciences, University of Teramo, Teramo, Italy (Guglielmini, Civitella, Di Tommaso, Luciani); and Veterinary Clinical Department, University of Bologna, Bologna, Italy (Diana, Cipone). This work was done at the Department of Veterinary Clinical Sciences and Veterinary Clinical Department of the University of Teramo and Bologna. Previously presented in part at the 25th Annual Forum of the American College of Veterinary Internal Medicine in Seattle, WA, June 6–9, 2007.

Corresponding author: C. Guglielmini, DVM, PhD, Department of Veterinary Clinical Sciences, School of Veterinary Medicine, University of Teramo, Viale Crispi 212, I-64100 Teramo, Italy; e-mail: cguglielmini@unite.it.

Submitted January 27, 2009; Revised September 14, 2009; Accepted October 13, 2009.

Copyright © 2009 by the American College of Veterinary Internal Medicine

10.1111/j.1939-1676.2009.0430.x

Abbreviations:

Ao	aortic diameter
APE	acute pulmonary embolism
cTnI	cardiac troponin I
cTnT	cardiac troponin T
CHF	congestive heart failure
FS	fractional shortening
ISACHC	International Small Animal Cardiac Health Council
LA	left atrial diameter
LVDd	left ventricular diameter at diastole
LVDs	left ventricular diameter at systole
L-CHF	left-sided congestive heart failure

illary PH from postcapillary PH, which is PH associated with left-sided cardiac disorders.^{2,4,5,12}

Cardiac catheterization is the gold standard for definitive measurement of pulmonary arterial pressure. Noninvasive evaluation of pulmonary artery pressure may be obtained by Doppler echocardiography.^{1–5,12} In the absence of pulmonic stenosis, systolic or diastolic pulmonary artery pressure can be estimated by applying the modified Bernoulli equation ($\Delta p = 4 \times \text{velocity}^2$) to the peak velocity of tricuspid regurgitation (TR) or pulmonic insufficiency (PI), respectively. Therefore, the widespread use of Doppler echocardiography has greatly enhanced the identification of dogs with PH in the recent years.¹²

Right ventricular failure resulting in low cardiac output is the main cause of death in human patients with PH.¹⁴ Severe respiratory distress is the main cause of death or euthanasia in dogs with PH.^{4,13} Severe PH in humans results in lower systemic blood pressure and this may decrease coronary perfusion gradient.¹⁵ At the same time, increased right ventricular intramural pressure can disturb the physiological pattern of right ventricular

myocardial perfusion.¹⁶ Cardiac troponin T (cTnT) and I (cTnI) are myocardial proteins that are released in the extracellular space when myocardial cellular injury and necrosis occur.¹⁷ In particular, the circulating concentration of cardiac troponins is proportional to the extent of myocardial injury.^{17,18} There is a high homology of the nucleotide and amino-acid sequences of human and canine cTnI, allowing human commercial cTnI analyzers to be used to measure cTnI in dogs.¹⁹ Reference range values of circulating cTnI concentration have been published in healthy dogs (ie, < 0.03 to 0.07 ng/mL with a mean of 0.02 ng/mL and < 0.05 to 0.12 ng/mL with a median < 0.05 ng/mL).^{20,21} Increased circulating level of cardiac troponins have been demonstrated in dogs with different cardiac disorders including MVD, dilated cardiomyopathy, pericardial effusion, congestive heart failure (CHF), gastric dilatation-volvulus, babesiosis, subaortic stenosis, arrhythmogenic right ventricular cardiomyopathy of Boxers, and blunt chest trauma.^{22–32} Increased levels of circulating cardiac troponins have been demonstrated in humans with pulmonary thromboembolism (PTE) and PH.^{16,33–36} Furthermore, patients with PTE and elevated cardiac troponins have a worse prognosis than those without troponins elevation. To the best of the authors' knowledge, circulating cardiac troponins have not been evaluated in dogs with PH.

The aim of the present study was to evaluate serum cTnI concentrations in dogs with precapillary PH and pulmonary hypertension associated with mitral valve disease (PH-MVD), and to compare them with those observed in healthy dogs and dogs with MVD without PH.

Methods

Animals and Selection Criteria

The protocol of this prospective study was approved by the Ethical Committees of the University of Teramo and Bologna. Dogs presented to the cardiology service of the Veterinary Teaching Hospital of the University of Teramo and Bologna from October 2003 to November 2008 were eligible for entry into the study. During this time period, healthy animals from hospital employees and students were also enrolled. Animals represented a wide range of ages and breeds. Enrollment was based on owner consent and the availability of the dog for ECG, survey thoracic radiography, and echocardiographic examination. In each center, the same experienced operator (C.G. and M.C.) evaluated the thoracic radiographs and echocardiograms. Based on results of the above exams, dogs were assigned to 1 of 4 groups according to the following criteria:

- (1) Healthy dogs: dogs with normal cardiac auscultation, 6-lead ECG, survey thoracic radiography, 2-dimensional (2D) and M-mode echocardiogram, and color flow and spectral Doppler examination.
- (2) MVD without PH: dogs with a left and right apical systolic murmur; negative serology for canine heartworm antigen; thickened, nodular, or prolapsing mitral valve leaflets on 2D echocardiography without echocardiographic and Doppler evidence of pulmonic stenosis; mild-to-severe mitral valve regurgitation and low velocity TR (ie, ≤ 2.4 m/s) and/or PI (ie, ≤ 1.9 m/s) on Doppler echocardiography. Dogs with MVD but without detectable TR, PI, or both were not included in this group, because pulmonary artery pressure cannot be deter-

mined by the above Doppler echocardiographic technique in these dogs.

- (3) PH-MVD: dogs with a left and right apical systolic murmur; negative serology for canine heartworm antigen; thickened, nodular, or prolapsing mitral valve leaflets on 2D echocardiography without echocardiographic and Doppler evidence of pulmonic stenosis; mild-to-severe mitral valve regurgitation, peak TR velocity ≥ 2.5 m/s (corresponding to a systolic pressure gradient of 25 mmHg) and/or PI velocity ≥ 2.0 m/s (corresponding to a diastolic pressure gradient of 16 mmHg) on Doppler echocardiography.
- (4) Precapillary PH: dogs with clinical signs of dyspnea, tachypnea, ascites, syncope, lethargy, or exercise intolerance, and a right-sided systolic murmur; right-sided cardiac hypertrophy without echocardiographic and Doppler evidence of other congenital or acquired cardiovascular diseases; peak TR ≥ 2.5 m/s and/or PI velocity ≥ 2.0 m/s on Doppler echocardiography.

Cardiac Evaluation

Echocardiographic and echo-Doppler examinations were performed without sedation with 2 echocardiographic machines^{b,c} equipped with 2.8–3.8 and 4.5–6.5 MHz, and 2.5–3.5 and 5.0–7.5 MHz phased array transducers. Standard echocardiographic scan planes were employed to obtain a definitive diagnosis in each dog.³⁷ Ventricular measurements were obtained from the right parasternal location during 2D-guided M-mode echocardiography. Measurements of the left atrial diameter (LA) and aortic diameter (Ao) were obtained with a 2D method. In dogs with MVD and PH-MVD, presence or absence of RVH was subjectively assessed as previously described.^{1,38} In brief, RVH was deemed if the right ventricular chamber size was greater than one third of the size of the left ventricle on M-mode measurements obtained from the right parasternal location and/or the right ventricular wall thickness was greater than one half of the left ventricular free wall. Furthermore, the following echocardiographic parameters were selected for successive statistical evaluation: left ventricular diameter at diastole (LVDd), left ventricular diameter at systole (LVDs), LA, and Ao. In particular, the following echocardiographic ratio indices were considered: LVDd:Ao, LVDs:Ao, fractional shortening (FS), and LA:Ao.

In dogs with PH, the pulmonary artery systolic pressure (PASP) was calculated by adding the estimated right atrial pressure (RAP) to the Doppler derived systolic right ventricle to RAP gradient. The latter was calculated by applying the modified Bernoulli equation ($\Delta p = 4 \times \text{velocity}^2$) to the peak velocity of TR obtained by the left parasternal 4-chamber view. The estimated RAP was 5 mmHg in dogs with a nonenlarged right atrium, 10 mmHg in dogs with an enlarged right atrium but without right-sided congestive heart failure (R-CHF), and 15 mmHg in dogs with R-CHF.³⁹ According to the International Small Animal Cardiac Health Council (ISACHC) classification score,⁴⁰ dogs with MVD and PH-MVD were further subdivided into 2 groups: dogs with compensated (ISACHC class Ia and Ib) and decompensated (ISACHC class II and III) CHF. Furthermore, the prevalent type of CHF (ie, left-sided congestive heart failure [L-CHF] or R-CHF) was recorded.

Data Collection and cTnI Analysis

Blood samples were collected in 5 mL serum blood tubes and centrifuged within 30 minutes after collection. The serum obtained was separated and stored at -80°C for batched cTnI analysis. Sample storage varied from 1 month to 6 months. Samples were thawed only once, at the time of analysis. The measurement of serum cTnI concentration was performed with a commercially available immunometric assay^d with a lower detection limit of 0.1 ng/mL. This assay has been validated for dogs in the laboratory of the Vet-

erinary Clinical Department of the University of Bologna⁴¹ and showed an intraassay and interassay variability < 10%. The assay has been previously used in 2 studies evaluating cTnI concentration in dogs with cardiac disorders.^{27,32}

Statistical Analysis

Normally distributed data are reported as mean \pm SD and non-normally distributed data are expressed as median and ranges. The 1-way analysis of variance test was used to analyze normally distributed continuous data (age, echocardiographic, and echo-Doppler data) followed by Tukey's posttest for multiple comparisons, and the chi-square test was used for comparison of categorical data. For nonnormally distributed data (body weight and serum cTnI concentration), the Kruskal-Wallis test was employed for comparison among groups followed by Dunn's multiple comparison posttest.

In dogs with MVD, the odds ratio (OR) was calculated to evaluate the association between the presence or absence of PH and development of L-CHF or R-CHF.

In dogs with precapillary PH and PH-MVD, the rank correlation by means of Spearman's ρ coefficient was used to assess the degree of association between serum cTnI concentration and calculated PASP. In dogs with MVD and PH-MVD, Spearman's ρ rank correlation coefficient was used to assess the degree of association between serum cTnI concentration and the echocardiographic indices LVDd: Ao, LVDs: Ao, FS, and LA: Ao.

Serum cTnI concentrations < 0.1 ng/mL were statistically analyzed for 0.1 ng/mL.

All statistical analyses were performed by use of statistical software packages.^{e,f} The minimum level of significance was chosen for $P < .05$.

Results

Patients

The study population included 133 dogs of different breeds, 66 males (2 castrated) and 67 females (13 spayed). Of these, 26 dogs were healthy, 42 had MVD without PH, 48 had PH-MVD, and 17 had precapillary PH. The signalments of each patient group are presented in Table 1. Dogs with MVD, PH-MVD, and precapillary PH were older compared with control dogs ($P < .001$, $P < .001$, and $P < .01$, respectively). Dogs with precapillary PH were younger compared with dogs with MVD ($P < .01$) and PH-MVD ($P < .001$). No statistical differ-

ence was found between dogs with MVD and PH-MVD regarding body weight and age.

Causes of precapillary PH included chronic respiratory disorders ($n = 5$; chronic tracheobronchial diseases, 3 dogs; chronic interstitial lung disease, 2 dogs), heartworm infection ($n = 4$), PTE ($n = 4$), congenital cardiac diseases (ie, reversed patent ductus arteriosus, $n = 2$), and angiostrongylosis ($n = 1$). In 1 dog, left-sided cardiac disease was excluded but the etiology of PH could not be determined.

Cardiac Evaluation

In dogs with MVD, PH was more prevalent in dogs with decompensated CHF ($n = 33/41$, 81%) compared with dogs with compensated CHF ($n = 15/49$, 31%) ($P < .001$). In dogs with MVD and decompensated CHF, R-CHF was more prevalent in dogs with PH ($n = 17/33$, 52%) compared with dogs without PH ($n = 2/8$, 25%), but no association was found between presence or absence of PH and type of CHF (OR = 3.2, 95% confidence interval = 0.6–18.2, $P = .34$). The overall prevalence of R-CHF in dogs with precapillary and post-capillary PH was 47% ($n = 8/17$) and 35% ($n = 17/48$), respectively. Similarly, RVH was more prevalent in dogs with PH-MVD ($n = 14$, 29%) compared with dogs with MVD ($n = 1$, 2%) ($P < .01$). In particular, dogs with compensated and decompensated PH-MVD had significantly higher prevalence of RVH ($n = 3$ and 11, respectively) compared with dogs with compensated MVD ($n = 0$, $P < .05$ and $P < .001$, respectively) but not to dogs with decompensated MVD ($n = 1$, $P = .90$ and $P = .46$, respectively).

Echocardiographic indices in dogs with MVD and PH-MVD are shown in Table 2. Dogs with decompensated MVD and PH-MVD had significantly higher LVDd: Ao ($P < .01$) compared with dogs with compensated MVD. The LA: Ao was significantly higher in dogs with decompensated MVD and PH-MVD compared with dogs with compensated MVD ($P < .001$). The LA: Ao was also significantly higher in dogs with decompensated MVD ($P < .05$) and PH-MVD ($P < .001$) compared with dogs with compensated PH-MVD. No statistical difference

Table 1. Signalment in 133 dogs.

	Healthy (n = 26)	MVD (n = 42)	PH-MVD (n = 48)	Precapillary PH (n = 17)
Sex				
Male	9	24	26	7
Female	17	18	22	10
Age (years)	4.1 \pm 2.2	10.7 \pm 3.4**,\$	11.4 \pm 2.7**,\$	7.5 \pm 4.2#
Body weight (kg)	23 (5–38)	9 (3–50)*	8.2 (3–43)*	15 (1.6–45)

Data are listed as the mean \pm standard deviation and median (range) for age and body weight, respectively.

* $P < .05$ compared with healthy dogs.

** $P < .001$ compared with healthy dogs.

\$ $P < .01$ compared with dogs with precapillary PH.

† $P < .001$ compared with dogs with precapillary PH.

$P < .01$ compared with healthy dogs.

MVD, mitral valve disease without pulmonary hypertension; PH-MVD, pulmonary hypertension associated with MVD; PH, pulmonary hypertension.

Table 2. Echocardiographic data in 90 dogs with mitral valve disease.

	C-MVD (n = 34)	D-MVD (n = 8)	C-PH-MVD (n = 15)	D-PH-MVD (n = 33)
LVDd: Ao	2.1 ± 0.5	2.9 ± 0.5**	2.3 ± 0.7	2.7 ± 0.8**
LVDs: Ao	1.2 ± 0.4	1.6 ± 0.4	1.4 ± 0.5	1.5 ± 0.6
FS (%)	40 ± 10	45 ± 10	39 ± 5	43 ± 11
LA: Ao	1.7 ± 0.4	2.7 ± 0.5***§	1.9 ± 0.5	2.6 ± 0.7***.#
RVH				
Yes/no	0/34	1/7	3/12*	11/22***

Data are reported as the mean ± standard deviation.

**P* < .05 compared with C-MVD.

***P* < .01 compared with C-MVD.

****P* < .001 compared with C-MVD.

§*P* < .05 compared with C-PH-MVD.

#*P* < .001 compared with C-PH-MVD.

C-MVD, compensated mitral valve disease without pulmonary hypertension (ISACHC class Ia and Ib); D-MVD, decompensated mitral valve disease without pulmonary hypertension (ISACHC class II and III); C-PH-MVD, compensated mitral valve disease associated with pulmonary hypertension; D-PH-MVD, decompensated mitral valve disease associated with pulmonary hypertension. LVDd, left ventricular diameter at diastole; LVDs, left ventricular diameter at systole; Ao, aortic diameter; FS, fractional shortening; LA, left atrial diameter; RVH, right ventricular hypertrophy.

was found regarding LVDs: Ao and FS among the four subgroups.

Trivial PI was found in 5 healthy dogs. High velocity (ie, > 2 m/s) PI was found in 8 dogs, 1 with PH-MVD and 7 with precapillary PH. All of these dogs had high velocity (ie, > 2.5 m/s) TR peak velocity. Values of TR peak velocity, Doppler-derived pressure gradient between the right ventricle and atrium, estimated RAP, and calculated PASP in dogs with MVD, PH-MVD, and precapillary PH are shown in Table 3. Significantly higher (*P* < .001) TR peak velocity, Doppler-derived pressure gradient between the right ventricle and atrium, RAP, and calculated PASP were found in dogs with precapillary PH and PH-MVD compared with dogs with MVD without PH. Furthermore, dogs with precapillary PH had significantly higher (*P* < .001) TR peak velocity, Doppler-derived pressure gradient between the right ventricle and atrium, and calculated PASP compared with dogs with PH-MVD.

cTnI

In healthy dogs, cTnI was below the detection limit of the test in 19/26 dogs (73%) and the median serum cTnI concentration was 0.10 ng/mL (range, 0.10–0.17 ng/mL)

with the upper 95th percentile at 0.15 ng/mL (the lower limit of detection for the cTnI assay is 0.1 ng/mL). The median cTnI concentration was 0.12 ng/mL (range, 0.10–1.00 ng/mL) in dogs with MVD, with *n* = 22 (52%) of dogs having cTnI levels > 0.10 ng/mL. The median cTnI concentration was 0.21 ng/mL (range, 0.10–2.10 ng/mL) in dogs with PH-MVD with *n* = 34 (71%) of dogs having cTnI levels > 0.10 ng/mL. The median cTnI concentration was 0.25 ng/mL (range, 0.10–1.90 ng/mL) in dogs with precapillary PH, with *n* = 14 (82%) of dogs having cTnI levels > 0.10 ng/mL.

Results of serum cTnI concentration in the 4 different groups of dogs are shown in Figure 1 and Table 4. No statistical difference was found in serum cTnI concentration between healthy dogs and MVD dogs, between dogs with MVD and PH-MVD, and between dogs with precapillary PH and PH-MVD. Dogs with precapillary PH and PH-MVD had serum cTnI concentration significantly higher compared with healthy dogs (*P* < .001). Median cTnI concentration was also higher in dogs with precapillary PH compared with dogs with MVD (*P* < .05). Considering all dogs with MVD as a unique group, thus including also dogs with PH-MVD, serum cTnI of these dogs was significantly higher compared with healthy dogs (*P* < .001). Results of serum cTnI

Table 3. Echo-Doppler data in 42 dogs with mitral valve disease without pulmonary hypertension and 65 dogs with pulmonary hypertension.

	MVD (n = 42)	PH-MVD (n = 48)	Precapillary PH (n = 17)
TR <i>V</i> _{max} (m/s)	1.9 ± 0.5	3.1 ± 0.5*	3.8 ± 0.9*.#
Δ <i>p</i> (mmHg)	16 ± 6	40 ± 12*	62 ± 30*.#
RAP (mmHg)	8.2 ± 2.7	13.4 ± 2.3*	12.4 ± 2.6*
PASP (mmHg)	24 ± 6	53 ± 13*	74.5 ± 31*.#

Data are reported as the mean ± standard deviation.

**P* < .001 compared with MVD.

#*P* < .001 compared with PH-MVD.

MVD, mitral valve disease; PH-MVD, Pulmonary hypertension associated with mitral valve disease; PH, pulmonary hypertension; TR *V*_{max}, tricuspid regurgitation maximal velocity; Δ*p*, right atrium-to-right ventricle pressure gradient; RAP, estimated right atrial pressure; PASP, pulmonary artery systolic pressure (Δ*p* + RAP).

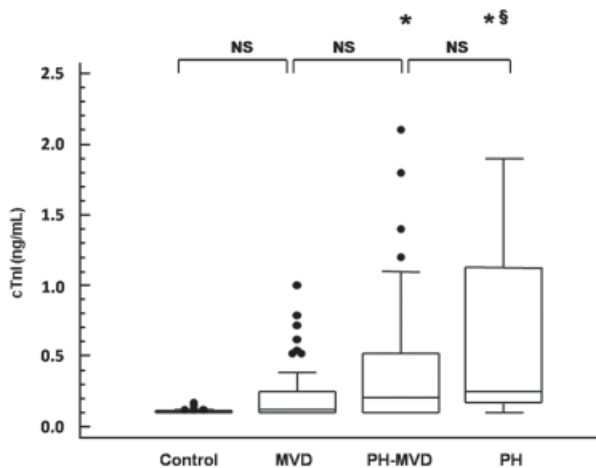


Fig. 1. Serum cardiac troponin I (cTnI) concentrations obtained from 26 healthy dogs, 42 dogs with mitral valve disease (MVD) without pulmonary hypertension, 48 dogs with pulmonary hypertension associated with mitral valve disease (PH-MVD), and 17 dogs with precapillary PH. The horizontal line in each box represents the median value. The boxes represent the interquartile range (25th to 75th percentile). Whiskers represent the 5th and 95th percentiles. Outliers are plotted separately as dots. *Statistical difference ($P < .001$) with control dogs; §Statistical difference ($P < .05$) with MVD dogs; NS, not significant.

concentration after subdivision of dogs with MVD and MVD-PH according to the ISACHC classification (ie, dogs with compensated and decompensated CHF) are shown in Figure 2. Dogs with decompensated PH-MVD had median cTnI concentration (0.38 ng/mL, range, 0.10–2.10 ng/mL) significantly higher compared with healthy dogs ($P < .001$), dogs with compensated MVD (0.10 ng/mL, range, 0.10–0.72 ng/mL $P < .001$), and compensated PH-MVD (0.10 ng/mL, range, 0.10–0.52 ng/mL $P < .01$), but no statistical difference was found compared with dogs with decompensated MVD (0.45 ng/mL, range, 0.10–1.00 ng/mL). Dogs with precapillary PH had significantly higher serum cTnI concentration compared with dogs with compensated MVD ($P < .05$). No statistical difference was found between dogs with precapillary PH and dogs with decompensated MVD and PH-MVD.

A significant modest positive correlation was found between serum cTnI concentration and the calculated PASP in all dogs with PH (ie, those with either precapillary and postcapillary) ($\rho = 0.46$, $P < .001$). In particular, the circulating cTnI concentration and calculated PASP had a significant moderate positive correlation in dogs with precapillary PH ($\rho = 0.56$, $P < .05$) and a significant modest positive correlation in dogs with PH-MVD ($\rho = 0.44$, $P < .01$). A significant modest positive correlation was also found between serum cTnI concentration and the echocardiographic indices LA: Ao ($\rho = 0.37$, $P < .001$), LVDd: Ao ($\rho = 0.24$, $P = .03$), and LVDs: Ao ($\rho = 0.22$, $P = .04$), in dogs with MVD and MVD-PH, but no correlation existed between serum cTnI concentration and FS ($\rho = -0.01$, $P = .92$).

Table 4. cTnI concentrations (ng/mL) in 133 dogs.

	Sample Size	Median	Range
Healthy	26	0.10	0.10–0.17
MVD	42	0.12	0.10–1.00
PH-MVD	48	0.21	0.10–2.10
Precapillary PH	17	0.25	0.10–1.90

MVD, mitral valve disease without pulmonary hypertension; PH-MVD, mitral valve disease associated with pulmonary hypertension; PH, pulmonary hypertension.

Discussion

Dogs with precapillary PH had significantly higher value of TR maximal velocity and, consequently, PASP compared with dogs with PH-MVD, because no difference was found in the estimated RAP between the 2 groups of dogs. These findings support that precapillary PH is usually associated with a greater increase in pulmonary arterial pressure compared with postcapillary PH in the dog.^{1,2,4,13} A positive correlation was found between cTnI concentration and severity of PH, as recently observed in dogs with precapillary PH experimentally induced via acute PTE.⁴² Thus, increased pulmonary arterial pressure could be an inciting factor for myocardial damage in dogs with either precapillary and postcapillary PH.

Significantly increased LA and, partially, LVDd were found in dogs with decompensated MVD and PH-MVD compared with their counterparts with compensated val-

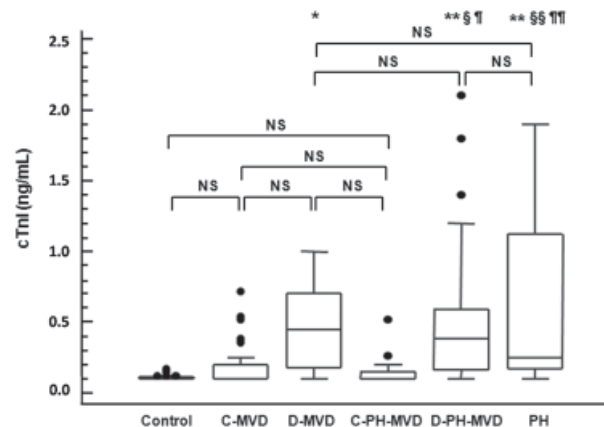


Fig. 2. Serum cardiac troponin I (cTnI) concentrations obtained from 26 healthy dogs, 34 dogs with compensated (ISACHC class Ia and Ib) mitral valve disease (C-MVD), 8 dogs with decompensated (ISACHC class II and III) mitral valve disease (D-MVD), 15 dogs with compensated mitral valve disease associated with pulmonary hypertension (C-PH-MVD), 33 dogs with decompensated mitral valve disease associated with pulmonary hypertension (D-PH-MVD), and 17 dogs with precapillary PH. The horizontal line in each box represents the median value. The boxes represent the interquartile range (25th to 75th percentile). Whiskers represent the 5th and 95th percentiles. Outliers are plotted separately as dots. *Statistical difference ($P < .01$) with control dogs; **Statistical difference ($P < .001$) with control dogs; §Statistical difference ($P < .05$) with control dogs; ¶Statistical difference ($P < .01$) with C-MVD; ¶¶Statistical difference ($P < .001$) with C-MVD; ¶¶¶Statistical difference ($P < .05$) with C-MVD; ¶¶¶¶Statistical difference ($P < .01$) with C-PH-MVD; ¶¶¶¶¶Statistical difference ($P < .001$) with C-PH-MVD; NS, not significant.

ular disease, and PH was more prevalent in dogs with decompensated CHF. These findings support that PH has a tendency to develop in the advanced stages of MVD, although nearly a third of dogs with PH-MVD had compensated CHF, as previously reported.¹² Dogs with PH-MVD had significantly higher cTnI concentration compared with dogs with MVD without PH indicating an increased myocardial damage in the former dogs. However, after subdividing all dogs with MVD (ie, either those with and without PH) according to the ISACHC classification score, only dogs with decompensated PH-MVD had significantly increased serum cTnI concentration compared with control dogs and dogs with compensated MVD, either with or without PH. On the contrary, cTnI did not differ between dogs with precapillary PH and dogs with decompensated MVD and PH-MVD. Furthermore, dogs with decompensated MVD, with or without PH, did not show any statistical difference in their cTnI concentration. Regarding the prevalent type of CHF, the development of PH in dogs with decompensated MVD was not associated with an increased prevalence of R-CHF compared with L-CHF. Irrespective of the underlying cause (ie, precapillary or postcapillary), right ventricular failure often represents the final common pathway portending a poor prognosis in humans with PH.⁴³ The prevalence of RVH was significantly higher in dogs with PH-MVD (33.3%) compared with dogs with MVD without PH, and was similar to the prevalence of right heart chambers enlargement (32.6%) observed in a previous study on dogs with MVD and Doppler-derived evidence of PH.¹² The aforementioned findings suggest that decompensated CHF is the primary inciting factor for myocardial damage in dogs with MVD followed by PH and RVH. Considering all dogs with MVD enrolled in the present study (ie, either those with and without PH), their overall cTnI concentration was higher compared with control dogs. In a previous study, dogs with compensated and decompensated MVD had higher cTnI concentration compared with healthy dogs.²⁸ In another study, dogs with MVD had higher cTnI concentration compared with healthy dogs, but dogs with compensated MVD did not show significant difference in cTnI levels compared with control dogs,²⁷ similarly to dogs of the present study. In the former study, a chemiluminescent sandwich ELISA technique with a lower limit of detection of 0.02 ng/mL was employed. In the latter study the same immunometric chemiluminescent assay system employed in our study was used. Different levels of sensitivity between the 2 cTnI assays may explain the above discrepancy, because results obtained with different cTnI analyzers do not agree sufficiently to be interchangeable.⁴⁴

The cTnI concentration had a modest but significant correlation with the left atrial size and left ventricular systolic and diastolic diameter in dogs with MVD and PH-MVD. These positive correlations are similar to those previously observed in dogs with MVD and cardiomyopathy.²⁸ Indeed, increased LA:Ao is the most significant variable for cardiac-related death in dogs with MVD and a significant positive correlation between left atrial and ventricular dimensions and PASP has already

been reported in the dog.^{12,45,46} Previously demonstrated associations between increased troponins concentration and severe prognosis in dogs with cardiac disorders include a decreased survival time in cardiomyopathy and negative prognostic indicator in acute myocardial damage associated with gastric dilatation-volvulus.^{28,29}

Different pathophysiological mechanisms may be responsible for increased circulating cTnI concentration in dogs with PH. Cardiac troponins are specific markers of cardiomyocyte injury which are detectable when either the right or left ventricle is injured.¹⁸ However, release from the right ventricle and subsequent troponins blood levels are low compared with those of the left ventricle because of differences in muscular mass.⁴⁷ Pressure overload of the right ventricle because of increased pulmonary arterial resistance leads to decreased myocardial perfusion and oxygen supply and, eventually, right ventricular dysfunction.³³ Furthermore, increased stress to the right ventricle is the cause of troponin increase in pulmonary embolism and increased cTnI concentration was associated with echocardiographic signs of right ventricular dilatation in humans with acute pulmonary embolism (APE).^{33,48-50} Thus, circulating troponins evaluation is considered highly sensitive for the early detection of minor myocardial cells injury in pulmonary embolism associated with right ventricular dysfunction.³³ Similarly, detectable serum cTnT is a strong independent marker of risk of death in patients with chronic precapillary PH, and patients with PTE and elevated cTnT have a worse prognosis than those without cTnT elevation.^{16,51} At the same time, severe PH induces lower systemic blood pressure and hypoxemia from perfusion-ventilation mismatch, thus resulting in decreased coronary perfusion gradient.^{15,51} In APE, myocardial necrosis can be caused by right ventricular infarction, which may be secondary to APE or can accompany this condition, even if coronary artery show no pathology.⁵⁰ Thus, the use of cardiac troponins for risk stratification of patients with APE may be limited, owing to the different mechanism of myocardial damage compared with that in patients with acute coronary syndrome.⁵¹ In particular, because of the complex release kinetics and clearance mechanisms of cardiac troponins, their circulating concentration in APE strictly depends on time elapsed from the onset of clinical signs.^{51,52} Therefore, the use of cTnI in risk stratification of APE might be limited to patients presenting early after onset of clinical signs.⁵² In dogs, disease conditions associated with precapillary PH mainly act through a chronic pathophysiological mechanism, because acute thromboembolic events are difficult to distinguish from other cardio-respiratory disorders.^{53,54} Reduced ventricular perfusion of both ventricles in the setting of precapillary PH as well as ongoing subclinical myocyte degeneration because of deterioration of clinical status in dogs with postcapillary PH-MVD are the likely causes of mild increases of cTnI observed in dogs with PH of the present study.

There are several limitations of this study that need emphasis. First, pulmonic or tricuspid valve regurgitation is not always detected in dogs with PH.^{5,8,55} Thus, it

is possible that some healthy dogs with PH but without detectable high velocity right-sided valvular regurgitation were included in the control group. Other echocardiographic techniques have been proposed for the indirect diagnosis of PH (ie, PW-Doppler evaluation of the pulmonic systolic flow profile, measurement of Doppler-derived systolic time intervals of pulmonary artery flow, and use of Doppler tissue imaging)^{1,5,55} but they are less commonly employed in the clinical setting compared with the Doppler evaluation of TR and PI velocity. However, PH was considered very unlikely in dogs without clinical, radiographic, and echocardiographic evidence of cardio-respiratory disorders. Second, dogs with MVD are also predisposed to development of concurrent broncho-pulmonary diseases leading to increased vascular resistance and, eventually, precapillary PH.¹² These diseases may be clinically silent and difficult to detect on thoracic radiographs because changes are masked by pulmonary edema.¹² Careful examination of thoracic radiographs of dogs with PH-MVD was particularly aimed to rule out concurrent respiratory disorders, although different cause-and-effect mechanisms of PH could not completely ruled out in dogs with postcapillary PH. Third, the type, degree, and distribution of myocardial damage were not assessed in dogs with PH. However, the accurate assessment of myocardial changes would have required histological examination of post-mortem tissue specimens or endomyocardial biopsy specimens, which was beyond the scope of our study. Finally, age and breed matching of the enrolled dogs would have strengthened the results of this prospective study, because a modest but significant positive correlation has been demonstrated between cTnI and age in the dog and some Terriers are predisposed to chronic pulmonary diseases leading to precapillary PH.^{5,8,28}

Footnotes

^a Atkinson KJ, Fine DM, Thombs LA, et al. Evaluation of pimobendan for therapy of canine pulmonary hypertension. *J Vet Intern Med* 2008;22:761–762 (abstract)

^b Aplio SSA-770A, Toshiba Medical Systems, Zoetermeer, the Netherlands

^c AU5 Epi, Esaote Biomedica, Florence, Italy

^d Immulite Troponin I, Diagnostic Products Corporation, Los Angeles, CA

^e SPSS 15.0 for Windows, SPSS Inc, Chicago, IL

^f GraphPad Prism 4.01 for Windows, GraphPad Software Inc, La Jolla, CA

Acknowledgments

The study was supported by a research fund of the University of Teramo. The authors are grateful for the assistance of the supporting technicians of the SEPAC-Vet of the Veterinary Clinical Department, University of Bologna.

References

1. Johnson L, Boon J, Orton EC. Clinical characteristics of 53 dogs with Doppler-derived evidence of pulmonary hypertension: 1992–1996. *J Vet Intern Med* 1999;13:440–447.
2. Pyle RL, Abbott J, MacLean H. Pulmonary hypertension and cardiovascular sequelae in 54 dogs. *Intern J Appl Res Vet Med* 2004;2:99–109.
3. Fleming E, Ettinger SJ. Pulmonary hypertension. *Compend Contin Educ Pract Vet* 2006;28:720–730.
4. Bach JF, Rozansky EA, MacGregor J, et al. Retrospective evaluation of sildenafil citrate as a therapy for pulmonary hypertension in dogs. *J Vet Intern Med* 2006;20:1132–1135.
5. Schober KE, Baade H. Doppler echocardiography prediction of pulmonary hypertension in West Highland White Terriers with chronic pulmonary disease. *J Vet Intern Med* 2006;20:912–920.
6. Galie N, Torbicki A, Barst R, et al. Guidelines on diagnosis and treatment of pulmonary arterial hypertension. The task force on diagnosis and treatment of pulmonary arterial hypertension of the European Society of Cardiology. *Eur Heart J* 2004;25:2243–2278.
7. Johnson LR, Hamlin RL. Recognition and treatment of pulmonary hypertension. In: Bonagura K, ed. *Current Veterinary Therapy*, XII ed. Philadelphia, PA: WB Saunders; 1995:887–891.
8. Corcoran BM, Cobb M, Martin MW, et al. Chronic pulmonary disease in West Highland White Terriers. *Vet Rec* 1999;144:611–616.
9. Glaus TM, Hassig M, Baumgartner C, Reusch CE. Pulmonary hypertension induced in dogs by hypoxia at different high-altitude levels. *Vet Res Commun* 2003;27:661–670.
10. Glaus TM, Soldati G, Maurer R, et al. Clinical and pathological characterisation of primary pulmonary hypertension in a dog. *Vet Rec* 2004;154:786–789.
11. Zabka TS, Campbell FE, Wilson DW. Pulmonary arteriopathy and idiopathic pulmonary arterial hypertension in six dogs. *Vet Pathol* 2006;43:510–522.
12. Serres FJ, Chetboul V, Tissier R, et al. Doppler echocardiography-derived evidence of pulmonary arterial hypertension in dogs with degenerative mitral valve disease: 86 cases (2001–2005). *J Am Vet Med Assoc* 2006;229:1772–1778.
13. Kellum HB, Stepien RL. Sildenafil citrate therapy in 22 dogs with pulmonary hypertension. *J Vet Intern Med* 2007;21:1258–1264.
14. Rich S, McLaughlin VV. Pulmonary hypertension. In: Zipes DP, Libby P, Bonow RO, Braunwald E, eds. *Braunwald's Heart Disease: A Textbook of Cardiovascular Medicine*, 7th ed. Philadelphia, PA: Elsevier Saunders; 2005:1807–1842.
15. Wensel R, Opitz CF, Anker SD, et al. Assessment of survival in patients with primary pulmonary hypertension: importance of cardiopulmonary exercise testing. *Circulation* 2002;106:319–324.
16. Torbicki A, Kurzynna M, Kuca P, et al. Detectable serum cardiac troponin T as a marker of poor prognosis among patients with chronic precapillary pulmonary hypertension. *Circulation* 2003;108:844–848.
17. Wells SM, Sleeper M. Cardiac troponins. *J Vet Emerg Crit Care* 2008;18:235–245.
18. Babuin L, Jaffe AS. Troponin: The biomarker of choice for the detection of cardiac injury. *Can Med Assoc J* 2005;173:1191–1202.
19. Rishniw M, Barr SC, Simpson KW, et al. Cloning and sequencing of the canine and feline cardiac troponin I genes. *Am J Vet Res* 2004;65:53–58.
20. Sleeper MM, Clifford CA, Laster LL. Cardiac troponin I in the normal dog and cat. *J Vet Intern Med* 2001;15:501–503.
21. Adin DB, Milner RJ, Berger KD, et al. Cardiac troponin I concentrations in normal dogs and cats using a bedside analyzer. *J Vet Cardiol* 2005;7:27–32.

22. Schober KE, Kirback B, Oechtering G. Noninvasive assessment of myocardial cell injury in dogs with suspected cardiac contusion. *J Vet Cardiol* 1999;1:17–25.
23. Schober KE, Cornand C, Kirbach B, et al. Serum cardiac troponin I and cardiac troponin T concentrations in dogs with gastric dilatation-volvulus. *J Am Vet Med Assoc* 2002;221:381–388.
24. Lobetti R, Dvir E, Pearson J. Cardiac troponins in canine babesiosis. *J Vet Intern Med* 2002;16:63–68.
25. DeFrancesco TC, Atkins CE, Keene BW, et al. Prospective clinical evaluation of serum cardiac troponin T in dogs admitted to a veterinary teaching hospital. *J Vet Intern Med* 2002;16:553–557.
26. Shaw SP, Rozanski EA, Rush JE. Cardiac troponin I and T in dogs with pericardial effusion. *J Vet Intern Med* 2004;18:322–324.
27. Spratt DP, Mellanby RJ, Drury N, et al. Cardiac troponin I: Evaluation of a biomarker for the diagnosis of heart disease in the dog. *J Small Anim Pract* 2005;46:139–145.
28. Oyama MA, Sisson DD. Cardiac troponin-I concentration in dogs with cardiac disease. *J Vet Intern Med* 2004;18:831–839.
29. Burgener IA, Kovacevic A, Mauldin N, et al. Cardiac troponins as indicators of acute myocardial damage in dogs. *J Vet Intern Med* 2006;20:227–283.
30. Linde A, Summerfield NJ, Sleeper MM, et al. Pilot study on cardiac troponin I levels in dogs with pericardial effusion. *J Vet Cardiol* 2006;8:19–23.
31. Baumwart RD, Orvalho J, Meurs KM. Evaluation of serum cardiac troponin I concentration in Boxers with arrhythmogenic right ventricular cardiomyopathy. *Am J Vet Res* 2007;68:524–528.
32. Pelander L, Häggström J, Jones B. Troponin I – a possible marker of myocardial cell damage in the dog? *Eur J Comp Anim Pract* 2002;12:66–71.
33. Meyer T, Binder L, Hruska N, et al. Cardiac troponin I elevation in acute pulmonary embolism is associated with right ventricular dysfunction. *J Am Coll Cardiol* 2000;36:1632–1636.
34. Douketis JD, Crowther MA, Stanton EB, et al. Elevated cardiac troponin levels in patients with submassive pulmonary embolism. *Arch Intern Med* 2002;162:79–81.
35. Adam T, Kurzyna M, Kuca P, et al. Detectable serum cardiac troponin T as a marker of poor prognosis among patients with chronic precapillary pulmonary hypertension. *Circulation* 2003;108:844–848.
36. Konstantinides S, Geibel A, Olschewski M, et al. Importance of cardiac troponins I and T in risk stratification of patients with acute pulmonary embolism. *Circulation* 2002;106:1263–1268.
37. Thomas W P, Gaber CE, Jacobs J, et al. Recommendations for standards in transthoracic two-dimensional echocardiography in the dog and cat. *J Vet Intern Med* 1993;7:247–252.
38. Boon JA. Evaluation of size, function and hemodynamics. In: Boon JA, ed. *Manual of Veterinary Echocardiography*. Baltimore, MD: Williams & Wilkins Co; 1998:151–260.
39. Kittleson MD, Kienle RD. Pulmonary arterial and systemic arterial hypertension. In: Kittleson MD, Kienle RD, eds. *Small Animal Cardiovascular Medicine*. Saint Louis, MO: Mosby; 1998:433–439.
40. International Small Animal Cardiac Health Council. Recommendations for diagnosis of heart disease and treatment of heart failure in small animals. In: Fox PR, Sisson D, Moïse NS, eds. *Textbook of Canine and Feline Cardiology*, 2nd ed. Philadelphia, PA: WB Saunders; 1999:883–901.
41. Mastrorilli C, Dondi F, Agnoli C, et al. Clinicopathologic features and outcome predictors of *Leptospira interrogans* australis serogroup infection in dogs: Retrospective study of 20 cases (2001–2004). *J Vet Intern Med* 2007;21:3–10.
42. Uzuelli JA, Dias-Junior CA, Tanus-Santos JE. Severity dependent increases in circulating cardiac troponin I and MMP-9 concentrations after experimental acute pulmonary thromboembolism. *Clin Chim Acta* 2008;388:184–188.
43. McDonald MA, Ross HJ. Trying to succeed when the right ventricle fails. *Curr Opin Cardiol* 2009;24:239–245.
44. Adin DB, Oyama MA, Sleeper MM, et al. Comparison of canine cardiac troponin I concentrations as determined by 3 different analyzers. *J Vet Intern Med* 2006;20:1136–1142.
45. Borgarelli M, Savarino P, Crosara S, et al. Survival characteristics and prognostic variables of dogs with mitral regurgitation attributable to myxomatous valve disease. *J Vet Intern Med* 2008;22:120–128.
46. Chiavegato D, Borgarelli M, D’Agnolo G, Santilli RA. Pulmonary hypertension in dogs with mitral regurgitation attributable to myxomatous valve disease. *Vet Radiol Ultrasound* 2009;50:253–258.
47. Logeart D, Lecuyer L, Thabut G, et al. Biomarker-based strategy for screening right ventricular dysfunction in patients with non-massive pulmonary embolism. *Intensive Care Med* 2007;33:286–292.
48. Roongsritong C, Warraich I, Bradley C. Common causes of troponin elevations in the absence of acute myocardial infarction: Incidence and clinical significance. *Chest* 2004;125:1877–1884.
49. Giannitsis E, Muller-Bardoff M, Kurowsky V, et al. Independent prognostic value of cardiac troponin T in patients with confirmed pulmonary embolism. *Circulation* 2000;102:211–217.
50. Mikulewicz M, Lewczuk J. Importance of cardiac biomarkers in acute pulmonary embolism. *Cardiol J* 2008;15:17–20.
51. Becattini C, Vedovati MC, Agnelli G. Diagnosis and prognosis of acute pulmonary embolism: Focus on serum troponins. *Expert Rev Mol Diagn* 2008;8:339–349.
52. Punukollu G, Khan IA, Gowda RM, et al. Cardiac troponin I release in acute pulmonary embolism in relation to duration of symptoms. *Int J Cardiol* 2005;99:207–211.
53. Johnson L, Lappin MR, Baker DC. Pulmonary thromboembolism in 29 dogs: 1985–1995. *J Vet Intern Med* 1999;13:338–345.
54. MacDonald KA, Johnson LR. Pulmonary hypertension and pulmonary thromboembolism. In: Ettinger SJ, Feldman EC, eds. *Textbook of Veterinary Internal Medicine*, 6th ed. Philadelphia, PA: Elsevier Saunders; 2005:1284–1288.
55. Serres FJ, Chetboul V, Gouni V, et al. Diagnostic value of echo-Doppler and Doppler tissue imaging in dogs with pulmonary arterial hypertension. *J Vet Intern Med* 2007;21:1280–1289.