


This article was downloaded by:[Riz Orthopedic Inst]
On: 6 December 2007
Access Details: [subscription number 741802781]
Publisher: Informa Healthcare
Informa Ltd Registered in England and Wales Registered Number: 1072954
Registered office: Mortimer House, 37-41 Mortimer Street, London W1T 3JH, UK



Acta Orthopaedica

Publication details, including instructions for authors and subscription information:
<http://www.informaworld.com/smpp/title~content=t713400243>

Bone grafting: historical and conceptual review, starting with an old manuscript by Vittorio Putti

Davide Donati ^a; Carola Zolezzi ^b; Patrizia Tomba ^c; Anna Viganò ^c

^a V Divisione Ortopedica, Istituto Ortopedico Rizzoli, Bologna, Italy

^b Lab. Patologia Clinica, Istituto Ortopedico Rizzoli, Bologna, Italy

^c Biblioteca Scientifica, Istituto Ortopedico Rizzoli, Bologna, Italy

Online Publication Date: 01 February 2007

To cite this Article: Donati, Davide, Zolezzi, Carola, Tomba, Patrizia and Viganò, Anna (2007) 'Bone grafting: historical and conceptual review, starting with an old manuscript by Vittorio Putti', Acta Orthopaedica, 78:1, 19 - 25

To link to this article: DOI: 10.1080/17453670610013376

URL: <http://dx.doi.org/10.1080/17453670610013376>

PLEASE SCROLL DOWN FOR ARTICLE

Full terms and conditions of use: <http://www.informaworld.com/terms-and-conditions-of-access.pdf>

This article maybe used for research, teaching and private study purposes. Any substantial or systematic reproduction, re-distribution, re-selling, loan or sub-licensing, systematic supply or distribution in any form to anyone is expressly forbidden.

The publisher does not give any warranty express or implied or make any representation that the contents will be complete or accurate or up to date. The accuracy of any instructions, formulae and drug doses should be independently verified with primary sources. The publisher shall not be liable for any loss, actions, claims, proceedings, demand or costs or damages whatsoever or howsoever caused arising directly or indirectly in connection with or arising out of the use of this material.

Bone grafting: historical and conceptual review, starting with an old manuscript by Vittorio Putti

Davide Donati¹, Carola Zolezzi², Patrizia Tomba³ and Anna Viganò³

¹V Divisione Ortopedica, ²Lab. Patologia Clinica, ³Biblioteca Scientifica, Istituto Ortopedico Rizzoli, Bologna, Italy
Correspondence DD: davide.donati@ior.it
Submitted 06-02-13. Accepted 06-05-19

ABSTRACT Vittorio Putti has been recognized as one of the founders of orthopedic science. He wrote a number of original papers on different topics from his vast experience of orthopedics. In a paper on bone grafting dated 1912, Putti demonstrated his modern way of thinking by his ability to study past experiences critically and by his willingness to compare his own experiences with those of other orthopedic surgeons. Putti's paper proposes principles that still apply today, and which can be considered as the basis of the modern science of grafting. The results of his work can be summarized as follows:

- a) The uniformity of bone graft integration processes, and a marked reduction in integration capacity in heteroplastic grafts.
- b) The osteogenetic incapability of the graft as opposed to the osteogenetic capability of the periosteum.
- c) Marked reduction in the biological capability of bone that has been treated with preservatives, boiled, or macerated.
- d) The importance of the quality of the tissues in which the bone graft is inserted, including the mechanical characteristics of the graft and its fixation.
- e) The importance of asepsis.
- f) The importance of functional exercise.

These important experiences were achieved without Putti having any knowledge of immunology, vascular surgery, tissue preservation or non decalcified histology techniques.

By digitalizing the content of the Rizzoli Orthopaedic Institute Library, a census of Vittorio Putti's scientific work could be carried out.



Figure 1. Professor Vittorio Putti in operating room.

Vittorio Putti (1880–1940), the director of the Rizzoli Orthopaedic Institute of Bologna from 1912 to 1940, was interested in all the major problems of orthopedics and introduced new methods and surgical instruments especially for the treatment of congenital dislocation of the hip, arthritis, arthroplasty, open treatment of subluxation of the shoulder, spinal abnormalities, cineplastic amputations, and artificial limbs (Figure 1).

Putti was a founder of the S.I.C.O.T. (Società Internazionale de Chirurgia Orthopedica et Traumatologica), Honorary Member of the American and British Orthopaedic Associations, and Foreign Editor of the *Journal of Bone and Joint Surgery* from January 1928 (Putti 1940, Benini et al. 1995).

Among the numerous documents of Professor Putti that aroused our curiosity and wonder there was a manuscript about bone grafting that contained a paper presented at the Seventh Congress of the Italian Society of Orthopedics in 1912. The indications, method and technique of bone grafting form the main body of the manuscript, which is supplemented with the statistics of cases known to the author that appeared in the literature after 1910—as a continuation of the series of cases published by Streissler the year before (Streissler 1910, Putti 1912). Starting from Putti's work, we have tried to reconstruct a short history of the science of grafting (1) in order to assess the state of the art at Putti's time, and (2) to publicize the surprising validity of his concepts a century later.

Historical description

Grafting of a bone fragment or transplanting a limb from one human being to another has preoccupied mankind for thousands of years. The first homologous transplant was described in the Old Testament when one of Adam's ribs was used to create Eve. Greek mythology also contains episodes of implants and replacement of body parts, as seen in the legend of Zeus who had Demeter make an ivory shoulder for Tantalus' son, Pelops, after she had absent-mindedly eaten it (Older 1992). It is not a coincidence that mythology described ivory as a reconstruction material; Putti himself stated: "among osteoplastic materials, ivory deserves a mention..." and "small sticks, nails, and splints made of ivory are well tolerated by the organism, and widely used in the treatment of nonunion..." and he remembered that "Gluck proposed the replacement of joints with ivory ones" (Putti 1912).

Medical science is almost as old as mankind itself and has had religious, philosophical, paleontological, and ethnological implications. Surgical intervention existed even in prehistoric times: paleopathologic research has revealed fractures, rickets,

and drilled skulls that represent processes of bone regeneration. The finding of a Peruvian tribal chief, dating back to the Neolithic age, revealed a defect in his frontal bone that had been repaired by a gold plate applied with a hammer (Urist 1994). The Aztecs of Central America described treatment of bone fractures by realigning the parts perfectly and splinting. If this failed, it was recommended that a wooden stick should be inserted into the medullary canal (Urist et al. 1994).

The anthropologist A. Jagharian, head of operative surgery at the Erivan Medical Institute in Armenia, examined 2 skulls from the ancient center of Ishtkunui, not far from Lake Sevan. In 2000 BC, this was inhabited by a prehistoric people known as the Khurits. In the first skull the prehistoric surgeons had inserted a piece of animal bone into a 7-mm defect caused by injury. We know that the patient survived, because the cranium, examined millennia later, showed regrowth around the grafted bone. The second cranium had signs of surgical intervention to repair a lesion produced by a sharp instrument that had made a 2.5-cm defect and splintered the bone. The findings showed that the surgeons had removed the splinter and the patient had lived for at least 15 years after the operation (Flati et al. 2004).

The Egyptians were also advanced in dental surgery and bone surgery in general. There are accounts of orthopedic operations performed on various segments of the human body and radiographic tests of the mummy of the priest Usermontu, which is preserved at San José museum in California and belonged to the 26th dynasty (656–525 BC), revealed that the left leg around the knee had a 23-cm prosthesis. This had been inserted by a complex surgical procedure. Further images showed that the prosthesis had been made of pure iron, cemented with a resin, and had been inserted while the priest was still alive. The Egyptians also applied artificial limbs; indeed, there is one account of a woman who was found to have undergone amputation and to have been given a wooden leg replacement, which, although simple in design, had been efficacious and had allowed the woman to live for many years after the operation.

There is no scientifically reliable evidence to support these accounts, but we certainly know that the ancient Egyptians had a great knowledge of orthope-

dics—as demonstrated in Smith’s papyrus, which is acknowledged as a treatise on orthopedics and traumatology (Hamada and Rida 1972, Zacco 2002). The ancient Greeks Herophilus and Erasistratus, of the Alexandrian school (third and second centuries BC), gave impetus to surgery, and, thanks to that school, the Roman surgeons could perform difficult operations such as amputation and tumor resection (Urist 1994). Progress throughout the centuries and the desire to replace anatomical parts that have been lost to injury, illness or defects have continued to arouse mankind’s curiosity and to inspire artists. The latter mixed science, religion, and imagination—and portrayed extraordinary healing.

In medieval times, many pictures were painted depicting traumaturgic events, but the most famous one from an orthopedic point of view is the miracle of Saints Cosmas and Damian painted by Fra Angelico: “the black leg miracle”, showing the homoplastic transplantation of the limb of an Ethiopian, buried a few hours earlier, onto the sacristan Justinian (Rinaldi 1987). Besides the legend and profound veneration for the two saints at the time, the “black leg miracle” can be interpreted as mankind’s desire to perform complex orthopedic operations and it lays the foundations for the concept of donor and host in modern transplantation techniques.

The modern age begins with the work of the surgeon Job van Meekeren who, in 1668, performed the first heterologous graft by inserting a fragment of dog skull into the skull of an injured soldier. The operation was successful but, because an animal graft was being used on a Christian, there were religious repercussions, and the soldier was excommunicated. The success of the operation was testified by the fact that when the soldier asked the surgeon to remove the fragment so that he could be readmitted into the church, the fragment had been fully incorporated (De Boer 1988).

In the seventeenth and eighteenth centuries orthopedic surgeons focused their attention on the structure of bone, which was described for the first time in 1674 by Antoni van Leeuwenhoek in *Philosophical Transactions*, concerning what would become known as Haversian canals. The concepts of bone callus, implant and resorption began to be outlined. In 1743, Duhamel published the results of his experiments on animals and suggested that

the periosteum has a pivotal role in the process of osteogenesis (De Boer 1988, Glicenstein 2000). Most operations requiring bone resection were for nonunion, which was often treated by amputating the limb. A technique called “sub-periosteal resection”—based on Duhamel’s theory of the importance of the periosteum in bone regeneration—was widespread until halfway through the nineteenth century, and it was used by many surgeons for the treatment of nonunion. In 1820, the first autologous graft was performed in Germany by the surgeon Philips von Walter, who replaced a fragment of cranium after trepanation.

More recently, a surgeon from Lyon, Leopold Ollier, studied the phenomenon of bone regeneration and in 1861 he published “*Traité de la régénération des os*”, a document describing the term bone graft (“greffe osseuse”) for the first time. In that publication, cited by Putti in 1912 as “an immortal work on bone generation”, Ollier maintained that “implanted bone fragments are viable if they include the periosteum, which is the most important viability factor of the graft” (Putti 1912, De Boer 1988). Ollier achieved an authoritative position with his theories and opened the way for complex experimental and clinical observations in bone grafting. At the same time, however, Barth achieved different results and stated—as summarized by Putti—that the bone, periosteum and marrow in the graft die and are replaced by newly generated bone. The cells of the implanted bone would thus die within a few days and then the implant, formed by dead bone, would be reabsorbed and replaced by newly formed bone produced by the cells of the living surrounding bone. The difference of opinion between Ollier and Barth prompted their contemporary fellow surgeons to study this phenomenon in greater depth and, as Putti stated in his report, even Codivilla took part in this research at Rizzoli Orthopaedic Institute (Putti 1912).

The grafts used by Ollier and his contemporaries, around 1860, were of autologous origin. Non-autologous grafts were not taken into consideration for many years. The reason for this is unknown; perhaps it was for religious reasons or because of the memory of Van Meekren’s operation performed two centuries earlier. It was not until 1880 that homologous bone was used, when

the Scottish surgeon William Macewen inserted a graft of tibia from a child affected by rickets into the infected humerus of another child (De Boer 1988). In the years that followed, he replaced a mandibular fragment with a graft of rib bone. Several difficulties had to be overcome before attempting a heterologous graft. However, in 1891 Phelps, following Curtis' hypothesis that "the ideal implant should be formed by living bone that fits the gap perfectly and continues to live without reabsorbing" (Urist et al. 1994), performed an experiment whereby a piece of bone from a dog was inserted into the tibial defect of a boy. Both donor and host were attached to each other for 2 weeks so that the blood could circulate between the two patients; then, by remaining vascularized, the graft could activate the growth of new bone in the boy's limb. After about 15 days, the two patients were separated. The boy's bone graft was irregularly covered in new bone, and both patients had a brief convalescence (Peltier 2000).

Putti's report of 1912

In Putti's work, the state of the art up to 1912 is reviewed; the work of previous authors and that of his contemporaries is assessed and conclusions drawn about it. He cited several authors regarding clinical and experimental observations on animals, and focused especially on the work of Ollier, Barth, Axhausen, and Macewan. He also described his personal experience and gave clinical indications (fracture, pseudarthrosis, arthrodesis, deformity lengthening and joint replacement) regarding ways of using the different types of grafts. It is worth pointing out this author's modern way of thinking, which can be summarized as follows:

1. The ability to be critical; review of case series.

In the preface, Putti cites a few words by Ollier: "the periodical revision of previous facts is one of the necessities (...) of a science", thus laying down the foundations of modern science, which is based on comparing series.

2. The uniformity of bone graft integration processes.

All grafts behave in the same way, but there is a qualitative difference between autoplasmic and homoplasmic bone, which is much more marked compared to heteroplasmic bone.

3. The marked reduction in integration capability of heteroplasmic grafts.

Putti said of heteroplasmic grafts "experience has shown that it cannot compare to autoplasmic and homoplasmic bone" and he went on to cite cases in which some contemporary surgeons used fresh calf, rabbit femur, and lamb tibia bone grafts. The same theories were supported by Phemister's experiments, who (in 1914) reported studies on dogs in which fragments of autologous bone had been grafted. The author stated that "it has been sufficiently demonstrated that bone from animals of the same species behaves in the same way as if it had come from the same animal, but with slightly reduced powers, and that a graft from a different species acts in the same way as dead bone or a foreign body" (Phemister 1914).

4. The lack of osteogenetic potential of grafts.

The graft does not take root by osteogenesis, but from the effect of the surrounding tissues. In fact, the tissue component of the graft dies and must be replaced.

5. The osteogenetic potential of the periosteum.

Putti rigorously reported the contrasting proposals of Ollier and Barth, and after careful consideration—taking into account all the experience known at that time—he accepted Ollier's theory extending the osteogenetic capability of the periosteum to autologous and homologous grafts. Nowadays, we know that it is only in autologous grafts that some cells able to activate a repair osteogenesis survive. This does not occur in homoplasmic or heteroplasmic grafts. For this reason, in homologous grafting we prefer nowadays to remove the periosteum (as all other surrounding tissue), because it impairs repair processes.

6. The marked reduction in the biological capability of bone that has been treated with preservatives, boiled, or macerated.

7. The importance of the quality of the tissues where the bone graft is inserted.

With regards to the grafting technique he said, "incisions should be made in such a way as to prevent the wounds from being in direct contact with the bone region that has received the graft. This region should be protected by large layers of soft tissue". Thus, he showed that he understood the importance of the conditions the graft is placed in.

8. *The importance of the mechanical characteristics of the graft and its fixation.*

“There are, in fact, technical conditions that are indispensable for a successful graft, and the most important of these is the mechanical strength and the morphology of the graft that replaces the missing bone... Experimentation and clinical tests have shown that for the graft to take root, not only should it be as viable as possible, but from the very beginning it should have a strong relationship with the host...” Putti, therefore, stated the need to use homoplastic grafts (although he considered them to be biologically inferior to autoplasmic ones), and above all the importance of a strong fixation.

9. *The importance of asepsis.*

With regard to the grafting technique, Putti stated that “the replacement of a bone segment by grafting can only be successful if healing takes place under aseptic conditions. If asepsis is not guaranteed, if the host environment or the graft is infected, if we fail to protect the operating field from external contamination, the graft is bound to fail”. These are the foundations of a modern bone bank, which must provide grafts free from contamination and ensure asepsis in the operating field.

10. *The importance of functional exercise.*

In a very modern way, Putti observed that “immobilization does not mean immobility. Functional exercise is the most necessary stimulus for the graft to take root; without it the graft remains in the organism like a foreign body, which being unneeded is bound to die”.

Discussion

First of all, we should acknowledge the impressive clarity of Putti’s affirmations. By looking at the manuscript, we can see that most of it was written without erasing or overwriting, which shows just how clear these principles must have been in Putti’s mind.

It should also be pointed out that his own experience and that of others led him to introduce new theories on the clinical application of grafts and their evolution. In this respect, the paragraph in which he proposes new possibilities of lengthening a tubular bone by distracting the growth plate in children, or even the grafting of growth plate

cartilage into adults, is amazing (Langenskiöld 1957).

Naturally, compared to current knowledge, there were some weak points in Putti’s work that were due in particular to biased observations. In some cases, comparison of clinical and experimental observations with different types of grafts used in different clinical indications led to diametrically opposing results. However, their incorrect setup was often derived from failure to develop technical means to be able, for example, to differentiate newly formed bone from grafted bone with any degree of certainty. In fact, Putti—in reference to Axhausen’s work—stated that “the way reabsorption and replacement of the grafted bone occurs remains uncertain...” and concluded by adding, “this aspect is not very important from a practical point of view” (Figure 2). In 1914, Plemister took a step forward when he introduced the modern concept of bone reabsorption, which he interpreted as a phenomenon called “creeping substitution” of old bone by new bone, and stated that, “the living cells on the graft surface proliferate and deposit around the graft lamellae of new bone that gradually replace the dead part inside the graft. The time needed to accomplish this replacement may vary from three months to a year, or even longer depending on the size and thickness of the graft” (Plemister 1914). Plemister’s estimation of time to replace the graft allows us to say that the histological interpretation of bone viability was still not very clear.

Another question not settled by Putti was the role played by the bone marrow. The text refers several times to authors who recommended exposing the bone marrow to improve the taking of the bone (Axhausen), but it also mentions Barth and Lexter who advised removing it. The latter author believed that, “it causes inflammation and temperature increase”. By this, it is obvious that theories on immune response were not yet within the grasp of these authors, although some of them highlighted the risk associated with adverse reactions caused by non-septic graft material.

Finally, the role of vascularization in repair processes was not yet clear at that time. Putti mentioned Hahn, who was the first to describe the so-called “pedicled graft” of the fibula. However, the rare indication for use and the rather poor mechanical capability of this type of implant led the author

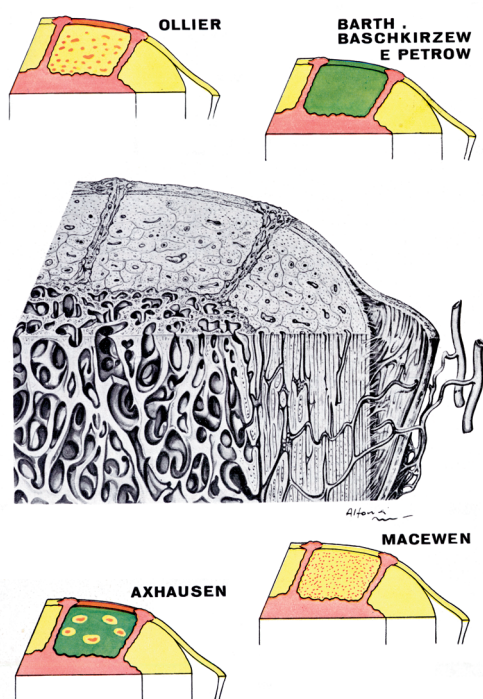


Figure 2. There were contrasting opinions about the biological activity of graft integration. Ollier: the autoplasmic graft survives the operation and is renewed by cells of the periosteum and bone marrow. Barth: the whole graft dies and the connective cells of the host regenerate it. Axhausen: the graft substance undergoes necrosis except for some thin layers arranged under the periosteum and Haversian canals. Instead: the periosteum and medullary element survive, and are responsible for renewing the material. Macewen: the osteocytes of the graft are not damaged by the operation and carry out the healing process, regardless of the cell elements of the periosteum and bone marrow which are not indispensable for bone production.

Green = necrotic bone. Yellow = living bone. Red = newly formed bone. Orange = graft soft tissue that survived the operation.

to underestimate its potential. In particular, Putti failed to fully understand the advantage of maintaining the vascular pedicle, and therefore did not make the fundamental discrimination between grafting and an actual transplant (Figure 3).

The concept of vascularization, necessary for the success of a transplant, developed later with the work of Carrel (a Nobel prizewinner in medicine) and Guthrie (Carrel and Guthrie 1906). Carrel can be considered to be the first vascular surgeon to open the way for future vascularized transplants, which were performed for the first time in 1975 by Taylor in Australia (De Boer 1988).

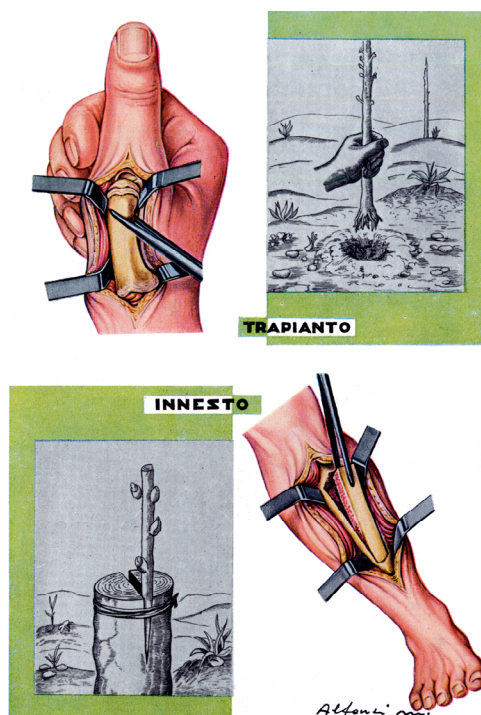


Figure 3. The author used this pictures to define a transplant by drawing an analogy between bones and plants. "The operation is performed on whole organs with or without immediate construction of the vascular connections (transplants); or on portions of organs (graft) when clearly dealing with living tissue". This shows that even after Putti, for long time, the role of the vascular pedicle was not exactly clear in the difference between grafts and transplants.

From Vigliani F. "Trapianti ossei". Relazione al XLIII Congresso della Società Italiani di Ortopedia e Traumatologia, Padova, 19–21 ottobre, 1958.

The history of grafting continues with the authoritative publications of F. H. Albee on the surgery of bone implants. In 1915 he introduced the "rules for using bone grafts", which still apply today (Peltier 1996). In an article published in 1932, he also defined the principles and use of bone grafts and published good results in 810 operations performed for nonunions in the limbs. The grafts used by Albee were all autologous, from the iliac, trochanter, tibia, metatarsal, olecranon, fibula, or cranium (Glicenstein 2000).

In the first half of the last century, there was widespread use of bone graft implants and numerous

articles were published on the subject. In an article published in the *Journal of Bone and Joint Surgery* in 1942, Inclan presented a large number of operations performed with autologous and homologous implants and also considered the difficulties that may be encountered in finding grafts suitable for the operation to be performed. At that time, problems related to the immune response were known, and the author stated that when the autologous graft is difficult to perform, a homologous graft between living patients of the same blood group can be performed—whereas grafts cannot be used from cadavers on sentimental and religious grounds (Inclan 1942). Inclan and his contemporaries had already begun to hint at the modern concept of storing bone material for different needs.

The preservation technique—described by the author as routine—consisted of placing the graft, immersed in the donor's blood or that of the host, in a sterile glass container. The graft was then kept in a refrigerator at a temperature of 2–5°C until it was used. In addition, during the period of preservation bacteriological tests were performed every 3–14 days on average, and in rare cases after 70 days (Inclan 1942).

Modern bone banks to store material for operations were only possible after the evolution of cooling techniques. In 1947, Bush and Wilson reported the need to preserve bone grafts at a temperature of –20°C, and they managed to build a bone bank for small fragments (Bush 1947, Wilson 1947). In 1951, Mouly and Sicard (at Beaujon di Cliché Hospital) and Herbert (at Aix-les-Bains) founded the first bone banks in France. Poitout described the way they worked in 1985 (Glicenstein 2000), but the first large bank for frozen osteoarticular grafts was already running in 1970 (Gross et al. 1983, 1993, Mankin et al. 1983).

Benini A, Böni Th, Vigano A. Vittorio Putti. *Spine* 1995; 20: 1728–31.

Bush L F. The use of homogenous bone grafts. *J Bone Joint Surg* 1947; 29: 620–8.

Carrel A, Guthrie C C. Results of a replantation of the thigh. *Science* 1906; 23: 393–7.

De Boer H H. The history of bone grafts. *Clin Orthop* 1988; (226): 293–8.

Flati G, Di Stanislao C. Chirurgia nella preistoria. Parte I. *Provincia Med.Aquila* 2004; 2: 8–11.

Glicenstein J. Histoire de la reconstruction osseuse. *Ann Chir Plast Esthét* 2000; 45: 171–4.

Gross A E, McKee N H, Pritzker K P, Langer F. Reconstruction of skeletal deficits at the knee, a comprehensive osteochondral transplant program. *Clin Orthop* 1983; (174): 96–106.

Gross T P, Cox Q, Jinnah R H. History and current application of bone transplantation. *Orthopedics* 1993; 16: 895–900.

Hamada G, Rida A. Orthopaedics in ancient and modern Egypt. *Clin Orthop* 1972; (89): 253–68.

Inclan A. The use of preserved bone graft in orthopaedic surgery. *J Bone Joint Surg* 1942; 24: 81–96.

Langenskiöld A. Inhibition and stimulation of growth. *Acta Orthop Scand* 1957; 26: 296–308.

Mankin H J, Doppelt S, Tomford W. Clinical experience with allograft implantation. *Clin Orthop* 1983; (174): 69–86.

Older J. Introduction: history and research on bone transplantation. In: *Bone implant grafting* (Ed. Older J). London, Springer-Verlag, 1992: XV–XVIII.

Peltier L F. Bone-graft surgery. *Clin Orthop* 1996; (324): 5–12.

Peltier L F. Transplantation of tissue from lower animals to man. *Clin Orthop* 2000; (371): 3–9.

Pemister D B. The fate of transplanted bone and regenerative power of its various constituents. *Surg, Gynecol Obstet* 1914; 19: 303–33.

Putti V. I trapianti ossei. *Arch Ortop* 1912; 29: 294–334.

Putti V. Vittorio Putti 1880–1940 (obituary). *N Engl J Med* 1940; 223: 955–6.

Rinaldi E. Il primo trapianto omoplastico di un arto secondo la leggenda dei santi Cosma e Damiano. *G. Ital. Ortop Traumatol* 1987; 13: 405–17.

Streissler E. Der gegenwärtige Stand unserer klinischen Erfahrungen über die Transplantation lebenden menschlichen Knochens. *Beitr Klin Chir* 1910; 71: 1–202.

Urist M R, O'Connor B T, Burwell R G (eds.). *Bone graft, derivatives & substitutes*. Cambridge, Butterworth-Heinemann, 1994: 3–102.

Vittorio Putti 1880–1940 (obituary) *N Eng J Med* 1940; 223: 955–6.

Wilson P D. Experiences with a bone bank. *Ann Surg* 1947; 126: 932–46.

Zacco R. *La cultura medica nell'antico Egitto*. Bologna, Ed. Martina, 2002: 76–9.