



Veterinary Quarterly

Publication details, including instructions for authors and subscription information:
<http://www.tandfonline.com/loi/tveq20>

Hyperplastic cholangitis in a naturally *Toxoplasma gondii*-infected cat

Anna S. De Tommasi^a, Maria Morini^b, Maria E. Turba^c, Domenico Otranto^a & Giuliano Bettini^b

^a Department of Veterinary Medicine, University of Bari Aldo Moro, Bari, Italy

^b Department of Veterinary Medical Sciences, Alma Mater Studiorum-Università di Bologna, Bologna, Italy

^c Genefast Lab, Bologna, Italy

Accepted author version posted online: 20 Oct 2014. Published online: 14 Nov 2014.



CrossMark

[Click for updates](#)

To cite this article: Anna S. De Tommasi, Maria Morini, Maria E. Turba, Domenico Otranto & Giuliano Bettini (2014) Hyperplastic cholangitis in a naturally *Toxoplasma gondii*-infected cat, *Veterinary Quarterly*, 34:4, 229-231, DOI: [10.1080/01652176.2014.978510](https://doi.org/10.1080/01652176.2014.978510)

To link to this article: <http://dx.doi.org/10.1080/01652176.2014.978510>

PLEASE SCROLL DOWN FOR ARTICLE

Taylor & Francis makes every effort to ensure the accuracy of all the information (the "Content") contained in the publications on our platform. However, Taylor & Francis, our agents, and our licensors make no representations or warranties whatsoever as to the accuracy, completeness, or suitability for any purpose of the Content. Any opinions and views expressed in this publication are the opinions and views of the authors, and are not the views of or endorsed by Taylor & Francis. The accuracy of the Content should not be relied upon and should be independently verified with primary sources of information. Taylor and Francis shall not be liable for any losses, actions, claims, proceedings, demands, costs, expenses, damages, and other liabilities whatsoever or howsoever caused arising directly or indirectly in connection with, in relation to or arising out of the use of the Content.

This article may be used for research, teaching, and private study purposes. Any substantial or systematic reproduction, redistribution, reselling, loan, sub-licensing, systematic supply, or distribution in any form to anyone is expressly forbidden. Terms & Conditions of access and use can be found at <http://www.tandfonline.com/page/terms-and-conditions>

CASE REPORT

Hyperplastic cholangitis in a naturally *Toxoplasma gondii*-infected cat

Anna S. De Tommasi^a, Maria Morini^b, Maria E. Turba^c, Domenico Otranto^a and Giuliano Bettini^{b*}

^aDepartment of Veterinary Medicine, University of Bari Aldo Moro, Bari, Italy; ^bDepartment of Veterinary Medical Sciences, Alma Mater Studiorum—Università di Bologna, Bologna, Italy; ^cGenefast Lab, Bologna, Italy

(Received 24 July 2014; accepted 15 October 2014)

Keywords: cat; feline; cholangitis; *Toxoplasma gondii*; biliary coccidiosis

The body of a one-year-old female domestic short-haired cat was submitted for post-mortem evaluation with a history of severe hepatic failure characterized by jaundice, vomiting and diarrhoea. The animal was euthanized as requested by the owner due to its poor clinical condition.

At necropsy, external mucosae and subcutaneous tissues were overtly jaundiced. The liver was enlarged and diffusely pale, and showed a grey lobular pattern. On cut section, biliary ducts were dilated up to 3 mm, with thickened wall, and creamy yellow content (Figure 1). The gallbladder was white coloured and markedly distended, and contained yellow-white catarrhal material. The pancreas was hardened and showed scattered 1–2 mm nodules. Other organs examined grossly were unremarkable.

The creamy material within bile ducts was collected and smeared onto glass slides for cytological examinations after May–Grünwald–Giemsa staining. Tissue samples were collected from the liver and main organs, fixed in 10% neutral buffered formalin, embedded in paraffin wax, sectioned at 4 µm and stained with haematoxylin and eosin.

Cytologically, the examined samples were highly cellular and displayed several columnar cells with pale blue cytoplasm and oval nuclei (bile duct epithelial cells). Blue ovoid 3-µm inclusions were evident within the cytoplasm of these cells, either individual or in roundish aggregates, and were morphologically consistent with coccidian parasites belonging to the Eucoccidiorida order (e.g., *Isospora* spp., *Eimeria* spp., *Toxoplasma gondii*) (Figure 2).

Histological examination of the liver showed a severe subacute eosinophilic cholangitis, with marked hyperplasia of the biliary epithelium, moderate to marked periportal fibrosis and biliary duct ectasia. Cellular inclusions consistent with those observed at cytology were present in the luminal portion of bile duct cells (Figure 3). A mild lymphocytic infiltrate (periportal chronic hepatitis) was also evident in the liver parenchyma surrounding portal tracts. Accessory findings were chronic interstitial pancreatitis with marked periductal lymphocytic infiltrate, necrotizing pneumonia and diffuse alveolar oedema. Protozoal inclusions were not evident in tissues other than biliary tree.

Formalin-fixed liver samples were post-fixed in 1% osmium tetroxide, stained with uranyl-acetate and lead

citrate, plastic embedded and sectioned at 60–90 nm for transmission electron microscopy. This confirmed intracellular protozoan parasites within parasitophorous vacuoles in the cytoplasm of biliary cells (Figure 4).

In an attempt to characterize the parasites at the molecular level, a nested-PCR approach targeting the internal transcribed spacer 1 region of *T. gondii* was applied. Genomic DNA was purified from a stained cytological smear by using a commercial kit following manufacturer's instructions (NucleoSpin Tissue, Macherey Nagel, Carlo Erba Reagents, Milan, Italy). The outer primers (Toxoout 1 5' GATTTCGATTCAA-GAAGCGTGATAGTA 3'; Toxoout 25' AGTTTAG-GAAGCAATCTGAAAGCACATC 3') were described in a previous study (Jauregui et al. 2001) while the inner primers (ToxoIn 15' GGTATTATTGCCTTCTTCATG 3'; ToxoIn 2 5' TCAGTATCCCAACAGAGAC 3') were designed by using a specific software (Beacon Designer V3, Biorad, Milan, Italy). An amplicon was evidenced in both PCR rounds. The first-round PCR product was then forward- and reverse-sequenced using a commercial kit (Big Bye Terminator v.1.1, Life Technologies, Milan, Italy) and then electrophoresed on an automated sequencer. The nucleotide sequence displayed a 100% homology with *T. gondii* sequence available in a public database (Genbank, <http://www.ncbi.nlm.nih.gov/genbank/>).

This case report describes the histological and cytological findings of a hyperplastic cholangitis associated to a biliary coccidiosis in a naturally *T. gondii*-infected cat.

Domestic and wild cats represent the definitive hosts of *T. gondii*, a widespread obligate coccidian parasite of zoonotic importance, due to the large range of intermediate hosts, which also include human (Dabritz & Conrad 2010; Torrey & Yolken 2013). Infection of both intermediate and definitive hosts occurs either by oral ingestion of sporulated oocysts from the environment or of meat harbouring tissue cysts, or by transplacental infection (Dubey 2009). The enteroepithelial life cycle occurs only in the intestine of felids, where *T. gondii* undergoes sexual reproduction (also known as gametogony) resulting in millions of environmentally resistant oocysts. The

*Corresponding author. Email: giuliano.bettini@unibo.it

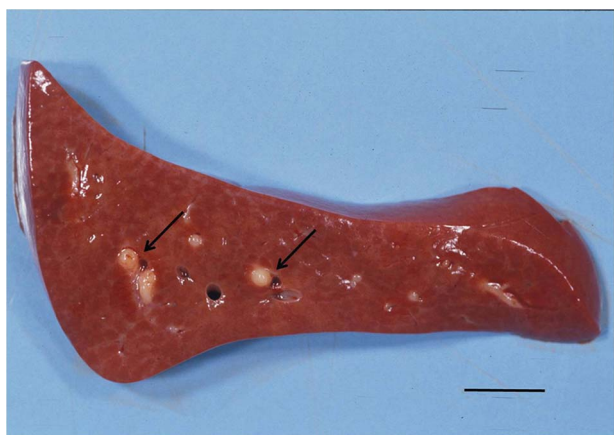


Figure 1. Section of a feline liver with *Toxoplasma gondii* cholangitis. Note the marked dilatation of bile ducts (arrows). Bar = 2 cm.

extraintestinal development of *T. gondii* is the same for all hosts, including cats. Indeed, after the ingestion of oocysts, sporozoites enter intestinal cells and divide into two by an asexual process known as endodyogeny, thereby becoming tachyzoites. Tachyzoites disseminate in blood or lymph during active infection, multiply into different cells of the host and eventually encyst in different tissues, including the liver (Dubey & Carpenter 1993). Toxoplasmosis is most severe in neonatal cats, whilst the infection in adult animals is typically subclinical (Dubey & Lappin 2006). However, interstitial pneumonia, necrotizing hepatitis, splenitis, lymphadenitis, ophthalmitis, myocarditis and encephalitis are the main pathologic features in clinically infected animals (Dubey & Jones 2008). In immunocompetent adult animals, the infection is mainly subclinical, but in cats with immunosuppression induced by drugs as cyclosporine (Bernsteen et al. 1999), hypercortisolism (Spada et al. 2010) or infection with retrovirus (Davidson et al. 1993), the infection could be severe and generalized. A limitation of this case report is that no information was available on history and immune status of the cat that could explain an unusual pathological presentation of *Toxoplasma* infection.

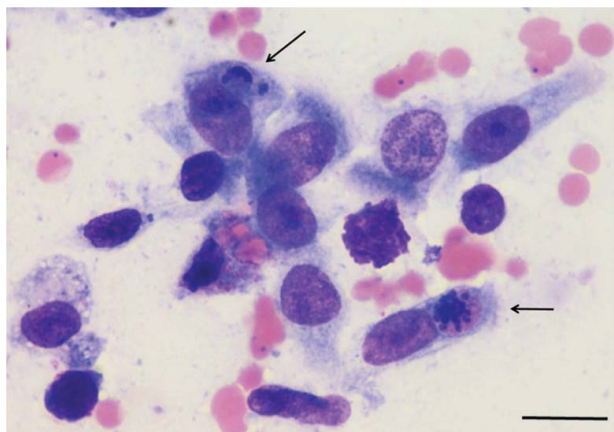


Figure 2. Cytology of bile duct content from a cat with *Toxoplasma gondii* cholangitis. Columnar bile duct cells exhibit dark blue cytoplasmic inclusions at different developmental stages, consistent with a coccidian parasite (arrows). May–Grünwald–Giemsa stain; bar = 20 μ m.

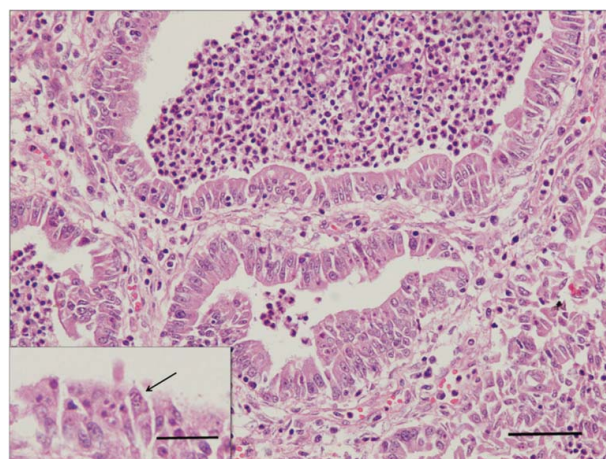


Figure 3. Histological view of *Toxoplasma gondii* cholangitis in a cat. Note the marked hyperplasia of the biliary epithelium and dilatation of bile ducts with a predominant eosinophilic exudate; moderate periportal fibrosis; bar = 100 μ m. Inset: bile duct cells frequently contained *T. gondii* inclusions (arrows). H&E stain; bar = 30 μ m.

According to the World Small Animal Veterinarian Association (WSAVA), cholangitis is one of the most important hepatobiliary diseases in cats. Four main forms of cholangitis are defined in cats: neutrophilic, lymphocytic, destructive and chronic cholangitis associated with liver fluke infestation (van den Ingh et al. 2006). In general, cholangitis is not considered a common cause of death in cats; mortality increased especially when concurrent diseases occur (Callahan Clark et al. 2011). Biliary coccidiosis represents an uncommon event in veterinary pathology, apart from hepatic coccidiosis of rabbits caused by *Eimeria stiedae*, a common and well-characterized disease (Hobbs & Twigg 1998). Other species in which biliary coccidiosis has been reported include ferret (Williams 1996), dog (Lipscomb et al. 1989), goat (Oruc 2007) and mink (Davis et al. 1953). Smart et al. (1973) reported the history of a one-year old male Siamese cat with generalized toxoplasmosis and chronic pancreatitis, cholangitis, splenitis, pneumonia and focal hepatic necrosis, where protozoa were histologically evident in bile

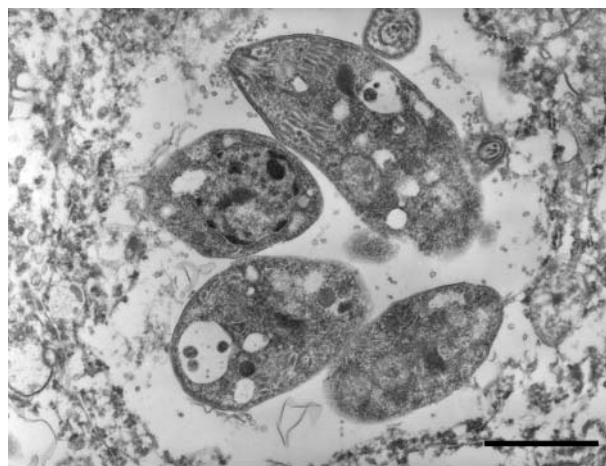


Figure 4. Transmission electron micrograph of feline liver. Intracytoplasmic unicellular parasites within parasitophorous vacuoles. Bar = 2 μ m.

duct epithelial cells, but also in liver parenchyma, pancreas, spleen and kidneys. Neufeld and Brandt (1974) described a case of feline cholangiohepatitis due to an unidentified protozoan parasite resembling either *Isospora* spp. or *T. gondii*, although a definite diagnosis was not achieved. Dubey et al. (1990) characterized the histological features of a *Toxoplasma*-induced hepatitis; multifocal areas of necrosis of hepatocytes, haemorrhage and inflammatory infiltration represented the main findings and *T. gondii* inclusions were observed both outside and within the hepatocytes, as well as in the pancreas, splenic reticuloendothelial and intestinal epithelial cells. The coccidian-like inclusions herein described were observed in this case at cytological examination of the liver smears; the organisms appeared sometimes as individual ovoid structures, deep blue coloured, consistent with meronts, other as roundish aggregates morphological similar to tachyzoites usually observed in the lungs of *T. gondii*-infected cats (Gardiner et al. 1998). The cytoplasmic inclusions within biliary cells were also evident histologically, and were ultrastructurally identical to those previously described for *T. gondii* (Ferguson & Hutchison 1987). As these structures were difficult to distinguish morphologically from the other coccidian parasites, definitive diagnosis of toxoplasmosis was achieved through molecular assays.

Liver involvement has been largely documented in naturally *T. gondii*-infected cats and it is predominantly characterized by hepatic inflammatory infiltration and necrosis which may extend from focal to confluent areas of necrosis; in severe cases, panlobular involvement could be observed (van den Ingh et al. 2006). Interestingly, necrosis was not observed in the liver of the cat herein examined, whilst inflammatory infiltrate localization was considered peculiar, being mostly gathered near biliary ducts; thus, inflammatory involvement of the liver may be secondary to *T. gondii*-induced cholangitis. Conversely, pulmonary lesions herein observed did not differ from those reported in literature (i.e., multifocal necrotizing pneumonia with infiltrates of macrophages and neutrophils), although *T. gondii* organisms were not evident in lung lesions.

Conclusion

To the authors' knowledge, *T. gondii* inclusions within biliary epithelial cells have been suspected but never confirmed in cats, being difficult to structurally distinguish them from other coccidian parasites. In this case report, biomolecular assay confirmed *T. gondii* infection enabling to conclude that biliary coccidiosis caused by *T. gondii* may occasionally occur in cats with histological features of cholangiohepatitis which differ from those previously reported.

References

Bernsteen L, Gregory CR, Aronson LR, Lirtzman RA, Brummer DG. 1999. Acute toxoplasmosis following renal

- transplantation in three cats and a dog. *J Am Vet Med Assoc.* 15:1123–1126.
- Callahan Clark JE, Haddad JL, Brown DC, Morgan MJ, Van Winkle TJ, Rondeau MP. 2011. Feline cholangitis: a necropsy study of 44 cats (1986–2008). *J Feline Med Surg.* 13:570–576.
- Dabritz HA, Conrad PA. 2010. Cats and *Toxoplasma*: implications for public health. *Zoonoses Public Health.* 57:34–52.
- Davidson MG, Rottman JB, English RV, Lappin MR, Tompkins MB. 1993. Feline immunodeficiency virus predisposes cats to acute generalized toxoplasmosis. *Am J Pathol.* 143:1486–1497.
- Davis CL, Chow TL, Gorham JR. 1953. Hepatic coccidiosis in mink. *Vet Med.* 48:371–375.
- Dubey JP. 2009. History of the discovery of the life cycle of *Toxoplasma gondii*. *Int J Parasitol.* 39:877–882.
- Dubey JP, Carpenter JL. 1993. Histologically confirmed clinical toxoplasmosis in cats: 100 cases (1952–1990). *J Am Vet Med Assoc.* 203:1556–1566.
- Dubey JP, Jones JL. 2008. *Toxoplasma gondii* infection in humans and animals in the United States. *Int J Parasitol.* 38:1257–1278.
- Dubey JP, Lappin MR. 2006. Toxoplasmosis and neosporosis. In: Greene CE, editor. *Infectious disease of the dog and cat.* Philadelphia (PA): WB Saunders Co; p. 754–775.
- Dubey JP, Zajac A, Osofsky SA, Tobias L. 1990. Acute primary toxoplasmic hepatitis in an adult cat shedding *Toxoplasma gondii* oocysts. *J Am Vet Med Assoc.* 197:1616–1618.
- Ferguson WM, Hutchison WM. 1987. An ultrastructural study of the early development and tissue cyst formation of *Toxoplasma gondii* in the brains of mice. *Parasitol Res.* 73:483–491.
- Gardiner CH, Fayer R, Dubey JP. 1998. An atlas of protozoan parasites in animal tissues. 2nd ed. Washington (DC): Armed Forces Institute of Pathology.
- Hobbs RP, Twigg LE. 1998. Coccidia (*Eimeria* spp.) of wild rabbits in Southwestern Australia. *Aust Vet J.* 76:209–210.
- Jauregui LH, Higgins J, Zarlenga D, Dubey JP, Lunney JK. 2001. Development of a real-time PCR assay for detection of *Toxoplasma gondii* in pig and mouse tissues. *J Clin Microbiol.* 39:2065–2071.
- Lipscomb TP, Dubey JP, Pletcher JM, Altman NH. 1989. Intrahepatic biliary coccidiosis in a dog. *Vet Pathol.* 26:343–345.
- Neufeld JL, Brandt RW. 1974. Cholangiohepatitis in a cat associated with a coccidia-like organism. *Can Vet J.* 15:156–159.
- Oruc E. 2007. Histopathological findings in naturally occurring biliary coccidiosis in a goat kid. *Vet Rec.* 160:193.
- Smart ME, Downey RS, Stockdale PHG. 1973. Toxoplasmosis in a cat associated with cholangitis and progressive pancreatitis. *Can Vet J.* 14:313–316.
- Spada E, Proverbio D, Giudice C, DiGiancamillo M, Lodi M, Perego R. 2010. Pituitary-dependent hyperadrenocorticism and generalised toxoplasmosis in a cat with neurological signs. *J Feline Med Surg.* 12:654–658.
- Torrey EF, Yolken RH. 2013. *Toxoplasma* oocysts as a public health problem. *Trends Parasitol.* 29:380–384.
- van den Ingh TSGAM, Cullen JM, Twedt DC, Van Winkle T, Charles JA, Desmet VJ. 2006. Morphological classification of biliary disorders of the canine and feline liver. In: Rothuizen J, Bunch SE, Charles JA, Cullen JM, Desmet VJ, Szatmári V, Twedt DC, van den Ingh, TSGAM, Van Winkle T, Washabau RJ, editors. *WSAVA standards clinical and histological diagnosis of canine and feline liver disease.* Edinburgh: Saunders Elsevier; p. 61–76.
- Williams BH, Chimes MJ, Gardiner CH. 1996. Biliary coccidiosis in a ferret (*Mustela putorius furo*). *Vet Pathol.* 33:437–439.