

# Reflectance confocal microscopy as noninvasive tool for monitoring tirbanibulin efficacy in actinic keratosis

Federico Venturi<sup>a,b,\*</sup>, Giulia Veronesi<sup>a,b</sup>, Carlotta Baraldi<sup>a</sup>, Emi Dika<sup>a,b</sup>

<sup>a</sup> Oncologic Dermatology Unit, IRCCS Azienda Ospedaliero-Universitaria di Bologna, Bologna Italy

<sup>b</sup> Department of Medical and Surgical Sciences (DIMEC), Alma Mater Studiorum University of Bologna, Bologna, Italy

## ARTICLE INFO

### Keywords:

Actinic keratosis  
Tirbanibulin  
Reflectance confocal microscopy  
Skin cancer

## ABSTRACT

Actinic keratosis (AK) is a common precancerous condition found on sun-damaged skin. Tirbanibulin 1 % ointment has been approved for the topical treatment of non-hyperkeratotic facial and scalp Olsen grade I AKs over a contiguous area of 25 cm<sup>2</sup> with a daily application for 5 consecutive days. Our aim was to investigate the use of *in vivo* RCM in the assessment of AKs treated with tirbanibulin, as it has never been described in the published Literature. A total of 10 AKs in 10 consecutive outpatients were enrolled in the present study in May 2023. The follow-up visit was scheduled after 30 days from last application of tirbanibulin ointment. At follow-up visit, a complete response was described by clinical, dermoscopic and *in vivo* RCM examination in 10 out of 10 lesions, with a recovery of stratum corneum, decrease in atypical honeycomb pattern and changes in dermal collagen. All patients were followed up for at least 8 months and further recurrences were not registered. Based on our experience, we confirm the efficacy and safety of tirbanibulin in treating AKs and the usefulness of RCM *in vivo* examination for the therapeutic monitoring of such lesions, even in a very early stage.

## 1. Introduction

Actinic keratosis (AK) is a common precancerous condition found on sun-damaged skin [1]. The primary cause of AK is the cumulative damage caused by UV radiation over time. While AK itself is not cancerous, it is crucial to address it promptly because a small percentage of lesions can progress to squamous cell carcinoma [2]. Regular skin examinations, sun protection measures, and appropriate treatment are essential components of managing AK. Among the different treatments we have at our disposal, recently, tirbanibulin 1 % ointment has been approved by FDA, EMA and AIFA for the topical treatment of non-hyperkeratotic facial and scalp Olsen grade I AKs over a contiguous area of 25 cm<sup>2</sup> with a daily application for 5 consecutive days [3]. It is a novel synthetic drug with potent antitumor and antiproliferative activity, able to induce cell cycle arrest and apoptosis through inhibition of tubulin polymerization. Assessment of treatment efficacy can be made by clinical observation, dermoscopy and, in doubtful cases, by histopathological analysis through skin biopsy [4,5]. Moreover, reflectance confocal microscopy (RCM) is a non-invasive imaging technique that has gained prominence for the evaluation and diagnosis of skin tumors [6,7]. It allows high-resolution imaging of the skin at a cellular level

without the need for biopsy. RCM utilizes laser light to create detailed images of skin structures and can be particularly useful in differentiating between benign and malignant lesions. Herein we present our real-life experience in 10 patients affected by non-pigmented, non-hyperkeratotic, non-hypertrophic Olsen grade I AKs located of the scalp and face treated with Tirbanibulin 1 % ointment for 5 consecutive days. The aim of this study was to investigate the use of *in vivo* RCM in the assessment of the response of AKs treated with tirbanibulin ointment, as it has never been described in the published Literature. We obtained excellent outcomes with complete response of the target lesions and a great safety profile.

## 2. Methods

A total of 10 biopsy-proven non-pigmented, non-hyperkeratotic, non-hypertrophic Olsen grade I AKs in 10 consecutive outpatients were enrolled in the present study in May 2023. The study was approved by the local ethics committee and all subjects gave written informed consent prior to entry. RCM investigation was performed with a Viva-scope 1500® (MAVIG GmbH, Munich, Lucid-Tech Inc., Henrietta, NY, USA) microscopy. Each skin lesions were systematically evaluated by

\* Corresponding author at: Via Massarenti 1, Bologna 40138, Italy.

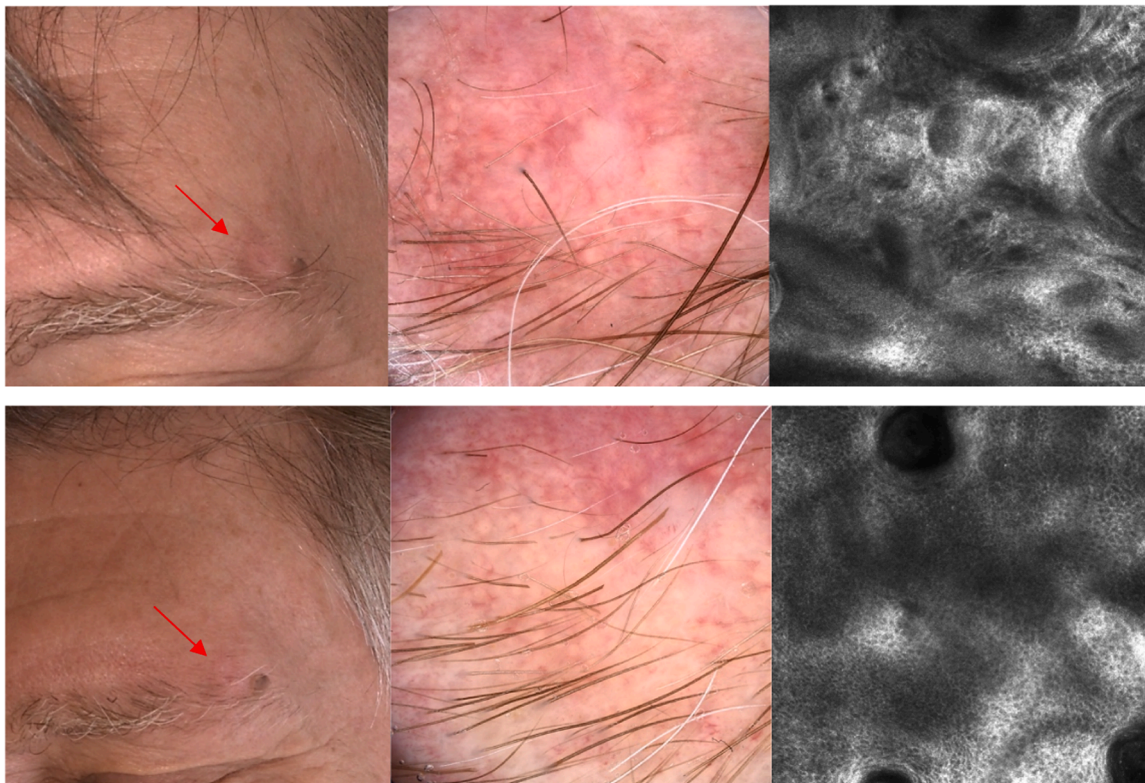
E-mail address: [federico.venturi@hotmail.it](mailto:federico.venturi@hotmail.it) (F. Venturi).

<https://doi.org/10.1016/j.pdpdt.2024.104235>

Received 26 April 2024; Received in revised form 23 May 2024; Accepted 5 June 2024

Available online 6 June 2024

1572-1000/© 2024 The Authors. Published by Elsevier B.V. This is an open access article under the CC BY license (<http://creativecommons.org/licenses/by/4.0/>).



**Fig. 1.** (A–F): Clinical, dermoscopic and *in vivo* reflectance confocal microscopy features of non-pigmented, non-hyperkeratotic Olsen grade I AK before and 1 month after last application of Tirbanibulin 1 % ointment for 5 consecutive days.

Clinical (A) and dermoscopic presentation of non-pigmented AK (red arrow) with 'strawberry' appearance, with white-to-yellow follicular keratotic plugs surrounded by a whitish halo, and background erythema/red pseudonetwork (B). *In vivo* RCM displays architectural disarray with pleomorphism of keratinocytes and thickened, moderately refractile fibres representative of solar elastosis.

Clinical (D) and dermoscopic presentation of non-pigmented AK 30 days after tirbanibulin treatment (red arrow) (E). *In vivo* RCM displays restoration of normal honeycomb pattern with no atypical features (F).

RCM: one X–Y horizontal mapping ( $4 \times 4$ -mm mosaic) was performed at each epidermal layer beginning with the stratum corneum through the entire epidermis and until the papillary dermis (maximal depth of imaging: 200–250  $\mu\text{m}$ ). We analyzed for each lesion the presence/absence of the most frequently described diagnostic RCM features for AKs before and 30 days after treatment with Tirbanibulin 1 % ointment: scale, hyperkeratosis, parakeratosis, atypical keratinocytes, normal or atypical honeycomb pattern in stratum granulosum, architectural disarray in stratum granulosum, atypical honeycomb pattern or architectural disarray in stratum spinosum, poorly defined and irregular keratinocyte cell boundaries, exocytosis, dilated blood vessels and dermal solar elastosis [8,9]. Imaging with *in vivo* RCM was performed before treatment starting to confirm the diagnosis of AK and after 1 month to evaluate the response to treatment.

### 3. Results

10 caucasian patients (1 female and 9 males, age ranging between 62 and 91 years) with 10 biopsy-proven non-pigmented AKs were enrolled. Patients presented AKs located on the face (6) or scalp (4). The lesions were located within a 25 cm [2] area of the face and scalp and were treated with 1 % tirbanibulin ointment for 5 consecutive days. All lesions showed clinical and dermoscopic features of non-pigmented non-hyperkeratotic AKs and presented upon RCM the above-mentioned criteria for *in vivo* confocal diagnosis of AKs (Fig. 1A–C). All patients reported having completed all five daily doses of the treatment, and none of them dropped out of the study. The follow-up visit was scheduled after 30 days from last application of tirbanibulin ointment. At follow-up visit, a complete response (total

disappearance of AK features) was described by clinical, dermoscopic and *in vivo* RCM examination in 10 out of 10 lesions, (Fig. 1D–F) with a recovery of stratum corneum, decrease in atypical honeycomb pattern and changes in dermal collagen. All patients were followed up for at least 8 months and further recurrences were not registered.

### 4. Discussion

RCM represent a useful tool for noninvasive diagnostic assessment of AK, especially in older patients that are not prone to surgery, with a high sensitivity and specificity [6,9,10]. Previous works evaluated RCM *in vivo* application in AKs treatment monitoring, both for topical and physical therapies [10]. Our study represents the first to consider this novel noninvasive tool for monitoring tirbanibulin 1 % ointment efficacy. As a matter of fact, tirbanibulin is a synthetic drug with potent antitumor and antiproliferative activity and a few related adverse events. Unlike other treatments for AKs, tirbanibulin does not induce tissue necrosis with a low rate of severe local skin reactions, which favors good tolerability and a high safety profile of the drug. Based on our experience, we confirm the efficacy and safety of tirbanibulin in treating AKs and the usefulness of RCM *in vivo* examination for the therapeutic monitoring of such lesions, even in a very early stage.

### 5. Conclusion

To conclude, our study supports the previous Literature confirming the role of *in vivo* RCM not only for the diagnosis of AK but also as a noninvasive tool for treatment monitoring. This approach may allow us to avoid unnecessary invasive procedure, especially in older patients, by

maintaining the same diagnostic accuracy. Moreover, we confirmed the efficacy of tirbanibulin 1 % ointment in treating non-hyperkeratotic Olsen grade I AKs of the face and the scalp, with a good safety profile and excellent outcomes. Thus, given its great compliance, it will decrease the risk of eventually progression of AKs into invasive carcinomas, that require advanced surgery or systemic treatments[11]. Finally, further studies are needed to confirm our preliminary data on larger cohorts

### Ethics approval statement

The study protocol was approved by the local ethics committee (SkinCancer2019).

### Patient consent

Patients were informed about the use of their clinical informations according to the Declaration of Helsinki principles and photos for a publication intent. The informed consent was appropriately obtained during the medical examination.

### Funding information

The authors declare that no funds, grants, or other support were received during the preparation of this manuscript.

### CRediT authorship contribution statement

**Federico Venturi:** Writing – review & editing, Writing – original draft, Visualization, Supervision, Investigation, Formal analysis, Data curation, Conceptualization. **Giulia Veronesi:** Writing – review & editing. **Carlotta Baraldi:** Writing – review & editing. **Emi Dika:** Writing – review & editing, Writing – original draft, Data curation, Conceptualization.

### Declaration of competing interest

The authors have no relevant financial or non-financial interests to

disclose.

### References

- [1] M.V. Heppt, U. Leiter, T. Steeb, et al., S3 guideline for actinic keratosis and cutaneous squamous cell carcinoma - short version, part 1: diagnosis, interventions for actinic keratoses, care structures and quality-of-care indicators, *J. Dtsch. Dermatol. Ges.* 18 (3) (2020) 275–294, <https://doi.org/10.1111/ddg.14048>.
- [2] U. Leiter, M.V. Heppt, T. Steeb, et al., S3 guideline "actinic keratosis and cutaneous squamous cell carcinoma" - update 2023, part 2: epidemiology and etiology, diagnostics, surgical and systemic treatment of cutaneous squamous cell carcinoma (cSCC), surveillance and prevention, *J. Dtsch. Dermatol. Ges.* 21 (11) (2023) 1422–1433, <https://doi.org/10.1111/ddg.15256>.
- [3] A. Blauvelt, S. Kempers, E. Lain, et al., Phase 3 trials of tirbanibulin ointment for actinic keratosis, *N. Engl. J. Med.* 384 (6) (2021) 512–520, <https://doi.org/10.1056/NEJMoa2024040>.
- [4] E. Campione, A. Rivieccio, R. Gaeta Shumak, et al., Preliminary evidence of efficacy, safety, and treatment satisfaction with tirbanibulin 1% ointment: a clinical perspective on actinic keratoses, *Pharmaceuticals* 16 (12) (2023) 1686, <https://doi.org/10.3390/ph16121686> (Basel).
- [5] F. Lacarubba, A.E. Verzi, M. Polita, A. Aleo, G. Micali, Line-field confocal optical coherence tomography in the treatment monitoring of actinic keratosis with tirbanibulin: a pilot study, *J. Eur. Acad. Dermatol. Venereol.* 37 (9) (2023) e1131–e1133, <https://doi.org/10.1111/jdv.19147>.
- [6] G. Pellacani, A. Scope, S. Gonzalez, et al., Reflectance confocal microscopy made easy: the 4 must-know key features for the diagnosis of melanoma and nonmelanoma skin cancers, *J. Am. Acad. Dermatol.* 81 (2) (2019) 520–526, <https://doi.org/10.1016/j.jaad.2019.03.085>.
- [7] F. Venturi, G. Pellacani, F. Farnetani, H. Maibach, D. Tassone, E. Dika, Noninvasive diagnostic techniques in the preoperative setting of Mohs micrographic surgery: a review of the literature, *Dermatol. Ther.* 35 (11) (2022) e15832, <https://doi.org/10.1111/dth.15832>.
- [8] K.P. Nguyen, M. Peppelman, L. Hoogedoorn, P.E.J. Van Erp, M.J.P. Gerritsen, The current role of *in vivo* reflectance confocal microscopy within the continuum of actinic keratosis and squamous cell carcinoma: a systematic review, *Eur. J. Dermatol.* 26 (6) (2016) 549–565, <https://doi.org/10.1684/ejd.2016.2872>.
- [9] A. Aleisa, M. Cordova, C. Payulert, et al., Combined reflectance confocal microscopy and optical coherence tomography in the evaluation of cutaneous squamous cell carcinoma, *J. Am. Acad. Dermatol.* (2024), <https://doi.org/10.1016/j.jaad.2024.01.072>. Published online February 10.
- [10] M. Venturini, A. Zanca, P. Calzavara-Pinton, *In vivo* non-invasive evaluation of actinic keratoses response to methyl-aminolevulinate-photodynamic therapy (MAL-PDT) by reflectance confocal microscopy, *Cosmetics* 1 (1) (2014) 37–43, <https://doi.org/10.3390/cosmetics1010037>.
- [11] V. De Giorgi, L. Trane, I. Savarese, et al., Lasting response after discontinuation of cemiplimab in a patient with locally advanced basal cell carcinoma, *Clin. Exp. Dermatol.* 46 (8) (2021) 1612–1614, <https://doi.org/10.1111/ced.14804>.