

Review: Myopathies in broilers: supply chain approach to provide solutions to challenges related to raising fast growing birds

Shai Barbut ^{*},¹ Randolph Mitchell,[†] Parker Hall,[†] Craig Bacon [‡], Ritchard Bailey,[§] Casey M. Owens,[#] and Massimiliano Petracci ^{||}

^{*}Department of Food Science, University of Guelph, Guelph, Ontario N1G 2W1, Canada; [†]Perdue Foods LLC, Salisbury, MD 21804, USA; [‡]Simmons Prepared Foods, Siloam Springs, AR 72761, USA; [§]Aviagen Ltd., Newbridge, Edinburgh, EH28 8SZ, Scotland; [#]Department of Poultry Science, University of Arkansas, Fayetteville, AR 72701, USA; and ^{||}Department of Agricultural and Food Sciences, University of Bologna, Bologna, Italy

ABSTRACT This review is a summary of a Poultry Science Association symposium addressing myopathies in broilers' breast meat, focusing on the interactions between genetics, nutrition, husbandry, and meat processing. The *Pectoralis major* myopathies (woody breast [WB]; white striping [WS]; spaghetti meat [SM]) and *Pectoralis minor* ("feathering") are described, followed by discussing their prevalence, potential causes, current and future ways to mitigate, as well as detection methods (in live birds and meat) as well as ways to utilize affected meat. Overall, breast myopathies remain an important focus across the poultry industry and whilst a lot of data and knowledge has

been gathered, it is clear that there is still a lot to understand. As there are multiple factors impacting the occurrence of breast myopathies, their reduction relies on a holistic approach. Ongoing balanced breeding strategies by poultry breeders is targeting the longer-term genetic component but comprehending the significant influence from nongenetic factors (short-term solutions such as nutrition) remains a key area of opportunity. Consequently, understanding the physiology and biological needs of the muscle through the life of the bird is critical to reduce the myopathies (e.g., minimizing oxidative stress) and gain more insight into their etiology.

Key words: broiler breast meat, genetic, myopathy, nutrition, woody breast

2024 Poultry Science 103:103801
<https://doi.org/10.1016/j.psj.2024.103801>

INTRODUCTION

In the 1920s, chicken meat was merely a by-product of the commercial egg industry. One of the significant developments occurred in the 1940s when the "Chicken of Tomorrow" contest was introduced, and the origin of commercial meat-type broilers started to change (e.g., became more efficient) (Siegel, 2023). For example, in 1960 it took 84 d to raise a 1.7 kg broiler with a feed conversion ratio of 3.6 (average growth rate of 20 g/d), with an overall meat yield of 65% and breast meat yield of 12%. In 2020, a fast-growing broiler could get to 2.7 kg in 38 d with a feed conversion ratio of 1.45 (average growth rate of 72 g/d) where carcass yield is 73% and breast meat yield is 25% (Havenstein et al., 2003;

Anonymous, 2022). It is also noteworthy to mention that today 70% of the broiler poultry meat in the USA comes from large birds weighing 2.8 kg or more. Presenting the concept of the Chicken of Tomorrow was a big event in 1948 (\$500 prize offered) where the vision of developing a plump heavy meat-type broiler was introduced. At the event, a wax model was presented (video is available at: <https://www.youtube.com/watch?v=Yjq9aIo5G3E>). Today, we have surpassed the goals presented in 1948. Meanwhile, we have also dealt with various other challenges such as animal welfare, sustainability, food safety, meat quality (focus of this review), profitability, and affordability.

Poultry meat production and consumption have also increased at a phenomenal rate over the last 60 years. In 1960, world poultry meat production was 10B tons and today it is 120B tons (FAO, 2022) and forecasted to be 180B in 2050. Another important fact is that the proportion of the whole bird market has significantly changed over those years. For example, in North America, sale of whole broiler carcasses was 77% in 1960 and today it is about 8%. At the same time, the proportion of cut-up

Crown Copyright © 2024 Published by Elsevier Inc. on behalf of Poultry Science Association Inc. This is an open access article under the CC BY-NC-ND license (<http://creativecommons.org/licenses/by-nc-nd/4.0/>).

Received February 15, 2024.

Accepted April 22, 2024.

¹Corresponding author: sbarbut@uoguelph.ca

chicken was 15% and today it is about 40% while further processed products went from 5% to 45%, respectively (USDA, 2014). Overall, the Agricultural Outlook (OECD-FAO, 2022) indicated that poultry meat remains the primary driver of growth in global meat production, and the long-term shift in meat consumption towards poultry continues to strengthen.

As indicated above, boneless meat sales have significantly increased and have become the most popular choice for consumers in the Western world, especially as incomes rise and markets expand. In many cases, those boneless meat cuts are further processed by the food industry and sold as ready-to-eat products (e.g., chicken nuggets, turkey ham, pastrami). It is important to realize as market demand for whole birds decreased (demand for portions increased) the meat industry moved to having large birds (Zuidhof et al., 2014) that can be cut up and processed at a centralized plant as the processing costs do not depend as much on size (Barbut, 2015). Another big change in marketing can be seen in the sale of turkey meat which used to be very seasonal when consumers purchased a whole turkey for certain holidays while today turkey meat is available in small portions (e.g., a single drumstick).

Overall, the increase in broiler size and meat yield has improved the efficiency of raising poultry but also introduced some challenges. The focus in this review is the myopathy issue which can be divided into:

(1) **Woody breast (WB)**: characterized by a region of tough muscle fibers within the breast fillet (Figure 1). This can be accompanied by out bulging and pale areas of hardened consistency either in the cranial

and/or the caudal areas of the muscle, which sometimes can be associated with the presence of hemorrhages and exudate of viscous material. Mueller (2021) have shown that as bird weight increases, so does the amount of WB incidences (Figure 2). It should be noted that the severity of the myopathy can vary and currently a scale of WB-0 (no myopathy), WB-1 (mild), WB-2 (moderate), and WB-3 (severe) is commonly used.

- (2) **White striping (WS)**: characterized by white striations (up to a few mm, parallel to the muscle fiber direction) on the surface of the broiler breast fillet.
- (3) **Spaghetti meat (SM)**: characterized by splitting of the muscle fiber bundles that tend to detach one from the other; mainly in the anterior part of the fillet. In some cases, excessive separation can be seen after primary processing. It is believed that this does not occur in the live bird.
- (4) **Feathering**: separation of muscle bundles and tears in the *Pectoralis minor*.
- (5) **Deep muscle myopathy**: can be seen as necrosis of inner *Pectoralis minor* muscle fibers. This usually appears as a greenish section in the deep breast fillet.
- (6) **Pale soft exudative (PSE)** meat: breast meat muscle that goes through a fast pH decline during the rigor mortis process.

Items 5 and 6 are not going to be discussed in great detail in this review as their prevalence is not so high


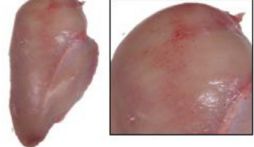

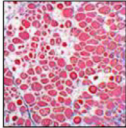
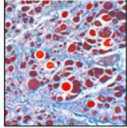
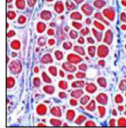
	White Striping	Wooden Breast	Spaghetti Meat
Phenotype			
Description	White striations of variable thickness running parallel to the myofiber direction	Out-bulging and pale areas having hardened consistency often exhibiting petechial hemorrhages	Loss of integrity and separation of the fiber bundles composing the tissue
Microscopic appearance			
Pathognomonic microscopic features	Increased deposition of lipid at perimysial level (lipidosis)	Proliferation of connective tissue at perimysial level up to fibrosis	Progressive rarefaction of the connective tissue composing the perimysial septa
Common histological traits	Profound modifications in the muscle architecture including the presence of fibers having rounded profile, nuclear rowing and internalization, hypercontracted fibers, degeneration up to lysis along with occasional regeneration, inflammatory cells infiltration, compromised perimysial septa		

Figure 1. Illustration of chicken breast fillet showing white striation (WS), woody breast (WB) myopathy, and spaghetti meat (SM) including microscopical images of the affected muscles. Note that the WS is characterized by abnormal deposition of adipose at the perimysial level (lipidosis), as well as some connective tissue fibers. Woody breast is characterized by proliferation and thickening of the perimysial network (fibrosis). Spaghetti meat is characterized by rarefaction of the endomysial and perimysial connective tissues. From Soglia et al. (2021) with permission.

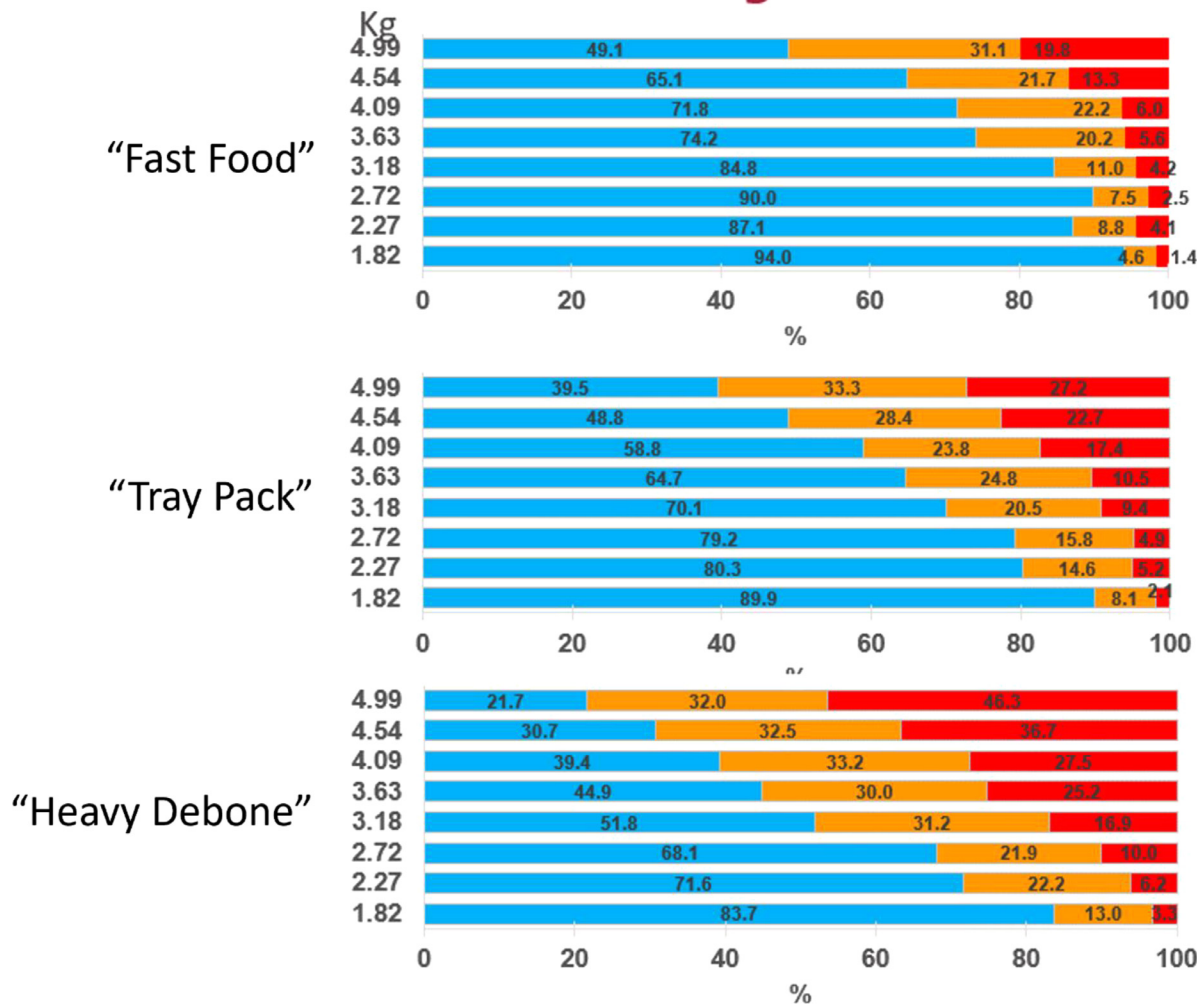


Figure 2. Incidences of woody breast by weight and bird type. Blue bars represent normal meat, orange represent mild woody breast, and red represent severe woody breast (n = 10,745 birds). Modified from de Almeida Mallmann (2019).

today in most parts of the world, and these issues have already been reduced/eliminated in the population via management and genetic strategies.

It is important to note that the myopathies described above can sometimes appear by themselves or in combination with other myopathies but no pattern of cooccurrence has emerged. Figure 3 illustrates the cooccurrence of myopathies in a group of 9,250 broilers sampled from 40 flocks collected over 2 y. Birds were 6 wk old and weighed 2.4 kg on average. The figure shows that a third of the birds had 3 cooccurring myopathies while about half had both WB and WS (in different severities). In the paper, the authors also show other effects such as season (spring the highest WB), and administration of coccidiosis vaccine (Che et al., 2022). Aguirre et al. (2020) also reported on the occurrence of WB and WS and showed, in a sample size of 4,300 fillets, that samples without WB had 44% WS1; samples with WB1 had 55% WS1 and 10% WB2; samples with WB2 had 36% WS1 and 34% WS2, while samples with WB3 had 20% WS1 and 40% WS2.

The economic impact of the above-mentioned myopathies was estimated to be 200 million USD in North America (Owens, 2014), and later, when prevalence increased, at over 1 billion dollars (Barbut, 2020).

Studies from around the world show that myopathies such as WB and WS are found on every continent, and depending on the study can range from 5-50% (also depending on average body weight, nutrition, breed, etc.). Overall, these myopathies do not pose a public health concern, as there are no pathogens involved. However, they represent meat quality issues (e.g., lower protein content, muscle fragmentation) that influence consumer acceptance (e.g., tough meat).

Over the past decade, research has focused on understanding the etiology and physiology of the 3 main myopathies (WB, WS, SM) in an attempt to reduce their incidence (Lake and Abasht, 2020; Velleman, 2023). Research employing metabolomics, proteomics, and gene expression has shown that they share a root in hypoxia and oxidative stress (Che et al., 2024). However, the exact etiology and circumstances by which they emerge are still not fully understood and remain an active area of research. One hypothesis for the development of myopathies is that they are an unwanted side-effect of selection for breast meat yield and body weight. However, published data from large populations of broiler pure lines shows that the heritability for the 3 myopathies is low to moderate ranging from 0.01 to 0.15 for SM, 0.024 to 0.097 for WB and 0.185 to 0.338 for WS

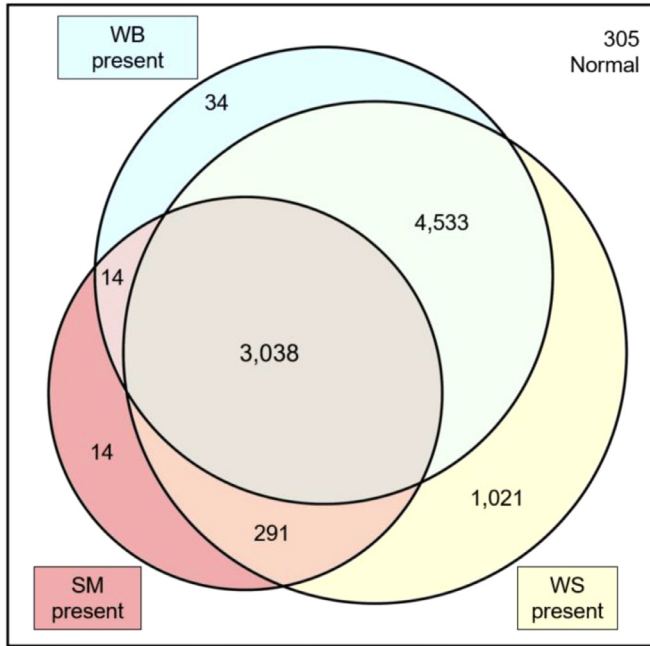


Figure 3. Venn diagram illustrating the incidence counts of spaghetti meat (SM), woody breast (WB), and white striping (WS) in 9,250 fillets. A total of 7,876 fillets presented multiple myopathies together. Within the 7,876 fillets, 3,038 fillets presented SM and WB and WS together. Out of 9,250 scored fillets, only 305 fillets did not show myopathies. [Che et al. \(2022\)](#) with permission.

([Bailey et al., 2015, 2020](#)). This indicates that while there is a genetic component, it is the influence from the nongenetic, management, and environmental effects that are influential ([Bailey et al., 2015; Bordignon et al., 2022](#)). The genetic component means that there is scope to select against the myopathies however, as the heritabilities are not high this must be seen as a long-term strategy. Published data comparing a higher generation broilers (produced by using pure line pedigree birds in the grandparent position) with the current commercial broiler show a potential relative reduction of 9.2% in WB annually in response to selection ([Bailey et al., 2020](#)). Therefore, in the shorter term, there should be more focus on understanding the nongenetic factors as they can likely be altered more instantly and have a greater and more immediate influence on the incidence of the myopathies. Furthermore, genetic correlations between the myopathies and broiler performance traits such as breast yield and body weight are also low to moderate, showing that there is limited shared genetic background between the myopathies and the performance traits. This is important as it indicates that selection for improved breast yield and broiler performance, while reducing incidence of myopathies, is possible through balanced breeding as shown in [Figure 4](#). The figure shows an XY plot of breeding values (BVs) for WB and % BY of line A (high-yielding line). It reveals that WB can occur in birds with both high and low BY ([Bailey et al., 2015](#)), indicating that breast yield is not necessarily the primary driver of WB manifestation. It can be seen that there is a proportion of birds with a high genetic potential for BY and below-average WB in

the bottom right quadrant of the plot. This proportion of birds represents those which can be selected for both traits in the desired direction.

WB has received the most attention of any myopathy over the last decade due to its prevalence and resulting loss of quality of the finished product. WB was first described in the scientific literature by [Sihvo et al. \(2014\)](#), but industry realized the presence of the condition and its significant effect on quality as early as 2010. The condition does not seem to have materialized overnight based on industry feedback of a similar issue in the early 2000s and some geneticists in the industry reported a hard breast muscle condition in pure lines several years prior to naming it WB. The early detection of this condition was mainly from consumer complaints around toughness, leading to the detection in the plant and then on live birds. The initial thought about the condition was that it was related to health, however the first veterinary report (with histology) of the myopathy described it as a nutritional myopathy. This set the industry on a path of dozens of field trials examining various vitamins, antioxidants, organic mineral replacements, and nutritional profile changes; none of which resulted in any consistent results to eliminate the problem. At that time, industry personnel noted that one of biggest hindrance to assessing the effect of any of these changes was the inconsistency of measurement. So, it took some time to develop reliable and consistent measures. Overall, the items discovered that mattered in terms of WB occurrence were:

1. Size matters: the bigger birds in a flock were the most affected. Larger birds (e.g., birds raised for jumbo deboning) are more affected than small, that is, used in the fast-food trade. ([de Almeida Mallmann, 2019](#). See also [Figure 2](#)).
2. Sex matters: males > females; however, at the time, the question was if this was independent of weight ([Mueller et al., 2023](#). See also discussion below).
3. Growth rate matters: farms with “new house syndrome” or very good growth rates show higher incidences ([Soglia et al., 2021](#)).
4. Feeding program matters: flocks fed high density diets show more than flocks fed low density diets ([Meloche et al., 2018a; Bordignon et al., 2022](#)).
5. Genetic strain matters: high yield strains show more than low yield strains ([Bailey et al., 2015, 2020](#)).
6. Yield matters: almost always birds with higher breast meat yield due to strain, nutrition, or live weight show higher WB incidence (See data [Figure 12](#)).

PREVALENCE AND SUGGESTED MECHANISMS

First, it is interesting to note the rapid increase in publications containing the keywords WB, WS, and SM over the past 10 y. In 2014, there were only 2 to 3 papers related to each topic whereas in 2023 there were about 300 papers mentioning WB, 200 mentioning WS, and 35

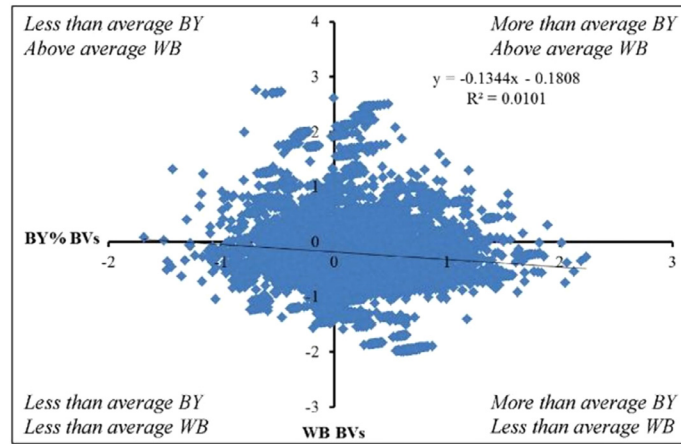


Figure 4. An XY plot of breeding values (BVs) for WB and % body weight (BY) of a high yielding broiler line showing that WB can occur in birds with both high and low BY and that there are birds with a high genetic potential for BY and below average WB (bottom right quadrant of the plot) that can be selected for both traits in the desired direction. From Bailey et al. (2015), with permission.

mentioning SM (note that the same paper can encompass more than 1 keyword) (Scopus; accessed July 2023).

Woody Breast

Papah et al. (2017) reported the progression of macroscopic and microscopic lesions in broilers during growth (1–7 wk) showing that after wk 3 more fiber degradation could be detected and it progressively increased up to wk 7. In terms of physically detecting WB (by palpation), mild situations appeared on wk 4 and doubled by wk 5. Santos et al. (2021a) showed that the rate of WS and WB in fast-growing broilers was higher compared to moderate and slow-growing breeds (fast growing 2.4 kg; moderate 2.3 kg; slow 2.0 kg at d 48). The same was observed when birds were processed at 62 d of age (fast-growing reaching 3.4 kg, moderate 3.2, and slow 2.8 kg).

It is important to note that we are currently grading the severity of WB (and other myopathies) on a continuous scale of 0 to 3, where 3.0 represents a very hard *Pectoralis major* throughout the muscle (Tijare et al., 2016). This is also important for the industry as mild WB fillets can be sold without any problem. When talking about WB, it is also important to emphasize that the meat has a higher amount of connective tissue. Solo (2016) indicated that when one tries to sell fillets affected with severe WB, the consumer feedback is generally unfavorable with comments such as rubbery texture, high chewiness, and poor texture. Aguirre et al. (2018) also reported that a consumer panel gave WB samples a significantly higher crunchiness value (2.78 ± 0.20) compared to normal fillet (1.88 ± 0.19). The same was true for chewiness, springiness, hardness, and fibrousness.

As for the appearance of severe WB, one might see some hemorrhages on the surface, with or without the accumulation of exudate. The meat pH is higher, while water holding capacity is lower (increased drip loss), due to replacement of myofibrillar proteins with connective tissue proteins (collagen) forming a scar tissue. The

meat also has a lower total protein content and a higher proportion of fat and moisture compared to normal meat (Kuttappan et al., 2013, 2017; Mudalal et al., 2015; Soglia et al., 2016; Tijare et al., 2016). Note, the difference in chemical composition is actually used to sort out the WB meat by NIR technology (Wold et al., 2017) as will be discussed below.

It should be noted that the hardness measured on the first day of processing WB meat will eventually decrease over time (Sun et al., 2018) (Figure 5). However, as was demonstrated by Sun et al. (2018) the relative difference between normal, moderate WB, and severe WB stays the same over an 8-d period. The actual values for d 0 were 6 N for the normal meat, and 27 N for the severe WB. After 8 d, they were 3 N and 14 N, respectively; the largest decrease was seen between d 1 and 4 of storage at 4°C.

As indicated before, WB affected fillets can show bulging, paleness, and are sometimes covered with clear viscous fluid. A ridge-like bulge at the caudal end of the fillet is often seen. Tijare et al. (2016) demonstrated that WB is associated with an infiltration of connective tissue,

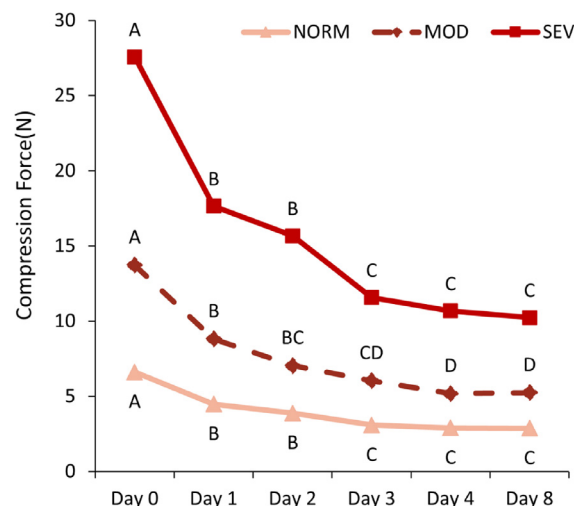


Figure 5. Changes in compression force of woody breast meat of different severity (normal, moderate, severe) over 8 d at 4°C. Redrawn from Sun et al. (2018).

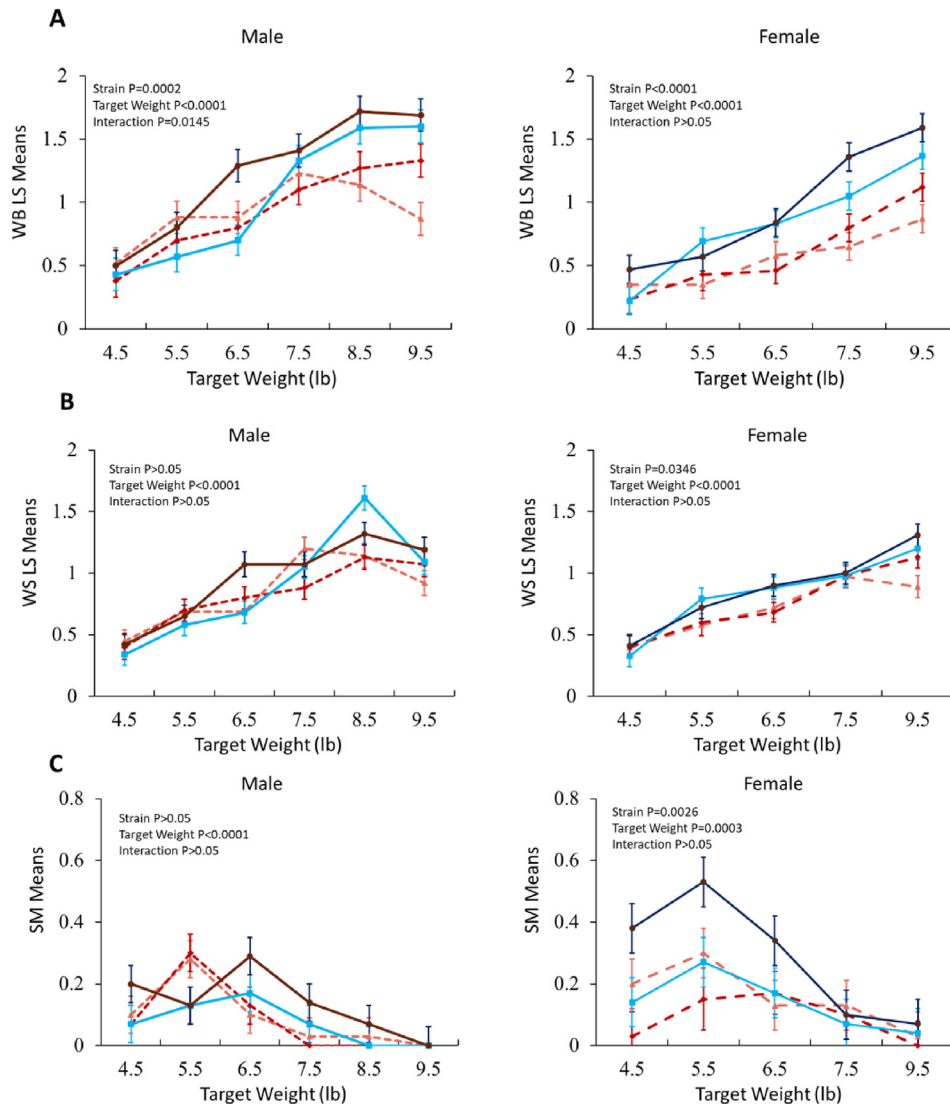


Figure 6. Effect of broiler strain and sex (male, female) on woody breast (A), white striping (B), and spaghetti meat (C). Graphs represent data reported in table form. Series lines in each graph represent a broiler strain used in the study by [Mueller et al \(2023\)](#) with permission.

which contributes to the increased hardness at different degrees of the severity. This increased hardness is often associated with higher weight ([Figure 6A](#)) and can also be with fillet thickness ([Mudalal et al., 2015](#)). [Kuttappan et al. \(2017\)](#) reported that WB breast yield and caudal region height are significantly higher than normal breasts. Additionally, WB affected fillets commonly show a higher pH (5.8–5.9) compared to normal fillets (5.6–5.7) and lower protein functionality ([Kuttappan et al., 2017](#); [Li et al., 2023](#)), as well as significantly higher drip loss ([Soglia et al., 2016](#); [Kuttappan et al., 2017](#)), pH, color (paleness), and cooking loss ([Aguirre et al., 2018](#)).

In a 2023 survey that looked at breast fillet packages in the North American market, obtained from 7 different companies (about 250 packages per company), the company with the least occurrence had 0.5% of mild WB and the most occurrence of 10%. This was also related to the average size of the fillets (225 g and 296 g, respectively) but also the fact that some companies are doing more sorting of the meat. For example, a company that merchandised 367 g fillets had only 3% of the packages

showing mild WB while another company with 239 g fillets had 9% ([Nolan, 2023a](#)).

[Figure 7](#) shows a schematic representation of the possible time series of events, molecular pathways, and biological processes involved in the onset and triggering the occurrence of WB, WS, and SM myopathies affecting broilers. Within this context, a low vascularization of the *Pectoralis major* muscle (due to its hypertrophic growth) is currently considered as the most feasible phenomenon that, leading to hypoxia, likely triggers the development of these disorders ([Soglia et al., 2021](#)). Recent findings, further corroborating this hypothesis, built a basis for supposing a key role of endoplasmic reticulum stress, likely triggered/induced by protein misfolding, in the development of these defects ([Bordini et al., 2021](#)). Indeed, the increase in protein synthesis which is required to support the hypertrophic growth of the pectoral muscle potentially overburdens the capacity of the sarcoplasmic reticulum thus leading to the accumulation of misfolded and/or dysfunctional proteins such as collagen type IV ([Bordini et al., 2024](#)). This hypothesis is supported by the evidence that alterations

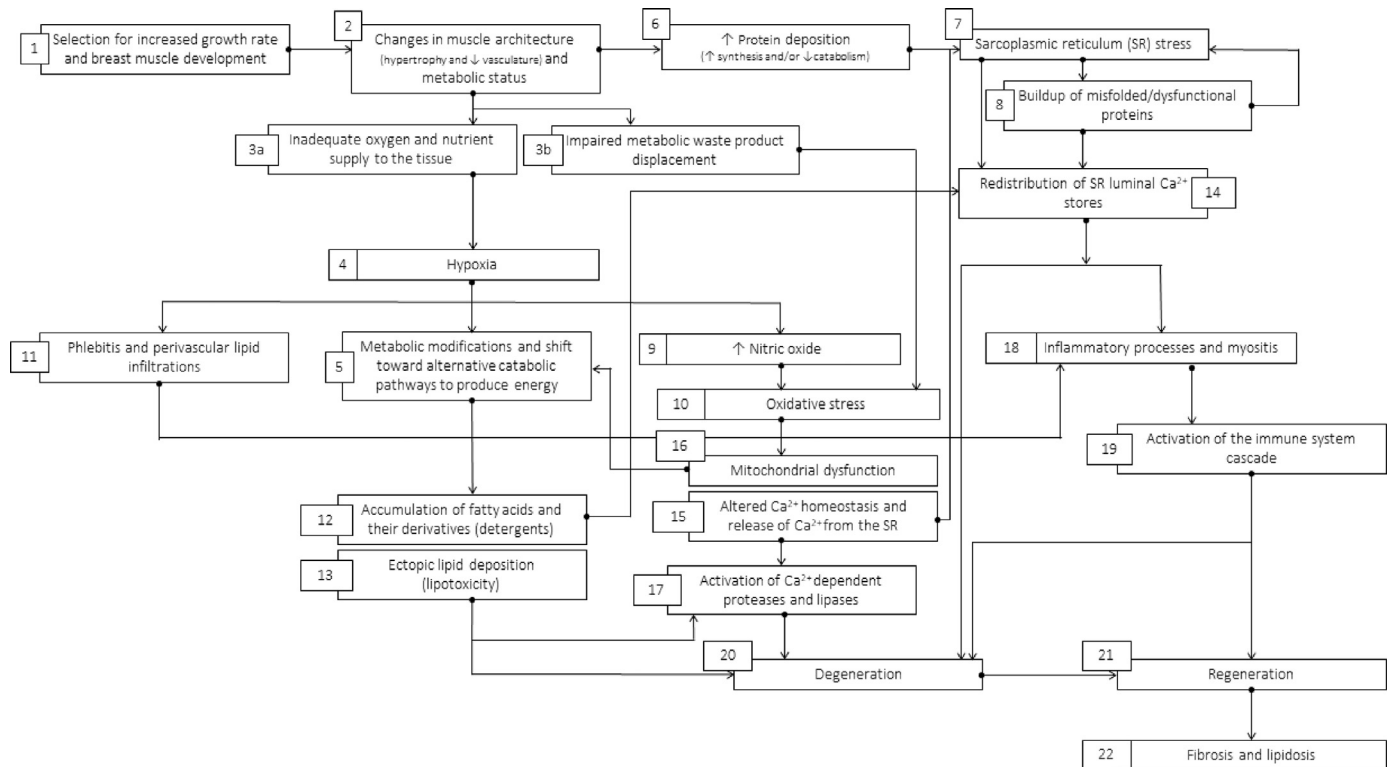


Figure 7. Schematic representation of the possible time series of events, molecular pathways, and biological processes involved in the onset and triggering of the white striping, woody breast, and spaghetti meat myopathies affecting broiler *Pectoralis major* muscle. From Soglia et al. (2021), with permission.

in the endoplasmic reticulum along with a subsequent activation of the Unfolded Protein Response are among the first ultrastructural and molecular changes associated to an early onset of WB (Sihvo et al., 2018; Papah et al., 2018). Then, once that the process has been established, a time-series sequence of events (i.e., phlebitis, oxidative stress, altered calcium homeostasis, etc.) is initiated thus resulting in the activation of complex response mechanisms (i.e., modifications in the energetic metabolism, inflammation, degeneration, and regeneration) which ultimately led to the development of the growth-related defects (Soglia et al., 2021; Che et al., 2024).

White Striping

The incidences of WS are also related to the weight of the birds (Figure 6b) where it was reported that male broilers show higher incidences than females. The WS (Figure 1) is characterized by white striping running parallel to the muscle fiber direction. Like the histology of WB, it shows necrosis and later replacement of muscle fibers with a scar tissue consisting of connective tissue and fat cells (Kuttappan et al., 2013; Che et al., 2022). One of the first reports on the occurrence of white striation (Bauermeister et al., 2009) indicated a relationship of WS and broiler size. Kuttappan et al. (2012) reported the influence of fast growth on increased WS severity. Later, Sihvo et al. (2014) elaborated on the myo-degradation with fibrosis and regeneration in *Pectoralis major* muscles.

Overall, WS is almost considered today as the norm since a large majority of the skinless breast fillets sold on the market show this myopathy (Che et al., 2022). If sorting is done at the plant, it is mainly to remove/separate the severe cases of WS from going to fresh skinless trays, especially not to be placed adjacent to WS0 or WS1 as consumers are sensitive to such large variations in appearance. Genetic selection in this area has been discussed earlier by Bailey et al. (2015).

Spaghetti Meat

Figure 6C shows the incidences of SM. In this case, the relation to the overall body weight is different than in WB and WS where broilers of ~2.5 kg (~5.5 lb) show the highest incidence of SM followed by a decrease in incidence as the broiler size increases (Mueller, 2021; Mueller et al., 2023). It should also be noted that today we also see an increase in muscle fiber separation found in the *Pectoralis minor* (“tenderloins”) where in some publications authors refer to it as “feathering” (to be discussed in the next section).

SM does not seem to occur in the live bird, but the condition for the separation (less collagen crosslinking and different types of collagen) are already present in the live muscles. Differences in the rate of SM have been recently reported to be related to the primary processing steps that can affect the muscle integrity as well as post-mortem muscle acidification. Che et al. (2022) reported higher SM in water chilling versus air chilling because of

the additional agitation in the former. Furthermore, mechanical force applied during primary processing operations such as defeathering, deskinning, deboning can also increase the severity and appearance of this condition (Baldi et al., 2021; Che et al., 2022).

SM is characterized by separation of the muscle bundles composing the *Pectoralis major*, suggesting an altered collagen turnover and synthesis, thus resulting in an altered immunoreactivity to procollagen type III (Mazzoni et al., 2020). Lower water holding capacity has also been observed in SM fillets compared to normal meat (Tasoniero et al., 2022). Overall, the meat appears soft, mushy, and sparsely tight, resembling spaghetti pasta (Baldi et al., 2021).

Considering the recentness of SM condition, the mechanisms underpinning its appearance are still mostly unknown and less investigated compared to WB and WS (Baldi et al., 2021). The incidence of SM can reach up to 20% and it also negatively affects meat appearance, nutritional value, and technological properties (Baldi et al., 2020; Wang et al., 2022). This obviously results in overall decreased meat value and economic losses.

Severity can also be graded on a 0 to 3 scale where 0 is normal, 1 shows some folding on the surface, 2 shows separation of muscle fibers on the surface, and 3 shows significant separation of muscle fibers below the surface (Che et al., 2022).

A comparison of the SM occurrence in broilers and roasters observed in 2 industrial plants in North America reported that the younger, smaller broilers showed a higher proportion of SM incidences (21% moderate and 7% severe) compared to older, larger roasters (15% moderate and 4.0% severe) (Nolan, 2023b).

Feathering

Feathering is a term used to describe muscle fiber separation in the *Pectoralis minor* and currently is reported to be on the rise (Nolan, 2023b). Like other myopathies,

feathering can be graded based on severity. Soglia et al. (2019) presented a 0 to 2 scale where 0 is normal, 1 is moderate with up to 2 separation points with a length <1.5 cm, and 2 is severe with more than 2 separation points with a length >1.5 cm.

A comparison was reported regarding the occurrence of feathering in broilers vs roasters in 2 large industrial North American complexes, where it was reported that the younger broilers had a higher proportion of feathering incidences (38% moderate and 58% severe vs 34% and 31% for the older roasters, respectively) (Nolan, 2023b). The results also showed that the *Pectoralis minor* is more susceptible than the *Pectoralis major*. Mueller (2021) reported no significant effect of broiler size on tender feathering in a research setting. However, it should be pointed out that increases in feathering of tenders might also be a result of the step(s) used during the primary processing to defeather, chill, and debone the meat (Barbut, 2015). For example, tender pullers on auto deboning machinery could enhance the feathering effect in *P. minor* susceptible muscle.

Muscle Growth Rates and Potential Effects on Myopathies

The increase in broiler bodyweight is a result of selection for birds with a large muscle mass with a focus on the breast meat fillets. To understand this, one should go back to the embryonic and post-hatch development of muscle fibers. The total numbers of fibers are mainly determined during embryonic development (hyperplasia) from d 0 to 21 while inside the egg (Velleman, 2015) (Figure 8). After hatching, the increase in skeletal muscle mass is mainly due to an increase in muscle fiber size (hypertrophy, increase in fiber diameter) (Siegel, 2023). Ausems et al. (2021) and Velleman (2023) discussed the importance of the extracellular environment for satellite cells in fast-growing broilers. Overall, space between the fiber bundles (covered by the perimysium connective tissue layer) and individual muscle

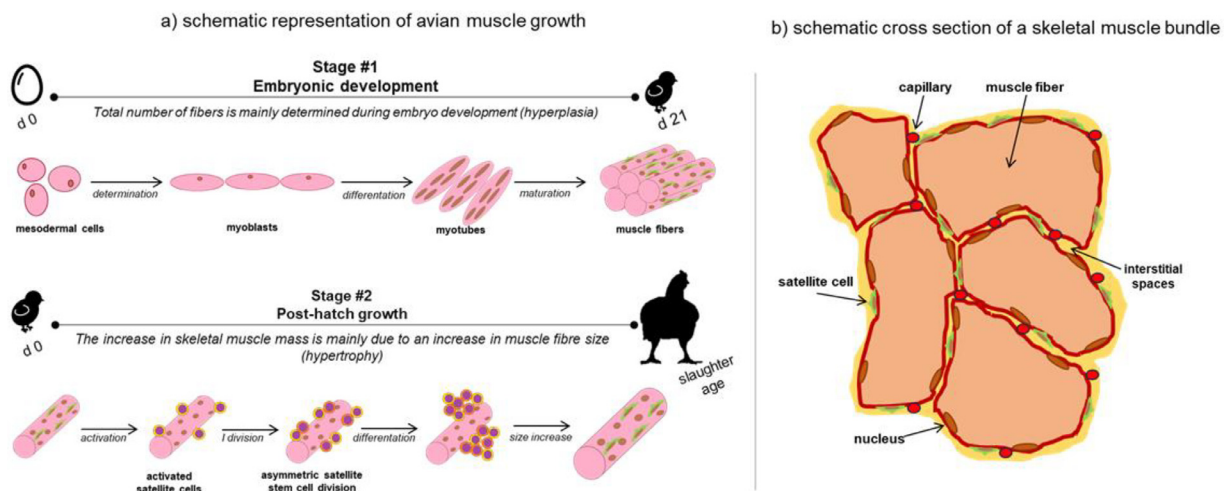


Figure 8. Avian muscle development and growth: (A) showing stage 1 of embryonic development and stage 2 of post-hatch growth; (B) showing the importance of extracellular environment for satellite cells. From Velleman (2015) and Ausems et al. (2021).

fibers (covered by the endomysium connective tissue layer) is necessary for liveability of the muscle. Satellite cells require appropriate niche environment and vascularization for muscle fiber enlargement and regeneration. However, due to extensive hypertrophy of the fast-growing broiler those spaces are diminishing, causing hypoxic conditions within the muscle, and therefore not so many satellite cells can be active in repairing injured muscle fibers during the growing period (Velleman, 2023). In a study by Branciari et al. (2009) the area of an average muscle fiber was reported to be $5.7 \mu\text{m}^2$ in meat-type broilers while it is only $1.6 \mu\text{m}^2$ in egg-type layers. This also causes reduced capillary density and less development and maturity of connective tissue in the muscle. The possible adverse effects on the functionality of the fibers include insufficient oxygen and energy supply as well as slower removal of metabolic waste products (Soglia et al., 2021; Velleman, 2023). It is interesting to note that turkeys do not exhibit so many growth-related abnormalities (Zampiga et al., 2020). Velleman (2023) suggested that the reason could be related to the different effect of selection for hypertrophy on satellite cell behavior. Indeed, in pectoral muscles of current fast-growing chicken-hybrids' satellite cells had decreased proliferation and differentiation compared to commercial chicken lines used in the 1990s (see the effect also in Figure 8B), opposite trend has been observed in modern commercial meat-type turkey which has increased proliferation and differentiation compared to older slower-growing turkeys.

Deep Muscle Myopathy

One of the first reports about breast meat myopathies in broilers appeared in 1985 with the title of "Deep pectoral myopathy: A penalty of successful selection for muscle growth" (Siller, 1985). The cause of this myopathy is that the fascial component is too small to accommodate the enclosed *supercoracoid* muscle during vigorous exercise, when the muscle increases its weight (and overall size) by about 20%. The inelastic compartment essentially strangulates the swollen activated muscle. In the paper, the author suggested that "the myopathy is man-made and the condition coincidental with the production of large breasted turkeys and broilers and is therefore a penalty for successful selection." Later, Swatland (1990) reported on the growth of connective tissue binding of turkey muscle fibers together, indicating that, on a radial basis, the growth of intramuscular connective tissue does not keep pace with the growth of the *Pectoralis* muscle fibers. A follow up report by Wilson et al. (1990) also showed some necrotic fibers due to this occurrence and suggested that one possibility is that the fibers have become rounded because of the growth of connective tissue and therefore have not kept up with the growth of the muscle fiber, thus depriving them of extracellular support. Today, we hardly see this problem in broiler/turkey breast meat fillets as breeders have selected against birds showing this condition.

Pale, Soft, Exudative Meat

Another challenge that appeared in the 1990's is the so-called PSE condition (Solomon et al., 1998). In this case, the muscle pH drops very quickly during the rigor mortis process and results in some protein denaturation that later affects the meat quality. In their paper, the author mentioned that morphological studies have related a significant increase in fiber size in addition to structural irregularities in PSE muscle (including decreased capillary density, hypercontracted fibers, and myoplasmic calcium loading). The PSE problem was also seen in pork meat where 2 major genes responsible for calcium movement within the muscle fiber have been identified as defective. In that case, breeding has helped to remove those genetic variants from the pig herd. In poultry, it appears that the PSE phenomena is governed by a cascade of genes (Barbut et al., 2008; Che et al., 2023), and it is therefore more complicated to select against it.

DETECTION METHODS (FOCUS ON WOODY BREAST)

In live animals, one can detect the presence of WB in birds at about 18 d of age by palpation (Sihvo et al., 2017). Later, as the bird grows, it is easier to detect but there is still a need for a trained person. There are more sensitive methods that rely on ultrasound (Simões et al., 2020) and/or radiofrequency/CT scanning (de Almeida Mallmann, 2019).

When the meat arrives at the plant, the industry is interested in sorting out the severe cases of WB as they will result in complaints from individual consumers or rejection by the fast-food industry. Different methods can be used to sort out the meat. Currently, the most popular method around the world is manual sorting by employees who are looking and touching deboned skinless breast fillets (see Palpation below). There is also automation by NIR where the basis of sorting is the difference in chemical composition of WB and normal meat.

Palpation

Employees are asked to assess the overall hardness of the sample by squeezing the meat between their fingers, where WB samples are harder in certain locations, especially at the cranial area of the fillet. As mentioned above, the severity is graded on a continuous scale which also requires training of the employees. This method is obviously subjective and depends on the consistency of the evaluator over time. Research scientists, at universities and industry, have used objective instruments to measure the hardness of normal and WB samples and came up with good standard values (Figure 9). The graph was obtained from using 260 fillets where a round probe (6 mm diameter) was used for an objective evaluation. Sun et al. (2018) also used a 6 mm probe for determining compression force of breast fillets and reported

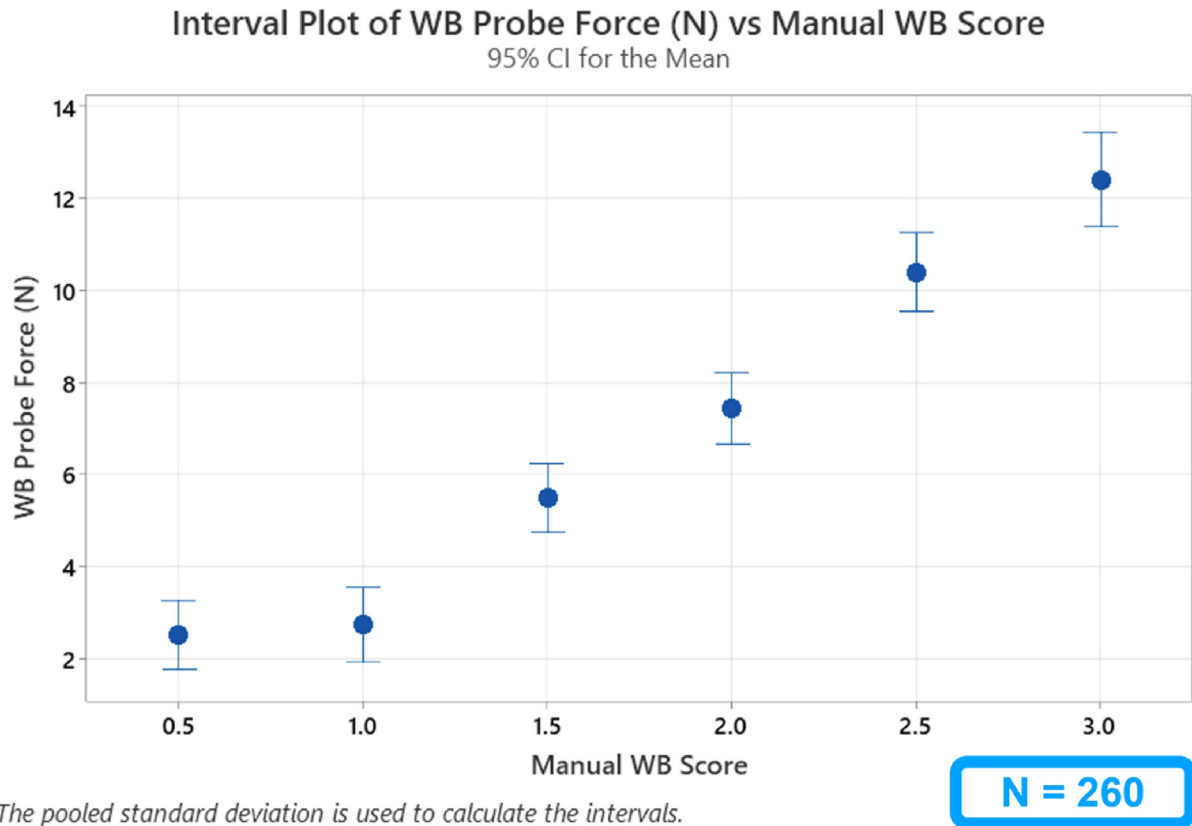


Figure 9. Plot showing the relations between woody breast (WB) severity and objective compression force (measured in Newtons). Industry developed curve (N = 260).

that compression force and palpation scores were highly correlated ($r > 0.79$). It should be noted that there are a few papers discussing the relationships between sensory analysis and objective texture analysis of WB meat (Maxwell et al., 2018; Soglia et al., 2021).

Near Infrared Spectroscopy

This method is based on detecting the amount of protein and moisture in the muscle. As mentioned above, WB samples have a lower protein content and higher moisture. The NIR technology has been used successfully, for >20 years, to determine, for example, poultry feed composition. In the case of meat, a strong NIR beam is scanning the skinless fillets, moving at a fast speed (240 fillets/min) on a conveyor belt. The operator can program the equipment to sort out meat (Figure 10) based on their criteria for separating severe/unacceptable to the consumer samples (Wold et al., 2019). Currently, this is the fastest method available on the market but challenges with false positive and negative can be an issue at some plants and therefore currently not so many NIR units are used by the industry.

Bioelectric Impedance Analysis

This is based on 2 to 4 electrodes inserted into the meat and sending a mild electric current into the meat to analyze the resistance and reactance. Later,

mathematical algorithms are used to detect the presence of WB at varying severity levels. Currently, it is mainly used in scientific laboratories (Morey et al., 2020). This method represents a contact type approach which can slow down the detection process and if not careful can result in cross contamination.

Optical Coherence Tomography and Hyperspectral Imaging

OCT is an interferometric technique capable of non-invasive 1D, 2D, and 3D imaging of the subsurface microstructure whereas hyperspectral imaging is an imaging modality to measure optical properties of samples, such as reflectance. According to this method, WB shows thicker epimysium tissue than normal fillets (Yoon et al., 2016). The hyperspectral imaging method has the potential to distinguish between compositional differences of the meat. Another benefit of hyperspectral imaging is its ability to detect foreign material (e.g., plastic) inside or outside the samples being scanned. In the future, a fusion of the OCT and hyperspectral methods may be used to rapidly and accurately sort out WB fillets.

Air Deformation System

In this method, a puff of air is used to deform the sample at the cranial area and then lasers are used to

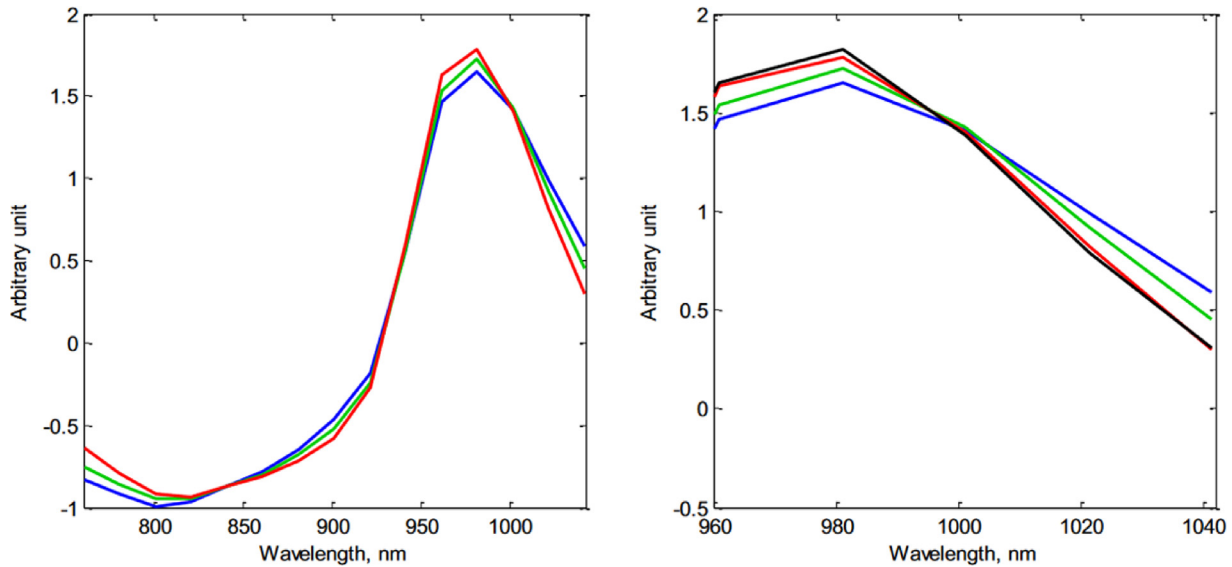


Figure 10. Near infrared (NIR) spectra from one selected fillet of each class normal (blue), moderate WB (green), severe WB (red). Right panel: zoom-in on water absorption peak with spectrum of liquid water (black) added for comparison. From [Wold et al. \(2019\)](#) with permission.

measure the recovery ([Sun et al., 2021](#)). This method has been adopted to detect WB (replacing a person pressing the fillet) and in the past was developed to assess the hardness of food products such as cheese (during the ripening process). In any case, this method requires an accurate positioning of the air puff relative to the sample and is not currently used in commercial settings.

Side-View Machine Vision System

In this case, machine vision technology is used to measure the degree and bending of the chicken breast fillet as it moves off the end of the conveyor belt. Fillets affected with severe WB are stiff and therefore will not bend as much as normal fillets. This requires a fast camera (e.g., 200 frames/sec) and according to [Yoon et al. \(2020\)](#) it can be placed on a fast-moving line (100 ft/min = 30 m/min with 90 images per fillet) at a high degree of accuracy. Note, this method is currently used to evaluate the quality of raw bacon slabs in pork processing plants.

Image Analysis of Carcasses

Using an image of the defeathered carcass and calculating the relative proportion of different sections of the skin-on *Pectoralis major* area has been shown to potentially enable the sorting out of birds with WB. The system is based on calculating the relative width of the breast area at 2 different locations (cranial and posterior part of the breast), breast length, area of the breast meat ([Sun et al., 2022](#)). A patent for this technology was granted in 2020 ([Hanning et al., 2020](#)). Further automation of data collection is needed for sorting purposes; however, the prediction of WB from carcasses could provide valuable information to processors upstream (i.e., live production impacts on WB) and downstream (i.e., expected incidence of WB in plants).

SOLUTIONS: SHORT- AND LONG-TERM

As indicated above, the poultry meat industry must deal with meat containing myopathies that is coming into the processing plant. There are short-term solutions that can include adjustments on the farm (e.g., affecting growth rate) and at the processing plant such as removing severe cases of WB and SM and diverting those fillets into further processed meat products. On the other hand, the industry is also looking for long-term solutions which include genetic selection that obviously will take much more time to achieve but are not resolving the current situation.

The non-genetic factors have been estimated to account for >65% of the variance ([Bailey et al., 2015, 2020](#)) include factors such as nutritional influences (e.g., antioxidants in the diet, anti-inflammatory additives, amino acids, and nutrient availability/quality that affect growth rate), management (e.g., ventilation, environmental temp), and meat processing ([Figure 11](#)).

The industry is also evaluating different breeds and their crosses for traits such as meat tenderness. In one such large scale industry trial, shear force values of breast fillets obtained from breeds identified as A, B, C, and D were 8.3 ± 0.3 , 9.1 ± 0.3 , 9.0 ± 0.2 , and 9.3 ± 0.3 N, respectively. The corresponding work values (area under the curve) were 105 ± 5 , 113 ± 4 , 114 ± 5 , and 117 ± 5 N·mm. This demonstrates that there are breed effects and in fact the industry has moved away/stopped using certain genetic lines and their crosses (Bacon, personal communication). This can also be visualized in [Figure 12](#) where the effect of fillet weight and WB score can be seen in a large industrial trial.

It is interesting to note that one of the large fast-food restaurants spent \$30 million to reduce the size of the chickens they use by 20% to make the fillets in their sandwiches and salads, in response to customer

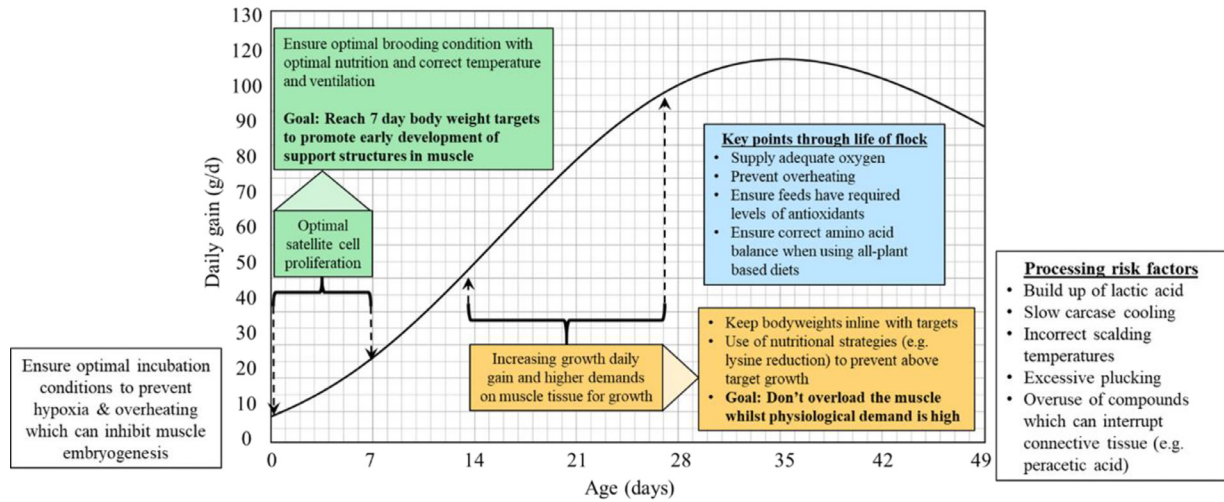


Figure 11. Proposed critical stages of broiler lifecycle where management may be critical for reducing myopathies. From Bailey (2023) with permission.

complaints about the rubbery texture of its chicken products (Swerdloff, 2017).

Interventions During Primary and Secondary Processing

Currently, severe woody breast (WB3) is diverted into products where either mechanical tenderization or chopping are used to mitigate the problem of tough meat. The meat is then usually incorporated into cooked

products such as deli loaves, sausages, nuggets, emulsion-type meat products (Oliveira et al., 2020). This is usually done by incorporating a limited amount of the affected meat into the deli products as inclusion of high amounts can result in greater cooking loss, poor binding, and poor texture (Bowker et al 2019). Also, in products such as chicken nuggets one should be careful to chop the meat to small sizes otherwise the tough meat chunks will be described by consumers as chewier, springier, and more cohesive (Brambila et al., 2017; Santos et al., 2021b). Caldas-Cueva et al. (2020) reported that cooked

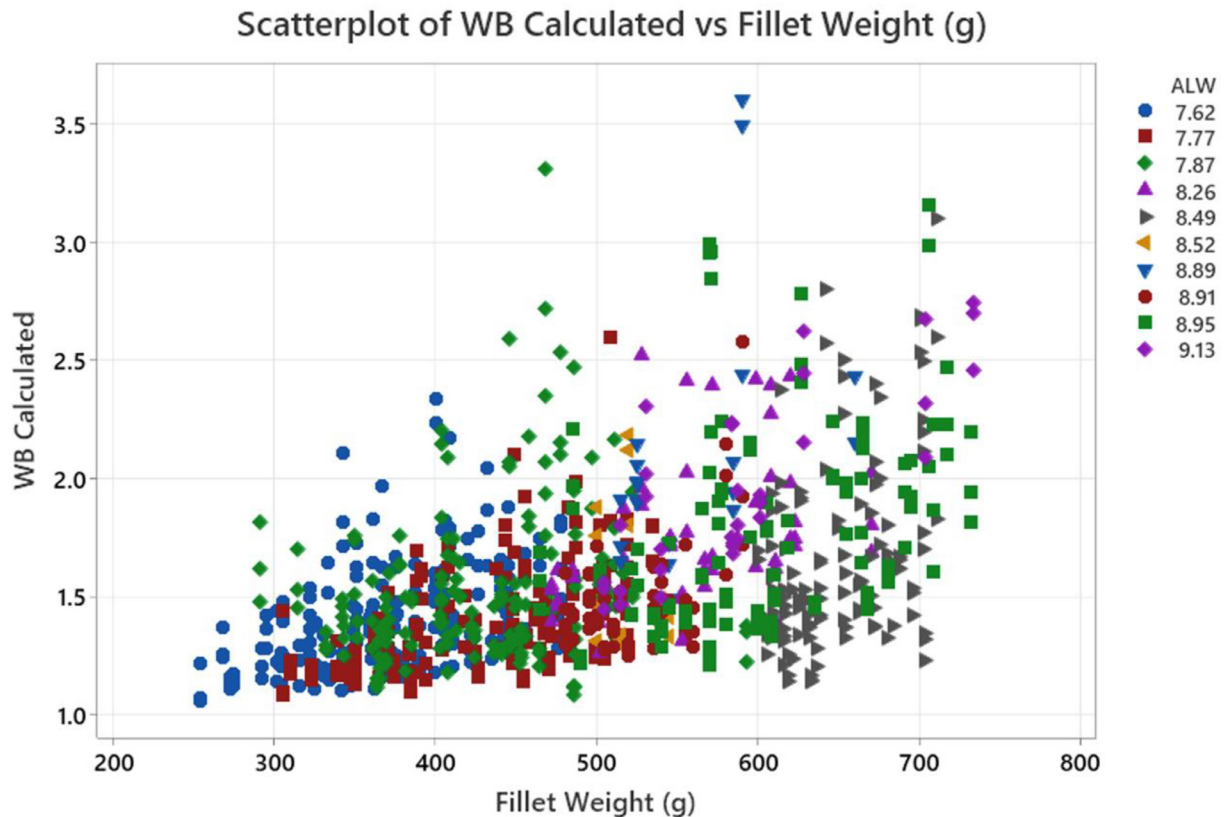


Figure 12. An example of the occurrence of woody breast (WB) fillets as a function of fillet weight and average fillet weight. Data from a commercial trial in the USA.

deli loaves made with 100% severe WB had cooking loss of 19% versus 5% for loaves made with 100% normal fillets. Overall, increasing the proportion of severe WB in the formulation (33% and 67%) resulted in successively higher cooking losses. At the same time, the hardness of the 100% normal fillet loaves was 22 N while the loaves made with 100% severe WB was significantly different at 27 N.

Industry data shows that some combinations of WB and normal breast meat can be used to make breaded chicken nuggets with no significant difference in overall liking, breading adhesion, or ranking. In one such large scale trial, 100% WB nuggets were too soft, too mushy, too moist, and showed the lowest cooking yield. Whereas nuggets with 25, 50, and 75% WB have the “just right” texture attributes. On the other hand, 100% normal breast nuggets can be too firm and too dry (Hamill, 2021). In the case of non-breaded breast patties, another large scale industry trial recommended using up to 50% severe WB to deliver the best result (both consumer and financial). Increasing WB inclusion was shown to result in increased flavor, moistness, and a decrease in firmness and significantly lower cooking yield. In the case of a whole muscle poultry product, cooking loss in moderate and severe WB was significantly higher than in normal fillets. Severe WB exhibited undesirable eating attributes. In general, moderate and severe WB fillets are crunchier and less tender than normal fillets (Barbut and Leishman, 2022; Smith et al., 2020; Hamill, 2021). Mincing the WB and/or SM meat and using it for meat loaves or nugget preparation with or without the addition of a hydrocolloid gum such as alginate or dairy proteins have also been reported as acceptable by industry and academic reports (Wang et al., 2022, 2023).

General Nutritional Interventions

Nutrition can play an important role in the reduction of WB. Overall feed is used to supply nutrients for the muscle to grow and the rate and density of its supply is critical to optimize muscle development (including satellite cells, as discussed above, see Figure 8). The nutrients used also support muscle cellular health, including blood flow, reducing oxidative stress and inflammation.

Simões et al. (2020) reported that restricting the diet of growing broilers can result in significantly lower rate and severity of WB. They used ad-libitum, 90, 80, 70, 60, and 50% feed restriction which resulted in birds weighing 3.6 kg, 2.8, 2.5, 2.1, 1.7 kg at 49 d. The corresponding average WB score (using a 1 to 4 scale; 1 = normal, 4 = severe) was 3.6 for the ad-libitum on d 49 and 3.3, 2.3, 1.7, 1.3, and 1.1 for the 90, 80, 70, 60, and 50% feed restriction, respectively.

White striping is generally considered today as the norm since a large majority of the skinless breast fillets on the market show this myopathy (see Figure 3). If sorting is done at the plant, it is mainly to remove/separate the severe cases (WB) from going to fresh skinless

trays, especially not to be placed adjacent to WS0 or WS1 as consumers are sensitive to large variations in appearance. Note, genetic selection against WS has already been discussed above.

Spaghetti meat has recently been reported to be affected by mechanical action exerted on the breast fillets. As discussed earlier in the review, the conditions for showing the problem (less collagen crosslinking and different type of collagen compared to normal meat) already exists in the muscle prior to arriving at the processing plant. For example, Cahaner (2023) indicated that longer exposure to defeathering equipment increases the proportion of SM, while Che et al. (2022) reported that air chilling resulting in less SM than water-chilling (i.e., exposure to more agitation).

Early Feed Restriction

Velleman et al. (2014) published a series of papers showing the effect of genetic selection and early feed restriction on expression of genes required for satellite cell proliferation and differentiation, necrosis, and formation of intramuscular fat deposits. Later, Velleman (2023) concluded that morphological structures of broiler breast muscle have changed in modern commercial broilers with muscle fiber diameter increased, circulatory supply decreased, and connective spacing between fibers and fiber bundles decreased. Meloche et al. (2018a) have showed that restricting feed intake (95, 90, and 85%) had a significant reduction on WB and WS. However, it also negatively impacted performance and yield. Cruz et al. (2017) showed that increasing dietary Lysine in grower and finishing diets was positively correlated with the occurrence of WB and WS as well as body weight gain and breast meat yield when broilers were processed on d 35 and 42. They concluded that the myopathies were responding to the increase in body weight gains in response to dietary Lysine and not Lysine itself. Livingston et al. (2019) showed that supplementing amino acids Glutamine (1%) and Arginine (0.25%) in an otherwise balanced diet resulted in improved performance; but suppressed breast yield. The high amino acids diet resulted in a fast growth rate, and higher incidence of WB and WS. They also reported that fillets with increased myopathy scores were associated with increased blood CO₂, H₂CO₃, and reduced O₂. This suggests that diets with excessive crude protein may contribute to hypoxic conditions and contribute to WB (see also Castilho Heiss et al., 2024; Bordignon et al., 2022).

Meloche et al. (2018b) showed that the concept of removing a portion of the synthetic Lysine during certain feeding periods can be effective at lower WB, without altering growth rate, but was associated with downward trends in breast meat yield. This concept termed “Lysine deletion” has proven difficult to translate into measurable reductions of WB in commercial operations, likely due to the variation among farmers, ingredients, and feed manufacturing. Due to the potential of

Table 1. Economic assessment of an alternative nutrition program that can yield a significant reduction in woody breast. Note that generically it will produce lower/poorer performance and yield and may mean lower margins (Mitchell, 2023. Unpublished internal company document. Perdue Farms Inc.).

Economic model	Standard	Alternative nutrition
Harvest number	1,000,000	1,000,000
Average live weight	9.00	9.00
Feed conversion ratio	1.850	1.900
Feed cost (\$/ton)	\$375.00	\$365.00
Livability	95.00%	95.00%
WOG yield	78.00%	77.00%
Total white meat (%)	29.00%	27.50%
Boneless breast price	\$2.00	\$2.00
Downgrade price	\$1.00	\$1.00
% Extreme hard muscle	5.00%	2.00%
Margin per bird (\$)	\$1.850	\$1.715

losing meat yield and growth performance, processor margins can be hurt even if the amount of WB drops. [Table 1](#) shows a calculation of the effects and illustrates that an alternative nutrition program that results in lower WB incidences can also result in lower margin per bird.

Use of Antioxidants/Anti-Inflammatory Agents

As indicated before ([Figure 7](#)) an increase in inflammation and oxidative stress is associated with the WB condition. Supplementation with Vitamin E, organic selenium, and other trace minerals that are directly involved in the antioxidant system have shown mixed results in reducing WB. [Wang et al. \(2020\)](#) showed that Vitamin E in the starter diets reduces the severity of WB. Vitamin E and the anti-inflammatory Alpha-Linolic Acid were shown to alleviate microscopic WB severity in young chicks when fed alone or in combination ([Wang et al., 2021](#)).

[Abasht et al. \(2016\)](#) found biomarkers associated with oxidative stress and overactivation of the Vitamin C synthesis pathway associated with WB. [Bodle et al. \(2018\)](#) reported that Vitamin C added at 94 ppm resulted in a significant reduction of average WB scores, including a large reduction in the most severe incidence. [Meyer and Bobeck \(2023\)](#) also reported that blended product containing Vitamin C had a positive effect on reducing WB. Overall, Vitamin C is not typically a part of vitamin premixes, however, it is sometimes delivered in the drinking water during heat stress. In any case, one should avoid the use of oxidized fats and oils ([Kuttapan et al., 2021](#)). The use of an appropriate antioxidant such as ethoxyquin would be warranted when fat quality is questionable ([Estevez and Petracci, 2019](#)) reported that addition of magnesium (0.3%) fed to chickens under heat stress, while also fed oxidized oil, reduced WB myopathies by 50%. The proposed mechanism is in support of the antioxidant capacity. Feeding extra magnesium might negatively impact litter quality, so its use should be watched carefully.

[Greene et al. \(2019\)](#) reported that phytase at 2-3X the standard dose has been shown to have a moderate effect on the severity of WB. The increase in plasma inositol, which acts as a cellular antioxidant is the proposed mechanism. The declining cost of phytase has made upping dietary inclusion a reasonable intervention for commercial producers.

L-Arginine is readily available as a feed additive and is involved in the synthesis of nitric oxide, is a vasodilator, and participates in the production of muscle creatinine. [Bodle et al. \(2018\)](#) and [Zampiga et al. \(2019\)](#) showed improvement trends of reducing WB and WS with increasing L-Arginine above traditional recommendations. [Zampiga et al. \(2019\)](#) also showed a reduction in spaghetti meat with elevated dietary Arginine.

Inositol-Stabilized Arginine (**ASI**) is also a source of Arginine that may boast the nitric-oxide vasodilation more than other arginine sources. [Meyer and Bobeck \(2023\)](#) demonstrated its ability to reduce WB incidence and severity. This form of Arginine is not currently commercially available.

Guanidino Acetic Acid has been shown to lower the incidence of WB when fed with all-vegetable diets and is a commercially available feed additive. The proposed mechanisms include precursor to creatinine, sparing arginine, glucose metabolism, and nitric oxide formation. By doing so it can improve vascularization, vasodilation, and oxygenation ([Oviedo-Rondón and Córdova-Noboa, 2020](#)).

Farm Management Factors

Overall, there are various risk factors for WB. For example, [Che et al. \(2022\)](#) separated factors into flock demographics variables (i.e., live weight of baby chicks, source of chicks), flock health variables (mortality rate, coccidiosis vaccination, hold time in lairage at plant), transportation variables (i.e., birds per crate, dead on arrival, loading duration), and environmental variables (i.e., season).

Other management factors recommended by primary breeders ([Anonymous, 2018](#)) that may impact myopathies include: 1) Incubation – temperature, oxygen, CO₂ levels that can affect the embryo development as well as the number of satellite cells. 2) During brooding ensure access to feed and proper ventilation to avoid high CO₂ levels. 3) Lighting can alter growth rate where also low intensity lighting encourages birds to sit more so exposing the breast muscles to higher temperatures. 4) Litter that is built up over numerous flocks may produce more heat that can affect the breast area when birds are sitting. 5) Flock thinning can result in sudden, rapid growth rate which might contribute to WB development.

As for [Che et al. \(2022\)](#), risk factors for SM were separated into farm variability, flock demographics variables (i.e., source of chicks, live weight of chicks), transportation variables (i.e., truck travel time), flock health variables (i.e., coccidiosis vaccination, infectious bursal

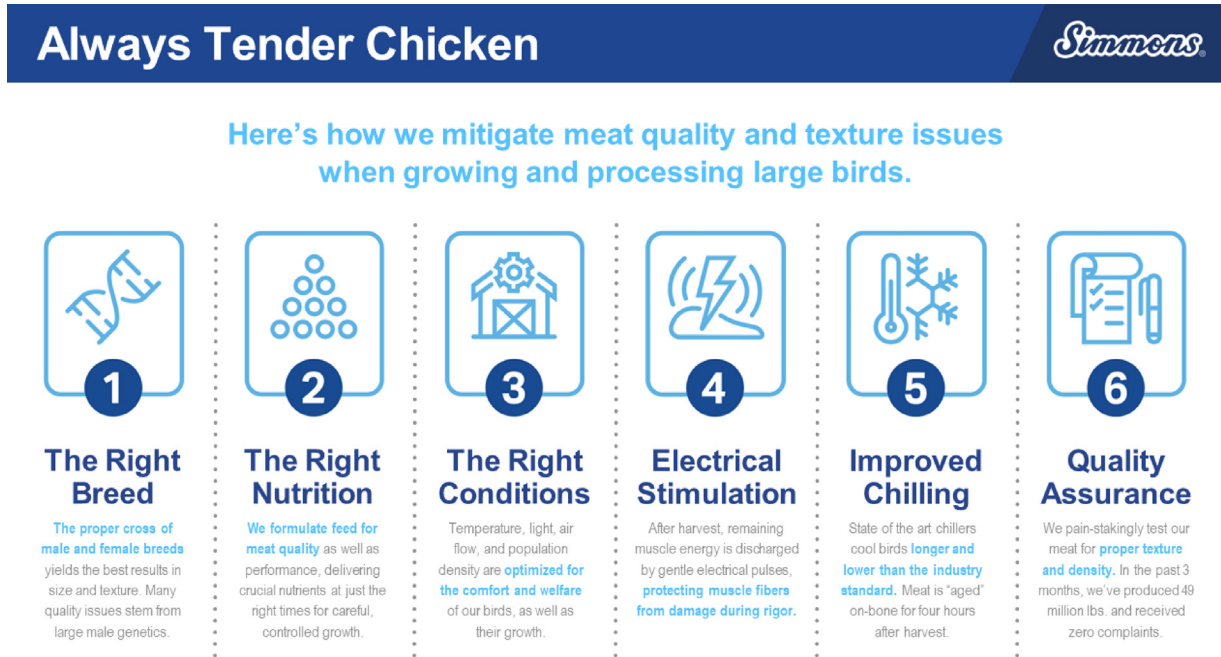


Figure 13. Ways to mitigate meat quality and texture to obtain tender chicken meat. Image courtesy of Simmons Inc.

disease vaccination), processing plant variables (i.e., time in lairage at plant, air vs. water chilling), and environmental variables (i.e., temperature during grow-out). The authors concluded that there is a strong association observed between myopathies and heavier and thicker breast fillets. Ultimately, the development of breast myopathies is complex, multi-factorial, and influenced by demographics, health, husbandry, and environmental factors. In their study of Canadian flocks, mild to moderate WS was observed in 95% of the birds (thus now referred to as the “new normal”), while >36% of fillets exhibiting SM, and about 10% of fillets exhibiting severe WB (see also Figure 3). The authors also concluded that SM and WB do not share the same pathogenesis, however, breast myopathies tend to cooccur with others. In fact, 2 risk factors were shared between SM and WB (positive association with live weight at harvest, and high temperatures during grow out). Interestingly, three factors had opposite effects on the odds of developing SM and WB; administration of the coccidiosis vaccine, source of chicks, and hold time on lairage.

LONG-TERM INTEGRATED SOLUTIONS

As indicated before, genetic selection can be one of the main strategies to get birds with less myopathies (see also Figure 4) but due to the low heritability of these myopathies, it will take some time. Cahaner (2023) reviewed the emergence of ascites and leg problems in the past and indicated that the industry thought that we have reached the limit of broiler growth. However, genetic selection was applied, and these problems were significantly reduced. Overall, the interventions mentioned in the short-term section can also be applied for the long-term solutions where recommendation for low-

density diets can be prescribed for certain periods of the growing cycle.

The main objective is to provide consumers with high quality, tender meat at an affordable price. This is not a small task and requires a good understanding of animal and meat science. Figure 13 summarizes steps the industry uses to achieve this objective.

CONCLUSIONS

Mild to moderate WS are now considered normal by consumers while moderate to severe WB is not acceptable by a number of consumers. WB incidence has been steadily decreasing (at approximately 10% observed reduction per year), however, there was a recent increase observed in May and June 2023 in several industrial USA facilities but has since returned the observed decline. WB utilization in further processing is now pretty well established as using the whole muscle from severe WB fillets usually results in a costly downgrade. SM incidences are increasing, and the causation is different than WB and therefore continued research is needed. Mild and moderate SM is not resulting in a significant number of consumer complaints, as compared to WB; more work is needed to understand why. SM is more prevalent in broilers than roasters, and the potential for SM utilization in consumer products is a work in progress.

As for short term solutions, feed restriction is perhaps the most effective nutritional approach to controlling WB; but it is the least practical and most penalizing in terms of performance. Supporting antioxidant capacity by supplying adequate Vitamin E and selenium is a basic part of any nutrition program aimed to support meat quality. Vitamin C supplementation may be an option especially in heat stress. Avoiding diets that

stress oxidative capacity such using excessive crude protein or oxidized fats is prudent. Feed additives such phytase, Arginine, and GAA that may benefit productivity and meat quality should be utilized when possible. Overall, many of the nutritional recommendations to reduce WB have significant consequences to production and feed cost. Feed additives can add to feed cost and nutritional density changes can result in performance losses that hurt margins. Therefore, we must ensure the approaches to nutritional changes are yielding improvements that have meaningful results.

As for longer term genetic improvement, it is important to have more breed studies, particularly of male lines, to reduce WB. More work should be done around nutritional effects by transitional feed stages. Enlarging the database of sensory correlations to WB should also provide better and more consistent texture analyzer probe data (objective) to be correlated with consumers (subjective). There are many ongoing efforts to develop innovative yet relevant detection methods. Though high predictability rates are observed in research settings, the challenge is that woody breast is not homogenous in nature. A combination of methods may be advantageous to gain better detectability in processing plants.

Overall, breast myopathies remain an important focus across the poultry industry and whilst a lot of data and knowledge has been gathered, it is clear that there is still a lot to understand. As there are multiple factors impacting the occurrence of breast myopathies, their reduction relies on a holistic approach. Ongoing balanced breeding strategies by poultry breeders is targeting the longer-term genetic component but comprehending the significant influence from non-genetic factors (short-term solutions such as nutrition) remains a key area of opportunity. Consequently, understanding the physiology and biological needs of the muscle through the life of the bird is critical to reduce the myopathies (e.g., minimizing oxidative stress) and gain more insight into their aetiology.

ACKNOWLEDGMENTS

The authors would like to thank the Poultry Science Association for helping to organize this symposium.

DISCLOSURES

The authors declare no conflicts of interest.

REFERENCES

- Abasht, B., M. F. Mutryn, R. D. Michalek, and W. R. Lee. 2016. Oxidative stress and metabolic perturbations in wooden breast disorder in chickens (AG Passi, Ed.). *PLoS ONE* 11:e0153750.
- Aguirre, M. E., H. Leyva-Jimenez, R. Travis, J. T. Lee, G. Athrey, and C. Z. Alvarado. 2020. Evaluation of growth production factors as predictors of the incidence and severity of white striping and woody breast in broiler chickens. *Poult. Sci.* 99:3723–3732.
- Aguirre, M. E., C. M. Owens, R. K. Miller, and C. Z. Alvarado. 2018. Descriptive sensory and instrumental texture profile analysis of woody breast in marinated chicken. *Poult. Sci.* 97:1456–1461.
- de Almeida Mallmann, B. 2019. Prediction and Evaluation of Breast Myopathy. University of Arkansas, Fayetteville PhD Thesis.
- Anonymous. 2018. Broiler Management Handbook. Accessed December 2023. Available at https://aviagen.com/assets/Tech_Center/Ross_Broiler/Ross-BroilerHandbook2018-EN.pdf.
- Anonymous. 2022. Ross 308 AP Broiler: Performance Objectives. Accessed December 2023. Available at https://aviagen.com/assets/Tech_Center/Ross_Broiler/RossxRoss308AP-BroilerPerformanceObjectives2022-EN.pdf (verified 20 December 2023).
- Ausems, C. R. M., B. G. M. Van Engelen, H. Van Bokhoven, and D. G. Wansink. 2021. Systemic cell therapy for muscular dystrophies: the ultimate transplantable muscle progenitor cell and current challenges for clinical efficacy. *Stem Cell Rev. Rep.* 17:878–899.
- Bailey, R. A. 2023. Strategies and opportunities to control breast myopathies: an opinion paper. *Front. Physiol.* 14:1173564.
- Bailey, R. A., E. Souza, and S. Avendano. 2020. Characterising the influence of genetics on breast muscle myopathies in broiler chickens. *Front. Physiol.* 11:1–12.
- Bailey, R. A., K. A. Watson, S. F. Bilgili, and S. Avendano. 2015. The genetic basis of pectoralis major myopathies in modern broiler chicken lines. *Poult. Sci.* 94:2870–2879.
- Baldi, G., F. Soglia, and M. Petracci. 2020. Current status of poultry meat abnormalities. *Meat Muscle Biol.* 4:1–7.
- Baldi, G., F. Soglia, and M. Petracci. 2021. Spaghetti meat abnormality in broilers: current understanding and future research directions. *Front. Physiol.* 12:684497.
- Barbut, S. 2015. Chapter 5 - Primary processing of poultry. *The Science of Poultry and Meat Processing*. University of Guelph. Accessed December 2023. www.poultryandmeatprocessing.com.
- Barbut, S. 2020. Meat industry 4.0: a distant future? *Anim. Front.* 10:38–47.
- Barbut, S., and E. M. Leishman. 2022. Quality and processability of modern poultry meat. *Animals* 12(20):2766.
- Barbut, S., A. A. Sosnicki, S. M. Lonergan, T. Knapp, D. C. Ciobanu, L. J. Gatcliffe, E. Huff-Lonergan, and E. W. Wilson. 2008. Progress in reducing the pale, soft and exudative (PSE) problem in pork and poultry meat. *Meat Sci.* 79:46–63.
- Bauermeister, L. J., A. U. Morey, E. T. Moran, M. Singh, C. M. Owens, and S. Mckee. 2009. Occurrence of white striping in chicken breast fillets in relation to broiler size. *Poult. Sci.* 88:33.
- Bodle, B. C., C. Alvarado, R. B. Shirley, Y. Mercier, and J. T. Lee. 2018. Evaluation of different dietary alterations in their ability to mitigate the incidence and severity of woody breast and white striping in commercial male broilers. *Poult. Sci.* 97:3298–3310.
- Bordini, M., M. Mazzoni, M. Di Nunzio, M. Zappaterra, F. Sirri, A. Meluzzi, M. Petracci, and F. Soglia. 2024. Time course evaluation of collagen type IV in Pectoralis major muscles of broiler chickens selected for different growth-rates. *Poult. Sci.* 103:103179.
- Bordini, M., M. Zappaterra, F. Soglia, M. Petracci, and R. Davoli. 2021. Weighted gene co-expression network analysis identifies molecular pathways and hub genes involved in broiler White Striping and Wooden Breast myopathies. *Sci. Rep.* 11:1776.
- Bordignon, F., G. Xiccato, M. Boskovic Cabrol, M. Birolo, and A. Trocino. 2022. Factors affecting breast myopathies in broiler chickens and quality of defective meat: a meta-analysis. *Front. Physiol.* 13:933235.
- Bowker, B., H. Zhuang, S. C. Yoon, and G. Tasoniero. 2019. Relationships between attributes of woody breast and white striping myopathies in commercially processed broiler breast meat. *J. Appl. Poult. Res.* 28:490–496.
- Brambila, G. S., D. Chatterjee, B. Bowker, and H. Zhuang. 2017. Descriptive texture analyses of cooked patties made of chicken breast with the woody breast condition. *Poult. Sci.* 96:3489–3494.
- Branciarri, R., C. Mugnai, R. Mammoli, D. Miraglia, D. Ranucci, A. Dal Bosco, and C. Castellini. 2009. Effect of genotype and rearing system on chicken behavior and muscle fiber characteristics. *J. Anim. Sci.* 87:4109–4117.
- Cahaner, A. 2023. New insight on genetic and production factors affecting spaghetti meat abnormality in broilers. XXVth European Symposium on the Quality of Poultry Meat.
- Caldas-Cueva, J. P., C. J. Maynard, A. Mauromoustakos, and C. M. Owens. 2020. Effect of woody breast condition on instrumental texture characteristics of poultry deli loaves. *Meat Muscle Biol.* 4:1–10.

- Castilho Heiss, V. A., C. M. Komiya, D. K. Barbosa, M. F. Burbarelli, R. G. Garcia, and F. R. Caldara. 2024. A systematic review of nutritional strategies to mitigate pectoral myopathies in broiler chickens. *World's Poult. Sci. J* 1–18.
- Che, S., P. H. Pham, S. Barbut, D. Bienzle, and L. Susta. 2024. Transcriptomic profiles of Pectoralis major muscles affected by spaghetti meat and woody breast in broiler chickens. *Animals* 14:176.
- Che, S., L. Susta, and S. Barbut. 2023. Effects of broiler chilling methods on the occurrence of pale, soft, exudative (PSE) meat and comparison of detection methods for PSE meat using traditional and Nix colorimeters. *Poult. Sci.* 102:102907.
- Che, S., C. Wang, C. Varga, S. Barbut, and L. Susta. 2022. Prevalence of breast muscle myopathies (spaghetti meat, woody breast, white striping) and associated risk factors in broiler chickens from Ontario Canada. *Plos One* 17:e0267019.
- Cruz, R. F. A., S. L. Vieira, L. Kindlein, M. Kipper, H. S. Cemin, and S. M. Rauber. 2017. Occurrence of white striping and wooden breast in broilers fed grower and finisher diets with increasing lysine levels. *Poult. Sci.* 96:501–510.
- Estevez and Petracci. 2019. Benefits of magnesium supplementation to broiler subjected to dietary and heat stress: improved redox status, breast quality and decreased myopathy incidence. *Antioxidants* 8:456.
- FAO. 2022. Meat Market Review - Emerging Trends and Outlook. Food and Agriculture Organization of the United Nations. <https://www.fao.org/markets-and-trade/publications/detail/en/c/1653522/>.
- Greene, E., J. Flees, S. Dadgar, B. Mallmann, S. Orlowski, A. Dhamad, S. Rochell, M. Kidd, C. Laurendon, H. Whitfield, C. Brearley, N. Rajaram, C. Walk, and S. Dridi. 2019. Quantum blue reduces the severity of woody breast myopathy via modulation of oxygen homeostasis-related genes in broiler chickens. *Front. Physiol.* 10:1251.
- Hamill, L. 2021. Effects of wooden chicken breast muscle inclusion on consumer acceptability of breaded chicken breast nuggets. 4th Pangborn Sensory Science Symposium, Poster Program, P07.025.
- Hanning, C. O., X. Sun, J. P. Caldas-Cueva, and A. Mauromoustakos. 2020. System and method for detecting woody breast condition in broilers using image analysis of carcass features. Patent US10806153.
- Havenstein, G., P. Ferket, and M. Qureshi. 2003. Growth, livability, and feed conversion of 1957 versus 2001 broilers when fed representative 1957 and 2001 broiler diets. *Poult. Sci.* 82:1500–1508.
- Kuttappan, V. A., W. Bottje, R. Ramnathan, S. D. Hartson, C. N. Coon, B.-W. Kong, C. M. Owens, M. Vazquez-Anon, and B. M. Hargis. 2017. Proteomic analysis reveals changes in carbohydrate and protein metabolism associated with broiler breast myopathy. *Poult. Sci.* 96:2992–2999.
- Kuttappan, V. A., V. B. Brewer, J. K. Apple, P. W. Waldroup, and C. M. Owens. 2012. Influence of growth rate on the occurrence of white striping in broiler breast fillets. *Poult. Sci.* 91:2677–2685.
- Kuttappan, V. A., M. Manangi, M. Bekker, J. Chen, and M. Vazquez-Anon. 2021. Nutritional intervention strategies using dietary antioxidants and organic trace minerals to reduce the incidence of wooden breast and other carcass quality defects in broiler birds. *Front. Physiol.* 12:663409.
- Kuttappan, V. A., H. L. Shivaprasad, D. P. Shaw, B. A. Valentine, B. M. Hargis, F. D. Clark, S. R. McKee, and C. M. Owens. 2013. Pathological changes associated with white striping in broiler breast muscles. *Poult. Sci.* 92:331–338.
- Lake, A. J., and B. Abasht. 2020. Glucolipototoxicity: a proposed etiology for wooden breast and related myopathies in commercial broiler chickens. *Front. Physiol.* 11:169.
- Li, B., J. Lindén, E. Puolanne, and P. Ertbjerg. 2023. Effects of wooden breast syndrome in broiler chicken on sarcoplasmic, myofibrillar, and connective tissue proteins and their association with muscle fiber area. *Foods* 12:3360.
- Livingston, M. L., P. R. Ferket, J. Brake, and K. A. Livingston. 2019. Dietary amino acids under hypoxic conditions exacerbates muscle myopathies including wooden breast and white striping. *Poult. Sci.* 98:1517–1527.
- Maxwell, A. D., B. C. Bowker, H. Zhuang, D. Chatterjee, and K. Adhikari. 2018. Descriptive sensory analysis of marinated and non-marinated wooden breast fillet portions. *Poult. Sci.* 97:2971–2978.
- Mazzoni, M., F. Soglia, M. Petracci, F. Sirri, G. Lattanzio, and P. Clavenzani. 2020. Fiber metabolism, procollagen and collagen type III immunoreactivity in broiler pectoralis major affected by muscle abnormalities. *Animals* 10:1081.
- Meloche, K. J., B. I. Fancher, D. A. Emmerson, S. F. Bilgili, and W. A. Dozier. 2018a. Effects of quantitative nutrient allocation on myopathies of the Pectoralis major muscles in broiler chickens at 32, 43, and 50 days of age. *Poult. Sci.* 97:1786–1793.
- Meloche, K. J., B. I. Fancher, D. A. Emmerson, S. F. Bilgili, and W. A. Dozier. 2018b. Effects of reduced digestible lysine density on myopathies of the Pectoralis major muscles in broiler chickens at 48 and 62 days of age. *Poult. Sci.* 97:3311–3324.
- Meyer, M. M., and E. A. Bobeck. 2023. Dietary vasodilator and vitamin C/L-arginine/choline blend improve broiler feed efficiency during finishing and reduce woody breast severity at 6 and 7 wks. *Poult. Sci.* 102:102421.
- Morey, A., A. E. Smith, L. J. Garner, and M. K. Cox. 2020. Application of bioelectrical impedance analysis to detect broiler breast fillets affected with woody breast myopathy. *Front. Physiol.* 11:808.
- Mudalal, S., M. Lorenzi, F. Soglia, C. Cavani, and M. Petracci. 2015. Implications of white striping and wooden breast abnormalities on quality traits of raw and marinated chicken meat. *Animals* 9:728–734.
- Mueller, A. J. 2021. Assessment of Meat Quality Attributes of Four Commercial Broiler Strains Processed at Various Market Weights. University of Arkansas, Fayetteville MSc Thesis.
- Mueller, A. J., C. J. Maynard, A. R. Jackson, A. Mauromoustakos, M. T. Kidd, S. J. Rochell, J. P. Caldas-Cueva, X. Sun, A. Giampietro-Ganeco, and C. M. Owens. 2023. Assessment of meat quality attributes of four commercial broiler strains processed at various market weights. *Poult. Sci.* 102:102571.
- Nolan, M. L. 2023a. Woody breast detection: marketplace product evaluation. Unpublished internal company document. Perdue Foods LLC, Salisbury, MD, USA.
- Nolan, M. L. 2023b. Detection of spaghetti meat in broilers and roasters. Unpublished internal company document. Perdue Foods LLC, Salisbury, MD, USA.
- Oliveira, R. F.d., M. S. Fávero, J. L. Mello, F. B. Ferrari, et al. 2020. Physicochemical properties and consumer acceptance of hamburgers processed with chicken meat affected by wooden breast myopathy. *Animals* 10:2330.
- Oviedo-Rondón, E. O., and H. A. Córdova-Noboa. 2020. The potential of guanidino acetic acid to reduce the occurrence and severity of broiler muscle myopathies. *Front. Physiol.* 11:909.
- OECD-FAO. 2022. Global meat trade value by type. Accessed December 2023. <https://www.oecd-ilibrary.org/sites/cf68bf79-en/index.html?itemId=/content/component/cf68bf79-en>.
- Owens, C. M. 2014. Woody breast in the poultry meat industry. Mid-West Poultry Convention, Minneapolis, MN, USA. <https://midwestpoultry.com/>.
- Papah, M. B., E. M. Brannick, C. J. Schmidt, and B. Abasht. 2017. Evidence and role of phlebitis and lipid infiltration in the onset and pathogenesis of wooden breast disease in modern broiler chickens. *Avian Pathol.* 46:623–643.
- Papah, M. B., E. M. Brannick, C. J. Schmidt, and B. Abasht. 2018. Gene expression profiling of the early pathogenesis of wooden breast disease in commercial broiler chickens using RNA-sequencing (A Yildirim, Ed.). *PLoS ONE* 13:e0207346.
- Santos, M. N., D. Rothschild, T. M. Widowski, S. Barbut, E. G. Kiarie, I. Mandell, M. T. Guerin, A. M. Edwards, and S. Torrey. 2021. In pursuit of a better broiler: carcass traits and muscle myopathies in conventional and slower-growing strains of broiler chickens. *Poult. Sci.* 100:101309.
- Santos, M. M. F., D. A. S. Lima, Í. B. da Silva Araújo, et al. 2021. Effect of wooden breast myopathy on texture and acceptability of emulsified chicken patties. *J. Food Sci. Technol.* 58:4062–4067.
- Siegel, P. B. 2023. Broiler genetics and the future outlook. *Front. Physiol.* 14:1150620.
- Sihvo, H.-K., N. Airas, J. Lindén, and E. Puolanne. 2018. Pectoral vessel density and early ultrastructural changes in broiler chicken wooden breast myopathy. *J. Comp. Pathol.* 161:1–10.
- Sihvo, H.-K., K. Immonen, and E. Puolanne. 2014. Myodegeneration with fibrosis and regeneration in the Pectoralis major muscle of broilers. *Vet. Pathol.* 51:619–623.

- Sihvo, H.-K., J. Lindén, N. Airas, K. Immonen, J. Valaja, and E. Puolanne. 2017. Wooden breast myo degeneration of Pectoralis major muscle over the growth period in broilers. *Vet. Pathol* 54:119–128.
- Siller, W. G. 1985. Deep Pectoral Myopathy: A penalty of successful selection for muscle growth. *Poult. Sci.* 64:1591–1595.
- Simões, C. T., S. L. Vieira, C. Stefanello, L. Kindlein, T. Ferreira, A. Favero, and B. Xavier. 2020. An in vivo evaluation of the effects of feed restriction regimens on wooden breast using ultrasound images as a predictive tool. *Br. Poult. Sci.* 61:583–589.
- Smith, B., C. Rowe, C. Crist, T. Jarvis, W. Schilling, and X. Zhang. 2020. Quality differences in traditional and clean label chicken patties formulated with woody breast meat. *Meat Muscle Biol* 4, doi:10.22175/mmb.10565.
- Soglia, F., S. Mudalal, E. Babini, M. D. Nunzio, M. Mazzoni, F. Sirri, C. Cavani, and M. Petracci. 2016. Histology, composition, and quality traits of chicken Pectoralis major muscle affected by wooden breast abnormality. *Poult. Sci.* 95:651–659.
- Soglia, F., M. Petracci, R. Davoli, and M. Zappaterra. 2021. A critical review of the mechanisms involved in the occurrence of growth-related abnormalities affecting broiler chicken breast muscles. *Poult. Sci.* 100:101180.
- Soglia, F., A. K. Silva, S. Tappi, L. M. Lião, P. Rocculi, L. Laghi, and M. Petracci. 2019. Gaping of pectoralis minor muscles: magnitude and characterization of an emerging quality issue in broilers. *Poult. Sci.* 98:6194–6204.
- Solo, J. 2016. Meat Quality and Sensory Analysis of Broiler Breast Fillets With Woody Breast Muscle Myopathy. MSc Thesis. Accessed December 2023. <https://scholarworks.uark.edu/etd/1603>
- Solomon, M. B., R. L. J. M. Van Laack, and J. S. Eastridge. 1998. Biophysical basis of pale, soft, exudative (PSE) pork and poultry muscle: a review. *J. Muscle Foods* 9:1–11.
- Sun, X., J. You, C. J. Maynard, C. J. Maynard, J. P. Caldas-Cueva, A. Giampietro-Ganeco, and C. M. Owens. 2022. Assessment of meat quality distributions of breast fillets with woody breast condition in the raw and cooked state. *J. Food Sci. Technol.* 59:3557–3566, doi:10.1007/s13197-022-05353-z.
- Sun, X., D. A. Koltas, C. N. Coon, K. Chen, and C. M. Owens. 2018. Instrumental compression force and meat attribute changes in woody broiler breast fillets during short-term storage. *Poult. Sci.* 97:2600–2606.
- Sun, X., C. J. Maynard, J. P. Caldas-Cueva, C. N. Coon, and C. M. Owens. 2021. Using air deformation of raw fillet surfaces to identify severity of woody breast myopathy in broiler fillets. *LWT* 141:110904.
- Swatland, H. J. 1990. A note on the growth of connective tissues binding turkey muscle fibers together. *Can. Inst. Food Sci. Technol. J.* 23:239–241.
- Swerdlhoff, A. 2017. Wendy's is spending \$30 million to solve its rubbery chicken problem. Accessed December 2023. Available at <https://www.vice.com/en/article/wnb8nb/wendys-is-spending-30-million-to-solve-its-rubbery-chicken-problem> (verified 20 December 2023).
- Tasoniero, G., H. Zhuang, and B. Bowker. 2022. Biochemical and physicochemical changes in spaghetti meat during refrigerated storage of chicken breast. *Front. Physiol* 13:894544.
- Tijare, V. V., F. L. Yang, V. A. Kuttappan, C. Z. Alvarado, C. N. Coon, and C. M. Owens. 2016. Meat quality of broiler breast fillets with white striping and woody breast muscle myopathies. *Poult. Sci* 95:2167–2173.
- USDA, Processed products dominate U.S. broiler production, *Eco. Res. Service - U.S. Depart. Agric.*, 2014. Accessed June 2024. <https://www.ers.usda.gov/data-products/chart-gallery/gallery/chart-detail/?chartId=77558>.
- Velleman, S. G. 2015. Relationship of skeletal muscle development and growth to breast muscle myopathies: a review. *Avian Dis* 59:525–531.
- Velleman, S. G. 2023. Broiler breast muscle myopathies: association with satellite cells. *Poult. Sci* 102:102917.
- Velleman, S. G., C. S. Coy, and D. A. Emmerson. 2014. Effect of the timing of posthatch feed restrictions on the deposition of fat during broiler breast muscle development. *Poult. Sci* 93:2622–2627.
- Wang, J., D. L. Clark, S. K. Jacobi, and S. G. Velleman. 2020. Effect of vitamin E and omega-3 fatty acids early posthatch supplementation on reducing the severity of wooden breast myopathy in broilers. *Poult. Sci.* 99:2108–2119.
- Wang, J., D. L. Clark, S. K. Jacobi, and S. G. Velleman. 2021. Alpha-tocopherol acetate and alpha lipoic acid may mitigate the development of wooden breast myopathy in broilers at an early age. *Br. Poult. Sci* 62:749–758.
- Wang, C., L. Susta, and S. Barbut. 2022. Restoring functionalities in chicken breast fillets with spaghetti meat myopathy by using dairy proteins gels. *Gels* 8:558.
- Wang, C., L. Susta, and S. Barbut. 2023. Textural restoration of broiler breast fillets with spaghetti meat myopathy, using two alginate gels systems. *Gels* 10:7.
- Wilson, B. W., P. S. Nieberg, R. J. Buhr, B. J. Kelly, and F. T. Shultz. 1990. Turkey muscle growth and focal myopathy. *Poult. Sci* 69:1553–1562.
- Wold, J. P., I. Måge, A. Løvland, K. W. Sanden, and R. Ofstad. 2019. Near-infrared spectroscopy detects woody breast syndrome in chicken fillets by the markers protein content and degree of water binding. *Poult Sci* 98:480–490.
- Wold, J. P., E. Veiseth-Kent, V. Høst, and A. Løvland. 2017. Rapid on-line detection and grading of wooden breast myopathy in chicken fillets by near-infrared spectroscopy (G-J Nychas, Ed.). *PLoS ONE* 12:e0173384.
- Yoon, S.-C., B. C. Bowker, and H. Zhuang. 2016. Toward a fusion of optical coherence tomography and hyperspectral imaging for poultry meat quality assessment. *Electronic Imaging* 14:1–5.
- Yoon, S. C., B. Bowker, H. Zuang, K. C. Lawrence, G. W., Heitschmidt, and T. S. Shin. 2020. Imaging system for sorting poultry meat with wooden breast myopathy. Patent Number: WO/2018/213535
- Zampiga, M., F. Soglia, G. Baldi, M. Petracci, G. M. Strasburg, and F. Sirri. 2020. Muscle abnormalities and meat quality consequences in modern turkey hybrids. *Front. Physiol* 11:554.
- Zampiga, M., F. Soglia, M. Petracci, A. Meluzzi, and F. Sirri. 2019. Effect of different arginine-to-lysine ratios in broiler chicken diets on the occurrence of breast myopathies and meat quality attributes. *Poult. Sci* 98:2691–2697.
- Zuidhof, M. J., B. L. Schneider, V. L. Carney, D. R. Korver, and F. E. Robinson. 2014. Growth, efficiency, and yield of commercial broilers from 1957, 1978, and 2005. *Poult. Sci* 93:2970–2982.